tailed information on obstetrics & gynecology books, visit our website www.ejaypee.com, for detailed information on obstetrics & gynecology books, visit our website www.ejaypee.com

Complimentary Online 63 Videos Duration (5 hours 20 minutes)

State of the Art Atlas of Endoscopic Surgery in Infertility and Gynecology

3rd Edition

HYSTEROSCOPY

VOLUME 2



JAYPEE

ormation on obstetrics & gynecology books, visit our website www.ejaypee.com, for detailed information on obstetrics & gynecology books, visit our website www.ejaypee.com

Complimentary Online 63 Videos Duration (5 hours 20 minutes)

State of the Art Atlas of Endoscopic Surgery in Infertility and Gynecology

3rd Edition

LAPAROSCOPY

VOLUME 1

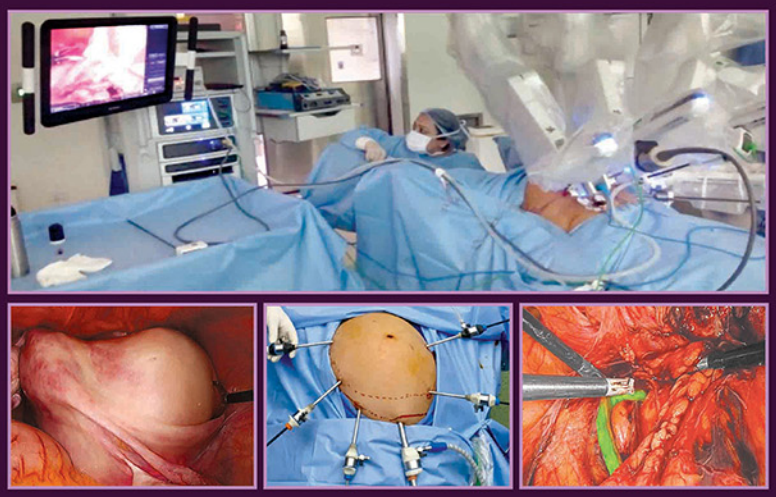

Nutan Jain

JAYPEE

Contents

Volume 1: Laparoscopy

SECTION 1: GENERAL

1. **Operating Room Setup and Basic Instrumentation for Gynecological Endoscopy** 1
   Nutan Jain, Vandana Jain, Divyanee Gulati
2. **Laparoscopic Retroperitoneal Anatomy** 13
   Farr R Nezhat, Connie S Liu, Ceana H Nezhat, Camran R Nezhat
3. **Laparoscopic Access** 26
   Giovanni Pecorella, Andrea Morciano, Gaetano Panese, Andrea Tinelli
4. **The Jain Point: Laparoscopic Entry** 42
   Nutan Jain, Vandana Jain, Sakshi Srivastava
5. **Laparoscopic Cutting and Hemostasis** 54
   Malcolm G Munro, Shivangini Sahay, Chetna Agrwal
6. **"1, 2 and V", Laparoscopic Suturing Simplified to the Core** 74
   Nutan Jain
7. **Laparoscopic Tissue Retrieval** 82
   Nutan Jain, Vandana Jain, Shivangini Sahay
8. **Laparoscopic Adhesion Prevention** 97
   Nutan Jain
9. **Correlation of Endosonography and Endoscopic Surgery** 107
   Narendra Malhotra, Neharika Malhotra, Jaideep Malhotra
10. **Anesthesia for Gynecological Laparoscopy Surgery: Enhanced Recovery after Surgery** 134
    Aarushi Jain

SECTION 2: MANAGEMENT OF ADNEXAL MASSES

11. **Triaging the Adnexal Masses** 140
    Agnaldo Lopes da Silva Filho, Gabriel Lage Neves, Matheus Eduardo Soares Pinhati
12. **Benign Ovarian Tumors** 149
    Nutan Jain, Vandana Jain
13. **Borderline Ovarian Tumors** 164
    Marco Arones Collantes, Julia López Grande, Juan Pablo García de la Torre
14. **Ovarian Transposition** 174
    Marco Arones Collantes, Gema Serrano García, Verónica López Honrubia-Chapter

15. **Evaluation and Management of Ectopic Pregnancy** 184
Amanda Ulrich, Rachel LaMonica, Danielle Luciano

16. **Cesarean Scar Niche and Scar Ectopic Pregnancy** 204
Michael Zebold, Mary McKenna

17. **Laparoscopic Treatment of Tubo-ovarian Abscesses** 212
Nutan Jain, Vandana Jain, Shivangini Sahay

SECTION 3: ENDOMETRIOSIS

18. **Peritoneal Endometriosis** 221
Ernesto Gallucci, Flávia Ribeiro, Hélder Ferreira

19. **Laparoscopic Management of Endometrioma** 227
Errico Zupi, Lucia Lazzeri, Eugenia Costantini, Ilaria Lampiasi

20. **Laparoscopic Excision of Rectovaginal Septum Adenomyosis** 237
Paulo Ayroza Ribeiro, Anna Luisa Lobão, Beatriz Taliberti Porto, Brunna Clemente, Ana Luisa Nicola, Helizabet Salomão

21. **Total Laparoscopic Hysterectomy with Extensive Endometriosis** 245
Nutan Jain, Vandana Jain, Chetna Agrwal

SECTION 4: INFERTILITY

22. **Laparoscopic Management of Polycystic Ovaries** 262
Nutan Jain, Shalini Singh, Chetna Agrwal

23. **Laparoscopic Surgery for Infertility** 271
Nutan Jain, Vandana Jain, Sakshi Srivastava

24. **Laparoscopic Microsurgery: Tubal Reanastomosis and Beyond** 284
Charles H Koh, Grace M Janik

SECTION 5: HYSTERECTOMY

25. **Laparoscopic Assisted Vaginal Hysterectomy** 294
Victoria Webber, Resad Paya Pasic, Allam Abdelmonem

26. **Laparoscopic Supracervical Hysterectomy** 308
Thomas L Lyons

27. **Total Laparoscopic Hysterectomy: Conventional and Novel Approaches** 318
Nutan Jain, Vandana Jain

28. **Laparoscopic Radical Hysterectomy of "The Pune-Techniques"** 343
Shailesh Puntambekar, Anjali Patil, Ravindra Sathe, Geetanjali Aggarwal, Seema Puntambekar

SECTION 6: PELVIC FLOOR REPAIR

29. **Laparoscopic Paravaginal Repair and Burch Urethropexy** 360
Robert D Moore, John R Miklos, Neeraj Kohli

30. **Laparoscopic Sacral Colpopexy and Enterocele Repair with Mesh** 372
Robert D Moore, John R Miklos, Neeraj Kohli

31. **Pectopexy for Pelvic Floor Repair** 387
Anneli Linnamägi

32. **Contemporary Edited Management of Stress Urinary Incontinence** 402
Nutan Jain, Shivangini Sahay

33. **Current Concepts in Rectocele Repair** 421
Jersey Burns, Petrina LaFaire, Amy Park

SECTION 7: MYOMA AND ADENOMYOMAS

34. **Contemporary Approach to Laparoscopic Myomectomy** 439
Charles Edward Miller, Kirsten Jill Sasaki

35. **Laparoscopic Assisted Myomectomy** 451
Nutan Jain, Shivangini Sahay, Sakshi Srivastava

36. **Backyard Theory for Cervical and Broad Ligament Myoma** 461
Nutan Jain, Vandana Jain, Shivangini Sahay

37. **Laparoscopic Adenomyomectomy** 474
Nutan Jain, Vandana Jain, Shivangini Sahay

SECTION 8: LAPAROSCOPY IN VARIED SITUATIONS

38. **Laparoscopic Management of Chronic Pelvic Pain** 492
Nutan Jain, Vandana Jain, Chetna Agrwal

39. **Laparoscopy in Genital Tuberculosis** 510
Nutan Jain, JB Sharma

40. **Laparoscopy in Pregnancy** 531
Togas Tulandi

41. **Laparoscopic Cerclage in Gravid and Nongravid Uterus** 536
Chintana R Chandra, Pandit Palaskar

42. **Laparoscopic Creation of Neovagina** 545
Nutan Jain, Vandana Jain

SECTION 9: COSMETIC GYNECOLOGY

43. **Cosmetogynecology** 554
Marco A Pelosi II, Marco A Pelosi III

SECTION 10: RECENT ADVANCES

44. **Use of Fluorescence-guided Surgery** 573
Nutan Jain, Vandana Jain, Shivangini Sahay

45. **Robot-assisted vNOTES for Gynecologic Indications** 581
Xiaoming Guan, Daniel Y Lovell, Qiannan Yang

46. Introduction of Robotics **590**
Nutan Jain, Vandana Jain, Chetna Agrwal

47. Laparoscopic Single-site Surgery **602**
B Ramesh, Shwetha Kamath, Vijaylaxmi Devarmani

SECTION 11: VAGINAL HYSTERECTOMY

48. Vaginal Hysterectomy **618**
Marco A Pelosi III

SECTION 12: COMPLICATIONS OF ENDOSCOPIC SURGERY

49. Extrocation: A Crucial Final Step in Laparoscopic Surgery **628**
Nutan Jain, Vandana Jain, Chetna Agrwal

50. Prevention and Management of Complications of Laparoscopy **635**
Nutan Jain, Vandana Jain, Shivangini Sahay

Index *I-0–I-00*

Volume 2: Hysteroscopy

1. Operating Room Setup and Instrumentation for Hysteroscopy **653**
Bolarinde Ola, Philomena Owende, Jude E Okohue

2. Advanced Operative Office Hysteroscopy **664**
Stefano Bettocchi, Divyanee Gulati, Chetna Agrwal

3. Endometrial Ablation **675**
Keith Isaacson, Tanvir Singh

4. Hysteroscopic Myomectomy **697**
Sabrina Reppuccia, Danilo Borrelli, Laura Carmen Ciccarelli, Massimiliano Pellicano, Attilio Di Spiezio Sardo

5. Intrauterine Adhesions (Asherman's Syndrome) **705**
Luis Alonso Pacheco, Ignacio Javier Brunel Garcia

6. Hysteroscopy for Metroplasty of Uterine Septa and Hypoplastic Uterus **713**
Nutan Jain, Shivangini Sahay

7. Hysteroscopic Tubal Cannulation for Proximal Tubal Block **723**
Nutan Jain, Vandana Goel

8. Classification of Microhysteroscopy and Hysterocolposcopy **730**
Alka Kumar, Luigi Montevecchi

9. Chronic Endometritis **739**
Alka Kumar, Nutan Jain

10. Routine Hysteroscopy before in Vitro Fertilization: Improving Fertility Outcomes 746
Radha Syed, Nutan Jain

11. Approach to Cervical Stenosis 754
Sukhbir S Singh, Hanan Alsalem

12. Fertiloscopy 761
A Watrelot, JG Grudzinskas

13. Role of Hysteroscopy in Endometrial Hyperplasia and Carcinoma Endometrium 777
Sergio Haimovich, Ursula Catena

14. Mini-Resectoscope 796
S Krishnakumar, Rohan Krishnakumar, Prapti Savant

15. Prevention and Management of Complications of Hysteroscopy 806
Patryk Piekos, Jose Carugno

Index I-0–I-00

CHAPTER 6

"1, 2 and V", Laparoscopic Suturing Simplified to the Core

Nutan Jain

INTRODUCTION

Laparoscopic suturing is an endoscopic skill necessary for the successful performance of a variety of advanced and complex laparoscopic procedures. Although some surgeons attempt to dismiss endosuturing as unnecessary, but most experienced endoscopic surgeons recognize that neither energy sources, clips or stapling devices can replace the need for suturing. As with conventional open surgery, laparoscopic suturing techniques permit restoration of normal anatomical relationships, organ reconstruction, approximation of tissue planes and establishment of hemostasis. Of the suturing and knot-tying methods adopted for laparoscopic surgery, the intracorporeal method remains the most difficult to master. Intracorporeal suturing is defined as the placement of a suture and the subsequent tying of a secure suture knot within the peritoneal cavity.

Once limited only to short straight or ski needles, endosuturing can now be performed with a variety of curved needles and different suture materials. The ability to utilize curved needle suturing provides surgeons with greater operative flexibility. Curve needle suturing has totally changed the dimensions of laparoscopic surgery. That is how nowadays laparoscopists are doing complex surgeries such as uterine prolapse repair, Burch colposuspension and tubotubal anastomosis. New curved needle holders have been designed to firmly hold the needle with minimal instability at the tip. This permits the SH, CT-1 needle to be driven through the tissue of various thickness and consistency. Suturing has dominated traditional open surgery for centuries. Laparoscopic suturing techniques were introduced and utilized by Kurt Semm in gynecology in the mid-1970s. The first significant step in the evolution of laparoscopic instruments[1] was combining the microsurgical handle with the laparoscopic instrument, permitting free movement and full rotation. The introduction of the two-handed suturing technique and the design of instruments as a matched pair, with each performing its specific role of needle driving or assisting grasper, is also important. To become skilled in laparoscopic suturing, endoscopic surgeons must learn to adept to the laparoscopic operating environment, i.e., acquire the skill of proper depth perception, hand-eye coordination, direct tactile sensation, steady practice and above all, patience.

EQUIPMENT

The following equipment is necessary for intracorporeal suturing:

- Two laparoscopic needle holders or one laparoscopic needle holder and a grasper.
- Suture materials.
- Laparoscopic scissors.

A 10 mm 0° or 30° telescope is used to permit direct visualization. The assistant holds the camera in a steady fashion, always keeping the target area in the center of the field of view. Proper placement of trocars is required for optimal intracorporeal suturing. As skills progress, advanced endoscopic surgeons will suture with ease from either side of the patient and either with the right or left hand. A telescope with a camera is placed in the umbilical region or anywhere between the umbilicus and xiphisternum ace to the size of the uterus/myoma. Ancillary ports are placed lateral to the inferior epigastric vessels.[2,3] Lower ports are placed 1–2 cm medial to the anterior superior iliac spine, though some surgeons may prefer a suprapubic port midway between pubic hairline and umbilicus and the other in the lower quadrant on the side, from where they are operating. Laparoscopic suturing in the pelvis is made easier by placing the upper trocar high, approximately at the level of the umbilicus, for continuous and prolonged suturing. A 10 mm trocar is needed to accommodate a Circle Taper 1 (CT-1) needle. A 5 mm trocar can be used for a small half-circle (SH)

JAYPEE BROTHERS

needle or smaller needles. The larger trocar is to be placed in the upper or lower lateral position. Alternatively, a 5 mm apple valveless trocar or metal trocars can be used for the "back loading" technique.

Needle Holders

- Self-righting needle holder with a fixed locking jaw mechanism.
- Standard articulating jaw needle holders that mimic open needle drivers.

Self-righting needle holders, such as Cook needle holders, EndoPath (Johnson & Johnson) needle holders, allow the needle to be grasped in an upright position, perpendicular to the needle driver, with little effort. One of the limiting factors of the self-righting needle holders is that one cannot grasp the suture with the needle holder, as it can damage the suture materials during the time of holding. Most advanced endoscopic surgeons, however, prefer the standard articulating jaw needle holder (Karl Storz and Wolf) that allows them to angle the needle preferably for a given stitch and to manipulate the suture. Needle holders are of two sizes, long and standard. Long needle holders will allow the surgeons to access deep structures in the pelvis. With this introduction, we would describe our own highly simplified manner of suturing.

Laparoscopic suturing is commonly considered to be complex, cumbersome and difficult to acquire skill and dreaded by most endoscopic surgeons. Suturing is the way upon the ladder of successful accomplishment of more advanced laparoscopic procedures. Being associated with suturing skills courses, training and teaching of residents, fellows and other gynae experts who now want to improve suturing skills, I realized, a lot of confusion exists in the minds of trainees and they regard it as a complex drill and are unwilling to go ahead with aligning the needle and making of throws and knots. We will try to give a very simplified, core basic way of doing laparoscopic suturing. Here, we will discuss only intracorporeal suturing utilizing the technique we prefer to call 1, 2 and V, the victory of laparoscopic suturing **(Fig. 1)**. Even the most novices of surgeons can be transformed into suturing wizards by the acquisition of this simple way of going ahead with laparoscopic suturing. Also, we would like to clarify that the technique we are going to demonstrate is compatible with ipsilateral, contralateral or mid suprapubic port placement **(Figs. 2A to C)**. It is beyond the restrictions of right-handed surgeons or left-handed surgeons, as it can be done by standing on the right side or left side of the patient. So, we like to call it the "Universal Method".

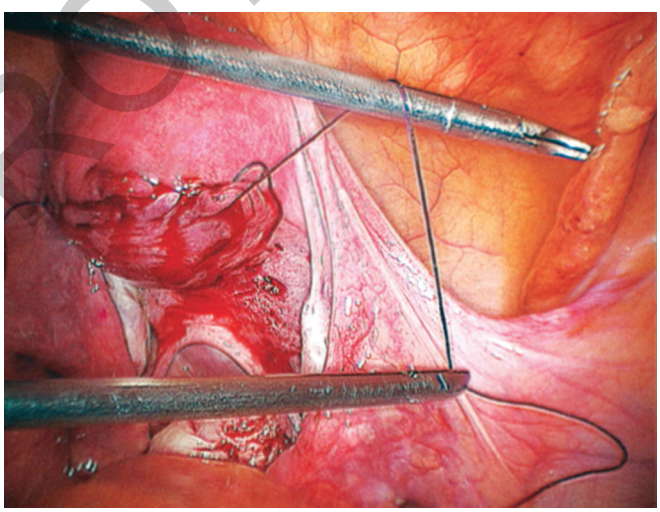

Fig. 1: "1, 2 and V," the victory of laparoscopic suturing.

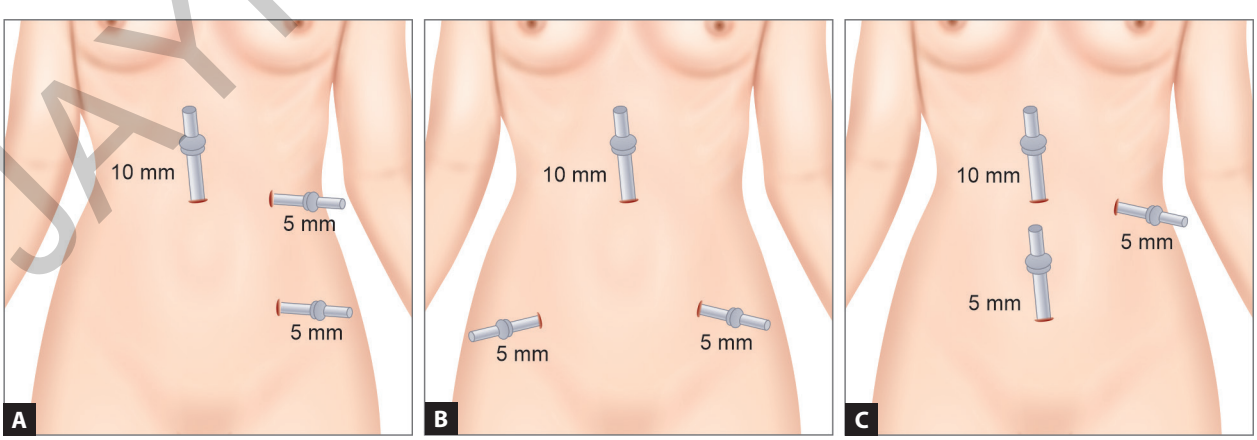

Figs. 2A to C: (A) Ipsilateral suturing port placement; (B) Contralateral suturing port placement; and (C) Suprapubic port placement.

JAYPEE BROTHERS

It does not make a difference; you stand on the right side of the patient or the left side of the patient. Best would be to try suturing by this simplified two-step procedure, standing on the right or left of the patient and using the right or left hand with the same port placement, as you have been doing till now. We do not want to create any confusion or controversy regarding ipsilateral or contralateral. Both are good techniques depending upon the surgeon's choice, comfort and particular surgical application.

Now, we shall Describe Our Simplified Technique

Length of suture: Beginners would better begin by using around 25 cm length of suture. More experience allows you to take more length of suture.[2]

Choice of Needle

Usually is a 36 mm curved round body or taper cut needle, but with the technique described ahead, even a 50 mm needle can be introduced easily.

Loading the Needle

Backloading of the suture is done. Here are the details of steps carried out on the trolley outside the patient's abdomen for preparing the needle to be inserted through the abdomen for suturing.

The best is to use short 5 mm valveless apple trocars, but a metal trocar can also be used. The 5 mm metal or valved trocar, which has been used till now in the surgery, is removed. The needle holder is now put in the apple trocar. It holds the tail at the end of the suture and brings it out of the trocar. Now the needle holder is again inserted and grasps the suture exactly about 2 cm from the hub of the needle. This is Step 1 **(Fig. 4A)**. Now this assembly of needle holder, suture and 5 mm apple trocar is ready for insertion **(Figs. 3A to C)** in the patient's abdomen.

Aligning the Needle

We advocate the use of two needle holders as this makes suturing faster, more accurate and better grip on the needle during suturing. The needle is grasped at 2 cm from the hub of the needle and this assembly is introduced from the nondominant hand position. Like for surgeons standing on the left and being right-handed, it will be introduced from the lower left port, and likewise for any further combination, as per the surgeon's position and being right or left-handed, port entry can be decided, but usually it is through the lower port. Now the needle is first introduced in the abdomen and the 5 mm trocar is threaded over it in the abdominal cavity. The needle is made to hang in the abdomen so that the concavity of the needle is towards the patient's legs or we call it the half-moon position. When the needle is hung in the abdomen, grasped at 2 cm from the hub rather than laid on any surface or tissue platform like the uterus, it is much easier to align it in the correct position. As the needle is held by the nondominant hand, the dominant hand brings another needle holder from the ipsilateral or contralateral port and comes into the abdomen and grasps the needle at the junction of its anterior two-thirds and posterior one-third. With a slight tug on the suture, the needle comes into instant alignment. Onlookers feel that these are self-righting needle holders **(Figs. 5A to E)**, but I simply say it is the "self-righting surgeon". Well, this is the most simplified way of aligning the needle. As most texts of laparoscopic suturing advocate one to nine steps of holding and aligning the needle, oversimplification to just two steps is a significant innovation.

Now, this needle holder held in the dominant hand passes the suture through the body tissue. As the needle comes out, it is instantly grasped by the other needle holder and this dominant hand needle holder presses the tissue back so that the needle comes out more easily to be grasped by the other needle holder without being dropped. In continuous curved needle suturing, it is extremely important to grasp the needle as soon as it comes out without letting it drop. If it drops, again we have to start from holding the suture at 2 cm from the hub of the needle and hanging it in the abdomen and again grasping it at the junction of the anterior two-third and posterior one-third **(Fig. 4B)**. Here lies the benefit of two needle holders as they grip better giving precision and speed, less chances of dropping the needle.

Making the Knot

We advocate the formation of letter V for making the throws and knots. Most texts till now in the literature advocate the making of a letter, P, B, Q, C and complex ways of fashioning the throws, which leave the novice a little confused as to which is the vertical limb of P and where to form the loop,[4] further confusing the reader. We advocate making the knots and throws by making a letter V.

JAYPEE BROTHERS

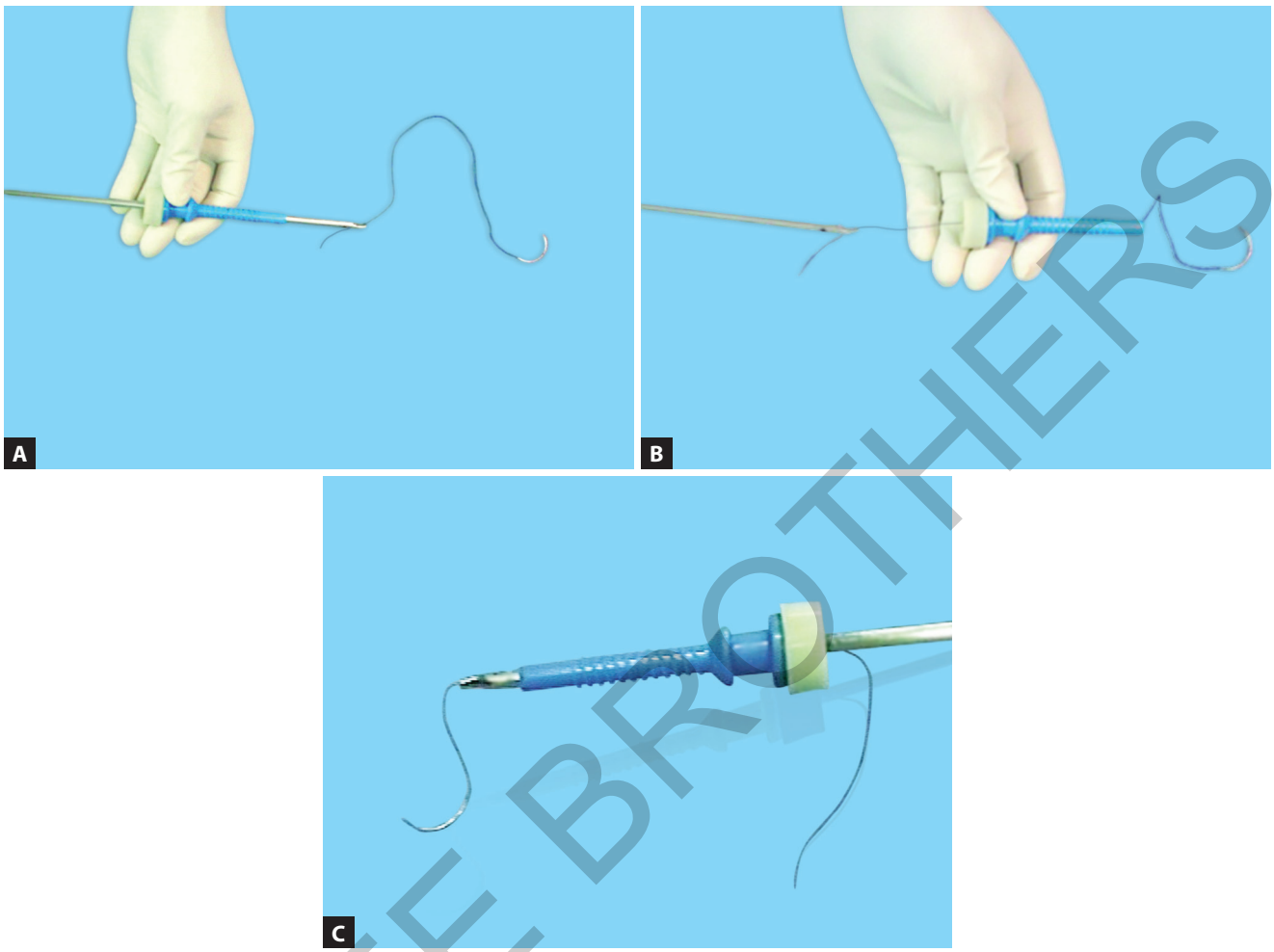

Figs. 3A to C: (A) Holding the free end of the suture and pulling it through the trocar; (B) Bringing the suture out through the valveless apple trocar; and (C) Completed loading of suture.

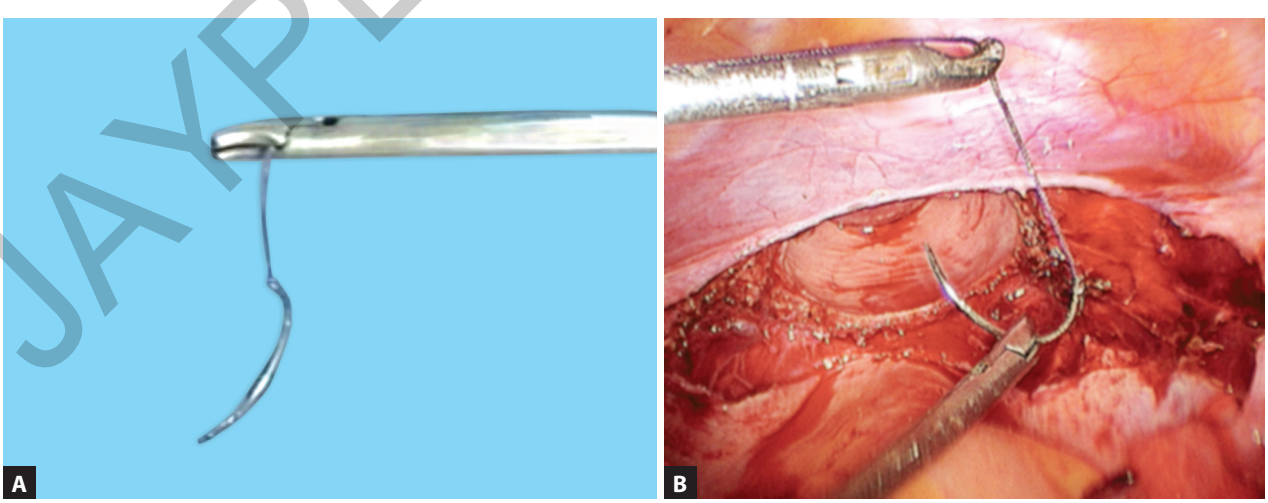

Figs. 4A and B: (A) Step 1: Holding the needle 2 cm away from the hub and (B) Step 2: Grasping the needle at the junction of the anterior two-thirds and posterior one-third.

JAYPEE BROTHERS

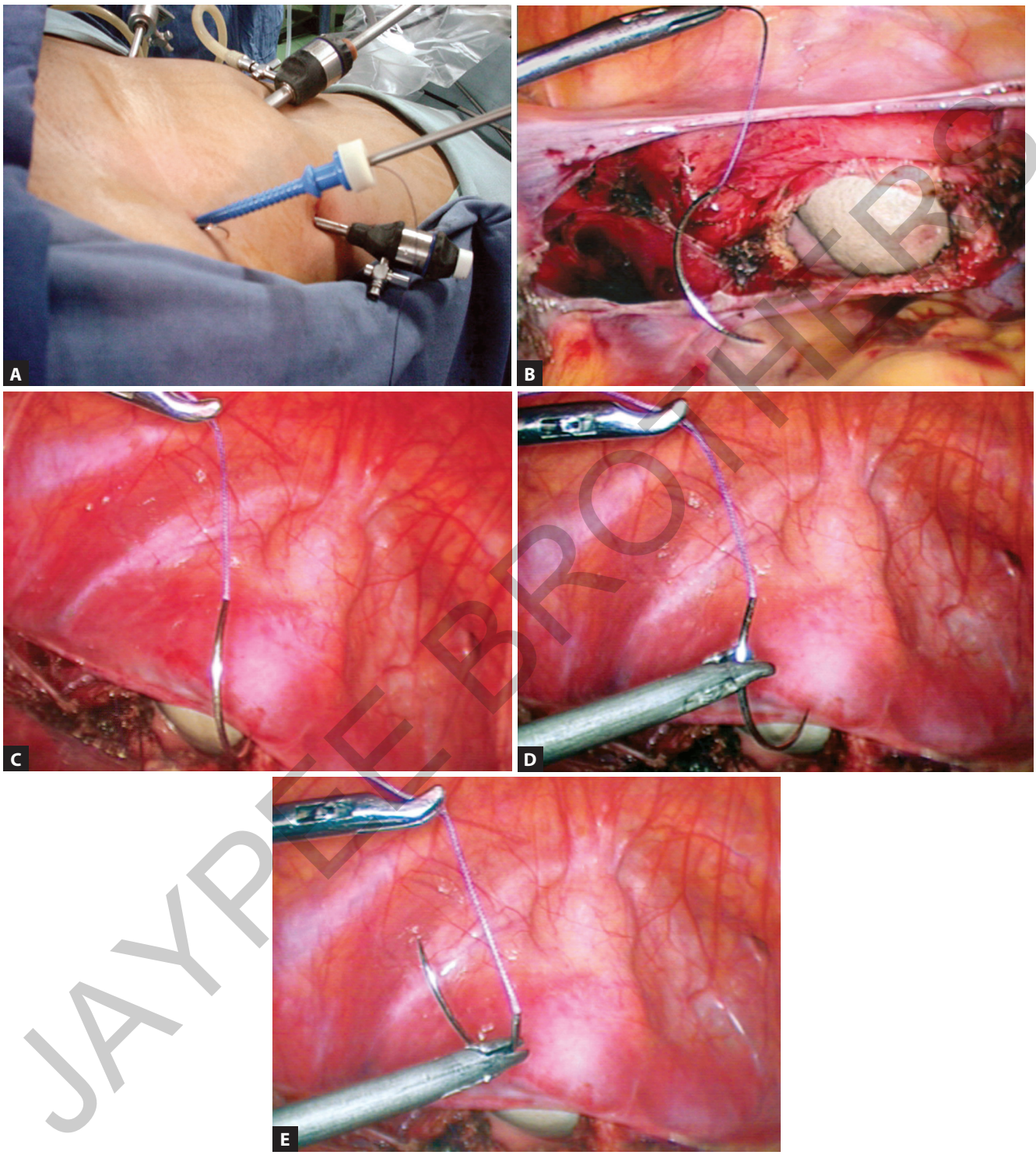

JAYPEE BROTHERS

Figs. 5A to E: (A) Insertion of the needle in the peritoneal cavity; (B) Introducing the curve needle by holding it 2 cm away from the hub by the left needle holder; (C) Hanging the needle vertically by the left needle holder with the concavity of the needle facing towards the pelvis; (D) Grasping the needle at the junction of the anterior two-thirds and posterior one-third by a right-handed needle holder; (E) By little tug on the thread from the left needle holder aligns the needle in the smiley position.

For this, as soon as the needle comes out of the tissue, the suture is pulled from the tissue till the tail end remains of about 2–3 cm. The needle is held like a boat or the smiley grip in the dominant hand needle holder and the left or nondominant needle holder hooks the suture upwards to form a letter V (inverted). Once this position is achieved, we start taking up one, two throws around the needle holder. Then the tail end of the suture is grabbed at the tip. The first knot is tied. The dominant hand needle holder, grasping the needle, is pulled while the other needle holder, grasping the tail of the suture, is kept relatively stationary, making it easy to spill the throws from the tip of the needle holder. If we move both needle holders, then the loops[5] get tightened over the needle holder, making their spill difficult. So, it is important to move only the dominant-handed needle holder and keep the nondominant hand rather stationary while tying the knot **(Figs. 6A to H)**. Like this, the first knot is tied, further one or two wraps are taken and the free end is held at the tip. To make a secure surgeon's knot, the two hands are pulled apart in the reverse direction to the first knot. Though we have extensively used the granny knot, in which both the knots are made by pulling the two needle holders in the same direction, we found that even the granny knot gives sufficient strength, having used it extensively in pelvic floor repair, and that too with "O" Prolene sutures. The ease of the granny knot lies in comfortably tying the knots in one direction only. The knots are secured, and excess suture is cut away.

Now, let us analyze the benefits of the formation of letter V over other P, B, Q, or C letters. In making a letter V with a needle in a boat configuration, both limbs of the throws are visible very clearly, and it is fashioned out at a

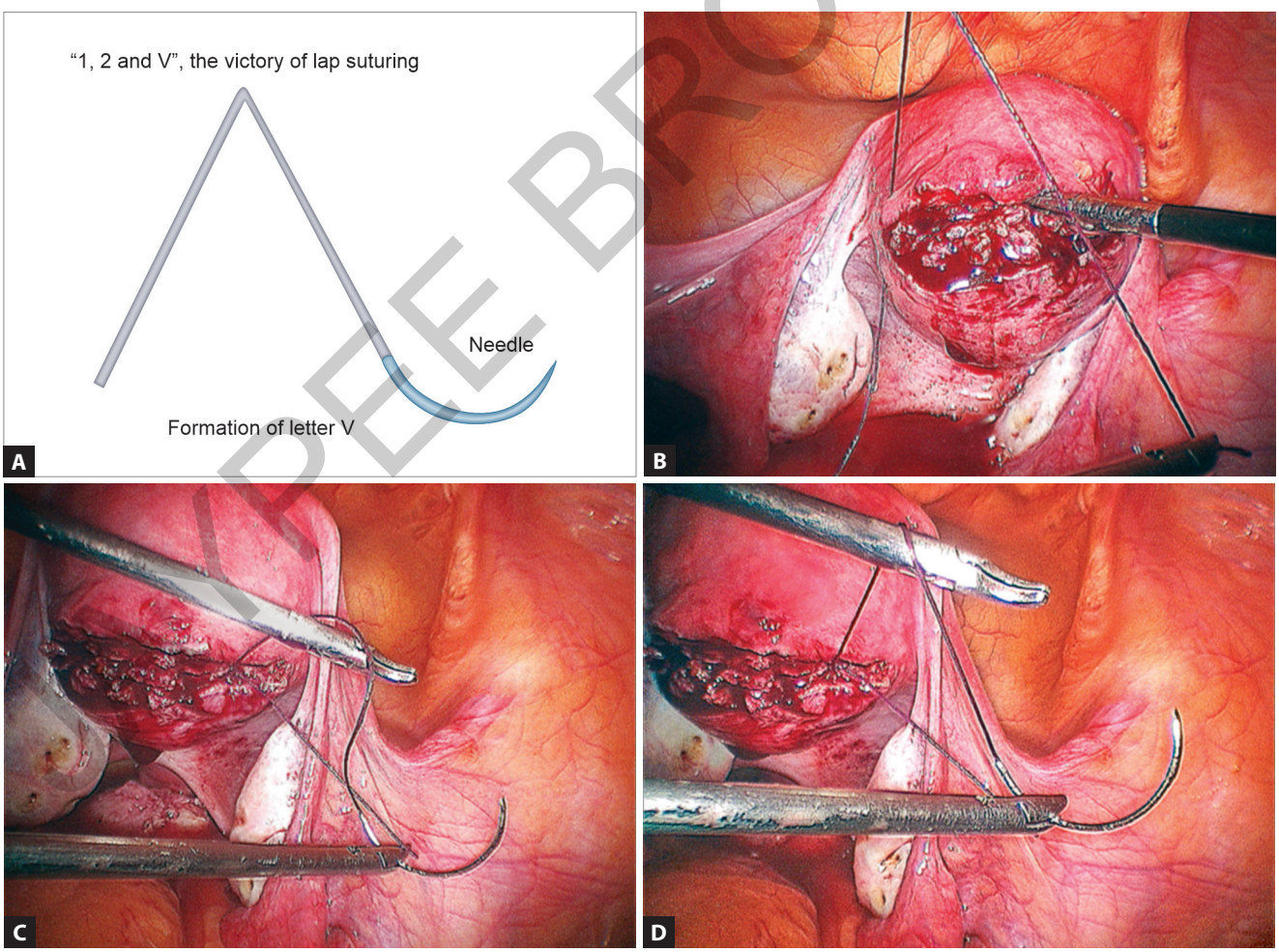

Figs. 6A to D

JAYPEE BROTHERS

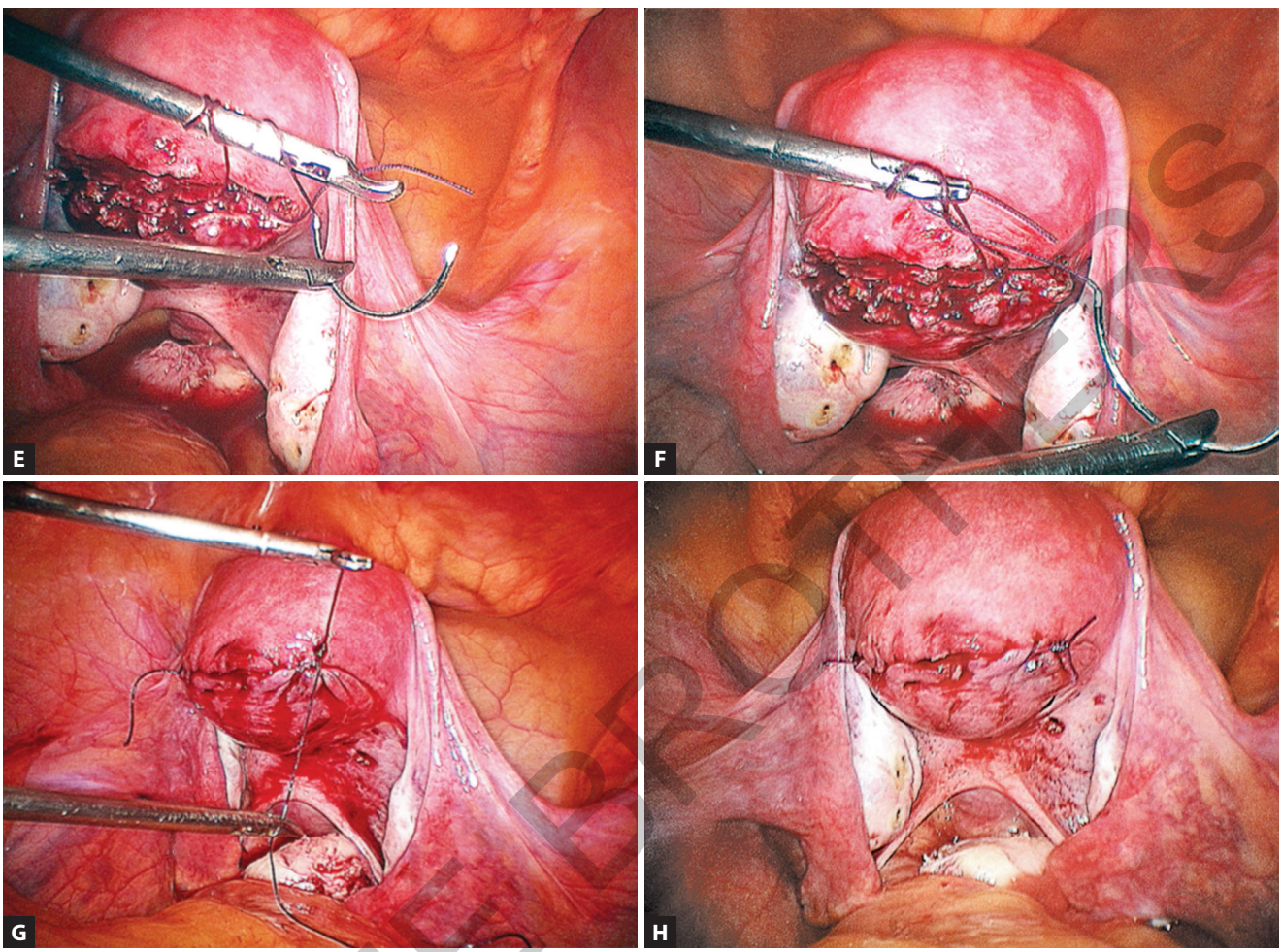

Figs. 6E to H

Figs. 6A to H: (A) Formation of letter "V"; (B) Showing the height of suture making "V" without a needle; (C) Needle held like a boat or the smiley grip in the dominant hand; (D) Nondominant needle holder hooks up the suture to form a letter V (inverted); (E) Taking 1 or 2 throws around the needle holder and tail end of the suture is grabbed at the tip of the suture; (F) Move only the dominant needle holder for spilling the suture; (G) Secure the surgeon's knot tied by pulling the two needle holders in opposite directions; and (H) Completed picture after subserosal closure.

JAYPEE BROTHERS

height from the body tissue, so there is no entanglement with the rest of the suture, or the tail end of the needle is moved away from intra-abdominal structures. This usually occurs when we are trying to make knots on the surface of the body tissue. We advocate that the surgeons make the throws and knots a little higher up in the pelvis so that both limbs of the V are clearly seen, and there is clarity of the rest of the suture and the tail end. Here lies the "1, 2, and V", the victory of laparoscopic suturing. So, making the letter V at a higher plane than the targeted tissue makes the wraps, throws and knots very simple, the most simplified way of doing suturing. The cut needle and thread are grabbed again closer to the needle and brought out via the lower port **(Figs. 7A and B)**.

For more detailed descriptions on suturing, the reader is referred to our textbook on laparoscopic suturing.

"State of the Art Atlas and Textbook of Laparoscopic Suturing."

In this text, we have encouraged surgeons to use this technique for application with an ipsilateral or contralateral approach. Use two needle holders and try to be ambidextrous to better utilize the full potential of laparoscopic suturing. Practice, patience, perseverance and passion make you more proficient. The rule of 5P.

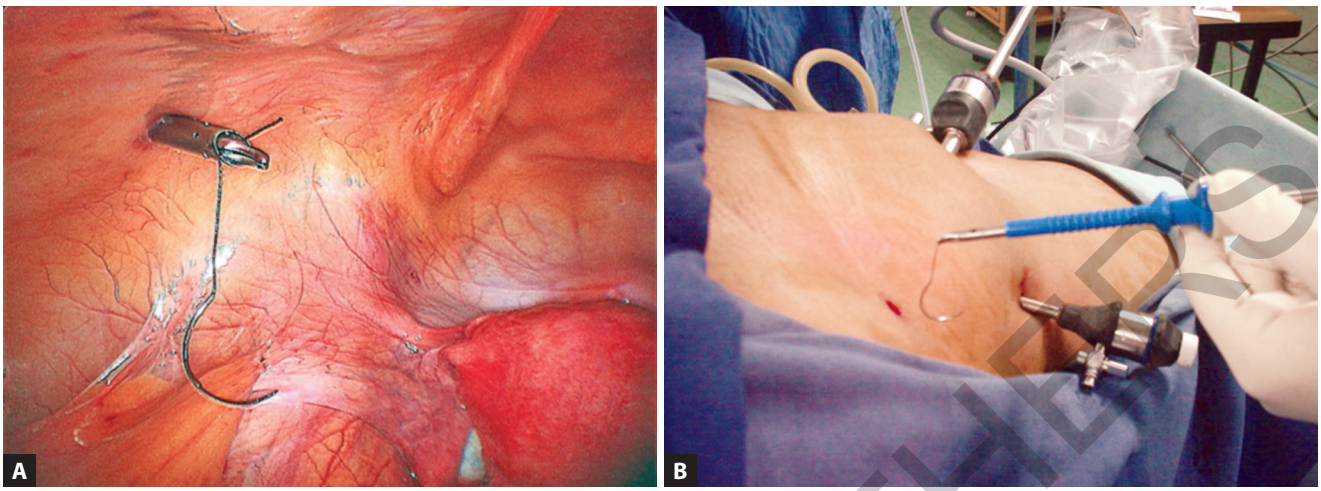

Figs. 7A and B: (A) Removing the needle from the abdominal cavity by removing the valveless, apply the trocar along with the needle and (B) Removing the needle from the abdominal cavity.

CONCLUSION

This manuscript tries to highlight the simple innovative technique of laparoscopic suturing, utilizing 2 needle holders, using two steps of holding and aligning the needle. It has been the author's experience that the formation of the letter "V" is an oversimplification of the intricacies of knot tying. We have provided descriptive pictures to understand the exact technique. A video has also been included to explain more clearly the relevance of the term "1, 2 and V", the victory of laparoscopic suturing. Understand it, practice it, master it and then enjoy unlimited access to advanced laparoscopic procedures requiring suturing.

REFERENCES

1. McComb PF. A new suturing instrument that allows the use of microsuture at laparoscopy. Fertil Steril. 1992; 57(4):936-8.
2. Desai PJ, Moran ME, Calvano CJ, Parekh AR. Running suturing: The ideal length facilitates this task. J Endoural. 2000;14(2):191-4.
3. Nathanson LK, Nathanson PDK, Cuschieri A. Safety of vessel ligation in laparoscopic surgery. Endoscopy. 1991;23(4):206-9.
4. Reich H, McGlynn F. Laparoscopic repair of bladder injury. Obstet Gynecol. 1990;76(5 Pt 2):909-10.
5. Pier A, Thevissen P, Eikel M, Götz F. Laparoskopische Naht- und Knüpftechniken [Laparoscopic suture and knot techniques]. Chirurg. 1994;65(5):473-83. German. PMID: 8050302.

JAYPEE BROTHERS

for detailed information on obstetrics & gynecology books, visit our website www.ejaypee.com, for detailed information on obstetrics & gynecology books, visit our website www

State of the Art
Atlas of Endoscopic Surgery in Infertility and Gynecology
LAPAROSCOPY

The third edition is a whole new textbook which is designed to include the latest technological advances which have occurred since the second edition was released. This atlas is a unique collection of all possible major and minor laparoscopic procedures. All the chapters are dealt with in the most exquisite manner with attention to every minute details. The richness of the textbook is further enhanced by a number of color illustrations, figures, graphic representations, and tables to impress upon the reader with the utmost clarity of the surgical steps and techniques. This textbook written by a team of global superspecialists becomes the most outstanding due to its multinational authorship. Each author has been well-chosen, keeping in mind their skills and expertise to cover a particular surgery. How the world differs in techniques with a change of continents also adds to the diversity of this atlas. To have so many renowned authors contributing within one book itself speaks volumes about the immense value of the *State of the Art: Atlas of Endoscopic Surgery in Infertility and Gynecology*. This book is well organized in 12 sections, covering all applications of "Gynecological Laparoscopic Surgeries." This book, with its rich text, is worthy of a place in any library, surgeon's desk, or an indispensable tool for a novice laparoscopic surgeon aspiring to advance their surgical skills.

Highlights

- International team of contributors
- Pictorial description of surgical steps
- More than 1930 color images and about 300 illustrations
- Streaming audio-narrated videos from live surgeries
- Covers all established and newer applications of laparoscopic surgery.

Nutan Jain MS (Obstetrics and Gynecology) is the Director, Department of Obstetrics and Gynecology, Vardhman Trauma and Laparoscopy Centre Pvt Ltd, Muzaffarnagar, Uttar Pradesh, India. She is an internationally recognized Gynecologic Endoscopic Surgeon and Educator, revered for her pioneering contributions to minimally invasive surgery. She has authored nine textbooks on laparoscopic surgery, several of them translated into Spanish and Chinese. Her latest publication, *Complex Total Laparoscopic Hysterectomy (TLH) with Newer Approaches in Bladder Dissection*, has become a well-recognized text.

She has been inducted into the International Advisory Board by the Society of Laparoscopic and Robotic Surgeons (SLS), USA. She has been nominated for the AAGL Board of Directors in 2009 and 2019 to represent the Asia-Pacific region and she performed a live telesurgery relay to the AAGL 46th Annual Global Congress in Washington, DC, USA (2017), showcasing her surgical excellence on the global stage.

She had the courage to think out of the box and introduced the innovative laparoscopic entry port, "The Jain Point," which revolutionized safe abdominal access and earned her the Best Innovation Award (1st Prize) at ASICON 2021 by the Association of Surgeons of India. Her research on the "Role of ICG" received the prestigious Harrith M Hasson Award for Best Presentation Promoting Education or Training at SLS MIS 2024, Florida, USA.

Her training programs and fellowships are among the most sought after. Through this book, she continues her lifelong mission—to share her innovative expertise and advance the art and safety of laparoscopic surgery for surgeons across the world.

Shelving Recommendation
OBSTETRICS & GYNECOLOGY

ISBN 978-93-7202-542-2

Buy from ejaypee

JAYPEE BROTHERS