information on anatomy books, visit our website www.ejaypee.com, for detailed information on anatomy books, visit our website www.ejaypee.com, for detailed information on anatomy books, visit our website www.ejaypee.com

Inderbir Singh's Textbook of

HUMAN HISTOLOGY

With Clinically Integrated Approach

As per the Revised Competency-based Medical Education Curriculum (NMC)

BEST SELLER Since 50 Years

Dr. Wise
Innovative & Genius AI Chatbot
access code inside

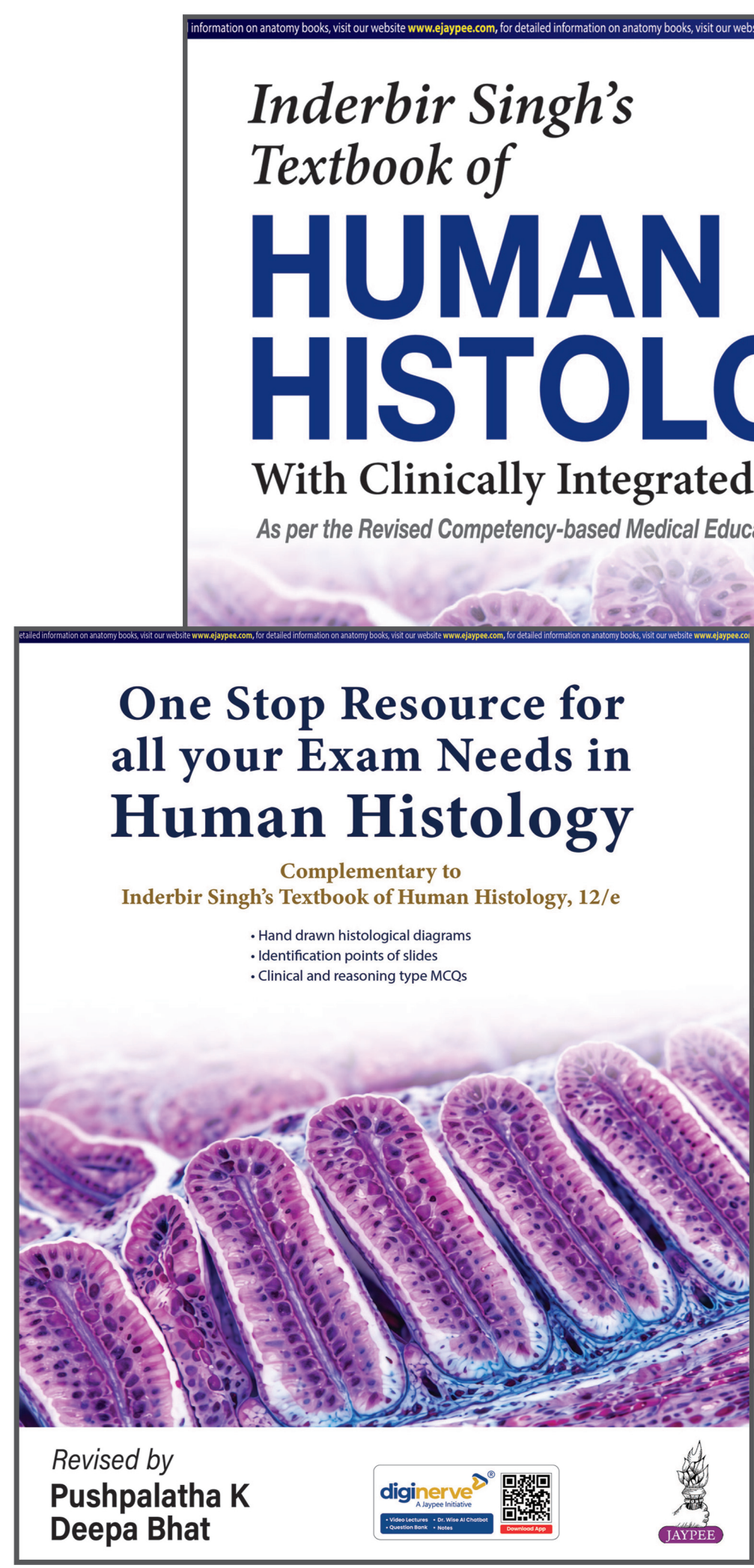

etailed information on anatomy books, visit our website www.ejaypee.com, for detailed information on anatomy books, visit our website www.ejaypee.com, for detailed information on anatomy books, visit our website www.ejaypee.com

One Stop Resource for all your Exam Needs in Human Histology

Complementary to
Inderbir Singh's Textbook of Human Histology, 12/e

- Hand drawn histological diagrams
- Identification points of slides
- Clinical and reasoning type MCQs

Revised by
Pushpalatha K
Deepa Bhat

diginerve® A Jaypee Initiative
• Video Lectures • Dr. Wise AI Chatbot • Question Bank • Notes
Download App

JAYPEE

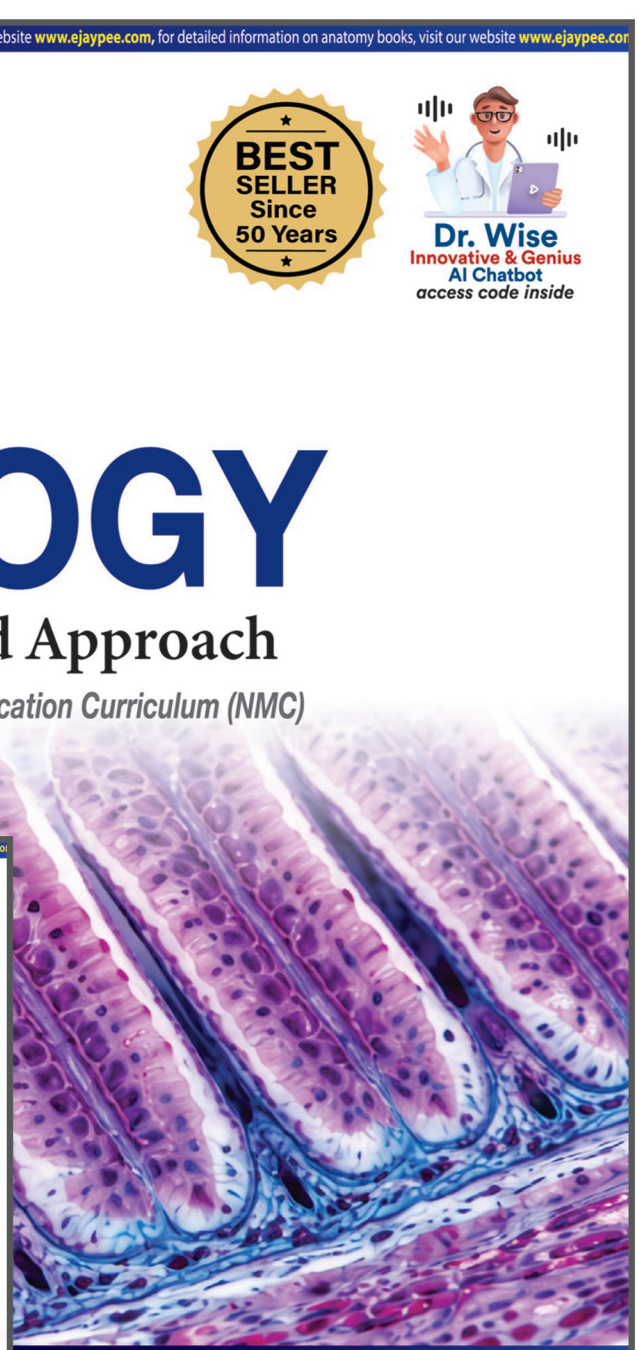

I your Exam Needs'

12th Edition

Genuine?
Scratch, Scan & Validate

JAYPEE

Contents

1. Light Microscopy and Tissue Preparation 1
   - History 1
   - Classification 1
   - Parts of a Light Microscope 1
   - Principle of Microscopy 3
   - Practical Tips in Using a Bright-Field Microscope 3
   - Types of Microscopes 4
   - Tissue Processing 4

2. Cell Structure 6
   - Components of a Cell 6
   - Projections from the Cell Surface 16
   - Staining of a Cell 18

3. Epithelia and Glands.....20
   - **Epithelia 20**
   - General Features of Epithelial Tissue 20
   - Functions 20
   - Structure of Epithelial Cell 20
   - Classification of Epithelia 21
   - Basement Membrane 33
   - **Glands 35**
   - Characteristic Features 35
   - Applied Histology 35
   - Classification of Glands 36
   - Classification of Exocrine Glands 36
   - Structure of Secretory Component 37
   - Development of Glands 38

4. General Connective Tissue 41
   - General Features 41
   - Classification of Connective Tissue 41
   - Components of Connective Tissue 41
   - Cells 42
   - Fibers of Connective Tissue 46
   - Intercellular Ground Substance of Connective Tissue 49
   - Different Forms of Connective Tissue 50
   - Functions of Connective Tissue 52
   - Applied Histology 54
   - Connective Tissue with Special Properties 54

5. Cartilage.....56
   - General Features of Cartilage 56
   - Perichondrium 56
   - Components of Cartilage 57
   - Types of Cartilage 57

6. Bone.....65
   - General Features 65
   - Composition of Bone Tissue 65
   - Bone Membranes 67
   - Classification and Structure of Bone 69
   - Formation of Bone—Ossification 74
   - How Bones Grow? 76

7. Muscular Tissue.....81
   - Types of Muscular Tissue 81
   - Applied Histology 92
   - Myoepithelial Cells 92

8. Lymphatics and Lymphoid Tissue 94
   - Classification 94
   - Lymph 95
   - Lymphatic Vessels 95
   - Lymphocytes 96
   - Lymph Nodes 97
   - Spleen 100
   - Thymus 103
   - Mucosa-Associated Lymphoid Tissue 106
   - Tonsils 107
   - Mononuclear Phagocyte System 107

9. Nervous Tissue 111
   - Structure of a Neuron 111
   - Neuroglia 114
   - Myelin Sheath 116
   - Types of Neurons 116
   - Peripheral Nerves 117
   - Optic Nerve 117
   - Ganglia 118

10. Cardiovascular System.....125
   - Basic Structure of a Blood Vessel 125
   - Structure of Arteries 127
   - Arterioles 129
   - Capillaries 131
   - Veins 131
   - Venules 132
   - Nutrition and Innervation of Blood Vessels 134
   - Heart 134

11. Skin and its Appendages.....137
   - Functions of Skin 137
   - Types of Skin 137

Structure of Skin 137
Blood Supply of the Skin 141
Nerve Supply of the Skin 142
Appendages of the Skin 142

12. Salivary Glands....149
Types of Salivary Glands 149

13. Placenta and Umbilical Cord 158
Placenta 158
Microscopic Structure 159
Placental Circulation and Barrier 161
Functions 161
Umbilical Cord 164

14. Respiratory System....167
Common Features of Air Passages 167
Nasal Cavities 167
Pharynx 170
Larynx 170
Trachea 171
Principal Bronchi 171
Lungs 171

15. Digestive System: Oral Cavity and Related Structures 180
Oral Cavity 180
Lips 180
Teeth 181
Tongue 184

16. Gastrointestinal Tract, Stomach and Intestines....190
General Structure of GIT 190
Esophagus 192
Stomach 194
Small Intestine 199
Large Intestine 206
Vermiform Appendix 208
Endocrine Cells of the Gut 210

17. Hepatobiliary System and Pancreas 213
Liver 213
Extrahepatic Biliary Apparatus 219
Gallbladder 219
Extrahepatic Ducts 219
Pancreas 221
Differences Between Serous Salivary Gland and Pancreas 224

18. Urinary System....227
Functions of Urinary System 227
Kidney 227
Cortex 228
Ureter 237
Urinary Bladder 239
Urethra 239

19. Spinal Cord, Cerebellar Cortex and Cerebral Cortex....243
Spinal Cord 243
Cerebral Cortex 245
Cerebellar Cortex 249

20. Male Reproductive System....255
Testis 255
Spermatogenesis 260
Epididymis 263
Ductus Deferens 263
Seminal Vesicle 265
Prostate 265
Penis 268

21. Female Reproductive System 273
Ovary 273
Uterine Tubes/Oviducts 280
Uterus 280
Cervix 285
Vagina 287
Female External Genitalia 287
Mammary Gland 289

22. Endocrine System 294
Hormones 294
Distribution of Endocrine Cells 295
Hypophysis Cerebri (Pituitary Gland) 295
Thyroid Gland 301
Parathyroid Glands 304
Suprarenal Glands/Adrenal Glands 304
Pineal Gland 308
Diffuse Neuroendocrine or APUD Cell System 309
Some Other Organs Having Endocrine Functions 310

23. Special Senses: Eye 313
Structure of Eyeball 313
Outer Fibrous Coat 313
Lens 325
Accessory Visual Organs 325

24. Special Senses: Ear 329
External Ear 329
Middle Ear 330
Internal Ear 330

Index *337*

CHAPTER

9

Nervous Tissue

COMPETENCIES ADDRESSED

AN68.1: Describe and identify multipolar and unipolar neuron, ganglia, peripheral nerve.
AN68.2: Describe the structure-function correlation of neuron.
AN68.3: Describe the ultrastructure of nervous tissue.
AN43.3: Identify, describe and draw microanatomy of optic nerve.



Case Scenario

A 30-year-old man presented with dizziness and experienced a sudden loss of consciousness accompanied by seizures. He was promptly taken to the emergency room, where a neurologist conducted an examination and ordered an MRI scan. The MRI showed multiple lesions with heterogeneously ring-enhanced characters in the right hemisphere, diagnosed as multifocal glioblastoma. Following this diagnosis, he underwent a craniotomy and tumor excision, followed by a course of radiotherapy and chemotherapy. Unfortunately, he experienced a recurrence of the disease after one year and ultimately succumbed to it. Glioblastomas, the most common type of brain tumors, typically originate from glial cells.

Comprehending the histological characteristics of nervous tissue serves as the foundation for correlating diagnosis with clinical presentation, thus determining the severity of the disease.

INTRODUCTION

- The nervous system is a **specialized type** of tissue that has property of ability to conduct impulses rapidly from one part of the body to another. Nerve cells can convert information obtained from the environment into codes that can be transmitted along their axons. By such coding, the same neuron can transmit different kinds of information.
- The total number of neurons in the human brain is estimated at more than 1 trillion. Nervous tissue is composed of neurons and neuroglia. ***Neurons*** are the structural and functional unit of nervous system and ***Neuroglia*** is the supporting connective tissue cells present in nervous system.
- The nervous system may be divided into the **central nervous system (CNS)**, made up of the brain and spinal cord, the **peripheral nervous system (PNS)**, consisting of the peripheral nerves and the ganglia associated with them, and the **autonomic nervous system**, consisting of the **sympathetic** and the **parasympathetic nervous systems (Flowchart 9.1)**.

STRUCTURE OF A NEURON

- Neurons are responsible for the receptive, integrative, and motor functions of the nervous system. Neurons vary considerably in size, shape, and other features. However, most of them have some major features in common, and these are described further.
- Neuron is made up of the following parts:

Cell Body/Soma/Perikaryon

A neuron consists of a **cell body** that gives off a variable number of **processes (Fig. 9.1)**.

Cytoplasm

- Like a typical cell, it consists of a mass of cytoplasm surrounded by a cell membrane.
- The cytoplasm contains a large central nucleus with a prominent nucleolus, highly developed rough endoplasmic reticulum, numerous mitochondria, lysosomes, and a Golgi complex **(Fig. 9.2)**.

JAYPEE BROTHERS

Flowchart 9.1: Anatomical classification of nervous system.

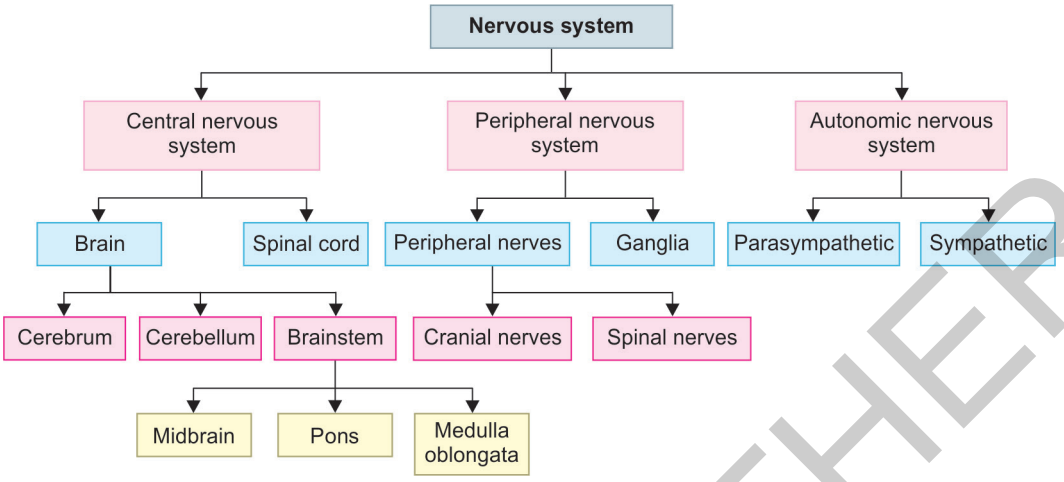

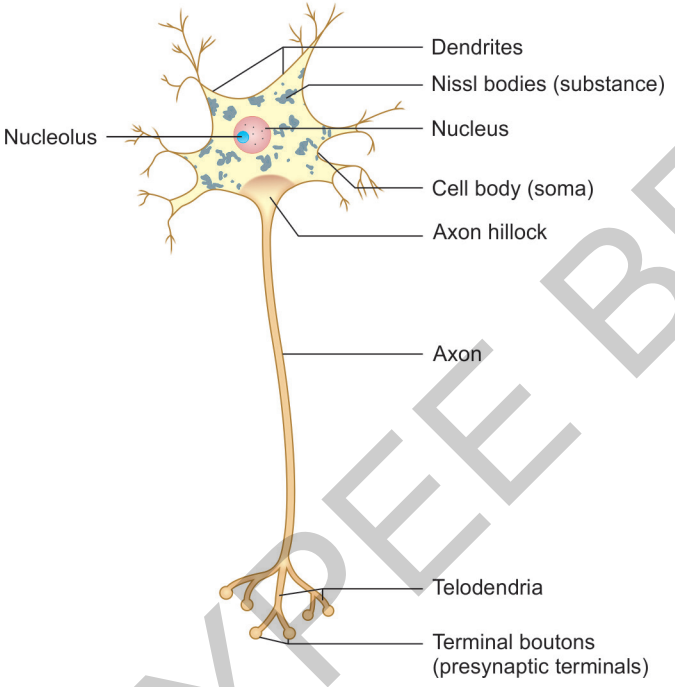

Fig. 9.1: Some parts of a neuron (schematic representation).

Nissl Substance

- The cytoplasm shows the presence of a granular material that stains intensely with basic dyes; this material is the **Nissl substance** (also called Nissl bodies or granules) **(Fig. 9.2)**.
- When examined by electron microscope (EM) **(Fig. 9.2)**, these bodies are seen to be composed of rough surfaced endoplasmic reticulum **(Fig. 9.2)**. The presence of abundant granular endoplasmic reticulum is an indication of the high level of protein synthesis in neurons. The proteins are needed for maintenance and repair, and for the production of neurotransmitters and enzymes.

Neurofibrils

- Another distinctive feature of neurons is the presence of a network of fibrils permeating the cytoplasm **(Fig. 9.2)**.
- These **neurofibrils** are seen when prepared by silver impregnation.
- When seen under EM, it shows microfilaments, micro tubules, and neurofilaments (the centrioles present in neurons may be concerned with the production and maintenance of microtubules).

Neurites

- The processes arising from the cell body of a neuron are called **neurites**.
- These are of two kinds, number of short branching processes called **dendrites** and one longer process called an **axon (Table 9.1)**.

Axon

- The axon may extend for a considerable distance away from the cell body. The longest axons may be as much as 1 meter long.
- Each axon has a uniform diameter and is devoid of Nissl substance. The Nissl-free zone extends for a short distance into the cell body: this part of the cell body is called the **axon hillock**. The part of the axon just beyond the axon hillock is called the **initial segment**.

JAYPEE BROTHERS

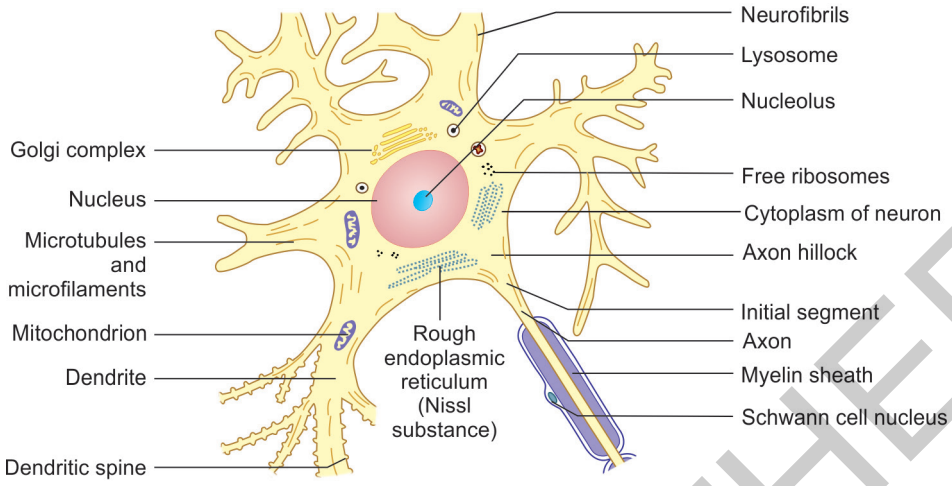

Fig. 9.2: Neuron stained to show Nissl substance. Note that the Nissl substance extends into the dendrites but not into the axon.

Table 9.1: Differences between axons and dendrites.

Axon	Dendrites
Axon is a single, long, and thin process of a nerve cell, which terminates away from the nerve cell body	Dendrites are multiple, short, thick, and tapering processes of the nerve cell which terminate near the nerve cell body
Axon rarely branches at the right angle (axon collaterals) but ends by dividing into many fine processes called axon terminals	Dendrites are highly branched. Their branching pattern forms a dendritic tree
It has uniform diameter and smooth surface	• The thickness of dendrite reduces as it divides repeatedly • Its surface is not smooth, but it bears many small spine-like projections for making synaptic contacts with the axons of other nerve cells
It is free of Nissl granules	Nissl granules are present in dendrites
The nerve impulses travel away from the cell body	The nerve impulses travel toward the cell body

- The axon hillock and the initial segment of the axon are of special functional significance. This is the region where action potentials are generated (spike generation), resulting in conduction along the axon.
- The initial segment is unmyelinated. It often receives axoaxonal synapses that are inhibitory. The plasma membrane here is rich in voltage sensitive channels.
- Some neurons contain pigment granules, e.g., neuromelanin in neurons of the substantia nigra. Aging neurons contain a pigment lipofuscin made up of residual bodies derived from lysosomes.
- The cytoplasm within the axon is called axoplasm, and its cell membrane is called axolemma.
- The axoplasm contains all the cell organelles of neurons cell body except ribosomes. Hence, proteins synthesized in the cell body are continuously transported toward the axon terminals by a process called axoplasmic transport.
- In an axon the impulse travels **away from the cell body**.
- Axons constitute what are commonly called **nerve fibers**. The bundles of nerve fibers found in CNS are called as **nerve tracts**, while the bundles of nerve fibers found in PNS are called **peripheral nerves**.
- An axon (or its branches) can terminate in two ways. Within the CNS, it always terminates by coming in intimate relationship with another neuron, the junction between the two neurons being called a **synapse**. Outside the CNS, the axon may end in relation to an effector organ (e.g., muscle or gland), or may end by synapsing with neurons in a peripheral ganglion.

Dendrites (Dendron Means Tree)

- They are short processes of neuron and terminate near the cell body.
- They are irregular in thickness, and Nissl granules extend into them. They bear numerous small spines that are of variable shape.
- In a dendrite, the nerve impulse travels **toward the cell body**.

JAYPEE BROTHERS

NEUROGLIA

In addition to neurons, the nervous system contains several types of supporting cells called neuroglia **(Flowchart 9.2)**.

Neuroglial Cells

- Astrocytes, oligodendrocytes, and microglia found in the parenchyma of the brain and spinal cord and ependymal cells lining the ventricular system.
- Schwann cells (lemmocytes) or peripheral glia forming myelin sheaths around axons of peripheral nerves. It is important to note that both neurilemma and myelin sheaths are the components of Schwann cells.
- Capsular cells or satellite cells or capsular gliocytes that surround neurons in peripheral ganglia.
- All neuroglial cells are much smaller in size than neurons. However, they are far more numerous. It is interesting to note that the number of glial cells in the brain and spinal cord is 10–50 times as much as that of neurons. Neurons and neuroglia are separated by a very narrow extracellular space.
- In ordinary histological preparations, only the nuclei of neuroglial cells are seen. Their processes can be demonstrated by special techniques.

Astrocytes

- These are small star-shaped cells that give off a number of processes **(Fig. 9.3)**. The processes are often flattened into leaf-like laminae that may partly surround neurons and separate them from other neurons. The processes frequently end in expansions in relation to blood vessels or in relation to the surface of the brain. Small swellings called **gliosomes** are present on the processes of astrocytes. These swellings are rich in mitochondria.
- The processes of astrocytes are united to those of other astrocytes through gap junctions. Astrocytes communicate with one another through calcium channels. Such communication plays a role in the regulation of synaptic activity and in the metabolism of neurotransmitters and neuromodulators.
- **Astrocytes are of two types:**
  - *Fibrous astrocytes* are seen mainly in white matter. Their processes are thin and are asymmetrical.
  - *Protoplasmic astrocytes* are seen mainly in gray matter. Their processes are thicker than those of fibrous astrocytes and are symmetrical.
  - *Intermediate forms* between fibrous and protoplasmic astrocytes are also present. Protoplasmic extensions of astrocytes surround the nodes of Ranvier.
- **Functions of astrocytes are:**
  - Biochemical support of endothelial cells
  - They help in the formation of blood-brain barrier
  - Provision of nutrients to the nervous tissue

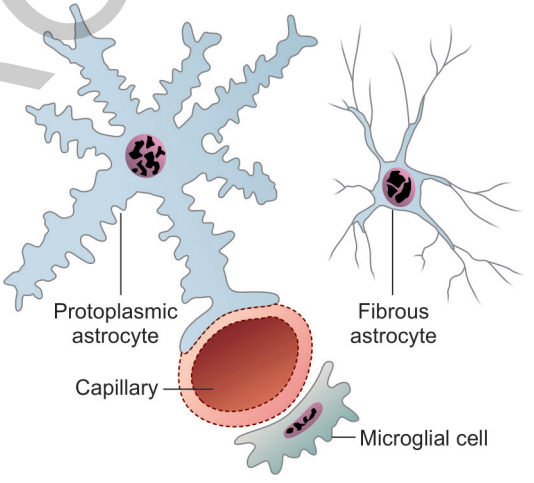

Fig. 9.3: Astrocytes and microglial cells (schematic representation).

Flowchart 9.2: Types of neuroglia found in central and peripheral nervous systems.

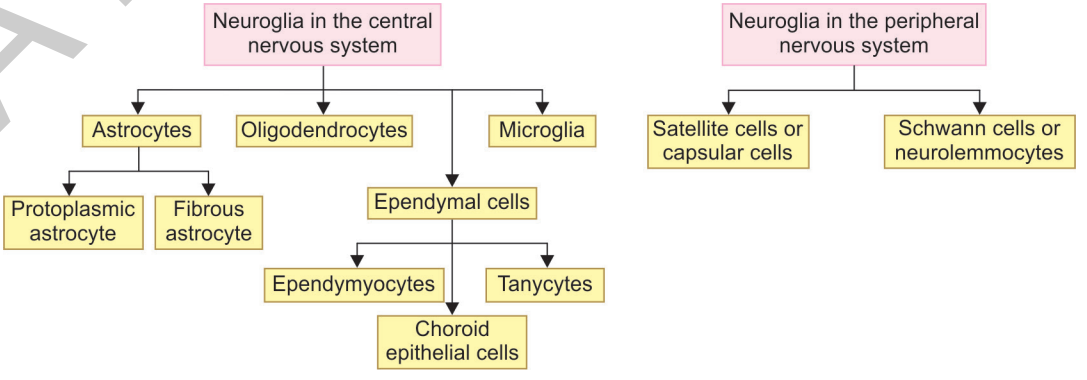

JAYPEE BROTHERS

- Maintenance of extracellular ion balance
- Help in repair process by forming cellular scar tissue **(gliosis)**.
- They serve as insulators and prevent neuronal impulses from spreading in unwanted directions.
- They are believed to help in maintaining a suitable metabolic environment for the neurons. They can absorb neurotransmitters from synapses, thus, terminating their action.

Oligodendrocytes

- These cells are rounded or pear-shaped bodies with relatively few processes (oligo—scanty) **(Fig. 9.4)**.
- These cells provide myelin sheaths to nerve fibers that lie within the brain and spinal cord. Their relationship to nerve fibers is basically similar to that of Schwann cells to peripheral nerve fibers.
- **Function:** Oligodendrocytes provide myelin sheaths to nerve fibers within the CNS for fast conduction of nerve impulses.

Ependymal Cells

- Ependymal cells are low columnar epithelial cells lining the ventricles of the brain and central canal of the spinal cord.
- The specialized ependymal cells in choroid plexuses (choroidal epithelial cells) secrete cerebrospinal fluid (CSF).
- In some regions, these cells are ciliated that helps in the movement of CSF.

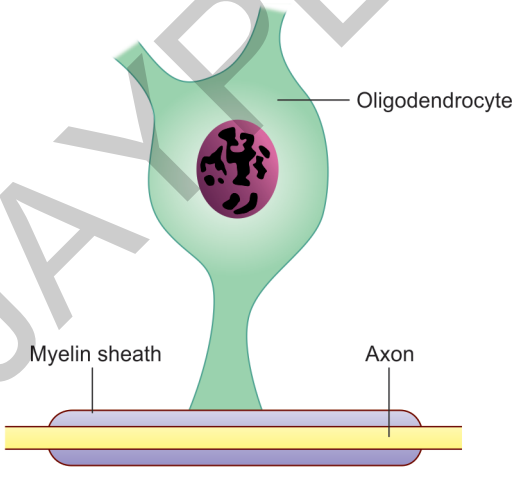

Fig. 9.4: Oligodendrocyte giving off a process that forms a segment of the myelin sheath of an axon (schematic representation).

- Modifications of the ependymal cells in the ventricle help in the formation of choroid plexus and CSF.
- The ependymal cells lining the floor of the fourth ventricle have long basal processes and are termed "**tanycytes**".
- **Functions:** (a) It secretes CSF and helps in maintaining the chemical composition of the CSF. (b) Ependymal cells are concerned in the exchange of material between the brain and the CSF at the brain–CSF barrier. The blood in the capillaries of the choroid plexus is filtered through choroid epithelial cells at the blood–CSF barrier to secrete CSF.

Microglia

- These are the smallest neuroglial cells **(Fig. 9.3)**. The cell body is flattened with short processes.
- They are the members of the mononuclear phagocyte system and mesodermal in origin.
- They are more numerous in gray matter than in white matter.
- **Functions:** (a) They act as phagocytes in clearing debris and damaged structures and become active after damage to nervous tissue by trauma or disease. (b) They also protect nervous system from viruses, microorganisms, and tumor formation.

Schwann Cells

- Schwann cells are located in PNS and envelop axons and form myelin sheath in **peripheral nervous system**.
- They are flattened cells with flattened nucleus. They are derived from **neural crest**.
- They form either myelinated or unmyelinated coverings over the axons. Axon may be myelinated or unmyelinated. Axons having a myelin sheath are called **myelinated axons**.

Satellite Cells

- Satellite glial cells are the principal glial cells found in the PNS, specifically in sensory, sympathetic, and parasympathetic ganglia. They are derived from **neural crest**.
- They help to regulate and stabilize the environment around ganglion cell bodies.
- **Function:** They supply nutrients to the surrounding neurons and also act as protective, cushioning cells **(Fig. 9.2)**.

JAYPEE BROTHERS

MYELIN SHEATH

- It is an insulating sheath surrounding the axons outside the axolemma.
- In PNS, myelin sheath is formed by **Schwann cells** and in CNS by an **oligodendrocyte**.
- Many Schwann cells surround the axons to form a myelin sheath in PNS, and single oligodendrocyte provides myelin sheath for many axons in CNS.

Steps of Formation of Myelin Sheath (Fig. 9.5)

- An axon lying near a Schwann cell invaginates into the cytoplasm of the Schwann cell, the axon comes to be suspended by a fold cell membrane of the Schwann cell: this fold is called the **mesaxon**. In some situations, the mesaxon becomes greatly elongated and comes to be spirally wound around the axon, which is thus surrounded by several layers of cell membrane.
- Lipids are deposited between the adjacent layers of the membrane. These layers of the mesaxon, along with the lipids, form the **myelin sheath**.
- Outside the myelin sheath, a thin layer of Schwann cell cytoplasm persists to form an additional sheath that is called the **neurilemma** (neurilemmal sheath or Schwann cell sheath).
- The presence of a myelin sheath increases the velocity of conduction. It also reduces the energy expended in the process of conduction.
- An axon is related to many Schwann cells over its length and each Schwann cell provides the myelin sheath for a short segment of the axon. At the junction between two such segments, there is a short gap in the myelin sheath called the **nodes of Ranvier**. It is the junction between the myelin sheath of two different Schwann cells.
- The nodes of Ranvier have great physiological importance. When an impulse travels down a nerve fiber, it jumps from one node to the next. This is called **saltatory conduction** (in unmyelinated neurons, the impulse travels along the axolemma. Such conduction is much slower than saltatory conduction and consumes more energy).
- The segment of myelin sheath between two nodes of Ranvier is called **internode**, and a single Schwann cell will myelinate an internode.
- Myelin contains protein, lipids, and water. The main lipids present include cholesterol, phospholipids, and glycosphingolipids.

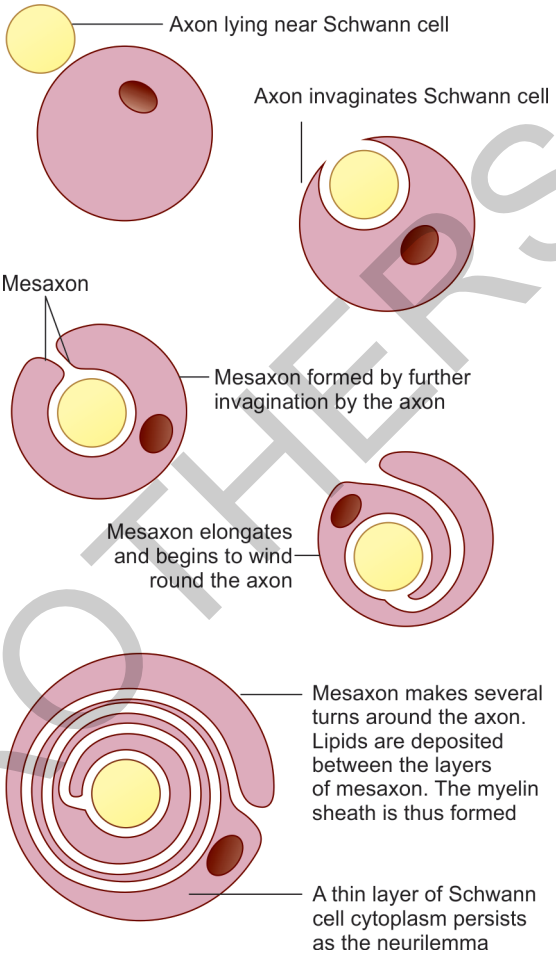

Fig. 9.5: Stages in the formation of the myelin sheath by a Schwann cell (schematic representation).

- **Functions of the myelin sheath:** (a) The presence of a myelin sheath increases the velocity of conduction and reduces the energy expended in the process of conduction. (b) It is responsible for the color of the white matter of the brain and spinal cord and provides insulation to the neurons.

Unmyelinated Axons

There are the axons that are devoid of myelin sheaths. These **unmyelinated axons** invaginate into the cytoplasm of Schwann cells, but the mesaxon does not spiral around them, and several such axons may invaginate into the cytoplasm of a single Schwann cell **(Table 9.2)**.

TYPES OF NEURONS

The neurons are classified on the basis of number of processes, function and length of axons. The brief description with examples is provided in **Table 9.3**.

JAYPEE BROTHERS

Table 9.2: Differences between myelinated and unmyelinated nerve fibers.

Myelinated nerves	Unmyelinated nerves
Axons are of large diameter	Axons are of small diameter
Axons surrounded by concentric layers of Schwann cell plasma membrane	Axons surrounded by cytoplasm of Schwann cells
Single axon is surrounded by many Schwann cells	Single or group of axons are invaginated by single Schwann cell
Nerve impulse jumps from one node to other node called as saltatory conduction	Nerve impulse travels uniformly along the axolemma
Conduction is fast and consumes less energy	Conduction is slow and consumes more energy

Table 9.3: Classification of neurons.

Morphology	Description	Location
According to the number of processes (Fig. 9.6)		
Unipolar/ pseudounipolar	These neurons have single process. After a very short course, this process divides into two. One of the divisions represents the axon; the other is functionally a dendrite, but its structure is indistinguishable from that of an axon	Sensory neurons of dorsal root ganglia and cranial nerve ganglia
Bipolar	These neurons have only one axon and one dendrite,	Bipolar cells of retina, and sensory ganglia of vestibulocochlear nerve
Multipolar	It is the most common type of neurons; the neuron gives off several processes, i.e., these neurons have one axon and many dendrites, e.g., motor neurons	Motor neuron and interneuron
According to the length of axons		
Golgi type I	These neurons have long axons and connect remote regions	Purkinje cells of cerebellum, anterior horn cells of spinal cord, and pyramidal cells of cerebral cortex
Golgi type II	These neurons have short axons which end near the cell body	Stellate cells, cells of Martinotti of cerebral cortex and granule cells of cerebellar cortex
According to the function		
Sensory neuron	They carry impulses from receptor organ to the CNS	
Motor neuron	They transmit impulses from the CNS to the muscles and glands	

PERIPHERAL NERVES

- Peripheral nerves are the bundles of nerve fibers (axons) outside the CNS. These may be myelinated or unmyelinated.
- Nerve fibers carry impulses from the spinal cord or brain to peripheral structures, such as muscle or gland, are called **efferent** or **motor** fibers. Efferent fibers are axons of neurons located in the gray matter of the spinal cord or of the brainstem.
- Nerve fibers carry impulses from peripheral organs to the brain or spinal cord are called **afferent** fibers. Afferent nerve fibers are processes of neurons that are located in ganglia.

Microscopic Structure of Peripheral Nerves (Fig. 9.7 and Plate 9.1)

- Nerve fibers (myelinated or unmyelinated) are arranged in the form of bundles surrounded by connective tissue coverings.
- Each nerve fiber with its Schwann cell and basal lamina is surrounded by a layer of connective tissue called the **endoneurium**. The endoneurium contains type II collagen fibers, fibroblasts, Schwann cells, endothelial cells, and macrophages.
- Many nerve fibers together form bundles or **fasciculi**. Endoneurium holds adjoining nerve fibers together and facilitates their aggregation to form **fasciculi**. Each fasciculus is surrounded by a thicker layer of connective tissue called the **perineurium**. The perineurium is made up of layers of flattened cells separated by the layers of collagen fibers. Flattened cells are joined at their edges by tight junctions, this controls diffusion of substances in and out of axons (nerve-blood barrier).
- Many fasciculi are held together by a fairly dense layer of connective tissue that surrounds the entire nerve and is called the **epineurium**. It is made up of fibroblast, collagen fibers, and adipose tissue which give cushioning effect to the nerve.
- Nuclei seen in the section of axon is of Schwann cells and fibrocytes.

OPTIC NERVE (PLATE 9.2)

- It belongs to CNS and its myelin sheath is formed by oligodendrocytes. It is second cranial nerve—a special sensory nerve.
- It is an outgrowth of brain—hence covered by meninges: dura mater, arachnoid mater, and pia mater which are

JAYPEE BROTHERS

separated from each other by subdural and subarachnoid spaces.

- It is made up of bundles of myelinated axons of ganglion cells of retina.
- In the center of the intraorbital part of the optic nerve lie the central retinal vessels enclosed in their envelope.

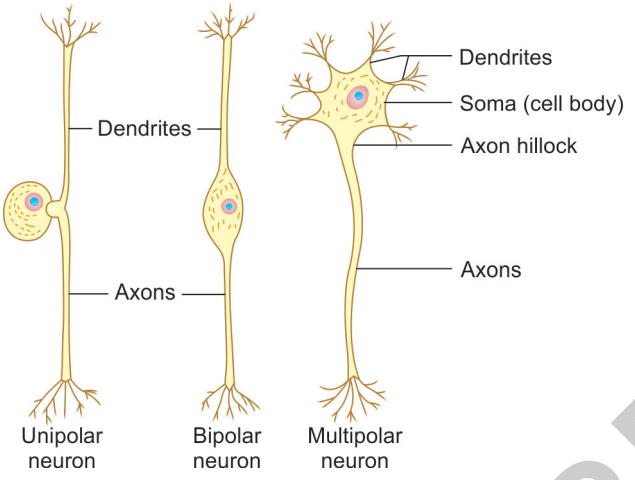

Fig. 9.6: Unipolar, bipolar, and multipolar neurons (schematic representation).

- The pia mater, attached directly to the optic nerve sends septa which divides the nerve into bundles/fascicles and guide the blood vessels to the nerve fibers.
- At the eyeball, the dura fuses with the sclera while the arachnoid and pia mater merge with the choroid. Connective tissue septa, which arise from the pia mater, separate the fiber bundles in the optic nerve.
- Since it is an extension of CNS, any changes in intracranial pressure are reflected in optic disc and nerve.

GANGLIA

Aggregations of cell bodies of neurons, placed outside the CNS, are known as ganglia. Ganglia are of two main types: **sensory** and **autonomic**. The difference between them is compared in **Table 9.4.**

Sensory Ganglia (Plate 9.3)

- Sensory ganglia are the collection of cell bodies of sensory neurons. They are associated with the dorsal nerve roots of spinal nerves called dorsal nerve root ganglia and with 5th, 7th, 8th, 9th, and 10th cranial nerves.
- Neurons in these ganglia are of the unipolar type (except in 8th nerve in which they are bipolar). The peripheral

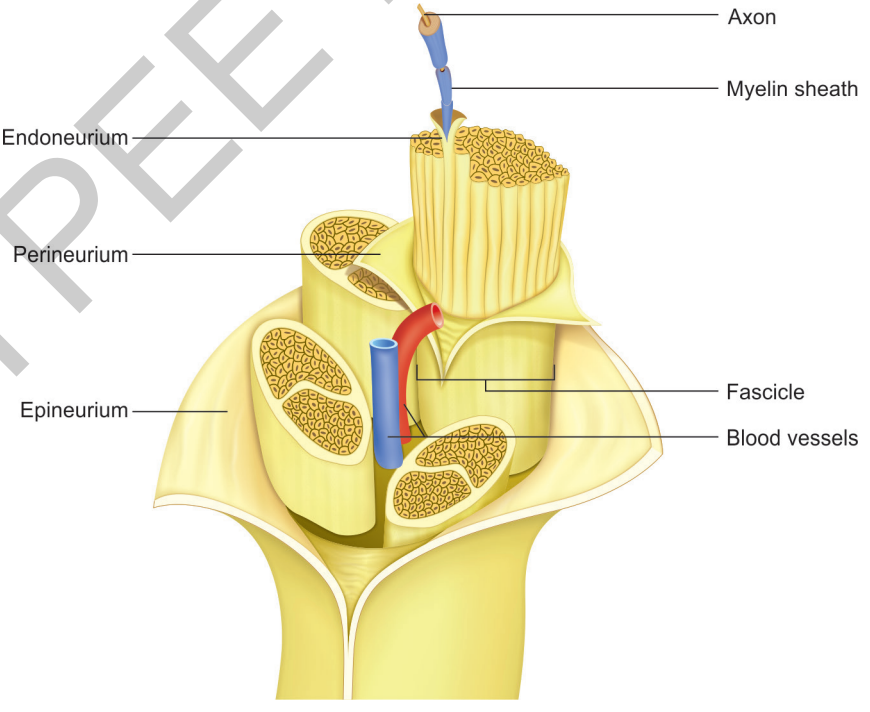

Fig. 9.7: Basic anatomy of peripheral nerves.

JAYPEE BROTHERS

Plate 9.1: Peripheral Nerve

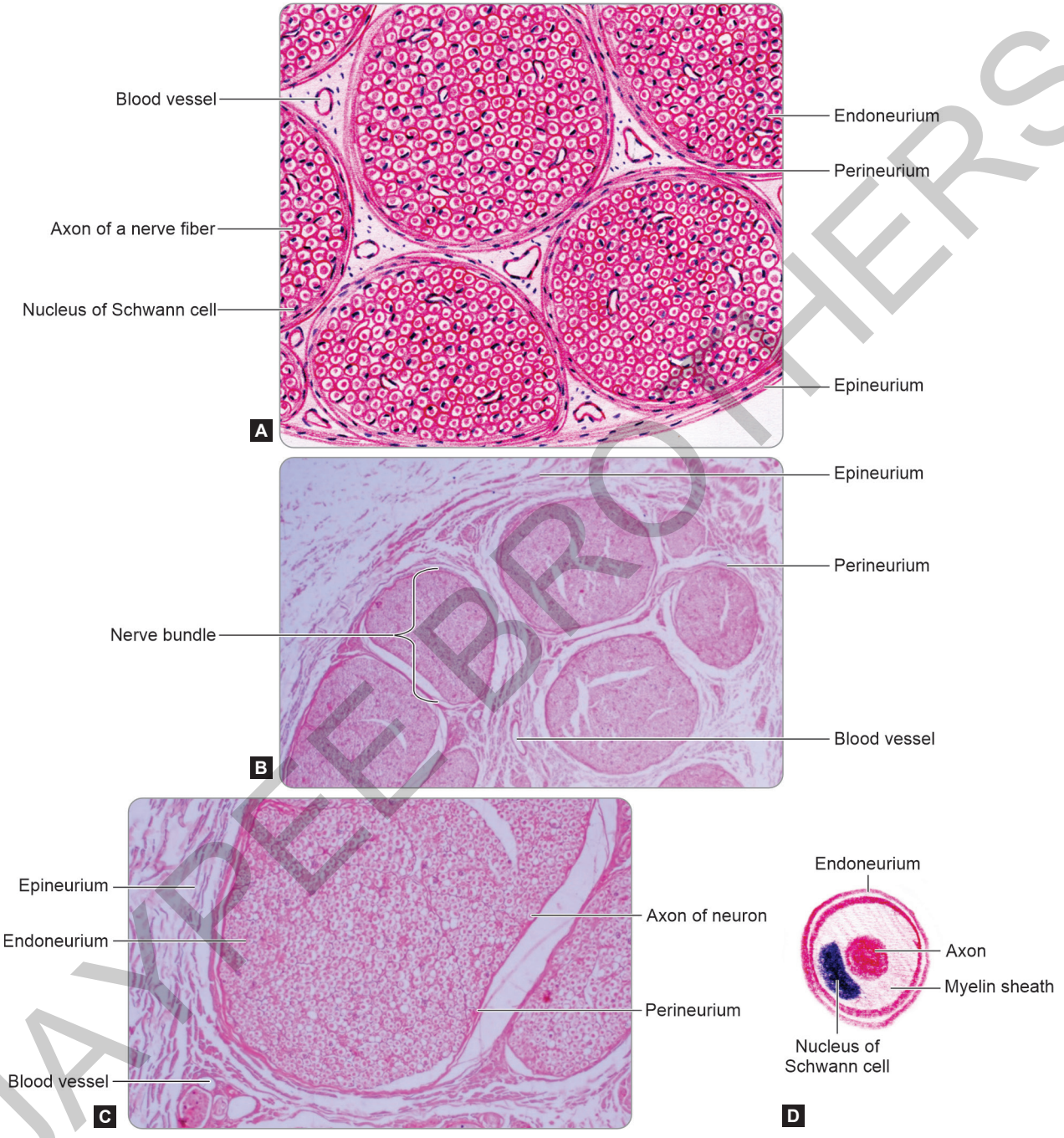

Peripheral nerve: As seen in: (A) Drawing; (B) Photomicrograph (low power); (C) Photomicrograph (high power); (D) Section of an axon.

Points of identification

- Each nerve fiber is covered by endoneurium.
- Each bundle of nerve fibers is covered by perineurium.
- Each nerve is covered by epineurium.
- Cut section of axon with myelin sheath and Schwann cell nucleus.

JAYPEE BROTHERS

Plate 9.2: Optic Nerve

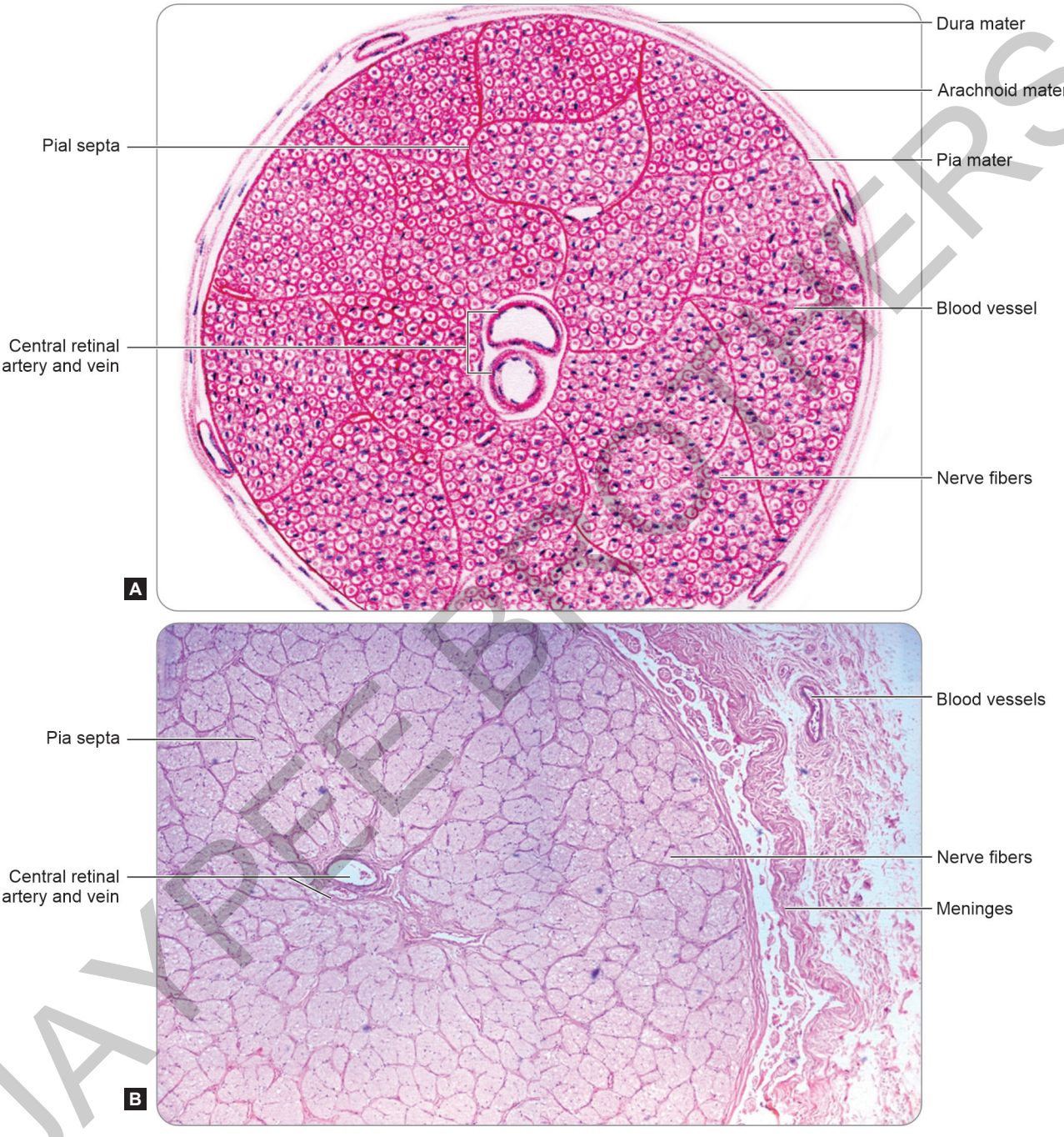

Optic nerve: As seen in: (A) Drawing; (B) Photomicrograph (low power).

Points of identification

- Covered by meninges—dura mater, arachnoid mater, and pia mater.
- Central retinal artery and vein are seen.
- Pial septa divides the nerve into bundles.

JAYPEE BROTHERS

Plate 9.3: Sensory Ganglia

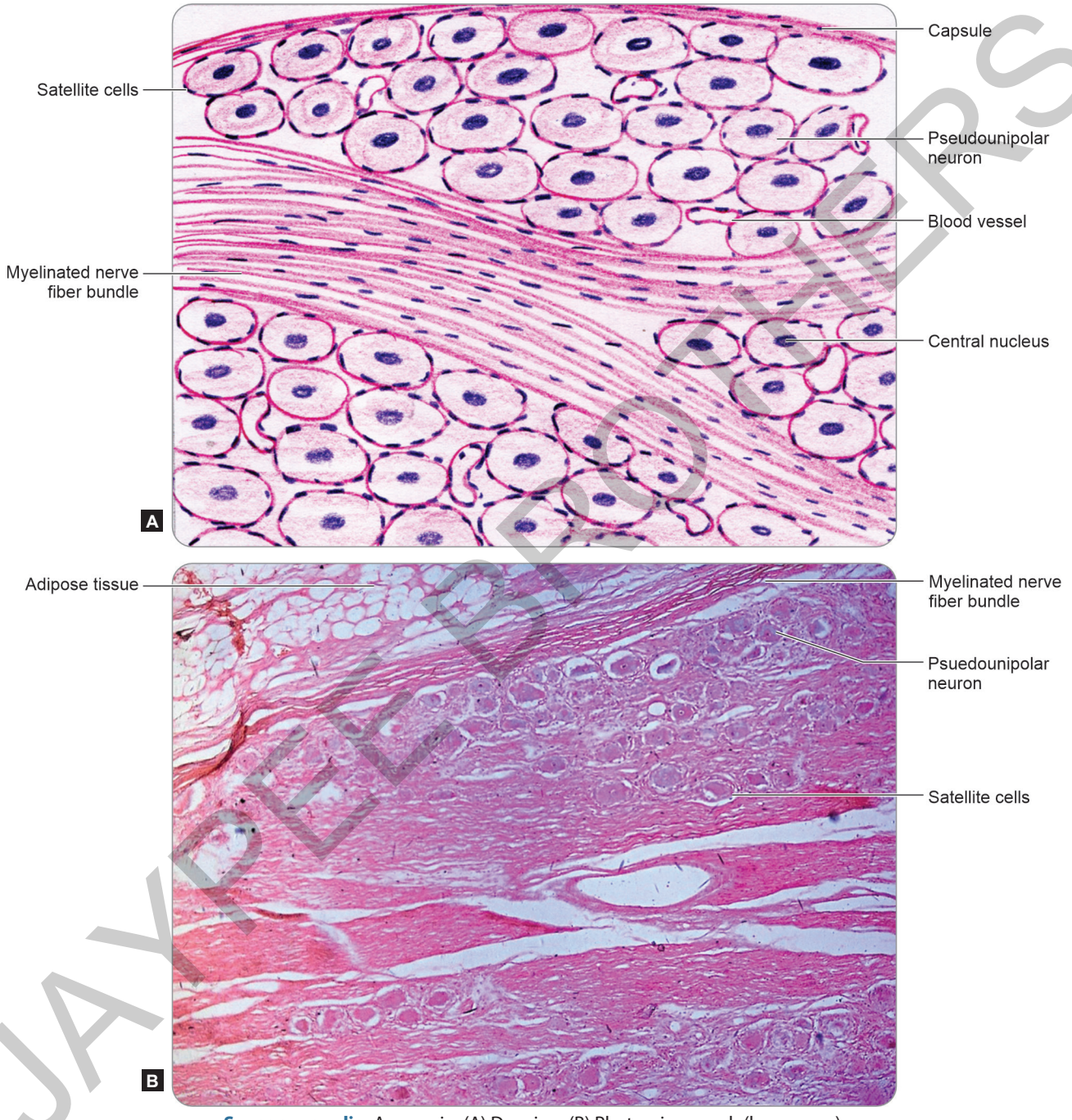

Sensory ganglia: As seen in: (A) Drawing; (B) Photomicrograph (low power).

Points of identification

- Unipolar neurons with centrally placed nucleus.
- Neurons are presented in a group between the group of nerve fibers.
- Prominent satellite cells are seen.

JAYPEE BROTHERS

Table 9.4: Difference between sensory and autonomic ganglia.

Sensory ganglia	Autonomic ganglia
Cell bodies are large	Cell bodies are smaller
Unipolar type of neuron except investibulocochlear nerve (bipolar)	Multipolar type of neuron
Neurons with centrally placed nucleus	Neurons with eccentrically placed nucleus
Cell bodies of the neurons are arranged in groups	Cell bodies of the neuron does not form definite groups
Myelinated nerve fibers are arranged in bundles	Unmyelinated nerve fibers are scattered
Prominent satellite cells	Satellite cells are less prominent
Well-defined connective tissue capsule	Poorly defined or absent connective tissue capsule

process of each neuron forms an afferent (or sensory) fiber of a peripheral nerve and the central process enters the spinal cord or brainstem.

- The ganglion is covered by a connective tissue capsule, and the entire ganglion is pervaded by fine connective tissue.
- The unipolar neurons are large with centrally placed nucleus. They are arranged in groups chiefly at the periphery of the ganglion and groups of cells are separated by the bundle of myelinated nerve fibers.
- The cell body of each neuron is surrounded by a layer of flattened **capsular cells or satellite cells**. Outside the satellite cells, there is a layer of delicate connective tissue (the satellite cells are continuous with the Schwann cells covering the processes of the neuron) and the connective tissue is continuous with the endoneurium.

Autonomic Ganglia (Plate 9.4)

- They are concerned with the nerve supply of smooth muscle or of glands. The pathway for this supply consists of two neurons: (1) preganglionic and (2) postganglionic.
- The cell bodies of preganglionic neurons are always located within the spinal cord or brainstem. Their axons leave the spinal cord or brainstem and terminate by synapsing with postganglionic neurons, the cell bodies of which are in autonomic ganglia.
- Autonomic ganglia are, therefore, aggregations of the cell bodies of postganglionic neurons and are subdivided into two major types: (1) sympathetic and (2) parasympathetic.
- The neurons of autonomic ganglia are **multipolar neurons**, and they are smaller than those in sensory ganglia.
- The ganglion is covered outside by a thin capsule and permeated by connective tissue (intramural ganglia have no capsule).
- The multipolar neurons with **eccentrically placed** nucleus are not arranged in definite groups as in sensory ganglia but are scattered throughout the ganglion. The **nerve fibers** are nonmyelinated, thinner, and they are, therefore, much less conspicuous than in sensory ganglia.
- **Satellite cells** are present around the neurons of autonomic ganglia, but they are not so well defined.
- The Nissl substance of the neurons is much better defined in autonomic ganglia than in sensory ganglia.
- In sympathetic ganglia the neuronal cytoplasm synthesizes catecholamines; and in parasympathetic ganglia, it synthesizes acetylcholine.

JAYPEE BROTHERS

Plate 9.4: Autonomic Ganglia

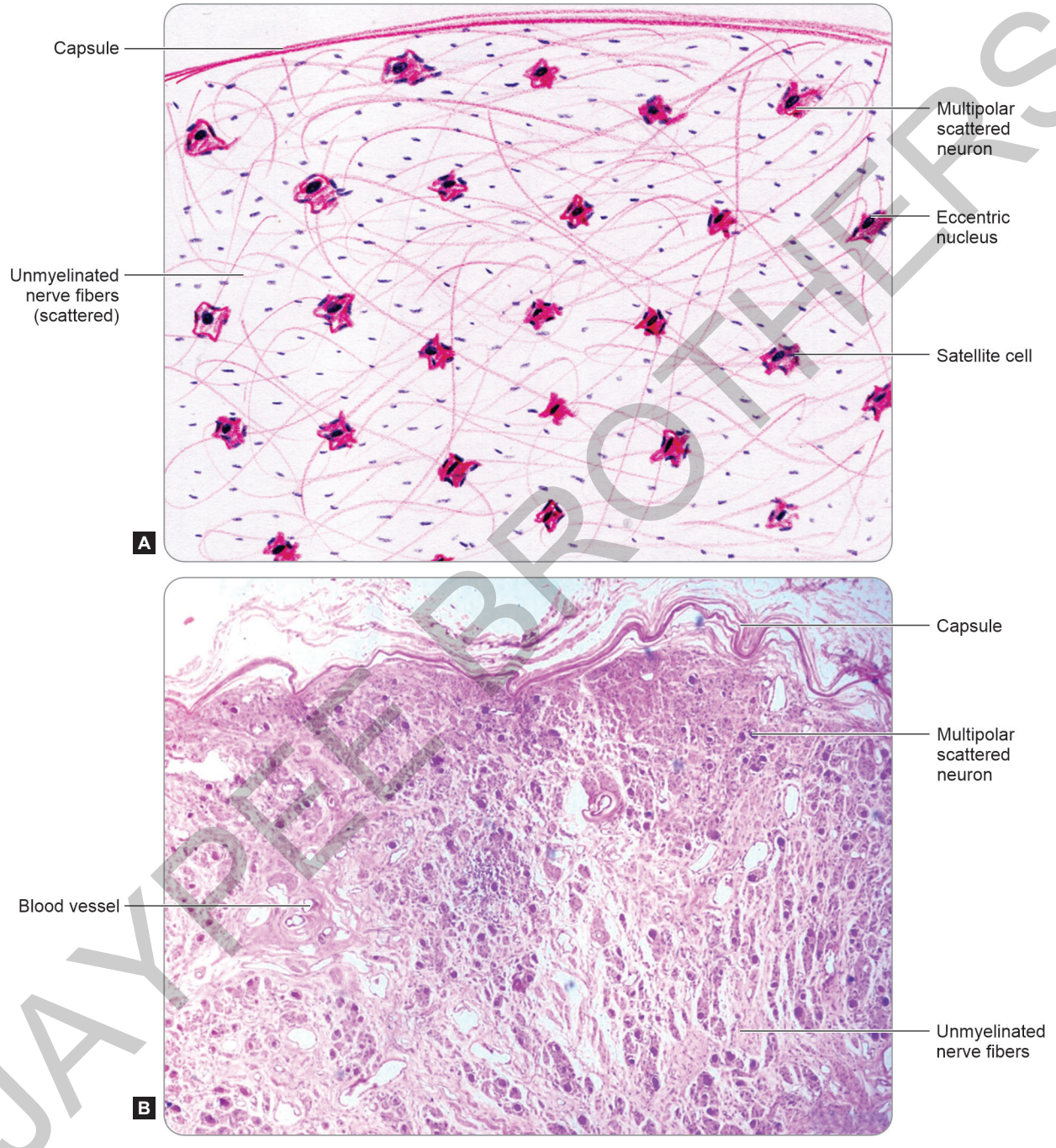

Autonomic ganglia: As seen in: (A) Drawing; (B) Photomicrograph (low power).

Points of identification

- Multipolar neurons with eccentrically placed nucleus.
- Neurons are scattered between the nerve fibers.

JAYPEE BROTHERS

APPLIED HISTOLOGY

- The regeneration of neurons does not occur in CNS as myelination is by oligodendrocytes. Hence in multiple sclerosis, myelin formed from oligodendrocytes undergoes degeneration, while myelin from Schwann cells is spared.
- The epineurium contains fat that cushions nerve fibers. Loss of this fat in bedridden patients can lead to pressure on nerve fibers and paralysis.
- Blood vessels to a nerve travel through the connective tissue that surrounds it. Severe reduction in blood supply can lead to **ischemic neuritis** and pain.
- **Tumors of nervous tissue:** Precursors of neural cells can give rise to medulloblastomas. Once mature neurons are formed, they lose the power of mitosis and do not give origin to tumors. Certain tumors called germinomas appear near the midline, mostly near the third ventricle. They arise from germ cells that also give rise to teratomas. Most tumors of the brain arise from neuroglial cells. Astrocytomas are most common. Oligodendromas are also frequent. Tumors can also arise from ependyma and from Schwann cells.

EXAM-ORIENTED QUESTIONS

1. **Describe the cells of the nervous tissue.**
2. **Neuroglia-structure and functional correlation.**
3. **Describe the structure of a neuron.**
4. **Describe the histology of peripheral nerve/optic nerve/ sensory ganglion/autonomic ganglion with neat labeled diagram.**
5. **Compare and contrast the peripheral and optic nerve.**
6. **Compare and contrast the histology of sensory and autonomic ganglia.**
7. **A single Schwann cell forms myelin around one axon, while a single oligodendroglial cell forms myelin around several separate axons.**
8. **Describe the myelin sheath.**

MULTIPLE CHOICE QUESTIONS

1. **All the following statements are true, *except*:**
   a. Spinal ganglia have unipolar neurons
   b. Autonomic ganglia have multipolar neurons
   c. Spinal ganglia have continuous sheath of satellite cells
   d. Autonomic ganglia has centrally placed nucleus
2. **All of the following statements regarding myelination are true, *except*:**
   a. Schwann cells are responsible for myelination in PNS
   b. Oligodendrocytes are responsible for myelination in CNS
   c. Initial segments are myelinated
   d. Myelination helps in saltatory conduction of impulses
3. **The gap between two adjacent myelin segments along an axon is called the:**
   a. Axolemma b. Axonal cleft
   c. Choroid plexus d. Node of Ranvier
4. **Schwann cell membrane wrapped many times around an individual axon is called:**
   a. Axolemma b. Myelin sheath
   c. Perikaryon d. Node of Ranvier
5. **A group of nerve cell bodies located outside the CNS is called a:**
   a. Ganglion b. Nucleus
   c. Node d. Myelin
6. **White matter appears white because of the:**
   a. Absence of blood vessels
   b. Absence of glial cells
   c. Presence of many collagen fibers
   d. Presence of many myelinated axons
7. **A single Schwann cell forms myelin around one axon, while a single oligodendroglial cell forms myelin around several separate axons.**
   a. True b. False
8. **Endoneurium, perineurium, and epineurium are the connective tissues which ensheath axons, axon bundles, and peripheral nerves.**
   a. True b. False
9. **Which of the following glial cell types is believed to be functionally related to macrophages?**
   a. Astroglia b. Oligodendroglia
   c. Microglia d. Schwann cells
10. **Which of the following cell types lines the central canal of the spinal cord and the ventricular system of the brain?**
    a. Astroglia b. Microglia
    c. Schwann cells d. Ependymal cells

Answers

1. d 2. c 3. d 4. b 5. a 6. d 7. a 8. a 9. c 10. d

JAYPEE BROTHERS

r detailed information on anatomy books, visit our website www.ejaypee.com, for detailed information on anatomy books, visit our website www.ejaypee.com, for detailed information on anatomy books, visit our website www.eja

Inderbir Singh's Textbook of

HUMAN HISTOLOGY

Salient Features

- The content has been updated while preserving the legacy of the original book.
- The syllabus follows National Medical Commission (NMC) of India requirements, including competencies.
- Content is simplified to aid students in easy understanding and retention.
- Better resolution slides with relevant plates that are student friendly are given.
- A core highlight of this edition is the addition of easily reproducible hand-written diagrams of histology slides observed in practical classes, assisting with practical record writing and examinations.
- Identification points are provided with every slide.
- Applied aspects are included based on relevance.
- Extra information is clearly marked as "Added Information" for optional reference.
- Clinical case scenarios relevant to histology are included in each chapter.
- Review questions and updated MCQs are added.
- Online video lectures of histology of basic structures and different organ systems are included.

Pushpalatha K MBBS MD (PhD) is Professor, Department of Anatomy, Jagadguru Sri Shivarathreeshwara (JSS) Medical College, Mysuru, Karnataka, India. She has 21 years of experience in teaching anatomy for various UG and PG courses like MBBS, BDS, MD, MSc and various allied health science courses. She is a Co-convenor of Medical Education Unit at her institute and Convenor of CCLPE (Center for Continuous and Lifelong learning for Professional Excellence). She was the core member in preparing the integrated timetable for CBME curriculum and key person to implement new curriculum at her institute. She is a FAIMER fellow with distinction and completed ACME with best poster award. She is pursuing PhD in medical education on the topic "Bench-marking of assessment in CBME". She is a passionate and dedicated teacher and works toward the betterment of the students.

Deepa Bhat MBBS MD (PhD) is Professor, Department of Anatomy, Jagadguru Sri Shivarathreeshwara (JSS) Medical College, Mysuru, Karnataka, India. With 17 years of experience in teaching anatomy, she is a distinguished Medical Educationist, holding a FAIMER fellowship and ACME certification from the NMC. Her passion for drawing and art has contributed valuable illustrations to this book. She is also a genetic counselor specializing in rare genetic disorders and is recognized as an expert in sickle cell disease. She has led several research projects on hemoglobinopathies and tribal health. Her dedication to teaching and commitment to educational reform reflect her drive to adapt to changing trends in the medical field.

diginerve®
A Jaypee Initiative
• Video Lectures • Dr. Wise AI Chatbot
• Question Bank • Notes
Download App

Buy from ejaypee
JAYPEE BROTHERS

Shelving Recommendation
ANATOMY

ISBN 978-93-7202-673-3
9 789372 026733