iled information on otorhinolaryngology books, visit our website www.ejaypee.com, for detailed information on otorhinolaryngology books, visit our website www.ejaypee.com

Atlas of Phonomicrosurgery

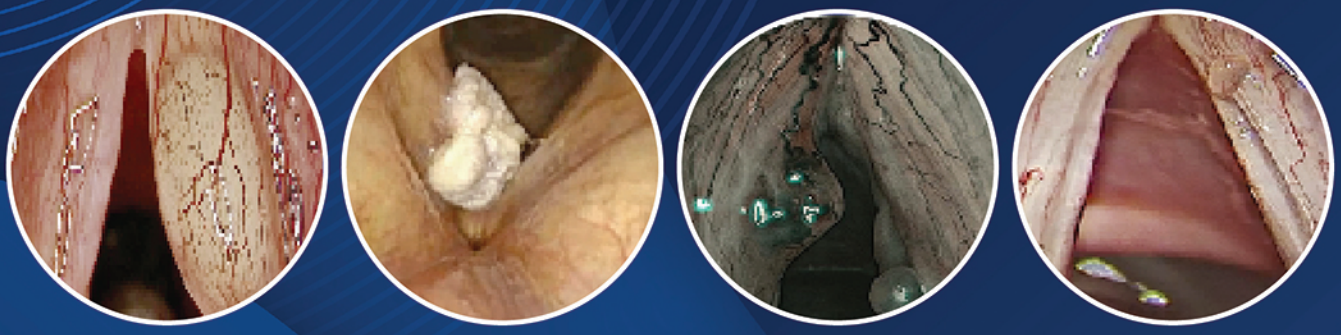

Nupur Kapoor Nerurkar

Forewords
Markus M Hess
Marc Remacle
Milind V Kirtane

2nd Edition

JAYPEE

Contents

Chapter 1: Microscopic Anatomy of the Vocal Folds 1
Chapter 2: Principles of Phonomicrosurgery 5
Chapter 3: Microlaryngoscopy for Phonomicrosurgery 12
Chapter 4: Vocal Fold Polyp 15
Chapter 5: Vocal Fold Cyst 31
Chapter 6: Polyst 53
Chapter 7: Sulcus 55
Chapter 8: Mucosal Bridge 67
Chapter 9: Reinke's Edema 76
Chapter 10: Nodules 81
Chapter 11: Anterior Glottic Web 85
Chapter 12: Voice Feminization Surgery 100
Chapter 13: Keratosis 104
Chapter 14: Contact Granuloma 115
Chapter 15: Lipoma of the Larynx 123
Chapter 16: Laryngeal Manifestations of Rheumatoid Arthritis 127
Chapter 17: Recurrent Respiratory Papilloma 129
Chapter 18: Amyloidosis 146
Chapter 19: Fungal Laryngitis 154
Chapter 20: Laryngeal Tuberculosis 164
Chapter 21: Plexiform Neurofibromatosis 170
Chapter 22: Granulomatosis with Polyangiitis (Wegener's Granulomatosis) 174
Chapter 23: Bilateral Vocal Fold Paralysis 178
Chapter 24: Early Glottic Malignancy 184

Appendices

Nerurkar et al. Classification of Sulcus 199

Ni (2011) Classification of Narrow-band Imaging 200

Ni (2019) Classification of Narrow-band Imaging in the Presence of Leukoplakia 201

European Laryngological Society Classification (2016) of Narrow-band Imaging 202

Index 203

12

CHAPTER

Voice Feminization Surgery

INTRODUCTION

Anterior glottic webs can be deliberately created in patients who desire to increase the fundamental pitch of their voice. This surgery was first described by Professor Jürgen Wendler in 1990.[1]

This surgery is commonly performed in patients who have undergone a male to female gender transition.

The physics behind the surgery is that as the length of the vibrating vocal fold decreases, the pitch will automatically increase.

Research has shown that a 40–50% shortening of the membranous vocal fold should be performed in order to achieve a quantitative increase of pitch at which the patient will be satisfied. There is usually no concern of dyspnea on exertion after this surgery because 75% of respiration takes place in the intercartilaginous area and only 25% takes place in the intermembranous area. The sutures taken may be absorbable or permanent and typically vary from 5-0 to 6-0 in size. Usually, 2–3 sutures are taken after freshening the medial vibrating edge of the vocal fold with either cold steel or with a laser.

There are certain modifications of the anterior glottic webbing technique.

One of the modifications proposed by professor Kim[2] is where the anterior most stitch is taken from the right vocal fold to the anterior subglottis and then to the left vocal fold in order to tilt the anterior commissure. This helps to achieve a tensioning as well as the shortening effect of the vocal fold. Another modification proposed is to remove the ligament along with the epithelium and SLP. This is aimed to decrease the mass.[3]

A third modification is freshening the vocal folds and performing an anterior augmentation into the paraglottic space bilaterally to allow for a web formation without suturing.[4]

For a slight increase in pitch which may be occasionally needed after a primary Wendlers Glottoplasty or in a patient who has a relatively high vocal pitch but wants a further increase, there are two procedures which may be considered. The first option is laser-assisted voice adjustment (LAVA) where epithelial cuts are made with a laser on the superior surface of the vocal folds producing stiffening of the vocal fold and thus increasing the pitch by 15–25 Hz.[5] The second surgery which may be performed is when these cuts are made deeper to reduce or remove the muscle mass , known as "laser-assisted mass reduction (LAMR)" which works on the theoretical principal that as mass decreases, pitch increases. However, it is seen that when the mass changes superficial to the ligament, it affects the pitch much more dramatically as compared to when the mass is decreased deeper to the ligament.

Cases of voice feminizing surgeries have been described from **Figures 12.1 to 12.12**.

CASE 1

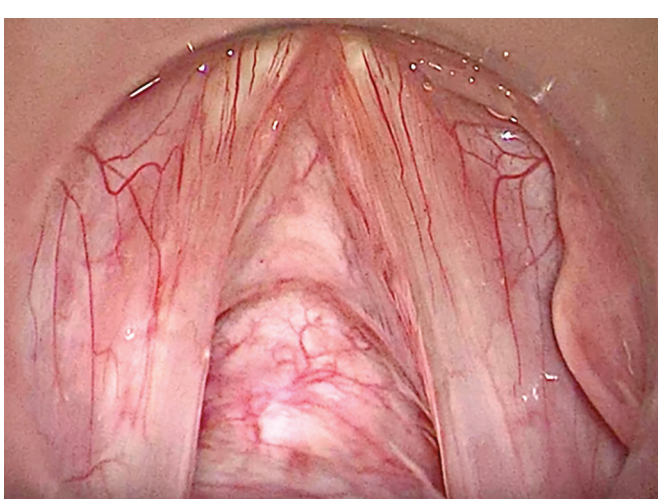

Fig. 12.1: Normal larynx in a patient who wants to increase her pitch following gender reassignment surgery.

JAYPEE BROTHERS

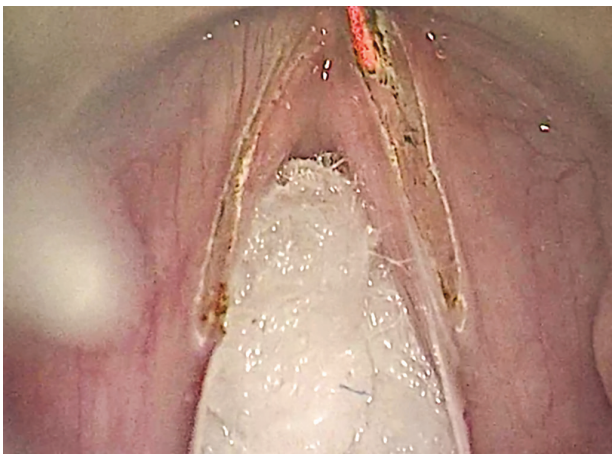

Fig. 12.2: CO_2 laser AcuBlade making the anterior half of the medial vibrating edge raw.

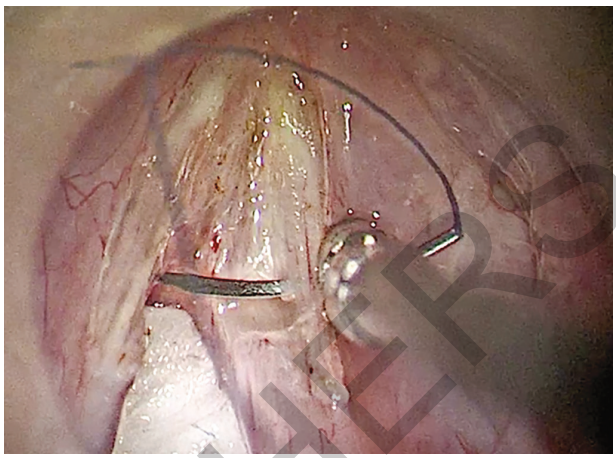

Fig. 12.3: This image shows the needle of 6-0 absorbable (vicryl) suture being held by a Kleinsasser needle holder with a rachet, which is being passed into the right vocal fold.

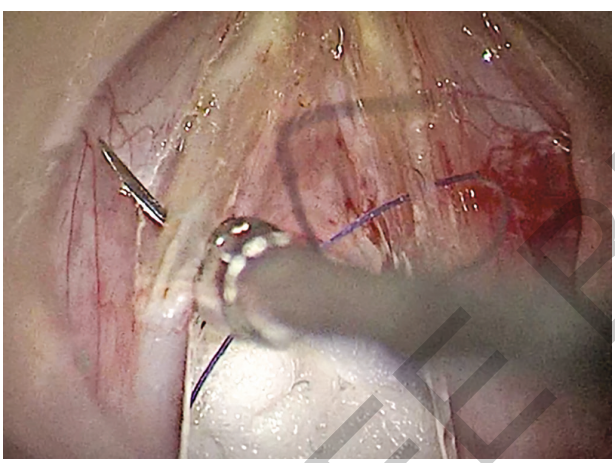

Fig. 12.4: This figure reveals the needle being passed from the infraglottic surface to the supraglottic surface of the left vocal fold to suture the vocal folds to one another at the anterior commissure. The vocal ligament is included in these sutures.

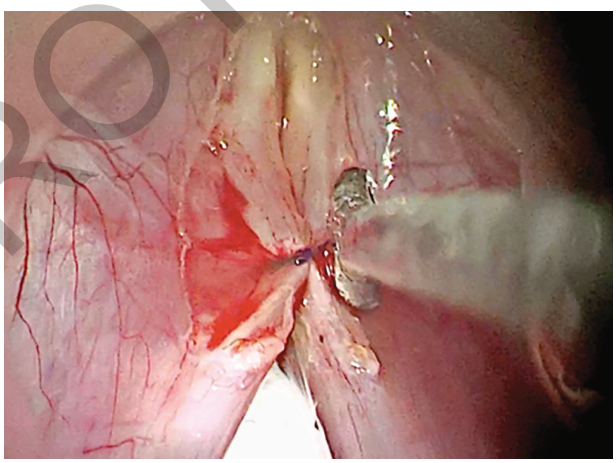

Fig. 12.5: The knot slider getting the knot in position.

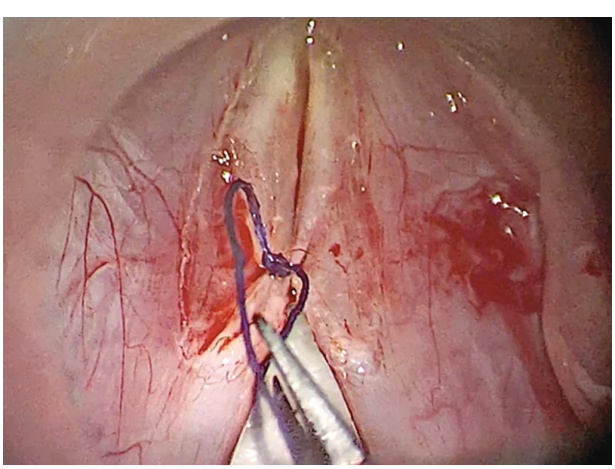

Fig. 12.6: Suture threads being cut once the knot has been taken.

JAYPEE BROTHERS

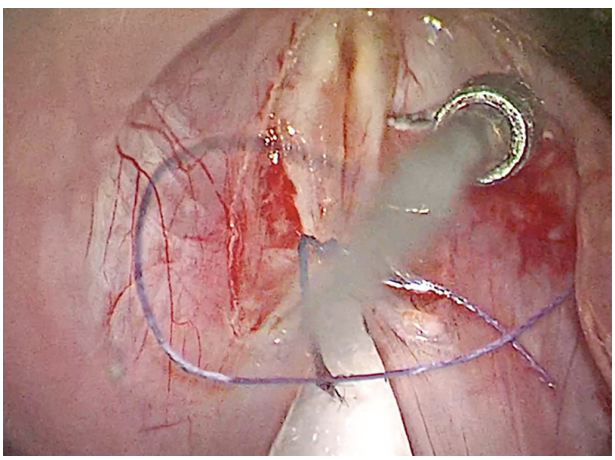

Fig. 12.7: Another knot being taken anterior to the previous one.

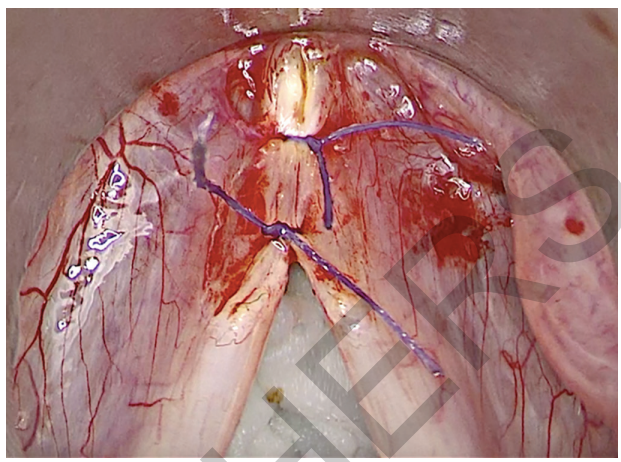

Fig. 12.8: Final postoperative image showing the creation of an anterior glottic web along half the membranous vocal fold.

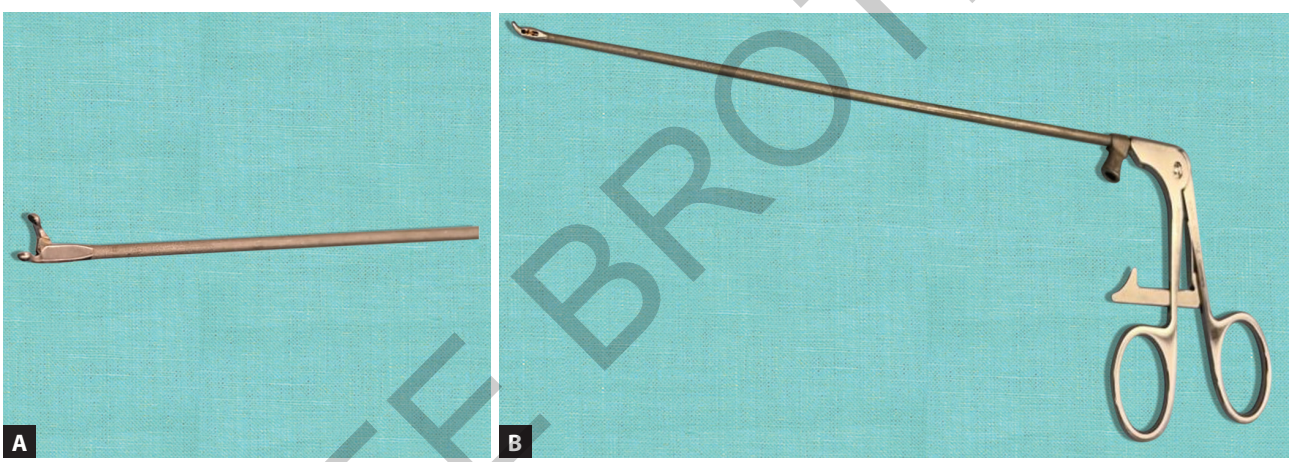

Figs. 12.9A and B: Images showing a Storz Wendler needle holder (Ø 2.5 mm).

CASE 2

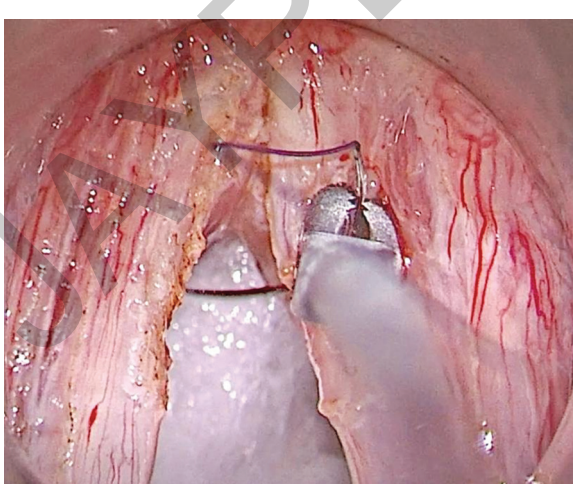

Fig. 12.10: This image shows the needle of 5-0 permanent suture (prolene) being held by a Wendler's needle holder, which is being passed into the right vocal fold.

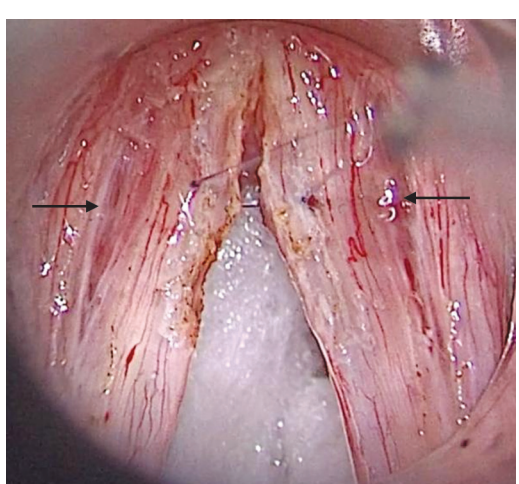

Fig. 12.11: Reveals the suture which has been taken through both the vocal folds at the same level and the needle being slid down with the knot slider. The arrows are pointing towards the LAVA epithelial cuts.

JAYPEE BROTHERS

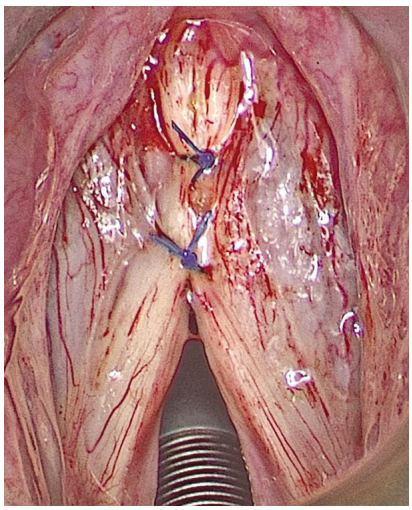

Fig. 12.12: Reveals the final postoperative image with two knots in situ achieving a webbing of 50% of the membranes vocal folds.

The advantage of using permanent sutures is that the knot slides down more easily without getting frayed. It is hypothesized that using permanent sutures allows for the tensile strength to remain constant on the knot as opposed to when absorbable sutures are used where the tensile strength may decrease over time, thus affecting the integrity of the web. However, the chances of granuloma formation are probably higher with permanent sutures. These are usually on the superior surface of the web and do typically settle with time.

Ideally, the web should have a sharp "V" and not a "U", so that there is no phonatory gap present anteriorly on the newly constructed anterior commissure.

Most patients are advised a variable period of 1–2 weeks of voice rest following the surgery so that the sutures do not give way. The author advises 2 weeks of voice rest postoperatively and avoidance of repeated throat clearing and management of any cough that may develop. Following WG, most patients will receive voice therapy and range and loudness exercises to work on various parameters such as resonance, intonation, affect, inflection and choice of word.

Feminization Laryngoplasty

Finally, another surgery which may be performed for feminizing the voice is the FEMLAR or the feminizing laryngoplasty in which the anterior portion of the cartilage along with the false and true vocal folds is excised and a new anterior commissure is formed for both the true and false vocal folds. This surgery works at various levels—decreasing the length of the vocal folds, increasing the tension of the vocal folds and also changing the resonance for the patient.

A survey on voice feminization surgery: Current practices, assessment techniques, and postoperative outcomes has been published in 2025 and provides a global perspective to this challenging subject.[6]

REFERENCES

1. Wendler J. Vocal pitch elevation after transsexualism male to female. Proceedings of the Union of the European Phoniatricians; Salsomaggiore, Italy. 1990;10:00221287-136.
2. Kim HT, Kang SJ, Cho IS, Lee DB. Update of Vocal Fold Shortening with Retrodisplacement of Anterior Commissure for Voice Feminization. Laryngoscope. 2024; 134(12):5054-61.
3. Rapoport SK, Park C, Varelas EA, Chang J, Brown SK, Kinberg E, et al. One-year results of combined modified Wendler glottoplasty with voice therapy in transgender women. Laryngoscope. 2023;133(3):615-20.
4. Anderson JA. Pitch elevation in transgendered patients: anterior glottic web formation assisted by temporary injection augmentation. J Voice. 2014;28(6):816-21.
5. Orloff LA, Mann AP, Damrose JF, Goldman SN. Laser-assisted voice adjustment (LAVA) in transsexuals. Laryngoscope. 2006;116(4):655-60.
6. Hess, MM, Hess, B. Survey on voice feminization surgery: current practices, assessment techniques, and postoperative outcomes. Eur Arch Otorhinolaryngol (2025). https://doi.org/10.1007/s00405-025-09772-4.

JAYPEE BROTHERS

for detailed information on otorhinolaryngology books, visit our website www.ejaypee.com, for detailed information on otorhinolaryngology books, visit our website www.ejaypee

Atlas of Phonomicrosurgery

Salient Features

- This second edition of *Atlas of Phonomicrosurgery* has some of the latest concepts in surgeries being performed for the management of glottic lesions of the vocal folds
- A concise introduction to the anatomy and principles of phonomicrosurgery, routine and difficult microlaryngoscopy including anesthesia and laser considerations
- High-resolution color photographs depicting the steps of surgery for various glottic lesions with special emphasis on the philosophy of phonomicrosurgery in each specific condition
- Case studies of polyps, cysts, sulci, mucosal bridge, Reinke's edema, glottic web, nodules, polyst, Wendler glottoplasty, leukoplakia, recurrent respiratory papilloma, contact granuloma, lipoma, autoimmune and granulomatous lesions, bilateral vocal fold paralysis and early glottic malignancy.

Nupur Kapoor Nerurkar MS (ENT) DORL is an ENT Surgeon, who has graduated with a first rank from King Edward Memorial Hospital, Mumbai, India. Since 2004, following her training in USA, she is practicing exclusively as a Laryngologist and Voice Surgeon. She is the Head of the Bombay Hospital Voice and Swallowing Center; Director of the Laryngology Fellowship Program and the DNB Coordinator of the ENT Department at Bombay Hospital in Mumbai where she has been conducting the popular annual workshops on phonosurgery since the past 19 years. She has been the past President of the Association of Phonosurgeons of India (APSI) and is on the governing council. She is the Chief Editor of *Textbook of Laryngology*, which is the official textbook of APSI.



Dr Nerurkar is a Founder and board Member of the International Association of TransVoice Surgeons (IATVS) and board Member of the International Association of Phonosurgeons (IAP). She is currently the only Indian Fellow of the American Laryngological Association (ALA) as well as the American Broncho-Esophagological Association (ABEA) and has been presented with a Presidential citation (ALA, 2024). She has over 100 publications to her credit and has delivered over 350 talks all over the globe including keynote addresses at International Federation of ORL Societies (IFOS-Paris), Cutting Edge Laryngology (UK) and LSA (Sydney). She remains passionate about teaching and staying abreast of cutting-edge advances in laryngology.

Shelving Recommendation
OTORHINOLARYNGOLOGY

ISBN 978-93-7202-839-3

9 789372 028393

Buy from ejaypee

JAYPEE BROTHERS