site www.ejaypee.com, for detailed information on radiology books, visit our website www.ejaypee.com, for detailed information on radiology books, visit our website www.ejaypee.com,

AIIMS-MAMC-PGI IMAGING SERIES

DIAGNOSTIC RADIOLOGY

Neuroradiology Including Head and Neck Imaging

Editors
Paramjeet Singh
Raju Sharma
Gaurav Shanker Pradhan

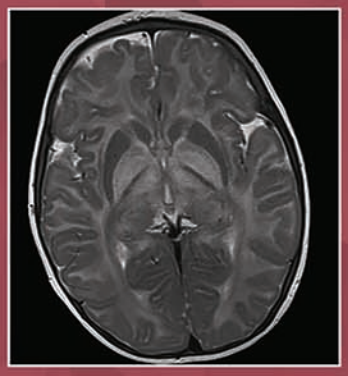



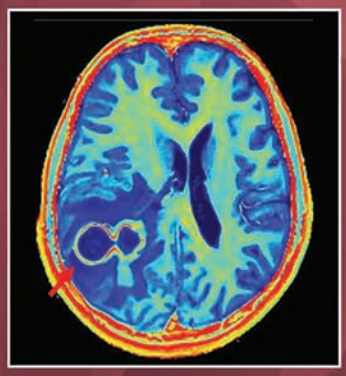

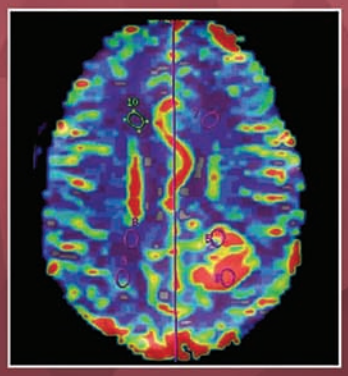

5th Edition

Associate Editors
Ajay Kumar
Sameer Vyas
Shailesh B Gaikwad
Ajay Garg
Sapna Singh
Jyoti Kumar

JAYPEE

CONTENTS

Section 1: Imaging Techniques and Advances

1. **Evaluation of Plain X-ray Skull: A Systematic Approach** 3
   Vikas Bhatia, Paramjeet Singh, Ajay Kumar

2. **Normal Anatomy of Brain on CT and MRI** 18
   Paramjeet Singh, Anuj Prabhakar, Vikas Bhatia

3. **Normal Cerebral Angiography** 42
   Shailesh B Gaikwad, Savyasachi Jain

4. **Advances in Neuroimaging Techniques: Computed Tomography** 53
   Sameer Vyas, Anuj Prabhakar, Ajay Kumar

5. **Advances in Neuroimaging Techniques: Magnetic Resonance Imaging** 67
   Sameer Vyas, Chirag Kamal Ahuja, Paramjeet Singh

6. **Magnetic Resonance Spectroscopy** 94
   Vikas Bhatia, Sameer Vyas, Paramjeet Singh

7. **Functional MRI** 121
   Anuj Prabhakar, Savyasachi Jain

Section 2: Interventional Neuroradiology

8. **Imaging and Interventions in Cerebral Ischemia** 133
   Shailesh B Gaikwad, Savyasachi Jain

9. **Imaging of Subarachnoid Hemorrhage** 153
   Chirag Kamal Ahuja, Vikas Bhatia, Ajay Kumar

10. **Endovascular Management of Intracranial Aneurysms** 176
    Shailesh B Gaikwad, Savyasachi Jain

11. **Endovascular Management of Arteriovenous Malformations** 199
    Ajay Kumar, Chirag Kamal Ahuja, Anuj Prabhakar

12. **Carotid-Cavernous Fistulas** 219
    Chirag Kamal Ahuja, Ajay Kumar, Sameer Vyas

Section 3: Infections/Demyelinating Disorders/Epilepsy

13. Central Nervous System Infections **237**
Sapna Singh, Gaurav Shanker Pradhan, Anjali Prakash, Radhika Batra

14. Imaging of White Matter Disease **301**
Anjali Prakash, Gaurav Shanker Pradhan, Swati Gupta

15. Imaging of Epilepsy **346**
Shailesh B Gaikwad, Savyasachi Jain

Section 4: Brain Neoplasms

16. Imaging of Supratentorial Brain Tumors **377**
Shailesh B Gaikwad, Savyasachi Jain

17. Imaging of Infratentorial Tumors **442**
Ajay Garg, Leve Joseph

18. Sellar and Parasellar Lesions **467**
Paramjeet Singh, Chirag Kamal Ahuja, Sameer Vyas

19. Intraventricular Lesions **495**
Chirag Kamal Ahuja, Paramjeet Singh, Anuj Prabhakar

Section 5: Head and Neck Imaging

20. Imaging of the Temporal Bone **521**
Anuj Prabhakar, Ajay Kumar, Chirag Kamal Ahuja

21. Imaging in Clinical Ophthalmology **545**
Sanjay Sharma, Amarinder S Malhi, Smriti Hari, Madhusudhan KS

22. Imaging of Paranasal Sinuses **567**
Jyoti Kumar, Swati Gupta, Satyam

23. Imaging of the Neck Spaces **596**
Rashmi Dixit, Sapna Singh, Radhika Batra, Alpana Manchanda

24. Thyroid Imaging **634**
Alpana Manchanda, Jyoti Kumar, Rashmi Dixit, Satyam

25. Malignancies of Upper Aerodigestive Tract **671**
Mukesh Kumar Yadav, Ashu Seith Bhalla, Sanjay Sharma, Stanzin Spalkit

26. Imaging of Skull Base Lesions **705**
Atin Kumar, Manisha Jana, Priyanka Naranje, Ashu Seith Bhalla

27. Maxillofacial Imaging: Imaging of Cysts, Tumors, and Tumor-like Conditions of the Jaw **727**
Smita Manchanda, Ashu Seith Bhalla, Atin Kumar

28. Craniovertebral Junction Anomalies **755**
Anuj Prabhakar, Vikas Bhatia, Sameer Vyas

29. Endovascular Management of Craniofacial Vascular Lesions **773**
Ajay Kumar, Chirag Kamal Ahuja, Vikas Bhatia

Section 6: Trauma and Spine Imaging

30. Imaging of Head Trauma **793**
Shivanand Gamanagatti, Atin Kumar, Rajendra Kumar Behera

31. Imaging of Facial Trauma **829**
Ajay Kumar, Paramjeet Singh, Anuj Prabhakar

32. Imaging of Acute Spinal Trauma **844**
Sameer Vyas, Vikas Bhatia, Paramjeet Singh

33. Spinal Neoplasm **861**
Ajay Garg, Leve Joseph

34. Spinal Vascular Malformations **883**
Shailesh B Gaikwad, Savyasachi Jain

35. Imaging of Low Backache **894**
Ankur Goyal, Shivanand Gamanagatti, Devasenathipathy Kandasamy, Raju Sharma

Section 7: Allied Neurosciences

36. Localization in Clinical Neurology **931**
Manish Modi, Manoj Goyal

37. Neuropathology for Neuroradiologists: A Practical Correlation **943**
Debajyoti Chatterjee, Sunny Bhardwaj

Index **959**

CHAPTER

32 Imaging of Acute Spinal Trauma

Sameer Vyas, Vikas Bhatia, Paramjeet Singh

JAYPEE BROTHERS

INTRODUCTION

Spinal trauma attributes to significant morbidity and mortality throughout the world and occurs with an annual incidence of approximately 15–40 cases per million.[1] It commonly results from motor vehicle accident (most commonly), fall from height, and penetrating and sports injuries.[1,2] Most studies had shown a bimodal age distribution and that it is more common in young adults (approximately 80%, <40 years) with a male predominance (80–85%).[3] Spinal cord injuries (SCIs) are seen in about 10–14% of spine fractures and dislocations. The incidence of neurological damage varies with the site of injury (fractures or dislocations) and is seen in approximately 40% of cervical spine, about 10% of thoracic spine, and about 4% of thoracolumbar junction injuries. However, there are no associated fractures or dislocations in about 10% of SCIs. Imaging plays a pivotal role in the evaluation of the acutely traumatized patient by providing information that allows timely and appropriate management, thus reducing the morbidity and mortality. In this chapter, we will discuss imaging indications, various imaging modalities, classifications, and imaging of spinal trauma.

IMAGING INDICATIONS OF SPINAL TRAUMA

Most of the patients presenting with blunt spinal trauma, even minors, are subjected to radiographs of the spine because of the significant morbidity and mortality associated with spinal trauma. It is very important to answer these two questions before performing any radiological investigation: Is imaging necessary? And if yes, what is the appropriate imaging technique? Several clinical trials have been carried out to improve guidelines, to standardize clinical practice, to help clinicians or radiologists to properly screen and use plain radiographs, and to reduce the workload of emergency department and cost of imaging.[2-4] Two clinical decision rules have been used for the suspected cervical spine injuries. The first rule developed was National Emergency X-Radiography Utilization Study (NEXUS) Low-Risk Criteria (NLC), which tested a five-part decision rule to predict patients with a spinal injury.[4] The NLC concluded that radiography after blunt C-spine trauma is unnecessary, if patients satisfy all five of the following *low-risk criteria*: (1) Absence of midline cervical spine tenderness, (2) normal level of alertness, (3) no evidence of intoxication, (4) no abnormal neurologic findings, and (5) no painful distracting injuries. Due to the low specificity of NLC, the Canadian C-spine rule (CCR) was developed subsequently based upon clinical questions. It stated that *low-risk patients* (ambulatory, without midline tenderness or immediate onset of pain, able to attain sitting position, victims of simple rear-end motor vehicle crashes) do not require imaging if they can actively turn their heads 45° in both directions. Similar clinical criteria have been evaluated in the thoracic and lumbar spine. Imaging is, however, indicated when high-risk factors are identified in these patients. These high-risk factors are summarized in **Box 1**.

The American College of Radiology (ACR) appropriateness criteria for suspected spine trauma highlight the following points:

- No imaging is required in patients having low-risk criteria by NLC/CCR.
- In adults with high-risk criteria by NLC/CCR, multidetector computed tomography (MDCT) is the investigation of choice. The entire spine is usually imaged due to high prevalence of noncontiguous multiple injuries.
- However, in children up to 14 years of age, radiography is the imaging method of choice due to high radiation

Box 1: Canadian C-spine rule: High risk-criteria.

High-risk criteria of CCR:

- Age > 65 years
- Dangerous mechanism of injury (e.g., fall from height > 1 m, high-speed motor vehicle accident)
- Paresthesia in extremities

Further high-risk criteria:

- Altered mental status
- Multiple fractures
- Drowning or diving accidents
- Significant head or facial injury
- Rigid spinal disease (i.e., ankylosing spondylitis, DISH)

(CCR: Canadian C-spine rule; DISH: diffuse idiopathic skeletal hyperostosis)

dose by a CT scan. Recommended views for cervical spine are anteroposterior (AP), lateral, and open mouth and for thoracolumbar spine are AP and lateral.

- Magnetic resonance imaging (MRI) is the method of choice when SCI, cord compression, and/or ligament injury is suspected, especially in obtunded patients.
- MRI is also considered in patients with persistent neck pain showing no evidence fracture on CT scan.[5]

Advanced imaging techniques are incorporated more frequently for evaluation of spinal trauma in older patients. It is because the elderly patients undergo a different injury pattern due to associated osteopenia, degenerative changes, and ankylosed spinal segments. Low-energy mechanism is a common cause of spinal fractures, especially in cervical spine. In addition, SCI is seen in over 20% of cases. CT is excellent to define the full extent of osseous injury; however, MRI should also be performed in this subset of patients due to a higher incidence of spinal cord and ligamentous injury.[6]

IMAGING MODALITIES OF SPINAL TRAUMA

The various imaging modalities for imaging spinal trauma are plain radiograph, tomography, myelography, CT, and MRI.[7,8] It is very important to decide the optimal imaging method for the spinal trauma patients depending upon the merits and limitations of each modality.

Plain Radiography

In the current scenario, radiographs are not usually obligatory prior to the CT for acute spinal trauma because a normal radiograph does not exclude an injury and hence a CT is eventually performed if the clinical suspicion of injury is high. Recent studies have shown that MDCT is more effective in the identification of thoracolumbar injuries compared to plain X-ray. The same fact is also supported by the ACR appropriateness criteria as already discussed. However, plain films are commonly used in the initial evaluation of a patient with spinal trauma. The first and most important radiograph in spinal trauma is the lateral view with cross-table technique.[9,10] This has been reported to be positive in 70–90% of cases. The standard additional views are AP open mouth for cervical spine, AP view for thoracic spine, and AP and oblique views for lumbosacral spine injury. The most important addition in the routine views of cervical trauma patients has been the cervical trauma oblique view.[11] This is obtained with patient lying supine and an X-ray tube is angled 30–40° from horizontal. This view more often provides a clear visualization of C1 to T1 with an additional 15° cranial tube tilt. A traditional "swimmer's view" is obtained only if "trauma oblique view" is inadequate.[11] The "swimmer's view" usually needs a change in the patient's position and is contraindicated in a high suspicion of cervicothoracic injury and is not helpful in obese or muscular patients. The use of flexion–extension radiographs is controversial and can be performed if there is a question of the ligamentous injury. However, they should be performed only in conscious patients who are able to cooperate and only active motion should be applied. Limitations of plain radiography include inability to detect subtle undisplaced fractures, to visualize upper cervical (C1, C2) and cervicothoracic junction, and to evaluate nonosseous injuries. At present, CT has replaced plain X-ray as the initial modality for evaluation of spinal trauma at many level 1 trauma centers across the world.[12]

The use of tomography in the evaluation of acute spinal trauma is obsolete with the advent of CT, especially MDCT. Disadvantages of tomography include need to change the position of the patient for lateral tomography and high radiation dose as compared to CT. The role of myelography has significantly reduced since the advent of CT and MRI. It is an invasive procedure and has limited role in the present scenario, i.e., patients with contraindication to MRI. There are contrast-related complications and risk of arachnoiditis. Myelography may still be indicated in the evaluation of nerve root avulsions or suspected dural tears.

Computed Tomography

Multidetector CT is the preferred imaging modality for evaluating blunt spinal trauma patients.[13-16] The high-quality multiplanar reformations in different planes in MDCT have markedly improved the detection of varied spinal abnormalities like abnormal intervertebral distance, abnormal angulations, subluxations, and dislocations which were not well visualized in axial CT plain radiography or tomography. The advantages of MDCT include larger area coverage, short scanning time, thinner slices, and better reconstructions. Thin

JAYPEE BROTHERS

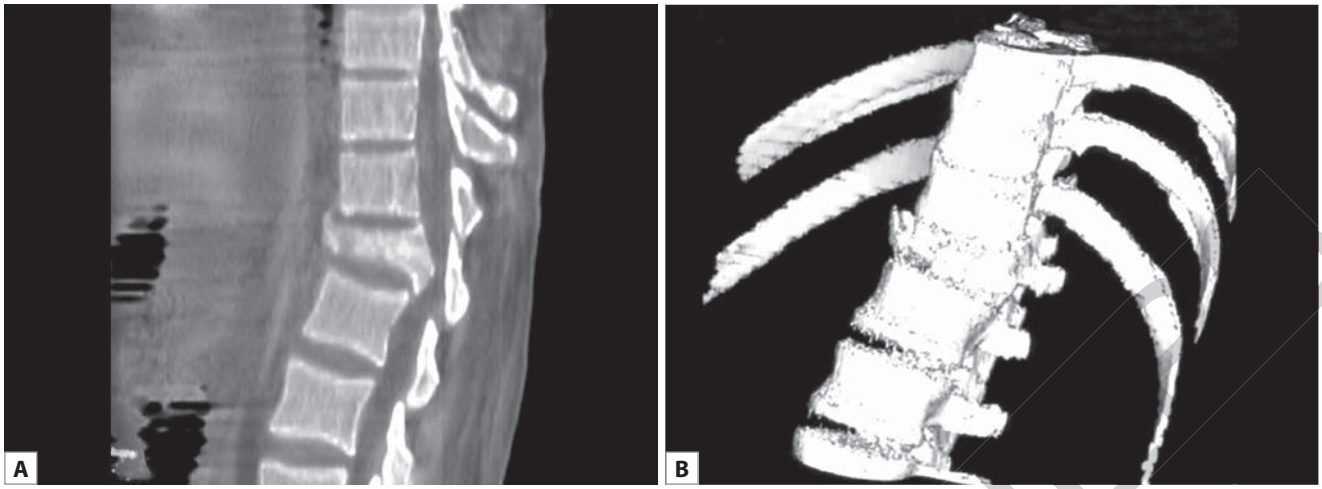

FIGS. 1A AND B: (A) Sagittal reformation of multidetector showing fracture fragments and posterior displacement; (B) 3D CT demonstrating the fractured vertebra.

contiguous axial sections are acquired in the helical mode at the site of interest. Other advantages of CT include the ability to assess the spinal canal and impingement by osseous fragments, optimal visualization of vertebral injuries, soft-tissue abnormality and associated disk prolapse and imaging without changing the patient's position. The disadvantages of CT include incomplete evaluation of horizontal fractures and displacements in the sagittal plane. Multiplanar and three-dimensional (3D) reconstructions help in the evaluation of vertebral alignment and horizontal fractures.[17,18] The spatial information and relationship in complex fractures are better appreciated on 3D images **(Figs. 1A and B)**. Limitations of the CT in spinal trauma include radiation exposure and inability to assess SCI.

Magnetic Resonance Imaging

The role of MRI in acute spinal trauma is fully established, especially in the evaluation of spinal cord, both in correlating the appearances of the spinal cord with the level of neurologic deficit and in identification of parameters predictive of neurologic outcome.[19-22] It is the investigation of choice for assessing injuries to the soft-tissue structures including posterior ligamentous complex, spinal cord, intervertebral disks, and adjacent muscles **(Figs. 2A and B)**. Thus, no contraindications assumed, an immediate MRI is warranted if CT/neurological symptoms suggest an injury to the neural/ligamentous structures.

According to ACR appropriateness criteria, MRI of spine combined with CT is appropriate in the setting of acute spinal trauma if NEXUS or CCR criteria are met and clinical/imaging (X-ray/CT) findings are suggestive of:

- Myelopathy
- Ligamentous injury
- Mechanically unstable spine

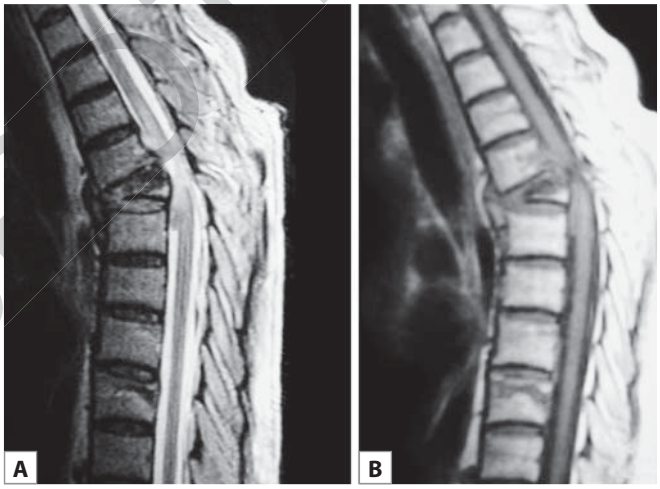

FIGS. 2A AND B: (A) Sagittal T2- and (B) T1-weighted MRI of the dorsal spine, showing burst fracture with retropulsion and spinal cord changes.

The radiographic or CT findings which suggest ligamentous injury include findings like spondylolisthesis, widening of facet joints/interspinous space, or asymmetric disk space widening.

Magnetic resonance imaging is also used for prognosticating the injury by differentiating the hemorrhagic and nonhemorrhagic cord injury as the former is associated with poorer prognosis.

Both T1- and T2-weighted sequences with a spin echo technique in axial, sagittal, and coronal planes are helpful in the assessment of the spinal injury. A spine surface coil is used to improve resolution. T1-weighted images are helpful in the assessment of bony element abnormality, while T2-weighted images are more useful for the assessment of spinal cord. Cord contusions manifest as hyperintense foci on T2-weighted images and are iso- to hypointense on T1-weighted images. Gradient-echo (GRE) images help to identify the hemorrhagic cord

JAYPEE BROTHERS

contusions which have prognostic significance. Short tau inversion recovery (STIR) and T2 fat sat images are sensitive for detection of marrow edema, which is seen in acute fractures but not in chronic fractures. Appearance of cord hemorrhage varies with the age of hematoma. Patients with predominant edema or contusions show neurological improvement, whereas cord hemorrhage has a poor outcome.

Ideally, MRI should be done within 72 hours of injury. It is because during this period, edema gives a T2 hyperintense signal which in turn increases the conspicuity of the ligaments. Later on, as the edema subsides, the sensitivity of MRI for detection of injury also reduces.[23] In addition, the long-term sequelae of spinal cord trauma such as cord transection, traumatic syrinx, myelomalacia, and meningocele are well delineated with MRI. The details of MRI for assessing nonosseous injury will be discussed later in this chapter.

The disadvantages of MRI as compared to CT include its relative inferiority for demonstration of osseous anatomy and fractures and failure to detect the posterior element fractures. In addition, MRI is expensive, not readily available, and patient support and ventilator system should be magnetic resonance compatible.

Advances in Magnetic Resonance Imaging

Diffusion-weighted imaging (DWI): Post-traumatic spinal canal hematoma, though rare, occurs most commonly in cervical spine due to the injury to the epidural venous plexus. Depending on the age of the hematoma, sometimes it becomes difficult to differentiate it from the epidural fat. Hoch et al. have shown that hematoma has fairly obvious hyperintensity on diffusion trace images due to echo planar imaging (EPI) signal artifact.[24] They also show diffusion restriction due to the gelatinous nature of the evolving hematoma. It has also been shown that if the cord shows T2 hyperintensity along with low apparent diffusion coefficient (ADC) value in acute epidural hematoma, the patient may suffer from irreversible compressive cord damage.[25] The role of DWI has also been studied in patients with spinal cord injury without neuroimaging abnormality (SCIWNA) as discussed later. Use of DWI is, however, limited by distortion of the image due to magnetic field inhomogeneity and susceptibility changes due to bones and ligaments of the spine. In addition, there is physiologic motion of the cord secondary to respiratory and cardiac motion which further degrades the quality of image.

Diffusion tensor imaging (DTI): It assesses the integrity of the white matter tracts in the spinal cord and can detect very early changes in SCI which are not seen on conventional MR images. Shanmuganathan et al. revealed that whole cervical spine DTI parameters in patients with cervical cord contusions were significantly different compared to healthy controls.[26] A higher decrease in ADC and average roughness (RA) values was seen at the site of injury. Thus, DTI can be used to document the true extent of injury which otherwise appears normal on conventional imaging. They also concluded that a change in DTI parameters correlated with the severity of cord injury and can be used for predicting the severity of cord injury and monitoring recovery following treatment.

CLASSIFICATIONS OF SPINAL TRAUMA

Spinal trauma can be classified according to the level of injury, severity of injury, mechanism of injury, and stability versus instability.[7]

Level of Injury

Cervical spine injury is most common (40–60%) due to excessive mobility and lack of supporting structures. Thoracic spine injury is less common (20%) as the stability is provided by thoracic cage, whereas, lumbar spine injury is seen in about 20–30%. Most of the thoracic and lumbar injuries are seen at the thoracolumbar junction (60% between D12 and L2) as there is a transition from the immobile to the mobile segment and orientation of facet joints from coronal to sagittal. Multilevel injury is seen in about 5–20%.

Severity of Injury

Spinal trauma is minor, when associated with no neurological symptoms and the patient is alert and able to cooperate. It is major, when associated with neurological deficits and the patient is unconscious as well as having multisystem trauma.

Mechanism of Injury

Flexion, extension, rotation, compression, distraction, or shear forces may produce damage in isolation or in combination. Ligaments are resistant to compression or distraction but are vulnerable to rotation or shear forces. But the osseous end plates fail when pure compressive or tensile forces are applied to the vertebra. Thus, pure compression or distraction produces fracture whereas rotatory or shear forces result in dislocations.

- Flexion injury results in anterior wedging, vertebral body fractures, and posterior longitudinal ligament (PLL)/interspinous ligament disruption.
- Hyperextension injury causes fractures of the posterior element and anterior longitudinal ligament (ALL) rupture and subluxations. It is common in C-spine.
- Vertical compression (axial load) injury causes burst/compression fractures and lateral element fractures. It is seen in diving and jumping injury.
- Rotation-shearing injury results in lateral mass fracture and facet subluxation.

JAYPEE BROTHERS

Stable versus Unstable Fracture

Spinal injuries which can withstand stress without progressive deformity and neurological damage are referred to as stable injuries, whereas injuries where spine is not able to maintain integrity and further damage to spinal cord or nerve root cannot be avoided are reefed to as unstable injuries. Dennis introduced the concept of three columns of spine and concluded that instability requires disruption of at least two of these columns.[27] Anterior column is formed by the anterior half of the vertebral body, ALL, and anterior annulus. Middle column is formed by the posterior half of the body, PLL, and posterior annulus. Posterior column is formed by the posterior bony complex (pedicles, lamina, articular processes, and spinous process) and the posterior ligamentous complex (facet joint capsule, ligamentum flavum, interspinous and supraspinous ligaments). Signs of instability on imaging include widened interspinous distance, increased facet joint distance, disk space narrowing, focal angulation of >11°, vertebral body compression of >25%, and subluxation of >3.5 mm.

RADIOLOGICAL INTERPRETATION OF SPINAL TRAUMA (ABCS)

The radiographic signs of trauma are as follows:

- *A—Alignment*: Disruption of lines, focal kyphoscoliosis, rotation of spinous process, increased interpedicular distance, and vertebral listhesis
- *B—Bone integrity*: Fracture, anterior wedging, cortical buckling, disrupted posterior vertebral line, and disrupted C2 ring
- *C—Cartilage*: Interspinous/facet joint widening, increased/decreased disk spaces, and vacuum phenomenon
- *S—Soft tissue*: Widening of pre-/paravertebral soft tissue

NEW RADIOLOGICAL CLASSIFICATION SYSTEMS

The newer classification systems like subaxial injury classification [Subaxial Injury Classification and Severity Scale (SLICS)] and thoracolumbar injury classification and severity score (TLICS) have included neurologic status of the patient and integrity of posterior ligamentous complex for grading the status of the patient **(Table 1)**. It is contrary to the old radiological classification systems which only considered the location and morphology of the fracture. These newer classifications (TLICS and SLICS) are based on a scoring system that also provides a therapeutic recommendation toward surgical or conservative management. In addition, MRI has found its way into this classification system which includes evaluation of the posterior ligamentous complex.[5]

AO Spine Classification[28]

The AO spine classification is developed by the AO Spine Knowledge Forum Trauma and is the new standard

TABLE 1: Thoracolumbar injury classification and severity score.

Morphology	0	No abnormality	Radiograph/CT/MRI
	1	Compression	
	2	Burst fracture	
	3	Rotation/translation	
	4	Distraction	
Posterior ligamentous complex	0	Intact	MRI*
	2	Suspected/indeterminate	
	3	Injured/disrupted	
Neurologic status	0	Intact	Physical examination
	2	Root injury	
	2	Complete cord/conus medullaris injury†	
	3	Incomplete cord/conus medullaris injury	
	3	Cauda equina syndrome	
Score	≤3	Nonoperative treatment	
	4	Consider conservative or surgical therapy	
	≥5	Operative treatment	

*The most reliable signs of PLC injury are disruption of the low-signal intensity black stripe on sagittal T1/T2WI, fluid in the facet capsules, or edema in the interspinous regions.

†Contrary to expectation, a higher score (3 points) is allocated to incomplete cord injury and cauda equina syndrome because these patients may experience a better outcome from surgical decompression than patients with complete SCI.

JAYPEE BROTHERS

for classifying spine injuries based on morphology, neurological status, and clinical modifiers. This classification is a simple and reproducible method for describing the pattern and severity of injury and is based on three mechanisms of injury with increasing severity: Type A as compression, Type B as distraction, and Type C as translation. It has evolved as a complete system which can be simply used as it is mainly CT based and MRI is not required in most cases. There are four injury classification systems published by this classification system based on the site of involvement—Spine has: (i) Upper cervical classification system, (ii) subaxial cervical classification system, (iii) thoracolumbar classification system, and (iv) sacral classification system.

IMAGING OF SPINAL TRAUMA

Cervical Spine Injury

Cervical spine injuries occur predominantly at two levels. One-third fractures occur at the level of C2 and one half at the level of C6 or C7. The most frequent mechanism of injury is flexion, followed by extension, vertical compression, and rotation. Injuries of the cervical spine can be divided into injury of upper (C1–C2) and lower (C3–C7) cervical spine.

Upper Cervical Spine Injuries

The upper cervical spine differs both anatomically and functionally from the remainder of the spine. The primary motion is rotation. The bony ring of C1 lacks a body and spinous process and its articulation with C2 is circular and flat. This unique anatomy results in a set of injuries. Upper cervical spine injuries can be divided into dislocations of the cervical spine (occipito-atlanto-axial injuries) and fractures of C1 or C2. Occipito-atlantoaxial injuries occur as atlanto-occipital dislocation or atlantoaxial subluxation.

Atlanto-occipital Dislocation

Traumatic atlanto-occipital dislocation is a rare but fatal injury as it is often associated with spinomedullary transection. The mechanism of the injury is hyperextension and distraction. Plain radiography shows retropharyngeal soft-tissue swelling, anterior displacement of basion from its normal position superior to odontoid (distance > 12.5 mm on lateral film), and malalignment between the spinolaminar line of C1 and the posterior margin of foramen magnum. CT demonstrates the above findings clearly particularly with the reformatted images. MRI helps to delineate cord transection that is often associated **(Figs. 3A and B)**.

Atlantoaxial Injuries

Post-traumatic atlantoaxial subluxation is a rare injury. Tears of the transverse ligament or avulsion fractures at the site of insertion allow anterior displacement of C1 relative to C2. The normal distance between dens and posterior margin of C1 in adults is <3 mm (<5 mm in children). It widens abnormally in flexion. Plain films in flexion and extension or conventional tomography is most helpful in detecting subluxation. Rotatory atlantoaxial dislocation may occur following minor trauma or it may develop spontaneously following upper respiratory tract infection. The atlas is rotated > 45° and the facets are often locked.

Anteroposterior open mouth view shows eccentrically placed dens and no movement following cranial rotation. CT in both resting positions and with maximum rotation to the contralateral side is the optimal method of evaluation. There is no change in the relationship of C1 and C2 with contralateral rotation in rotatory dislocation, whereas in normal healthy subjects or patients with torticollis, the deformity is corrected.

Fractures of the Atlas (C1)

A variety of C1 ring fractures have been described, but the most common is that involving posterior arch as it is compressed between the occiput and posterior arch of C2 in extension. Gehweiler and colleagues classified it into five types:

- *Type 1*—fracture of the anterior arch
- *Type 2*—fracture of the posterior arch
- *Type 3*—combined fracture of the anterior and posterior arches (Jefferson fracture)
- *Type 4*—fracture of lateral mass
- *Type 5*—fracture of transverse process

Axial compression of C1 results in Jefferson fracture that consists of ipsilateral disruption of both the anterior and posterior arches and it may be unilateral or bilateral. The patient is neurologically intact unless the transverse ligament is disrupted. Plain film or CT shows soft-tissue swelling, anterior/posterior arch fracture, and lateral displacement of lateral masses of atlas relative to C2.

Vertebral artery injury (VAI) can be associated with atlas fracture (most commonly with type 5 fracture).

Fractures of the Axis (C2)

The Anderson and d'Alonzo classification of odontoid fractures is based on fracture location and has both therapeutic and prognostic significance **(Fig. 4)**. Type I fractures are oblique fractures through the tip of the dens secondary to avulsion of the alar ligament (stable). Type II fracture occurs at the junction of dens and body of C2 (nonunion is as high as 36%). Type III is horizontal fracture

JAYPEE BROTHERS

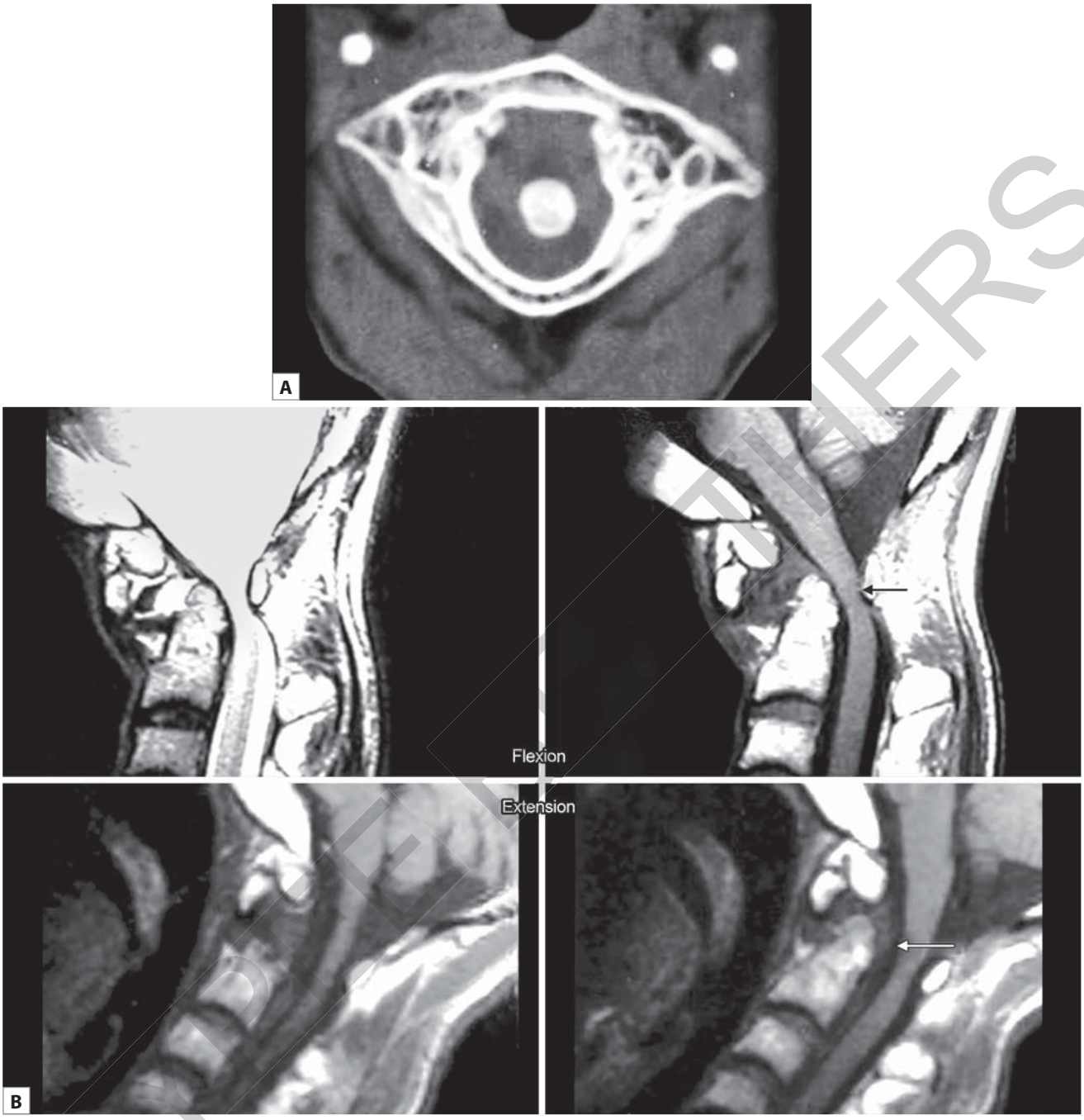

FIGS. 3A AND B: (A) Axial CT showing posteriorly dislocated odontoid process with anterior compression of cord; (B) Sagittal MRI T1 and T2WI in flexion and extension confirm atlantoaxial dislocation as well as cord compression (maximum in flexion).

JAYPEE BROTHERS

through the C2 vertebral body (frequently displaced). Odontoid fractures are best evaluated by open mouth AP view. Since these fractures are mostly horizontal, CT with sagittal and coronal reformats is useful for their detection and characterization.

The most characteristic injury of C2 is Hangman's fracture that includes bilateral avulsion of neural arches from the vertebral body. In reality, this fracture usually involves the pars interarticularis and is referred to as traumatic spondylolisthesis and accounts for 4–7% of all cervical spine fractures. It is classified into three subtypes. Type I is a minimally displaced fracture, Type II is associated with more displacement with involvement of the adjacent disk, and Type III includes bilateral facet dislocation with anterior displacement and angulations **(Figs. 5 and 6)**. The lateral view of the cervical spine demonstrates the fracture in more than 90% of patients. There is anterior subluxation of C2 vertebral body and

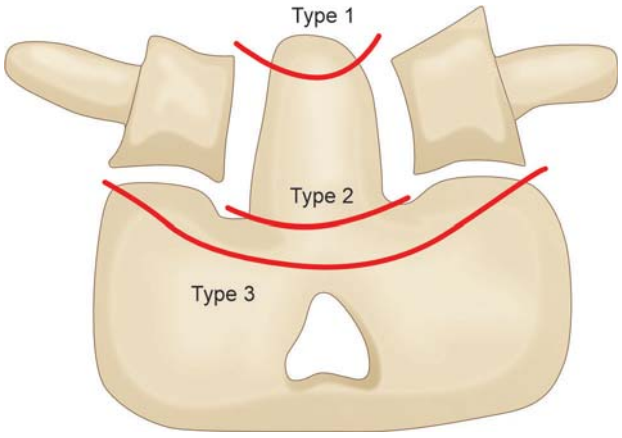

FIG. 4: Anderson and d'Alonzo classification of odontoid fractures.

retrolisthesis of the posterior elements of C2 relative to C3. CT is necessary to detect type I fracture as well as vertebral foramen involvement.

Lower Cervical Spine Injury (C3–C7)

The most frequent mechanisms of lower cervical spine injury are flexion and hyperextension.

Flexion injuries are the most common accounting for 50–80% of all cervical spine injuries.[29] C4–C7 vertebrae are affected most commonly **(Figs. 7 and 8)**. Simple wedge compression fracture may involve one or more anterior vertebral bodies without concomitant injury to the posterior vertebral body or posterior bony elements. The clay shoveler's fracture is an oblique fracture of the



FIG. 5: Sagittal multidetector CT (MDCT) reformation showing fracture of the C2 with anteriorly displaced odontoid.

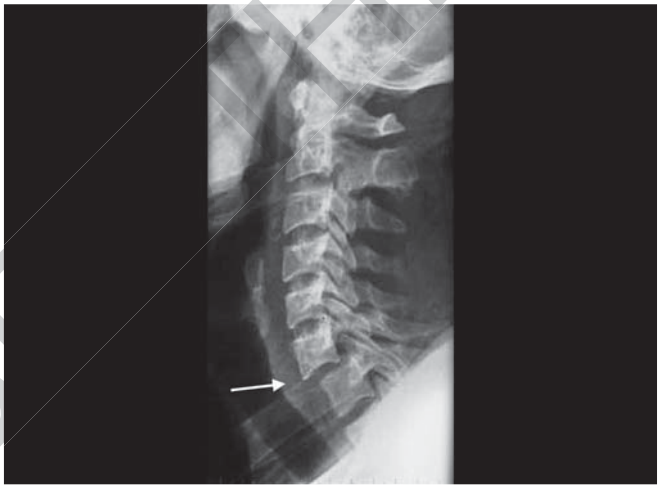

FIG. 7: Lateral view of the C-spine showing anterolisthesis of C6 over C7 with widening of prevertebral space (arrow).

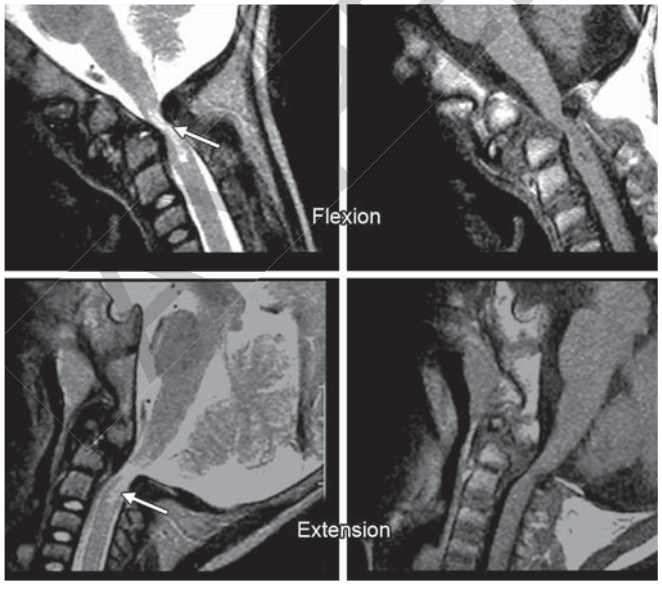

FIG. 6: Sagittal T1 and T2WI in flexion and extension show Type II odontoid fracture with cord compression and abnormal T2 cord signal (arrow).

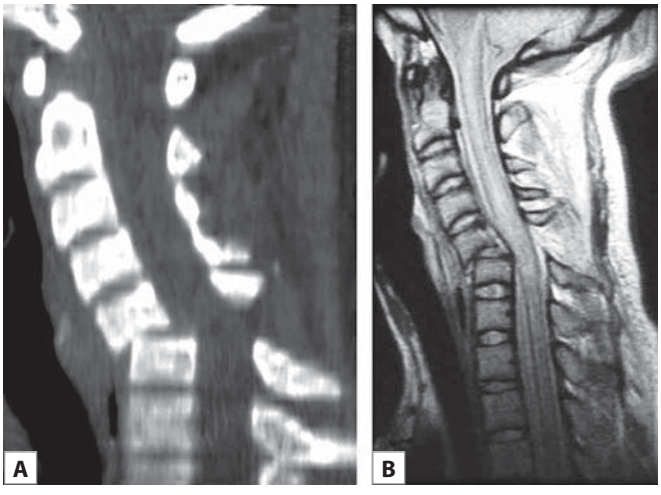

FIGS. 8A AND B: (A) CT sagittal reformation showing fracture dislocation of C5 with anterior displacement; (B) Sagittal T2WI confirms the fracture dislocation but additionally demonstrates cord injury.

NOT TO BE DISTRIBUTED

spinous process of C6 or C7 resulting from avulsion by the supraspinous ligament. The unstable flexion injuries include hyperflexion sprain, bilateral articular facet lock, and flexion tear drop fracture. The hyperflexion sprain is a ligamentous injury with disruption of the posterior ligamentous complex. Radiographic features are focal hyperkyphosis, mild anterior listhesis, widened apophyseal and interspinous space, and narrowed anterior disk space. The facet joint may be subluxated. Flexion/extension views as well as delayed images after resolution of muscle spasm are often helpful. Bilateral facet lock is secondary to disruption of posterior and middle columns. This injury is recognized easily on lateral film as anterior subluxation with "bow-tie" sign (oblique position of facet and articular masses). On CT, facet dislocation is recognized by the "naked" facet sign where articular surfaces of the apophyseal joints are no longer in apposition.

Flexion tear drop fracture results in acute anterior cord syndrome due to disruption of anterior and posterior ligamentous structures as well as intervertebral disk and apophyseal joints. Radiographically, there is a triangular fragment from the anteroinferior corner of the vertebral body (the tear drop), widening of interspinous and interfacet spaces, posterior disk space narrowing, fracture of lamina, and focal kyphosis.

Hyperextension injuries include a wide spectrum of injuries that may be radiologically occult. In patients with neurologic damage and normal radiographs, hyperextension injury should be suspected. The injuries include hyperextension tear drop fracture, SCIs secondary to impingement, and ligamentous sprain. MRI is the optimal method for evaluation of spinal cord impingement in these patients **(Figs. 9A and B)**.

THORACOLUMBAR SPINE INJURY

Most of the fractures in the adult thoracic and lumbar spine occur near the thoracolumbar junction; about 60% are found between T12 and L2 and about 90% are located between T11 and L4. The increased susceptibility to injury at the thoracolumbar junction is due to loss of the stabilizing effect of the ribs and thoracic musculature, change of thoracic kyphotic curve to lumbar lordotic curve, and change in orientation of the articular facet joints from the thoracic coronal to lumbar sagittal plane. The thoracolumbar injuries have been classified into hyperflexion compression (wedge) fractures, burst fractures, flexion distraction (chance type fracture or lap seat-belt type), and fracture dislocation.

Compression or Wedge Fracture

It is the most common type of injury of the thoracolumbar spine comprising approximately 48% of all fractures. The mechanism of injury is hyperflexion of the spine with the axis of rotation located in the center of the intervertebral disk and represents failure of the anterior column. Flexion compression injuries result in anterior wedge fractures **(Figs. 10 and 11)**. Depression of the anterior column is usually <50% of the focal vertebral height and is usually most prominent at the superior endplate. A >50% loss of the anterior vertebral body height is frequently associated with posterior ligamentous injury and/or subluxation/dislocation of facet joints. Plain radiograph shows anterior wedging of the vertebral body with or without fracture of the anterior bony cortex. Height of posterior bony cortex and interpedicular distance is maintained. In general, anterior vertebral height > 2 mm shorter than the posterior vertebral height indicates a fracture.

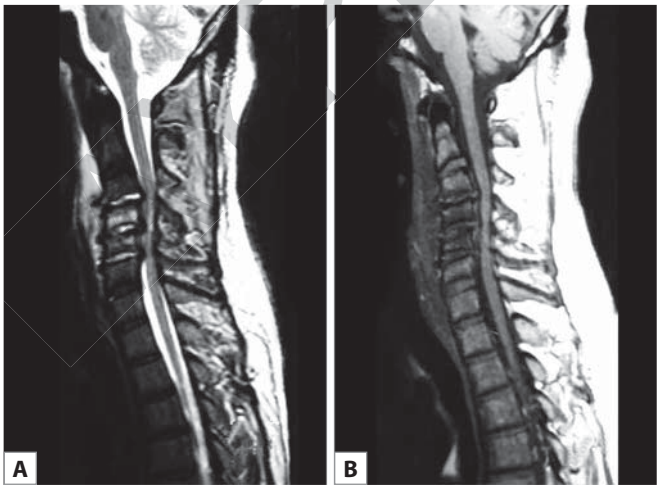

FIGS. 9A AND B: Sagittal T2 and T1WI showing altered curvature with marrow signal of the mid-cervical vertebrae. In addition, cord changes are also seen in the form of abnormal T2 cord signal.

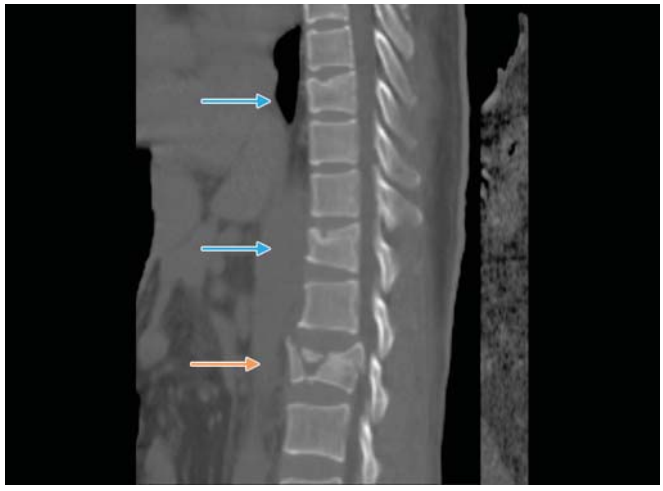

FIG. 10: Sagittal noncontrast CT spine (bone window) showing burst fracture (orange arrow) of the L2, with wedge compression fracture (blue arrows) of D12 and D9 vertebral levels.

PEER REVIEWERS

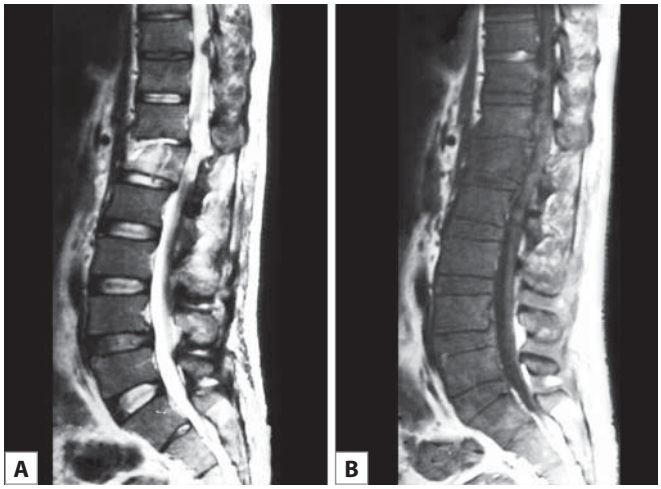

FIGS. 11A AND B: Sagittal T2- and T1WI showing wedge fracture with altered marrow signal of L1 vertebra.



FIG. 12: Sagittal multidetector CT reformat showing burst fracture of the D5.

Burst Fracture

Burst fracture comprises approximately 14% of all spinal fractures. The mechanism of injury is axial compression of the vertebral body and represents failure of both the anterior and middle columns. The fractures are usually unstable and frequently associated with neurological deficit **(Figs. 12 to 14)**. Plain radiograph shows a decrease in the height of the vertebral body (anterior and posterior), displacement of bony fragment in the spinal canal, and vertical fractures involving the pedicle/laminae/spines. Two signs, namely posterior bow sign and vanishing line sign, have been described recently to diagnose burst fractures. Normally, the posterior cortex is seen as thin white line concave posteriorly. Posterior bow sign occurs when the posterior cortex is deformed and becomes convex. This represents the most posterior aspect of the retropulsed fragment. Vanishing line sign occurs when the

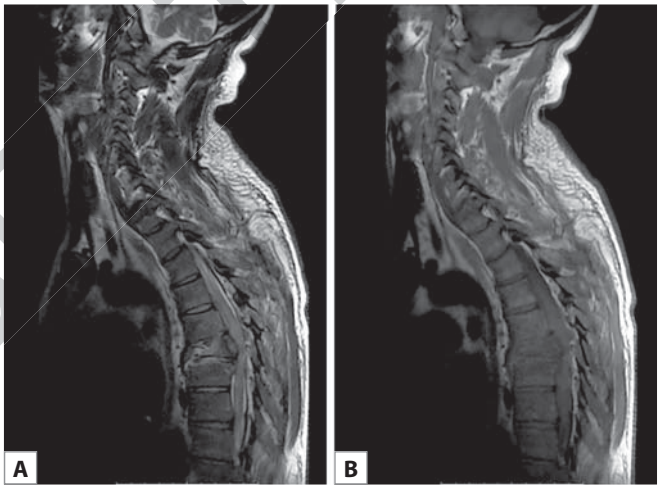

FIGS. 13A AND B: Sagittal T2 and T1WI showing burst fracture of D6 vertebra with posterior displacement. Note associated ligamentous disruption and cord edema.

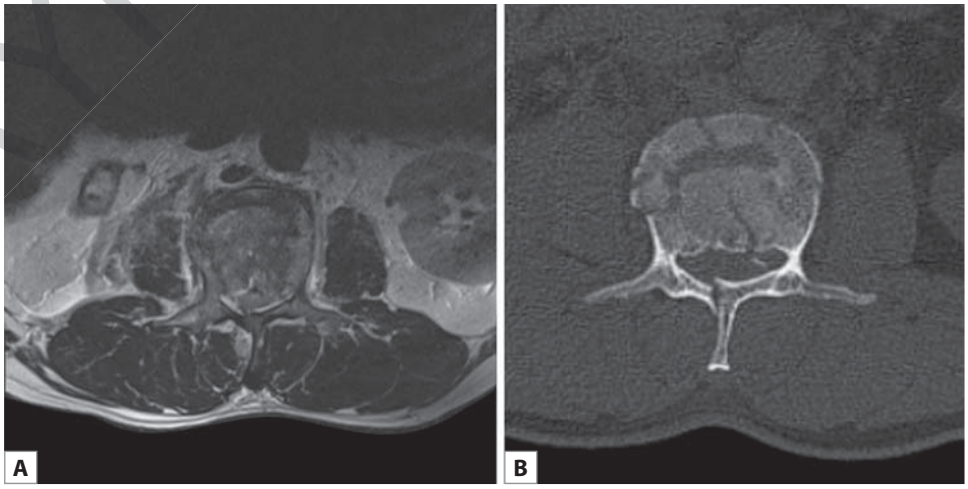

FIGS. 14A AND B: T2W MRI axial (A) and axial noncontrast CT in bone window (B) and showing burst fracture of the L2 vertebral body.

JAYPEE BROTHERS

dorsal cortex is displaced so far back that it is no longer visible and becomes obscured by the posterior elements.

Computed tomography is clearly the best way to evaluate burst fractures. The findings include comminuted fracture of the vertebral body (greatest near the superior aspect), disruption of the posterior vertebral body, fracture fragments in the spinal canal, and fractures of posterior elements with or without disruption of the apophyseal joint. Sagittal or 3D reconstruction clearly shows the retropulsed fracture fragment and the unstable spine. MRI may show the cord changes like cord contusion/hemorrhage, compression of cord, and soft-tissue hematoma/contusion.

Lap Seat-belt-type Fracture or Chance Fracture

The most common variant of flexion-distraction injuries of the thoracolumbar spine is the "seat-belt-type injury". It represents 10% of all spinal fractures and has a high frequency of neurological deficits. The mechanism of injury is hyperflexion with distraction of the posterior spinal elements and the axis of rotation is located more anteriorly at the anterior abdominal wall in contrast to compression or wedge fracture. It is frequently but not always the type of injury associated with the use of lap seat-belt. It represents failure of both posterior and middle columns.

Three subtypes of seat-belt-type injury have been described. Horizontal disruption pattern may either involve posterior bony elements (type I chance fracture) or posterior ligaments (type II Smith fracture). In the third type, the annulus fibroses are torn allowing for subluxation. Plain radiograph shows an increase in the distance between the spinous process and horizontal fractures of lamina, pedicles, and posterior aspect of the vertebral body. There may be an apparent increase in the height of the posterior aspect of body or widening of disk space. MDCT with sagittal reconstruction may demonstrate the nature and extent of the injury.

Fracture Dislocation

Fracture dislocation comprises approximately 15% of all spinal injuries. The injuries result from violent complex shearing force, and there is disruption of all three spinal columns which causes gross instability. There is anterior dislocation with severe hyperflexion injuries and facet joints may be dislocated with flexion rotation injuries **(Figs. 15A and B)**. Plain radiograph shows displacement of vertebral bodies, multiple fractures, locking of articular processes, and compression of vertebrae below. CT demonstrates fracture dislocation very clearly as these are recognized by "double rim" sign and "naked facet" sign. When the inferior facet of superior vertebra and superior facet of inferior vertebra are displayed on different images, the facet joint is said to be disrupted and the sign is called "naked facet sign". Reconstructed images demonstrate the degree of canal compromise.

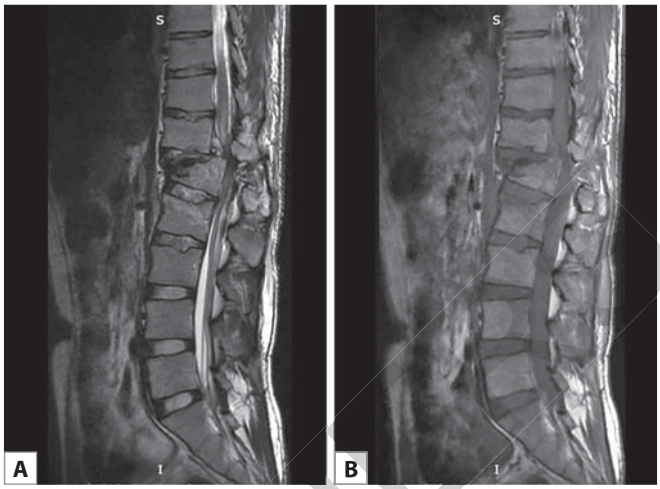

FIGS. 15A AND B: Sagittal T2WI and T2WI MR images show unstable fracture involving all three columns with associated cord edema.

NONOSSEOUS INJURY

Nonosseous injuries in the spinal trauma include injury to spinal cord, intervertebral disk, ligaments, and nerve roots.[30,31] In addition, there is formation of spinal epidural hematoma and tears of dura in major spinal trauma.

Spinal Cord Injuries

Spinal cord injuries can result directly from spinal trauma (fracture or dislocations) or indirectly from compression by the displaced bony fragment, hematoma or disk material, or ischemia from damage or impingement of the spinal arteries. MRI can depict the exact location, extent, and severity of the injury and cord changes (edema or hemorrhage) **(Figs. 16 and 17)**. Patients with minimal cord changes on MRI have the best outcome followed by those with cord edema.[32]

For assessment of SCI, the best MRI sequences are axial and sagittal T2W and T2*GRE images. The most common MRI findings of SCI are hyperintensity on T2WI involving the cord suggestive of edema and hypointensity on T2/GRE indicating hemorrhage. Presence of hemorrhage on MRI is the most important imaging finding associated with poor prognosis, probably explained by the acceleration of the injury cascade due to the presence of iron that potentiates lipid peroxidation. Other findings of prognostic significance are extent of cord hematoma or edema and cord compression by extra-axial hematoma **(Fig. 17)**. In addition, very early detection of spinal

JAYPEE BROTHERS

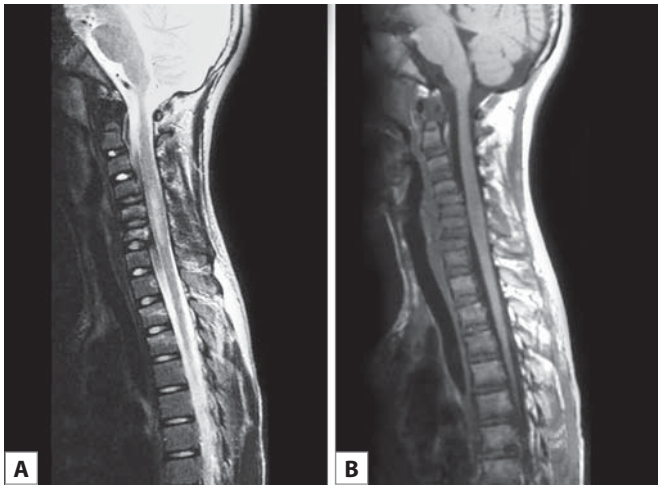

FIGS. 16A AND B: Sagittal T2 and T1WI showing increased signal intensity within the cervical spinal cord representing intramedullary edema.

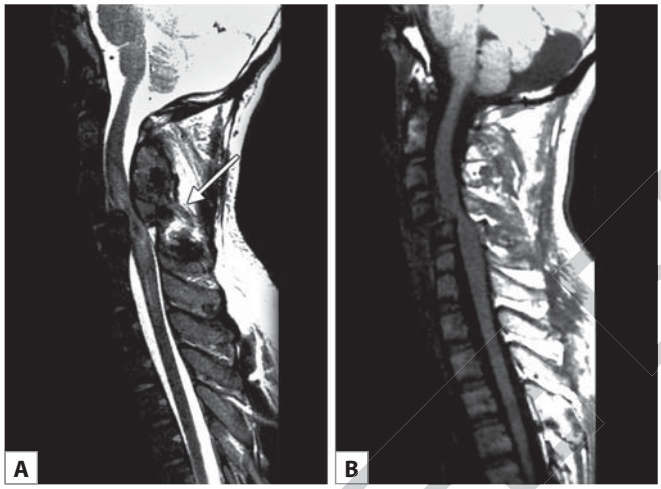

FIGS. 17A AND B: Sagittal T2 and T1WI demonstrate unstable fracture with fracture dislocation of C4–C5 vertebrae. Extensive abnormal cord signal on T2WI which is consistent with cord contusion. Note also the mode of interspinous ligament injury (arrow).

cord damage is possible with diffusion-weighted MRI. Resolution of spinal cord edema as demonstrated on follow-up MRI often will correlate with (limited) neurologic improvement. An entity which is more frequently described in elderly patients with hyperextension injury is "acute traumatic central cord syndrome" in which the patient experiences disproportionately severe upper extremity motor weakness along with bladder dysfunction and sensory loss below the level of injury. This happens due to associated extensive degenerative changes in the elderly patients. The osteophytes or buckled ligamentum flavum along with narrowed spinal canal may result in injury to the central gray matter along with injury to the central portion of the corticospinal tract of the spinal cord.

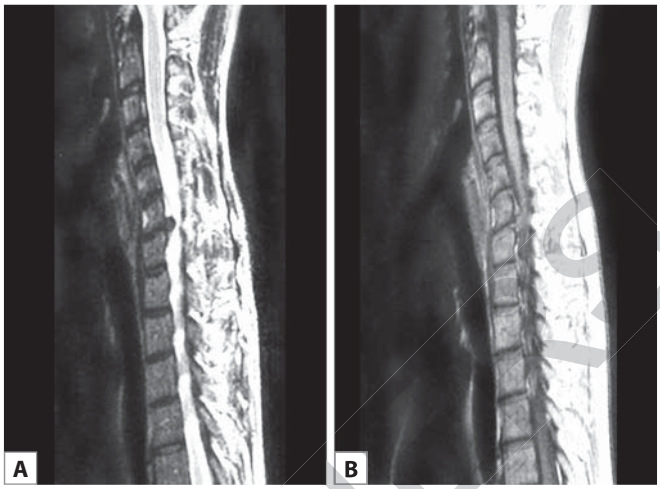

FIGS. 18A AND B: Sagittal T2- and T1WI showing protrusion of C6–C7 disk into the epidural space with significant neural compromise.

Many studies have shown correlation of SCI with the neurological outcome and concluded that MRI is a useful modality for prognostication.[33] For assessment of the extent of SCI, both transverse and longitudinal extent are required. A score system has been developed by Brain and Spine Injury Center (BASIC Score) to assess the extent of spinal injury and that can help to predict the neurological status at discharge.

Intervertebral Disk Injury

Intervertebral disk injury is seen as widening or asymmetric narrowing of disk space, relative hyperintensity of one disk on T2WI, frank protrusion of disk material into the epidural space, and dorsal displacement of PLL and epidural venous plexus **(Figs. 18A and B)**.

Disk herniations are commonly seen in association with vertebral fracture dislocation and hyperextension injuries. These are caused due to injury to the annulus fibrosus with resultant herniation of the nucleus pulposus. It is important to identify the disk herniation as undetected herniation can later cause new/worsening cord injury which can result in progressive neurological deficits. Radiologically, however, it is difficult to differentiate a traumatic versus nontraumatic disc herniation as appearance is the same. The presence of other post-traumatic lesions at the same level can help in differentiating the two entities.

Ligamentous Injury

Spinal ligaments are very essential to maintain the normal vertebral alignment and integrity. Presence of ligamentous injury can convert a stable single-column fracture into an unstable two-column fracture. Recently, the TLICS and SLICS classification systems have also taken into account the status of the posterior ligamentous complex.

JAYPEE BROTHERS

Normal ligament of the spine shows low signal intensity in all the sequences. The ligamentous injury can be partial or complete and depends on the mechanism of injury. The partial tear/sprain is the more common variety.

Partial tears are visualized as areas of abnormally high signal areas on T2/STIR images which occur due to associated edema/hemorrhage. Complete tears are seen as complete lack of continuity of fibers associated with increased signal on T2/FLAIR. Hyperextension injuries result in damage to the anterior column ligaments with or without involvement of the ligaments of posterior column depending on the severity of the injury. Conversely, injury to the posterior column ligaments occurs on hyperflexion injuries.[23]

Anterior longitudinal ligament and PLL injuries are seen as focal disruption of the hypointense signal on all the sequences **(Figs. 19A and B)** with associated soft-tissue edema best seen on STIR. Injury to the ligamentum flavum is best seen in the parasagittal image and is usually associated with posterior element fractures. Injuries to the supraspinous/interspinous ligaments are seen as increased signal in the interspinous space and tip of the spinous process, especially on STIR sequence.

Epidural and Subdural Hemorrhage

It is a common finding in a trauma patient, and symptoms depend on the location as well as the severity of compression of the spinal cord. Surgical evaluation is necessary for a favorable outcome. In some scenarios, it becomes difficult to exactly localize the compartment of hemorrhage to epidural or subdural space. "Curtain sign" may help in differentiating the two if the hematoma is localized anteriorly in the spinal cord. Normally, the dura is attached to the PLL by the Trolard ligament. Thus, the epidural hemorrhage may lift the dura except anteriorly in midline. Accordingly, a subdural hemorrhage will show a negative curtain sign.[25]

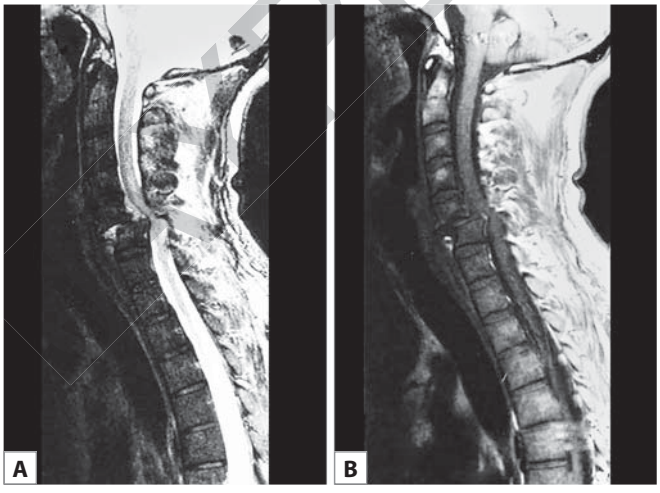

FIGS. 19A AND B: Sagittal T2- and T1WI showing fracture dislocation of C5–C6 with discontinuity in the ligaments (ALL and PLL).

(ALL: anterior longitudinal ligament; PLL: posterior longitudinal ligament)

Nerve Root Avulsion

Nerve root avulsion is usually seen in cervicothoracic location due to a higher degree of mobility of the cervical spine. Complete avulsion of the nerve root can result in pseudomeningocele formation which is pathological collection of cerebrospinal fluid (CSF). These collections that are in communication with the physiological CSF space, however, are not covered by dura. These injuries can be easily seen on high-resolution T2W sequence, e.g., constructive interference in steady state (CISS) or fast imaging employing steady-state acquisition (FIESTA).

Vascular Injury

The incidence of the vascular injury in blunt trauma patients is <1%.[2] Vascular injuries should be looked for in patients with otherwise unexplained neurologic deficits and in patients with severe blunt trauma to the neck.[2] Vertebral arteries are more commonly involved as compared to carotid arteries in patients with neck trauma. There is a risk of cerebral and cerebellar infarctions, especially when the injury is bilateral. The risk factors for vascular injury according to the Denver screening criteria in patients with neck injury are as follows:

- C1 to C3 fracture
- Fracture extending into foramen transversarium
- Cervical spine subluxation
- Facial fractures Le Fort II and III
- Base of the skull fracture involving the carotid canal
- Expanding neck hematoma
- Diffuse axonal injury

Digital subtraction angiography (DSA) is the gold standard investigation, but it carries a minor risk of stroke itself (risk of ~0.5%). CT angiography (CTA) is a fast, high-resolution technique and is a preferred investigation for detecting vascular injury. A recent clinical review revealed sensitivity of CTA in detecting VAI to be around 99%.[23]

Magnetic resonance angiography (MRA) is also proven to be a valid technique for detecting vascular injury. Most of the vascular injuries can be seen as loss of flow void on spin-echo sequences associated with wall irregularity. In addition, intramural hematoma can be seen as T1 hyperintense periarterial rim with flow void in the patent lumen. This T1 hyperintensity is imparted by the T1 shortening effect of methemoglobin. In equivocal cases, further evaluation can be done by CTA/DSA. However, in the context of polytrauma patients, MRA can be unsuitable due to long scan time as well as safety challenges within the scanning environment.

PEE BROTHERS

SUBACUTE AND CHRONIC INJURIES

In the subacute phase following SCI, MRI often reveals hyperintense signal on T2WI in the white matter tracts above (dorsal columns) and below (lateral columns) the injury level. This Wallerian degeneration is first noticeable on MRI approximately 1 month after trauma. Approximately 1–3 weeks following cord injury, a subacute progressive ascending myelopathy occasionally can be seen, presenting as an enlarged cord with high signal on T2WI, several segments superior to the original injury site.

Late sequelae of SCI include progressive enlargement of an intramedullary or extramedullary cyst, progressive myelomalacia, tethering and adhesions, and/or cord atrophy.

Post-traumatic syringomyelia: It develops after severe SCI and is fusiform intramedullary cystic cavitation with an incidence of 3.5–4.3%. Contrary to hydromyelia which is pathologic dilatation of the central canal, it is not lined by ependyma. The pathogenesis of post-traumatic syringomyelia is multifactorial, and symptoms depend on the location and extent. Arachnopathic scarring plays an important role in its development. Due to altered CSF flow, the lesion may ascend later, even years after the initial insult, and can lead to worsening of the neurological status. High-resolution T2-weighted images (like CISS) have a role to assess the arachnoid adhesions which facilitate in planning surgical procedures. The disturbance of CSF circulation can also be detected using modern sequences like ECG-gated phase-contrast imaging which can detect and quantify the altered dynamics of CSF flow.[32]

SCIWORA

Spinal cord injury without radiographic abnormality (SCIWORA) is defined as "clinical symptoms of traumatic myelopathy with no radiographic or CT features of spinal fracture or instability.[32] Almost 6–19% of spinal injuries in children comprise SCIWORA compared to 9–14% in adults.[32] SCIWORA is most common in children < 8 years of age, probably due to greater head size, weaker neck muscles, and higher elasticity of vertebral ligaments. In addition, the facet joints are more horizontally oriented which in turn increase the susceptibility to injury. The specific biomechanics of the vertebral column allows for a greater physiological range of motion of the spine without association with fracture. During the excessive motion of the spine, there is temporary occlusion of the vertebral artery which leads to ischemic injury to the cord.

In adults, SCIWORA mostly occurs as a result of hyperextension forces (e.g., rear-end car accident). It is commonly associated with underlying degenerative changes, and the level of injury to the cord corresponds to the location of these degenerative changes. Venous congestion in the compressed cord is also believed to be an additional factor.

The most typical presentation of SCIWORA is upper extremity weakness which is more severe than the lower extremity weakness. MRI is the investigation of choice of spinal cord. Edema **(Figs. 20A to C)** and hemorrhages can be seen using T2 and GRE sequences. The appearance of the hemorrhage on MR will depend on the age of bleed. Bone marrow edema can also be assessed on STIR sequence that cannot be seen on CT. A number of patients, however, have normal MRI of the spinal cord but have neurological symptoms. Such patients should be classified as SCIWNA.[32] In this subset of patients, advanced imaging like DWI and DTI can provide vital information. Szwedowski et al. have shown that patients with SCIWNA revealed hyperintense signal on DWI in the areas corresponding to cord injury. In addition, DTI can assess the white matter integrity in spinal cord. However, the quality of images may be degraded by artifacts due to

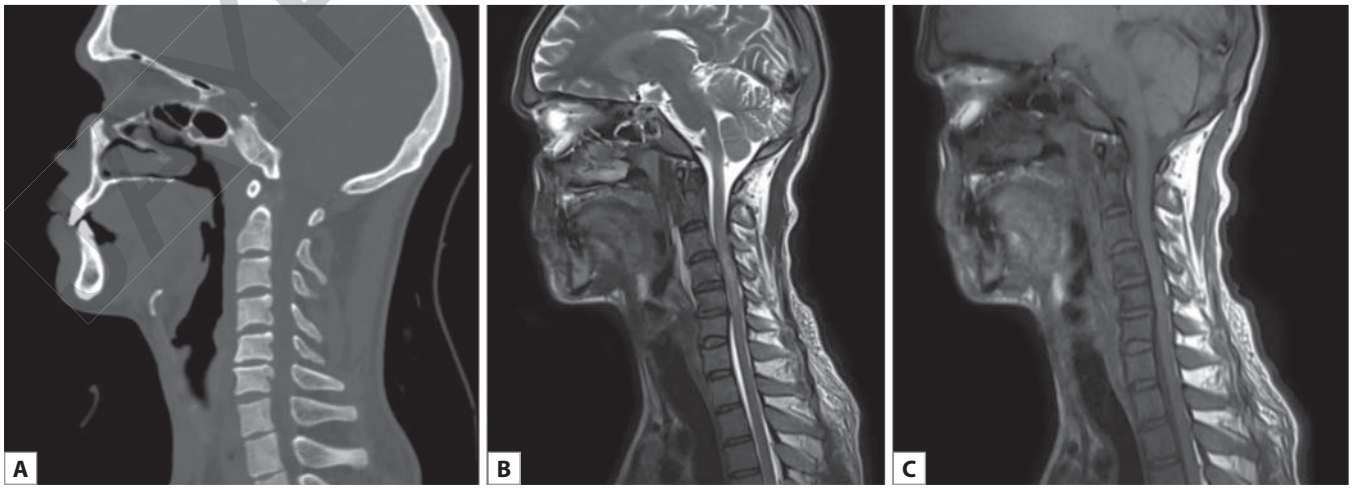

FIGS. 20A TO C: NCCT cervical spine sagittal reformat (A), sagittal T2 (B), and T1WI (C) demonstrate abnormal cord signal on T2WI suggesting cord edema; however, there is no evidence of bony injury.

JAYPEE BROTHERS

breathing or pulsatile motion of CSF. In a study conducted in the institute comprising 40 patients, SCIWORA contributed to 12% of cases of SCI.[34]

Whiplash Injury

The term "whiplash" refers to a wide variety of soft-tissue neck injuries resulting from multiple causes.[2] Commonly, the injury follows a forced hyperextension–hyperflexion of the spine. It can result from rear-end vehicle collision and side- or front-impact collisions. The injury has a wide variety of nonspecific clinical presentations. Common symptoms include neck pain or stiffness, paresthesia, upper extremity pain, jaw pain, and headache. Plausible causes are muscle tears, ligamentous injuries, perineural scarring, discogenic and joint disease, and fractures. Plain radiograph may show abnormal soft tissue or vertebral alignment. CT helps to exclude the presence of fractures or dislocations. MRI is helpful in demonstrating the lesion of the ligaments, disks, spinal cord, prevertebral soft tissue, and muscles.

OSSEOUS VARIANTS THAT MAY SIMULATE INJURY[35]

Variants of the Atlas (C1)

- *Atlantal clefts*: Most commonly, they occur at posterior synchondrosis; however, they can be seen anywhere within the C1 ring. They occur due to nonfusion of the ossification center. These clefts show a smooth corticated margin differentiating it from fracture. An anterior midline cleft can be formed due to failure of anterior ossification center to form or a bipartite anterior ossification center.
- A normal *groove* is seen along the posterolateral aspect of atlas on both the sides which transmits the vertebral artery and suboccipital nerve (C1). These structures are normally covered by the posterior atlanto-occipital membrane. Occasionally, this membrane can become partially calcified and give an appearance of an apparent bony fragment. On complete ossification, an osseous ring is formed which is known as arcuate foramen.

Variants of the Axis (C2)

Ossific densities cranial to odontoid process: Persistent os terminale, os odontoideum

- *Persistent os terminale*: It is a normal secondary ossification center that fuses to the odontoid process by 12 years of age. However, there can be nonfusion and is seen as a well-corticated ossicle abutting the odontoid tip.
- *Os odontoideum*: It can be mistaken for dens fracture. It has a sclerotic and well-corticated margin. It is also associated with hypertrophy of the anterior arch of C1. An os odontoideum also has a larger gap between the os and the odontoid process. It usually does not exhibit the expected contour of the upper odontoid process.

Anterior Subluxation of C2 on C3

It is usually seen in children < 8 years of age. It is caused due to ligamentous laxity and a horizontal orientation of the facet joint.

Variants of C3 through L5 Vertebrae

- *Anterior wedging of cervical vertebra*: It is a normal finding in young population and is most prominent at the C3 level. A difference in height of up to 3 mm between the anterior and middle aspects of the vertebral body is considered normal. It should not be confused with compressed fracture.
- *Single linear osseous defect through foramen transversarium*: It likely represents a developmental cleft. A fracture involving the transverse foramen or any ringlike structure will likely involve two or more locations and are usually displaced fractures. An isolated defect of the transverse foramen is unlikely to be a fracture.
- *Limbus vertebra*: It is due to herniation of disk material between the ring apophysis and the vertebral body. It most commonly occurs in the lumbar spine in the anterosuperior aspect and is seen as a small triangular bony fragment with a smooth corticated margin.
- *Clefts* may occur at several locations due to nonfusion of synchondrosis. It may involve pars interarticularis, pedicle, lamina, etc.

ARTIFICIAL INTELLIGENCE IN SPINAL TRAUMA[36,37]

Over the years, AI applications have significantly evolved in all sections of radiology, including spine imaging. Many AI algorithms have developed in spine imaging based on radiographs, CT, and MRI for detection and characterization of spinal pathologies. AI has enabled detection and classification of spine trauma, documentation of osseous lesions, and assessing spinal cord abnormalities. There are many applications which are evolving as a useful tool for evaluation of spinal trauma patients like automated detection of fractures by AI and triaging the patients for imaging in emergency (like Aidoc AI). Software like Subtle MR can do imaging enhancement which is useful for reducing the motion artifacts in the acquired images.

JAYPEE BROTHERS

CONCLUSION

Imaging in acute spinal trauma plays a pivotal role for the diagnosis and treatment of patients by delineating the extent, classification, and severity of the osseous and ligamentous injury. There is a significant change in imaging spinal trauma over the recent years with advancement in CT (MDCT) and MRI technology. When the clinical suspicion of spinal injury is high, MDCT is performed, as it is faster and more accurate and needs less patient mobilization than radiography. MDCT is an excellent modality in detecting the osseous abnormalities (especially posterior element fractures), spinal alignment, and assessment of stability. Early and accurate diagnosis of spinal injury is crucial in better patient management and prevention of neurological deterioration. However, plain radiography remains usually the initial screening modality as it is readily available, portable, and inexpensive. MRI is the best imaging modality for detection of spinal cord changes (edema and hemorrhage), extradural lesions (disk herniation and epidural hematoma), ligamentous injury, and characterizing spinal fractures.

ACKNOWLEDGMENT

The authors acknowledge Dr Alaipreet, DM Resident in the Neuroradiology Division of Department of Radiodiagnosis, PGIMER, Chandigarh, for her support in editing of the chapter.

REFERENCES

1. Kaji A, Hockberger R. Imaging of spinal cord injuries. Emerg Med Clin North Am. 2007; 25:735-50,ix.
2. Bagley LJ. Imaging of spinal trauma. Radiol Clin North Am. 2006; 44:1-12.
3. Lali HS, Fehlings MG. Epidemiology, demographics and pathophysiology of acute spinal cord injury. Spine. 2001; 26:2-12.
4. Tins B, Cassar-Pullicino V. Controversies in "clearing" trauma to the cervical spine. Semin Ultrasound CT MR. 2007;28: 94-100.
5. Wolf M, Weber MA. Neuroimaging of the Traumatic Spine. Magn Reson Imaging Clin N Am. 2016; 24(3):541-61.
6. Shah LM, Ross JS. Imaging of spine trauma. Neurosurgery. 2016;79(5):626-42.
7. Pathria MN, Petersirge CA. Spinal trauma. Radiol Clin North Am. 1991;29:847-65.
8. Heinemann U, Freund M. Diagnostic strategies in spinal trauma. Eur J Radiol. 2006;58:76-88.
9. Dalinka MK, Boorstein JM, Zlatkin MB. Computed tomography of musculoskeletal trauma. Radiol Clin North Am. 1989;27:933-43.
10. Kaye JJ, Nance EP. Thoracic and lumbar spine trauma. Radiol Clin North Am. 1990;28:361-77.
11. Abel MS. The exaggerated supine oblique view of the cervical spine. Skeletal Radiol. 1982;8:213-9.
12. Gamanagatti S, Rathinam D, Rangarajan K, Kumar A, Farooque K, Sharma V. Imaging evaluation of traumatic thoracolumbar spine injuries: Radiological review. World J Radiol. 2015;7(9):253-65.
13. Murphey MD, Batnitzky S, Bramble JM. Diagnostic imaging of spinal trauma. Radiol Clin North Am. 1989;27:855-72.
14. Rabassa AE, Guinto FC, Crow WN, Chaljub G, Wright GD, Storey GS. CT of the spine: Value of reformatted images. Am J Roentgenol. 1993;161:1223-7.
15. Gonzalez-Beicos A, Nunez DB. Role of multidetector computed tomography in the assessment of cervical spine trauma. Semin Ultrasound CT MR. 2009;30:159-67.
16. Bensch FV, Koivikko MP, Kiuru MJ, Koskinen SK. Measurement of spinal canal narrowing, interpedicular widening, and vertebral compression in spinal burst fractures: Plain radiographs versus multidetector computed tomography. Skeletal Radiol. 2009;38:887-93.
17. Blackmore CC, Mann FA, Wilson AJ. Helical CT in primary trauma evaluation of the cervical spine: An evidence-based approach. Skeletal Radiol. 2000;29:632-9.
18. Siberstein M, Tress BM, Hennessy O. A comparison between MRI and CT in acute spinal trauma. Australas Radiol. 1992;36:192-7.
19. Provenzale J. MR imaging of spinal trauma. Emerg Radiol. 2007;13:289-97.
20. Demaerel P. Magnetic resonance imaging of spinal cord trauma: A pictorial essay. Neuroradiology. 2006;48:223-32.
21. Mhuircheartaigh NN, Kerr JM, Murray JG. MR imaging of traumatic spinal injuries. Semin Musculoskelet Radiol. 2006;10:293-307.
22. Geck MJ, Yoo S, Wang JC. Assessment of cervical ligamentous injury in trauma patients using MRI. J Spinal Disord. 2001;14:371-7.
23. Kumar Y, Hayashi D. Role of magnetic resonance imaging in acute spinal trauma: a pictorial review. BMC Musculoskelet Disord. 2016;17:310.
24. Hoch MJ, Rispoli J, Bruno M, Wauchope M, Lui YW, Shepherd TM. Clinical utility for diffusion MRI sequence in emergency and inpatient spine protocols. Clin Imaging. 2017;45:37-50.
25. Endo T, Suzuki S, Inoue T, Utsunomiya A, Uenohara H, Tominaga T. Prediction of neurological recovery in spontaneous spinal epidural hematoma using apparent diffusion coefficient values. Spinal Cord. 2014;52(10):729-33.
26. Shanmuganathan K, Gullapalli RP, Zhuo J, Mirvis SE. Diffusion tensor MR imaging in cervical spine trauma. Am J Neuroradiol. 2008;29(4):655-9.
27. Dennis F. The three column spine and its significance in the classification of acute thoracolumbar spinal injuries. Spine. 1983;8:817-31.

JAYPEE BROTHERS

28. Divi SN, Schroeder GD, Oner FC, Kandziora F, Schnake KJ, Dvorak MF, et al. AO Spine-Spine Trauma Classification System: The Value of Modifiers: A Narrative Review With Commentary on Evolving Descriptive Principles. Global Spine J. 2019;9(1 Suppl):77S-88S.
29. Jelly LM, Evans DR, Easty MJ, Coats TJ, Chan O. Radiography vs spinal CT in the evaluation of cervicothoracic junction injuries in polytrauma patients who have undergone intubations. Radiographics. 2000;20:251-9.
30. Tewari MK, Gifti DS, Singh P, Khosla VK, Mathuriya SN, Gupta SK, et al. Diagnosis and prognostication of adult spinal cord injury without radiographic abnormality using magnetic resonance imaging: Analysis of 40 patients. Surg Neurol. 2005;63:204-9.
31. Babalola TI, Yusuf SA, Raji M, Kamaldeen JO, Dolapo D. Value of the Brain and Spinal Injury Center Score in Assessment and Prognosis of Acute Traumatic Spinal Cord Injury. Neurotrauma Rep. 2024;5(1):592-605.
32. Van Goethem JW, Maes M, Ozsarlak O, van den Hauwe L, Parizel PM. Imaging spinal trauma. Eur Radiol. 2005;15:582-90.
33. Sundgren PC, Philipp M, Maly PV. Spinal trauma. Neuroimaging Clin N Am. 2007;17:73-85.
34. Szwedowski D, Walecki J. Spinal Cord Injury without Radiographic Abnormality (SCIWORA) - Clinical and Radiological Aspects. Pol J Radiol. 2014;79:461-4.
35. Carr RB, Fink KR, Gross JA. Imaging of trauma: Part 1, Pseudotrauma of the spine—osseous variants that may simulate injury. AJR Am J Roentgenol. 2012;199(6):1200-6.
36. Martín-Noguerol T, Oñate Miranda M, Amrhein TJ, Paulano-Godino F, Xiberta P, Vilanova JC, et al. The role of Artificial intelligence in the assessment of the spine and spinal cord. Eur J Radiol. 2023;161:110726.
37. Gill SS, Ponniah HS, Giersztein S, Anantharaj RM, Namireddy SR, Killilea J, et al. The diagnostic and prognostic capability of artificial intelligence in spinal cord injury: A systematic review. Brain Spine. 2025;5:104208.

JAYPEE BROTHERS

for detailed information on radiology books, visit our website www.ejaypee.com, for detailed information on radiology books, visit our website www.ejaypee.com, for detailed information



AIIMS-MAMC-PGI IMAGING SERIES

DIAGNOSTIC RADIOLOGY

Neuroradiology Including Head and Neck Imaging

In 1996, a unique venture was jointly initiated by the faculty of Radiodiagnosis and Imaging at AIIMS, MAMC, and PGIMER to organize continuing medical education (CME) program based on a series of imaging courses. An integral part of this endeavor was publishing books covering all organ systems. The aim was to provide updated state-of-the-art knowledge to postgraduates and practicing radiologists along with establishing a uniform pattern of teaching in radiology across the country. The first series of seven courses was successfully completed in the year 2000. The overwhelming response to the teaching courses as well as the accompanying textbooks paved the way for three more series of courses over the next 20 years.

These courses have seen a steady rise in popularity among the radiology residents. This is reflected in the enthusiasm and continued maintenance of this format of teaching even after almost three decades of its inception. The favorable response has prompted the team to device the latest series, which is the ongoing fifth in succession, with fresh energy and vigor. The current course is dedicated to the imaging of brain and spine along with head and neck imaging. The various chapters are drafted and compiled by experts in the respective fields of neuro and head and neck radiology who have curated the most relevant topics in the current scenario. Artificial Intelligence and radiomics have transformed the field of medicine and radiology in recent years and it is pertinent to add these in the current sections. Functional neuroimaging and interventional neuroradiology continue to evolve with newer modalities and therapies coming into vogue. The current book has taken this into account and it has been exhaustively written and extensively revised keeping in mind the vast majority of readers including residents, practicing radiologists, and other neuroscience professionals that this book caters to.

We hope that this book will be a valued addition to the learning libraries of residents, medical colleges, private practitioners, and medical faculty all across India and the world.



Paramjeet Singh
PGI, Chandigarh



Raju Sharma
AIIMS, New Delhi



Gaurav Shanker Pradhan
MAMC, New Delhi

Buy from ejaypee

JAYPEE BROTHERS

Shelving Recommendation
RADIOLOGY

ISBN 978-93-7202-840-9