hopedics books, visit our website www.ejaypee.com,for detailed information on orthopedics books, visit our website www.ejaypee.com, for detailed information on orthopedics books

3

Master Series Monographs

Elbow Fractures in Children



Editor-in-Chief
Gautam Zaveri

Section Editors
Taral Nagda
Binoti Sheth

JAYPEE

Contents

Note from the Editor-in-Chief xi

Note from the Section Editors xiii

Contributors xv

1. **ABC of the Pediatric Elbow** 1
   Chasanal Rathod, Ashish S Ranade

2. **Radiology of the Pediatric Elbow** 11
   Tushar Agrawal, Swapnil Keny, Deepak Jain

3. **Typical Supracondylar Humerus Fractures** 21
   Sandeep Vaidya, Mudit Shah

4. **Atypical Supracondylar Humerus Fractures** 35
   Chintan Doshi, Sandeep Patwardhan

5. **Supracondylar Humerus Fractures with Neurovascular Injury** 49
   K Venkatadass, Mandar Agashe

6. **Management of Complications and Delayed Presentation of Supracondylar Humerus Fractures** 59
   Darshan M Kapoor, Premal Naik, Gautam Zaveri

7. **Lateral Condyle Humerus Fractures** 71
   Gauri Patki, Alaric Aroojis

8. **Complications of Lateral Condyle Humerus Fractures** 81
   Sameer Desai, Taral Nagda

9. **Medial Epicondyle Fractures** 91
   Shalin Shah, Maulin Shah

10. **Radial Head and Neck Fractures** 99
    Bhushan Sagade, Rujuta Mehta

11. **Monteggia Fracture-dislocations** 113
    Atul Bhaskar, Khyati Gupta

12. TRASH Lesions of the Elbow **125**
Sukalyan Dey, Rajul Gupta, Kevin J Little, Shital N Parikh

13. Short Notes: Complete Physeal Separation, Radial Head Fractures, Medial Condyle Fractures and Olecranon Fractures **137**
Avi Shah, Jaideep Dhamele, Yogendra Singh Shekhawat, Taral Nagda

Index **151**

4 Atypical Supracondylar Humerus Fractures

Chintan Doshi, Sandeep Patwardhan



Introduction

Fractures with a horizontal fracture line running across the olecranon fossa where displacement of the distal fragment is posterior into extension, are labeled as "Typical" fractures of the supracondylar humerus. The typical fracture type is, by far, the most commonly (97%) seen pattern of injury among SCHFs in children.[1,2] Depending on the mode of injury, a number of other relatively less common fracture patterns have been identified, which are labeled "atypical" fractures.[3] Since atypical injuries are less common, limited literature is available regarding long-term outcomes and hence their management remains uncertainties. The methods of reduction and fixation technique are different from those of typical fractures. The current chapter aims to discuss the peculiarities of these atypical fractures and outline their management.

Typical Supracondylar Fracture

A fall on an outstretched hand produces an extension moment at the distal humerus, resulting in a transverse fracture at the level of the supracondylar ridge, just above the olecranon fossa **(Fig 1)**. The distal fracture fragment is angulated or displaced posteriorly into extension. Extension-type supracondylar fractures are reduced by flexing the elbow and then fixed using 2 or 3 lateral pins in parallel or

JAYPEE BROTHERS

divergent pattern, or occasionally in cross-pin configuration.

Atypical Supracondylar Fractures

Supracondylar injuries with fracture morphology different from that of the typical extension type, in terms of fracture pattern, direction of angulation or displacement are labeled "atypical". The fractures require distinct reduction techniques, and the positioning of K-wires for optimum stabilization also differs. The long-term outcomes too may be significantly different from those of the extension-type fracture.

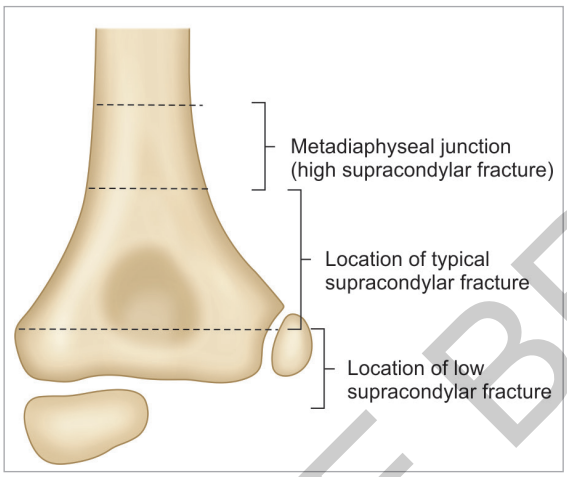

Fig 1: Location of typical supracondylar fracture on anatomical line diagram of distal humerus.

Gartland and modified Gartland classifications do not describe fracture patterns with obliquity in the sagittal or coronal plane.[4,5] Bahk et al, emphasized that compared to fractures with coronal obliquity of < 10°, fractures with coronal obliquity of ≥ 10° were associated with significantly more comminution and rotational malunion.[6] Similarly, compared to fractures with sagittal obliquity of < 20°, fractures with sagittal obliquity of ≥ 20° were associated with a significantly higher incidence of additional injuries and were more likely to result in extension malunion. They identified four coronal and two sagittal subtypes of supracondylar fractures that had different injury characteristics entailing specific treatment considerations **(Figs 2A to F)**. The coronal subtypes included typical transverse (49%), lateral oblique (44%), medial oblique (4%), and high transverse fractures (3%) while the sagittal subtypes included low sagittal and high sagittal fractures. Apart from this classification, a number of atypical presentations of supracondylar fracture exist, some of which are discussed in the ensuing paragraphs.

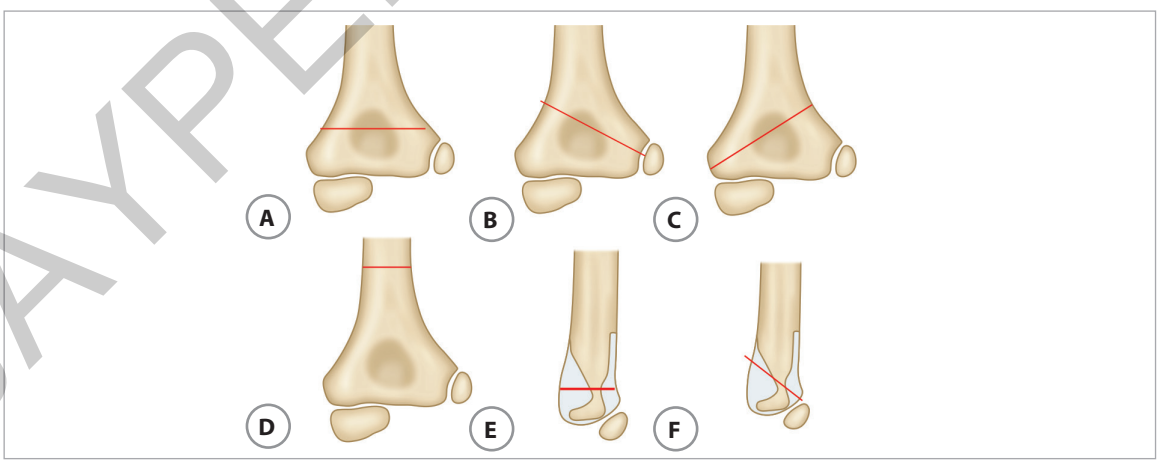

Figs 2A to F: Line diagram showing Bahk's classification of supracondylar fractures of humerus: (A) Typical coronal fracture; (B) Lateral oblique fracture (> 10° of coronal obliquity); (C) Medial oblique fracture (> 10° of medial obliquity); (D) High supracondylar fracture; (E) Low sagittal pattern; and (F) High oblique sagittal pattern.

JAYPEE BROTHERS

Medial Oblique Supracondylar Fracture

Bahk et al, described a supracondylar fracture with an oblique fracture line in the coronal plane which starts at the lateral epicondyle and exits on the medial supracondylar ridge proximally, resulting in a fracture where the medial humeral condyle forms a significant part of the distal fragment **(Fig 3A)**.[6] Sometimes there may be severe comminution over the medial supracondylar ridge making it more prone to collapse into varus. The distal fragment may be angulated in flexion or extension. Since the medial condyle is a large part of the fragment, a medial pin is invariably required to attain stability post fixation. A cross-pin configuration would achieve maximum stability **(Figs 3B and C)**. A commonly reported iatrogenic complication with medial pin insertion is ulnar nerve injury. To avoid this, a small incision can be placed over medial elbow and with elbow kept in relative extension ulnar nerve is identified and retracted. A drill guide can be placed directly on bone and drill can be walked directly over bone and used in an oscillating mode.

High Supracondylar Fracture

A rotational strain coupled with an axially transmitted impact force may result in a rare fracture pattern, where the fracture line is above the supracondylar ridge at the metaphysio-diaphyseal junction **(Figs 4A and B)**.[7,8] These fractures are usually seen in adolescents. High supracondylar fractures are very unstable and require a different technique to stabilize the fracture. Fixation usually requires a cross-pin configuration with K-wires inserted into the intramedullary canal up to the proximal half of humerus so as to confer adequate stability **(Figs 5A to C)**.[9] Some studies

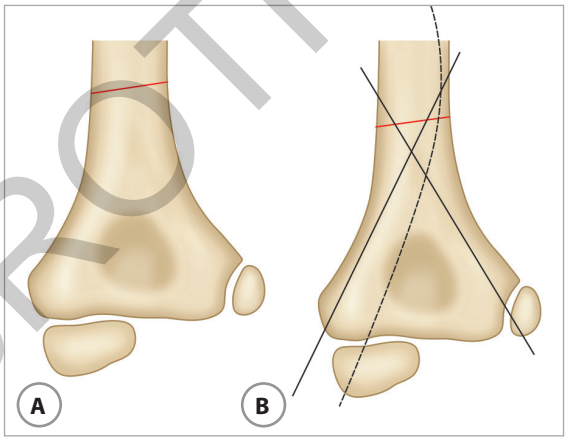

Figs 4A and B: Line diagram showing: (A) Location of fracture in high supracondylar fractures; and (B) Use of cross pin configuration with an an intramedullary pin (dotted line trajectory) required for fixation and stability of fracture.

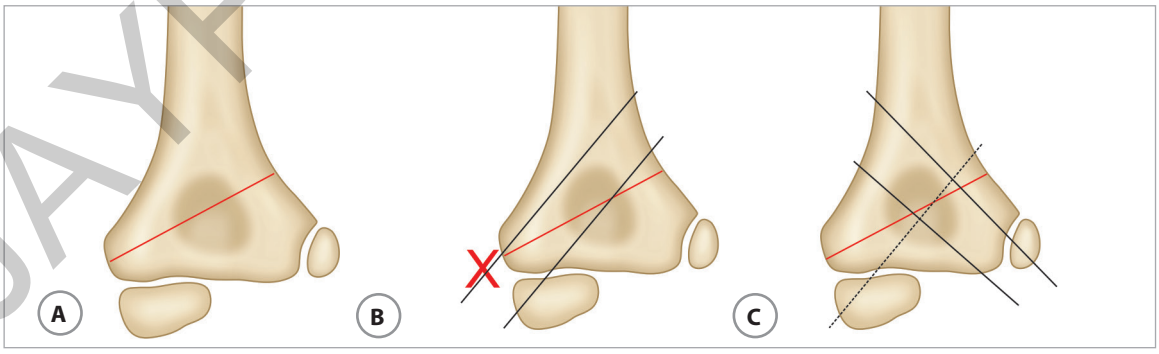

Figs 3A to C: (A) Fracture morphology in medial oblique fracture; (B) Position of standard 2 lateral pin configuration not suitable for fixation and stability; and (C) Use of parallel medial pins or cross-pin configuration is necessary for fixation and stability.

JAYPEE BROTHERS

have also reported an anterograde elastic intramedullary nailing technique in treating high supracondylar fractures of the distal humerus **(Figs 6A to C)**.[10,11]

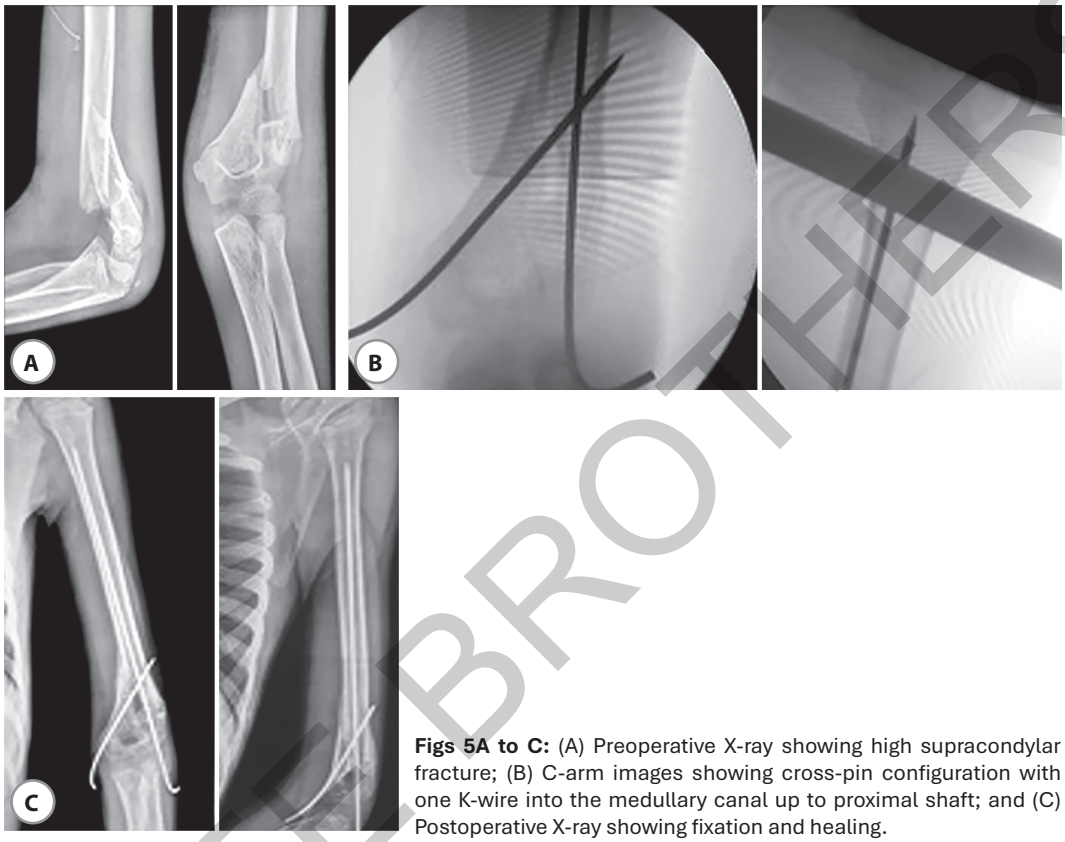

Figs 5A to C: (A) Preoperative X-ray showing high supracondylar fracture; (B) C-arm images showing cross-pin configuration with one K-wire into the medullary canal up to proximal shaft; and (C) Postoperative X-ray showing fixation and healing.

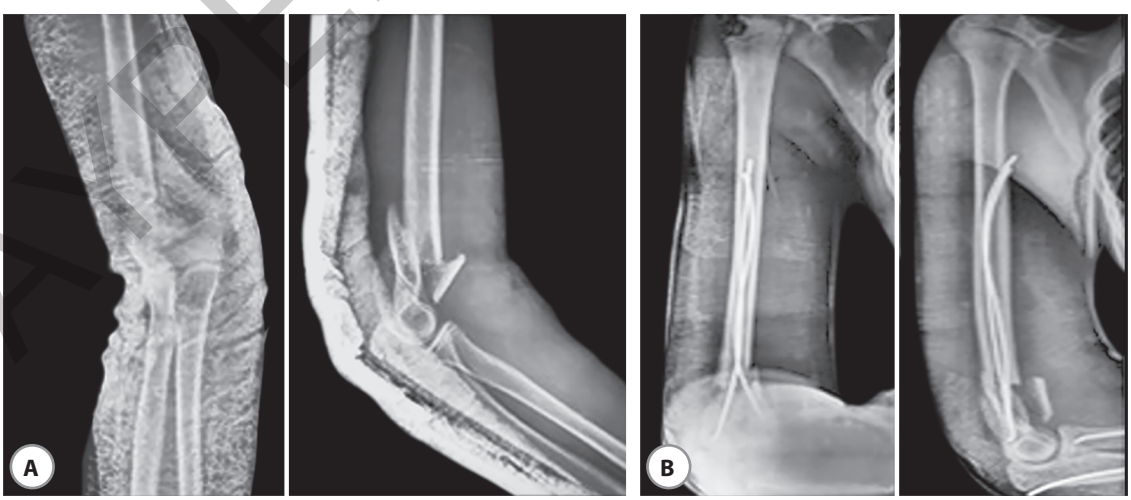

Figs 6A to C: *Continued*

JAYPEE BROTHERS

Continued



Figs 6A to C: (A) Preoperative X-ray showing a comminuted high supracondylar fracture; (B) Postoperative X-ray showing anterograde elastic nailing done; and (C) Follow-up X-ray showing healing of fracture.

Low Supracondylar Fractures and Transphyseal Separation

The fracture line lies below the olecranon fossa and there is a very thin flake of metaphyseal bone in the distal fragment **(Fig 7)**. Low supracondylar fractures are more commonly flexion-type fractures. As there is not enough bone distally to accommodate two lateral wires, low supracondylar fractures are fixed using a cross-pin configuration to achieve stability **(Figs 8A and B)**.

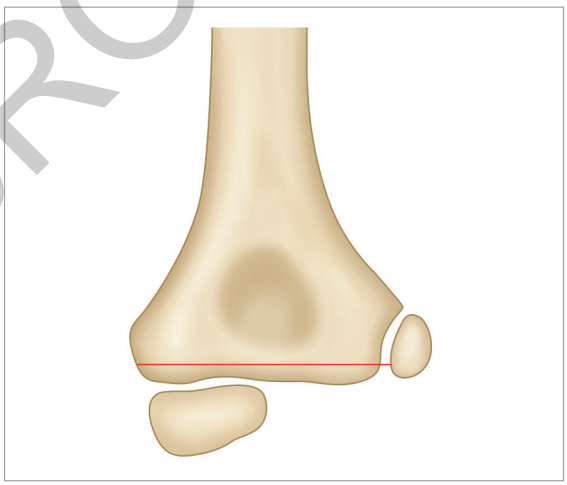

Fig 7: Line diagram showing location of low supracondylar fracture.

The distal metaphysis of the humerus is supplied by a solitary nutrient artery which ends roughly 3–4 cm above the olecranon fossa. The areas distal to this point are considered watershed areas.[12] Hence the probability of avascular necrosis of trochlea is higher in low supracondylar fractures.[13] Serial radiographs have to be obtained to monitor for avascular necrosis of the trochlea, which appears radiographically radiographically as a "fishtail deformity".[14]

Transphyseal separations occur most commonly before 3 years of age due to accidental, nonaccidental, or birth trauma. At this age, the cartilaginous epiphyseal component is large and ossification has not yet occurred, making the physeal area weak and most vulnerable to separate. The diagnosis of transphyseal separations is often very difficult. The fracture line is not visible, but the long axes of ulna and humerus do not align. Sometimes a thin flake of bone is seen separately from the distal metaphysis which would indicate the fracture.[15] Arthrogram or magnetic resonance imaging (MRI) is usually required to visualize the fracture

JAYPEE BROTHERS

line and pattern. Arthrogram is also very useful intraoperatively to identify the fracture and adequately fix it **(Figs 9A to C)**.

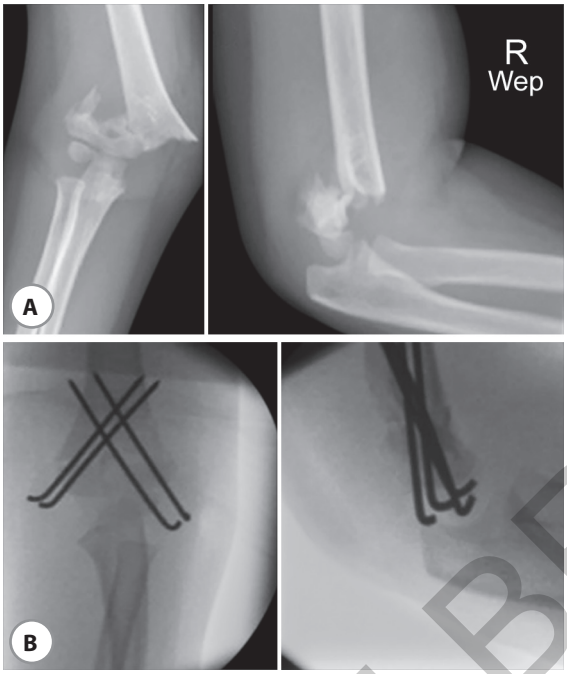

Figs 8A and B: (A) Preoperative X-ray of low supracondylar fracture and (B) intraoperative image of fixation.

Sagittal Oblique Pattern

Bahk et al, described a unique fracture pattern where in the fracture line is > 20° oblique to the vertical in the sagittal plane on a lateral radiograph.[6] In these fractures, the reduction maneuver is as per the extension or flexion-type injury. Fixation involves passing K-wires perpendicular to the fracture line. The direction of the wires will depend on the direction of the fracture line **(Figs 10 and 11)**.

Flexion-type Supracondylar Fracture

A direct blow to the flexed elbow or a fall on the point of the elbow produces a hyperflexion moment that results in an atypical supracondylar fracture (1–3% of all supracondylar fractures) where the distal fragment is anteriorly flexed or displaced **(Figs 12A to C)**.[16] Flexion supracondylar fractures may be associated with penetration of the medial intermuscular septum, a higher chance of ulnar nerve injury, and higher rate of irreducibility. Undisplaced type 1 fractures are treated with immobilization in a cast. Minimally displaced type 2 fractures and

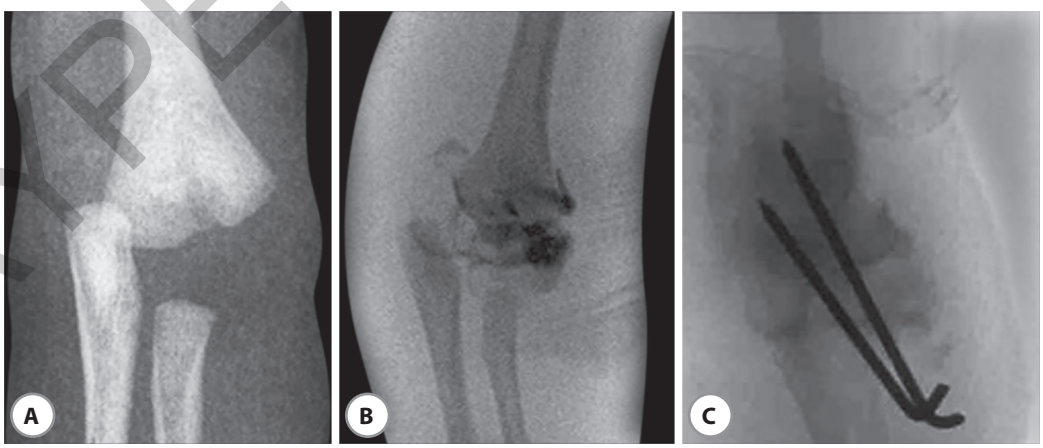

Figs 9A to C: (A) Presenting X-ray in a 2-year-old child; (B) Arthrogram delineating transphyseal separation; and (C) Fixation of the fracture with two lateral K-wires.

JAYPEE BROTHERS

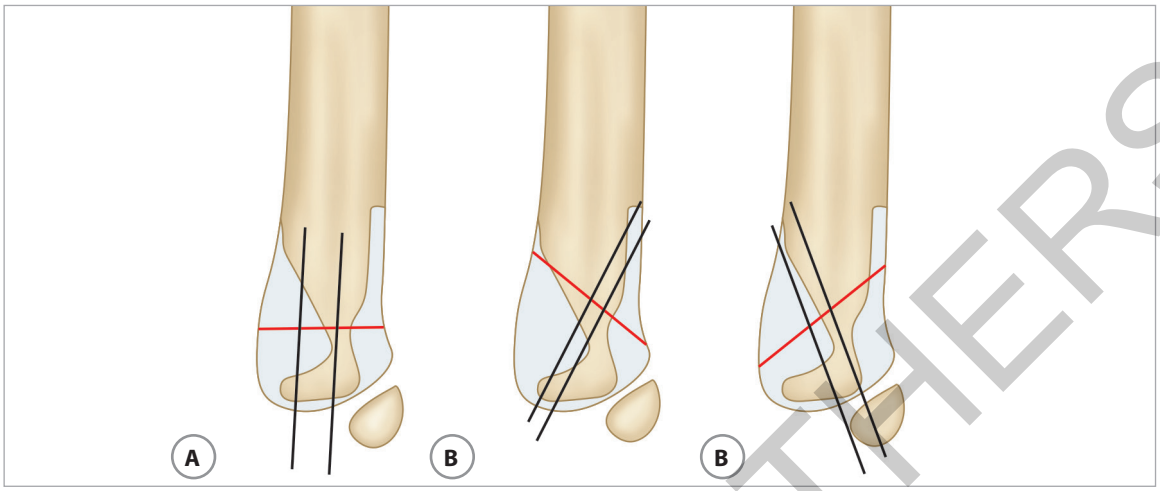

Figs 10A to C: Line diagram showing sagittal fracture subtypes: (A) Sagittal transverse fracture: K-wires (indicated by black lines) placed vertically, perpendicular to fracture line (indicated by red line); (B) High sagittal oblique fracture: K-wires placed obliquely from posterior to anterior; and (C) High sagittal oblique fracture: K-wires placed obliquely from anterior to posterior.



Fig 11: X-ray of a high sagittal fracture with intended direction of K-wires marked by a black line.

the more significantly displaced, highly unstable type 3 fractures are best treated with close or open reduction and fixation with percutaneous K-wires. Type 3 fractures are highly unstable and difficult to reduce through closed methods.

De Boeck reported 86% good to excellent results among 29 patients with flexion type SCHFs—seven type 1 fractures were treated with closed reduction and casting, while nine type 2 and 13 type 3 fractures were treated with closed/open reduction and percutaneous pinning.[7] The ulnar nerve is at an increased risk (7–18%) for injury during a flexion-type supracondylar fracture.[16]

Chukwunyerenwa et al, described a push-pull method for reducing type 3 flexion-type supracondylar fractures.[17] In this technique, longitudinal traction is applied to the forearm while the elbow is held in about 10° of flexion and then the elbow is slowly brought to near 90° of flexion while applying downward pressure from the forearm to push back the anteriorly displaced fracture fragment till it realigns with the proximal fragment. Then, while, maintaining this alignment, a gentle pull is exerted to restore the normal anterior angulation of the distal humerus, as judged by the anterior humeral line crossing the capitellum **(Figs 13A to C)**. Subsequent fixation is similar to any other supracondylar fracture using 2 or 3 lateral pins or cross-pin configuration **(Figs 14A and B)**. The C-arm is rotated to evaluate the fracture on a lateral view, rather than rotating the arm and losing reduction. This is true for flexion type, unstable extension type with posterolateral displacement, and type IV (unstable in both flexion and extension) fractures.

JAYPEE BROTHERS

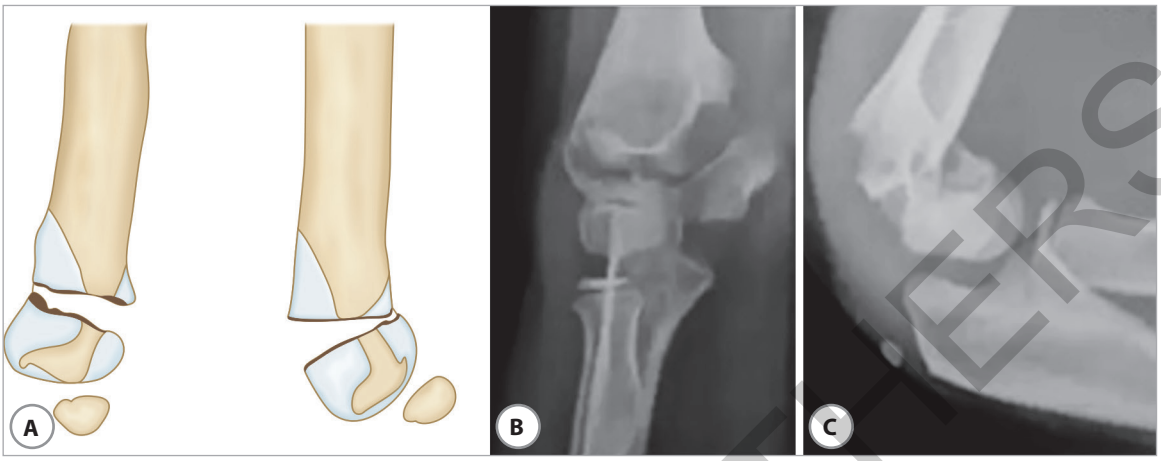

Figs 12A to C: Line diagram showing: (A) Typical extension-type; (B) Flexion-type supracondylar fracture; and (C) X-ray of flexion-type supracondylar fracture.

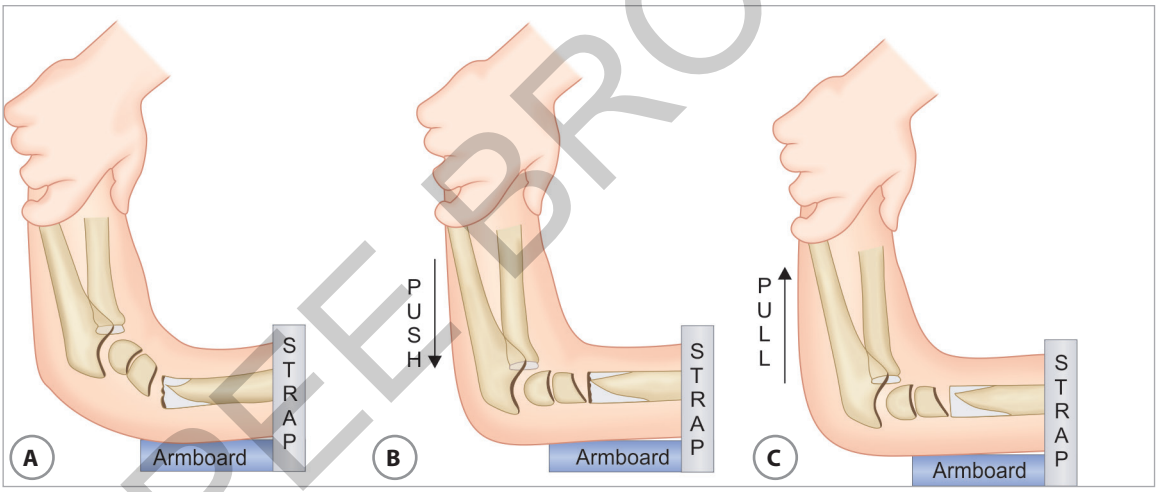

Figs 13A to C: Line diagram showing the reduction technique for a flexion-type supracondylar fracture of humerus. (A) Flexion type of supracondylar fracture; (B) Apply a downward force with elbow in 90° flexion to correct anterior displacement and reduce the fractured fragment to the proximal fragment (push); and (C) Gentle upward force to recreate a mild anterior angulation of the distal humerus, aligning the capitellum with the anterior humeral line (pull).

Green et al, used a transolecranon pin in the treatment of flexion-type supracondylar fractures.[18] It is advisable to initiate reduction in lateral view with elbow positioned in 70° extension. Once sagittal alignment is confirmed, a 1.8 mm K-wire is inserted starting from olecranon, traversing the distal fragment and keeping it intramedullary in the proximal fragment. This transolecranon pin helps align the fragment in lateral view. Following this, coronal alignment is addressed in anteroposterior (AP) view and then final fixation is done with K-wires for stability. The transfixing olecranon K-wire is then removed and stability is assessed. Thus, this transfixing olecranon K-wire utilizes the olecranon and distal fragment as leverage to facilitate fracture reduction **(Figs 15A to C)**.[19]

JAYPEE BROTHERS

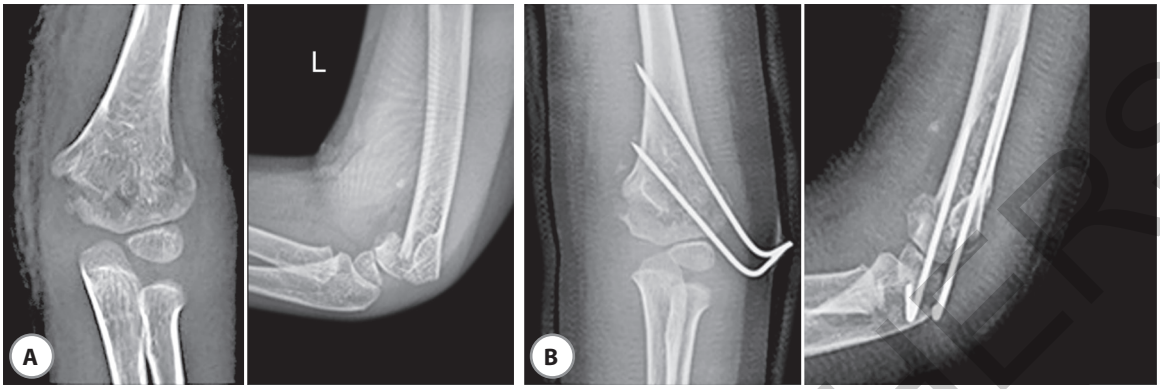

Figs 14A and B: Pre- and postoperative radiographs of a flexion type of supracondylar fracture treated with closed reduction and pinning.

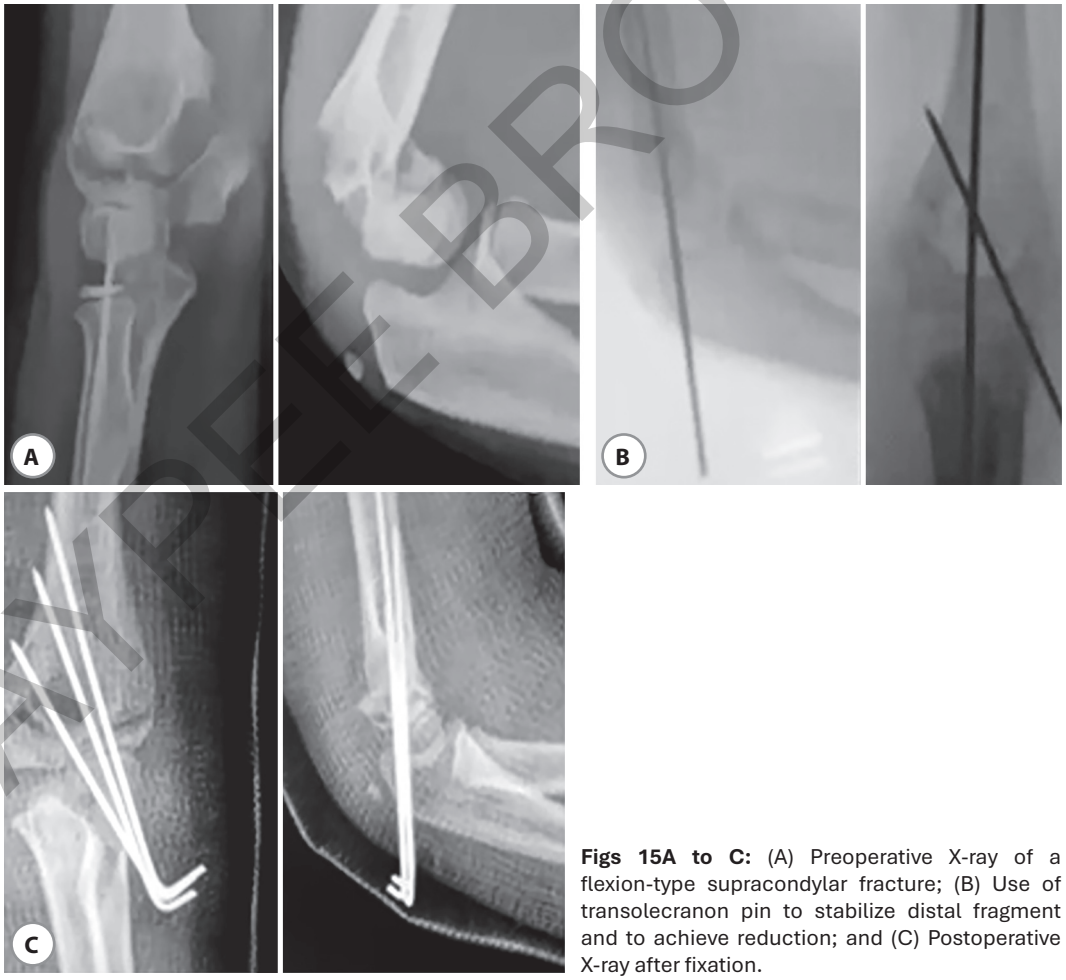

Figs 15A to C: (A) Preoperative X-ray of a flexion-type supracondylar fracture; (B) Use of transolecranon pin to stabilize distal fragment and to achieve reduction; and (C) Postoperative X-ray after fixation.

JAYPEE BROTHERS

Multidirectionally Unstable Supracondylar Fracture

Leitch et al, described a novel type IV supracondylar fracture which is unstable in both flexion and extension **(Fig 16)**.[20] During intraoperative assessment using C-arm, when the elbow is flexed, the fracture tends to over-reduce **(Figs 17A and B)**. To address such fractures, the "arm board technique" proves beneficial.[21] The proximal fragment is secured to an arm board using hypoallergenic radiolucent tape. Then two parallel or divergent pins are inserted from the lateral side into the distal fragment and used to manipulate the distal fragment to correct translation, varus-valgus and gross rotational malalignment. The image intensifier is then adjusted to achieve a true lateral view of the elbow joint. The sagittal deformity and the remaining rotational malalignment are then corrected, before the K-wires are advanced into and across the opposite cortex of the proximal fragment. Novais et al, have described a technique whereby a pin is inserted into the center of the distal fragment to joystick it into reduction before final fixation is done **(Figs 18A to H)**.[22]

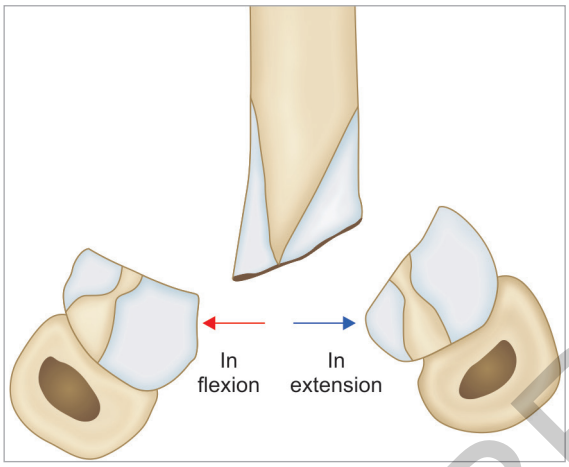

Fig 16: Line diagram showing a multidirectionally unstable fracture. Both flexion and extension maneuvers result in further fracture displacement.

Complications

For most of the atypical supracondylar fractures, the chances of needing an open reduction are

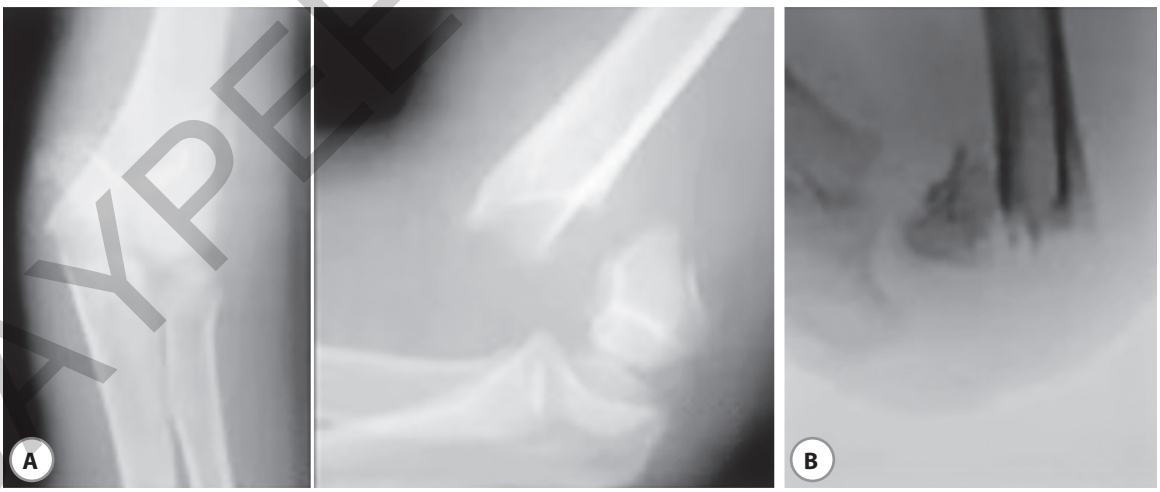

Figs 17A and B: (A) X-ray of a completely displaced supracondylar fracture seen in extension and (B) during reduction under image intensifier, the fragment slips into flexion suggesting multidirectional instability.

JAYPEE BROTHERS

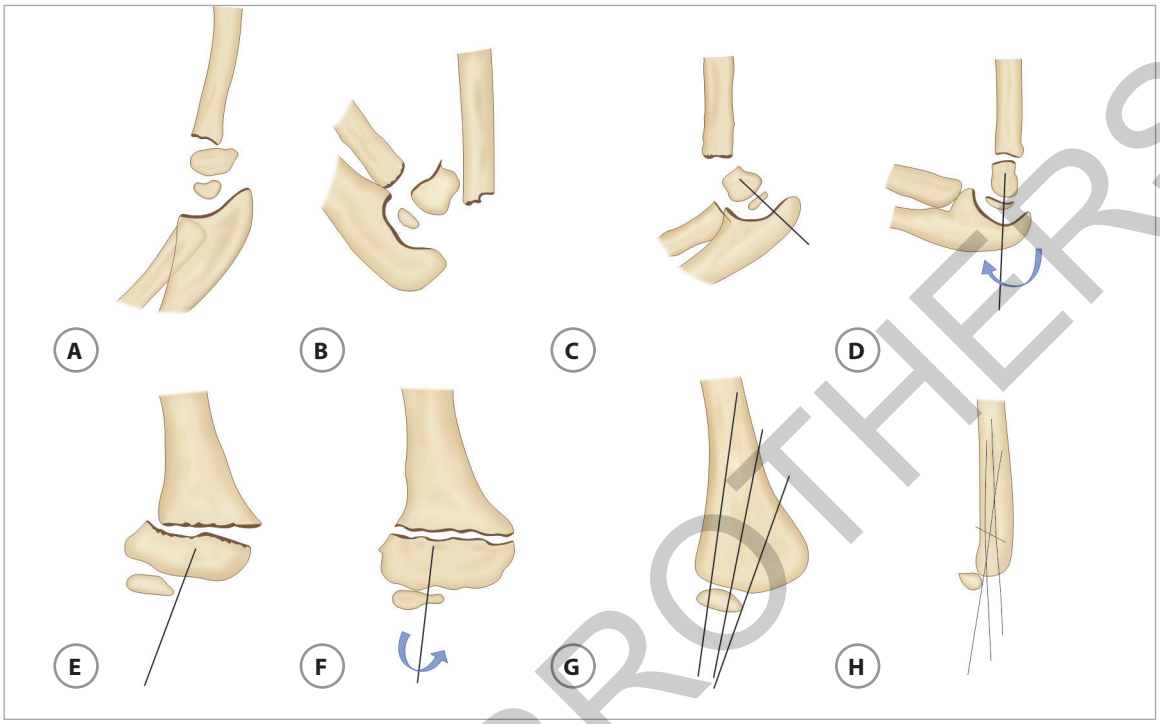

Figs 18A to H: Line diagram showing use of K-wire-assisted reduction. (A and B) Multidirectionally unstable fracture; (C) K-wire inserted in distal fragment; (D) K-wire used as joystick to get reduction in lateral view; (E and F) K-wire manipulated for reduction in coronal plane; and (G and H) Final fixation with 3 K-wires.

relatively higher and there should be a low threshold for an open reduction, if a couple of attempts of closed reduction fail. The ulnar nerve is known to be at risk for injury in flexion type of supracondylar fractures.[16,19] Since many of the atypical supracondylar fractures necessitate the use of a medial wire, there is significant risk of iatrogenic ulnar nerve injury. Failures of closed reduction may be because of soft-tissue interposition as seen with fractures having a sharp medial spike that button holes through the brachialis muscle necessitating open reduction or other techniques to free the spike from the muscle.[23] Atypical fractures are often more unstable than typical supracondylar fractures and if not adequately fixed, there may be loss of reduction leading to a malunion. Chances of avascular necrosis of trochlea are higher in low supracondylar fractures.

Conclusion

Supracondylar fractures are the most common fractures that occur around the elbow in children. The fractures need not always present as a typical extension-type transverse supracondylar fracture. Sometimes, they present with a varying fracture configuration, angulation, or displacement which is uncommon making it atypical. It is important that the treating orthopedician understands the fracture geometry at presentation and follows specific techniques of reduction and fixation to avoid problems in the postoperative period.

JAYPEE BROTHERS

KEY POINTS

- Fractures with a different fracture geometry, angulation, or displacement when compared with typical extension-type supracondylar fracture entail special consideration, vis-à-vis the reduction maneuvers and stabilization techniques employed.
- Medial pins or cross-pin fixation is required for the medial oblique fracture.
- High supracondylar fractures require intramedullary extension of the wires into the proximal humerus for superior fixation.
- Low supracondylar fractures are vulnerable to avascular necrosis of the trochlea.
- Transphyseal separations are often difficult to detect on plain X-rays and may need an MRI or an arthrogram for diagnosis.
- Care should be taken to insert K-wires perpendicular to the fracture site in sagittal oblique fractures.
- Flexion-type supracondylar fractures are more vulnerable to ulnar nerve injury, both at the time of injury and during insertion of the medial K-wires. The type 3 fracture is highly unstable and frequently requires open reduction.
- Supracondylar fractures unstable in both flexion and extension are reduced by joysticking the distal fragment into alignment with the proximal fragment.

References

1. Cheng JC, Shen WY. Limb fracture pattern in different pediatric age groups: a study of 3,350 children. J Orthop Trauma. 1993;7(1):15-22.
2. Otsuka NY, Kasser JR. Supracondylar fractures of the humerus in children. J Am Acad Orthop Surg. 1997;5(1):19-26.
3. Shrader MW. Pediatric supracondylar fractures and pediatric physeal elbow fractures. Orthop Clin North Am. 2008;39(2):163-7.
4. Gartland JJ. Management of supracondylar fractures of the humerus in children. Surg Gynecol Obstet. 1959;109(2):145-4.
5. Wilkins KE. Fractures and dislocations of the elbow region. In: Rockwood CA, Wilkins KE, King R (Eds). Fractures in Children. Philadelphia: Lippincott; 1984. pp. 363-575.
6. Bahk MS, Srikumaran U, Ain MC, Erkula G, Leet AI, Sargent MC, et al. Patterns of pediatric supracondylar humerus fractures. J Pediatr Orthop. 2008;28(5):493-9.
7. Sen RK, Tripathy SK, Kumar A, Agarwal A, Aggarwal S, Dhatt S. Metaphyseo-diaphyseal junction fracture of distal humerus in children. J Pediatr Orthop B. 2012;21(2):109-14.
8. Fayssoux RS, Stankovits L, Domzalski ME, Guille JT. Fractures of the distal humeral metaphyseal-diaphyseal junction in children. J Pediatr Orthop. 2008;28(2):142-6.
9. Zhou H, Zhang G, Li M, Liu X, Qu X, Cao Y, et al. Closed Reduction and Percutaneous Pinning in the Treatment of Humeral Distal Metaphyseal-Diaphyseal Junction Fractures in Children: A Technique Note and Preliminary Results. Front Pediatr. 2021;9:670164.
10. Lacher M, Schaeffer K, Boehm R, Dietz HG. The treatment of supracondylar humeral fractures with elastic stable intramedullary nailing (ESIN) in children. J Pediatr Orthop. 2011;31(1):33-8.
11. Marengo L, Canavese F, Cravino M, De Rosa V, Rousset M, Samba A, et al. Outcome of displaced fractures of the distal metaphyseal-diaphyseal junction of the humerus in children treated with elastic stable intramedullary nails. J Pediatr Orthop. 2015;35:611-6.
12. Kimball JP, Glowczewskie F, Wright TW. Intraosseous blood supply to the distal humerus. J Hand Surg Am. 2007;32(5):642-6.
13. Etier BE Jr, Doyle JS, Gilbert SR. Avascular necrosis of trochlea after supracondylar humerus fractures in children. Am J Orthop (Belle Mead NJ). 2015;44(10): e390-3.

JAYPEE BROTHERS

14. Glotzbecker MP, Bae DS, Links AC, Waters PM. Fishtail deformity of the distal humerus: a report of 15 cases. J Pediatr Orthop. 2013;33(6):592-7.
15. Hariharan AR, Nugraha HK, Ho CA, Bauer A, Mehlman CT, Sponseller PD, et al. Transphyseal Humeral Separations: An Often-Missed Fracture. Children (Basel). 2023;10(10):1716.
16. De Boeck H. Flexion-type supracondylar elbow fractures in children. J Pediatr Orthop. 2001;21: 460-3.
17. Chukwunyerenwa C, Orlik B, El-Hawary R, Logan K, Howard JJ. Treatment of flexion-type supracondylar fractures in children: the 'push-pull' method for closed reduction and percutaneous K-wire fixation. J Pediatr Orthop. 2016;25(5):412-6.
18. Green BM, Stone JD, Bruce RW Jr, Fletcher ND. The Use of a Transolecranon Pin in the Treatment of Pediatric Flexion-type Supracondylar Humerus Fractures. J Pediatr Orthop. 2017;37(6):e347-52.
19. Mahan ST, May CD, Kocher MS. Operative management of displaced flexion supracondylar humerus fractures in children. J Pediatr Orthop. 2007;27:551-6.
20. Leitch KK, Kay RM, Femino JD, Tolo VT, Storer SK, Skaggs DL. Treatment of multidirectionally unstable supracondylar humeral fractures in children. A modified Gartland type-IV fracture. J Bone Joint Surg Am. 2006;88(5):980-5.
21. Sodhai VM, Patwardhan SA, Alao SO, Shyam AK, Haphiz A. Arm board technique for closed reduction percutaneous pinning of displaced supracondylar fractures of humerus in children: Technical note. J Orthop Case Rep. 2020;9(6): 98-101.
22. Novais EN, Andrade MA, Gomes DC. The use of a joystick technique facilitates closed reduction and percutaneous fixation of multidirectionally unstable supracondylar humeral fractures in children. J Pediatr Orthop. 2013;33(1):14-9.
23. Shah M, Agashe MV. Supracondylar Humerus Fractures: Classification Based Treatment Algorithms. Indian J Orthop. 2020;55(1):68-80.

JAYPEE BROTHERS

JAYPEE BROTHERS

for detailed information on orthopedics books, visit our website www.ejaypee.com, for detailed information on orthopedics books, visit our website www.ejaypee.com,for detailed info

Master Series Monographs

Elbow Fractures in Children

BOS Worldwide

Building bridges—Sharing knowledge, experience, and expertise…

The BOS Masterseries Monographs are a series of books commissioned by the Bombay Orthopaedic Society with the goal of providing updated information, decision-making algorithms, and surgical techniques on selected orthopedic conditions. Reputed orthopedicians from Mumbai, around India, and internationally renowned experts have shared their knowledge, experience, and expertise in the field through this series.

"Elbow Fractures in Children" will be immensely beneficial to practicing orthopedic surgeons and trainees alike.

Key Features

- The monograph aims to serve as a single source for updated information on the management of elbow fractures in children.
- The decision-making and surgical technique of management of various injury patterns is discussed at length.

Gautam Zaveri is President of the Bombay Orthopaedic Society and the Bombay Spine Society. He is the Director of Spine Surgery at the Jaslok Hospital and Research Centre, Mumbai, Maharashtra, India. He is also the Editor-in-Chief of the ASSI Monograph Series, a series of books on various spinal disorders.



Taral Nagda is a Senior Pediatric Orthopedic Surgeon from Mumbai attached to SRCC Children's Hospital and Jupiter Hospital, Mumbai, Maharashtra, India. He is also Director of Jupiter Gait Lab and Jupiter Cerebral Palsy Clinic.



Binoti Sheth is a Pediatric Orthopedic Surgeon from Mumbai, attached to the Lokmanya Tilak Municipal Medical College and General Hospital, Mumbai, Maharashtra, India, as a Professor and Unit Head. She is also the author of books titled Pediatric Orthopaedic Trauma: Protocols and Techniques, Textbook of Orthopedics and Practicals for Undergraduate Orthopaedics.



Buy from ejaypee

JAYPEE BROTHERS

Shelving Recommendation
ORTHOPEDICS

ISBN 978-93-7202-841-6