l information on radiology books, visit our website www.ejaypee.com, for detailed information on radiology books, visit our website www.ejaypee.com,

Clinico Radiological Series

Imaging of Chest Infections

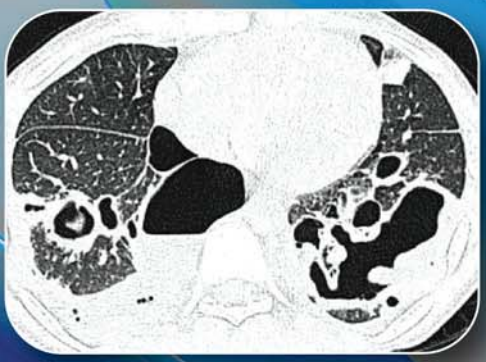

Editors
Ashu Seith Bhalla
Manisha Jana

Co-Editors
Surabhi Vyas
Priyanka Naranje

Clinical Content Editors
Anant Mohan
Karan Madan

2nd Edition

JAYPEE

Contents

SECTION 1: GENERAL

1. **Imaging in Chest Infections: Basics and Approach** 3
   Ashu Seith Bhalla, Manisha Jana
2. **Imaging Techniques in Evaluation of Chest Infections** 11
   Devasenathipathy Kandasamy, Priyanka GB, Nishikant Avinash Damle
3. **USG in Chest Infections** 26
   Manisha Jana, Ashu Seith Bhalla
4. **Microbiology of Pulmonary Infections** 37
   Sarita Mohapatra, Gagandeep Singh
5. **Pathology of Lung Infections** 47
   Deepali Jain, Sudheer Arava

SECTION 2: IMAGING ACCORDING TO CAUSATIVE ORGANISM

6. **Bacterial Pneumonia: Imaging** 57
   Smita Manchanda, Ravinder Kaur
7. **Viral Pneumonia: Imaging** 72
   Devasenathipathy Kandasamy, Poonam Sherwani
8. **COVID Pneumonia: Imaging** 83
   Dheeksha DS, Ashu Seith Bhalla
9. **Fungal Infections in Chest: Part 1** 98
   Priyanka Naranje, Ashu Seith Bhalla, Vijay Hadda
10. **Fungal Infections in Chest: Part 2** 121
    Priyanka Naranje, Ashu Seith Bhalla, Sudhakar Pipavath
11. **Parasitic Chest Infections: Imaging** 135
    Ashu Seith Bhalla, Priyanka Naranje
12. **Chest Tuberculosis: Imaging** 152
    Ravinder Kaur, Manisha Jana
13. **Nontuberculous Mycobacterial Pulmonary Infection: Imaging** 173
    Ashu Seith Bhalla, Smita Manchanda

SECTION 3: IMAGING ACCORDING TO CLINICAL SCENARIOS

14. Radiological Signs in Chest Infections **185**
Shivani Singh, Manisha Jana

15. Community-acquired Pneumonia: Imaging **197**
Surabhi Vyas, Anant Mohan

16. Imaging of Hospital-acquired Pneumonia **209**
Smita Manchanda, GC Khilnani

17. Approach to Infections in Immunocompromised Host **219**
Manisha Jana, Sushil K Kabra

18. Hematopoietic Stem Cell Transplantation: Imaging of Chest Infections **234**
Mukesh Yadav, Chandrashekhara SH, Priyanka Naranje

19. Imaging of Pulmonary Infections Following Solid Organ Transplantation **250**
Priyanka Naranje, Ashu Seith Bhalla

20. Pulmonary Manifestations of HIV Infection **268**
Surabhi Vyas, Ashu Seith Bhalla, Naveet Wig

21. Pediatric Lower Respiratory Tract Infections: Imaging **283**
Manisha Jana, Rakesh Lodha

22. Nonresolving or Recurrent Pneumonia: Imaging Approach **295**
Ashu Seith Bhalla, Manisha Jana

23. Imaging in Cardiac Infections **310**
Priya Jagia, Vyjayanthi Kadambi

SECTION 4: COMPLICATIONS AND MANAGEMENT OF PNEUMONIA

24. Complications of Chest Infections **329**
Ashu Seith Bhalla, Surabhi Vyas, Karan Madan

25. Interventional Radiology in Chest Infections **350**
Rajendra K Behera, Ankur Goyal, Ashu Seith Bhalla

26. Surgical Perspective for Evaluation and Treatment of Pulmonary Infections **369**
Rajinder Parshad, Ajit Singh Oberoi, Manjunath Bale

SECTION 5: PATTERN-WISE APPROACH TO THORACIC INFECTIONS

27. Approach to Consolidation and Ground-glass Opacity **381**
Stanzin Spalkit, Smita Manchanda, Ashu Seith Bhalla

28. Approach to Nodules and Cavities in Suspected Chest Infection **393**
Ankur Goyal, Ashu Seith Bhalla

29. Infections of Pleura and Chest Wall: Imaging **414**
Priyanka Naranje, Randeep Guleria

30. Infections of the Mediastinum: Imaging **432**
Priyanka Naranje, Manisha Jana

31. Airway Infections: Approach **446**
Priyanka Naranje, Abanti Das

SECTION 6: REPORTING FORMATS

32. Reporting Templates **463**
Smita Manchanda, Ashu Seith Bhalla

33. Self Appraisal **474**
Manisha Jana, Priyanka Naranje, Ashu Seith Bhalla

Index **491**

21 Pediatric Lower Respiratory Tract Infections: Imaging

Manisha Jana, Rakesh Lodha

- Etiology
- Clinical Features
- Imaging Modalities
- Terminology
- Imaging Findings
  - Neonates
  - Infants and Older Children
  - Imaging Patterns
  - Bacterial versus Viral Pneumonia
- Long-term Sequelae of Pediatric Pneumonia
  - Postinfectious Obstructive Bronchiolitis

INTRODUCTION

- Pneumonia is a major cause of morbidity and mortality in children, especially below 5 years of age.
- The conditions which predispose a child to develop pneumonia include malnutrition, low birth weight, lack of proper immunization, and lack of breast feeding. Also, overcrowding, passive smoking, and indoor pollution contribute to development of pneumonia. Concomitant diseases like diarrhea, asthma or congenital heart diseases also predispose a child to pneumonia.

ETIOLOGY

- The causative organism of infectious pneumonia in children varies depending on the age of the child.
- While in adults, airborne person to person transmission is the major route of infection; in young children aspiration is also a common route.
- Hence, the spectrum of organisms differs as oral or upper respiratory tract colonizers are implicated more frequently.
- Also the implicated organisms vary depending upon the age of the child **(Table 21.1)**.
- This chapter discusses bacterial and viral pneumonia. Fungal, parasitic and tubercular infections are discussed in Chapters 9–12.

JAYPEE BROTHERS

TABLE 21.1: Common causative organism of pneumonia in children according to age.

Age of the child	Organisms
Newborn	• Group B Streptococci • Gram-negative bacilli • *Listeria monocytogenes* • Herpes simplex • Rubella
1–3 months	• *Chlamydia trachomatis* • Respiratory viruses, especially respiratory syncytial virus (RSV)
3–12 months	• Respiratory viruses, especially RSV • *Streptococcus pneumoniae* • *Haemophilus influenzae* • *Staphylococcus aureus*
1–5 years	• Respiratory viruses • *Streptococcus pneumoniae* • *Haemophilus influenzae*
5–18 years	• *Mycoplasma pneumoniae* • *Streptococcus pneumoniae* • *Chlamydophila pneumoniae*

CLINICAL FEATURES

- The clinical features vary depending on the age of child, severity of pneumonia, and the organism.
- The classical presentation is fever with or without chills, cough, and fast breathing or difficult breathing. Severe cases present with chest retraction, lethargy, and refusal to feed. Young infants may present only with lethargy and refusal to feed.
- On clinical examination, tachypnea is seen (there are different age-related cut-offs for respiratory rate to define tachypnea). Severe cases have tachypnea with nasal flaring and chest retraction. There may be decreased breath sounds or crepitations, which may subsequently progress to a large area of decreased breath sounds.
- Viral infections that cause bronchiolitis are characterized by tachypnea, rhonchi on chest auscultation; in some children, hyperinflation may be appreciable.
- These days pulse oximetry is considered part of clinical examination; this is a reliable way to identify hypoxemia as none of the clinical signs have good sensitivity to pick up hypoxemia; cyanosis is a late sign.
- The typical findings of pneumonia may not be seen in the age group below 2 years. Unusual clinical findings in this age group include vomiting, diarrhea, abdominal distension, and neck retraction.

JAYPEE BROTHERS

IMAGING MODALITIES

- For management of a usual case of lower respiratory tract infection, imaging is not essential.
- Among the imaging modalities, the primary modality in pediatric pneumonia is *chest radiograph*. In several parts of the world, lateral view is also obtained routinely, while elsewhere only a frontal view is used.
- Unlike adults, chest radiograph is not routinely advocated in evaluation of pediatric lower respiratory tract infection (LRTI) which is mild and uncomplicated.
- *Indications of CXR:*
  - Infant less than 3 months of age with fever (to exclude pneumonia)
  - Severe infection
  - Equivocal diagnosis—to exclude other causes of dyspnea, e.g., foreign body, cardiac cause
  - Suspicion of staphylococcal etiology
  - In suspected complications, such as pleural effusions, empyema.
- *Ultrasonography (USG):*
  - With the advent of concept of point-of-care ultrasound (POCUS), transthoracic USG is being increasingly used for initial evaluation and follow-up of both outpatients and inpatients with pneumonia.
- *Lung ultrasound (LUS)* is now advocated as the first-line imaging modality in pediatric community-acquired pneumonia, even before a chest X-ray (CXR). Studies have demonstrated the superiority of ultrasound (US) over CXR in the diagnosis of pneumonia in children. It can be used in conjunction with a CXR also effectively.
- *Computed tomography (CT):* Contrast-enhanced chest CT, though clearly superior to CXR, is reserved for:
  - Suspected complications in severe infections
  - Recurrent or non-resolving infections
  - Its role in recurrent infections is discussed in Chapter 19.
- *Magnetic resonance imaging (MRI):*
  - In recent times, rapid lung MRI has emerged as a viable alternative to children requiring repeated imaging, e.g., immunocompromised patients.

TERMINOLOGY

- The World Health Organization in 2005 gave standard radiographic descriptive terms, to be used in children suspected of pneumococcal pneumonia (vs. viral infections).[1,2] The purpose was primarily to facilitate homogeneity in epidemiological studies and vaccine trials, while reporting CXRs, and provide a radiological "case distinction".
- "*Endpoint consolidation"* refers to an opacity (dense or fluffy) occupying part of a lobe/entire lobe/entire lung **(Fig. 21.1)**.
- *"Other infiltrates" include the following **(Fig. 21.2)**:*
  - Densities that are linear or patchy
  - Peribronchial thickening

JAYPEE BROTHERS

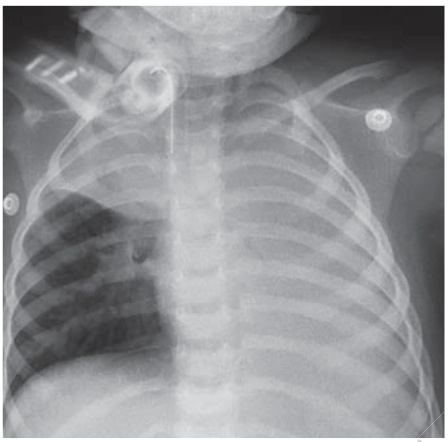

FIG. 21.1: Endpoint consolidation. A 10-month-old infant right upper lobe consolidation with opaque left hemithorax due to collapse (mucus plug).

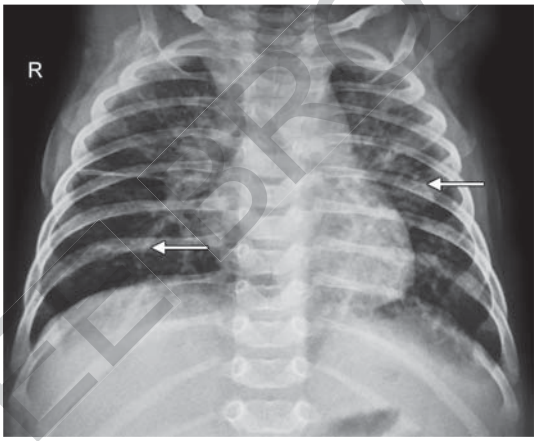

FIG. 21.2: Other infiltrates (arrows). 2-year-old with fever. Peribronchial thickening and nodules.

JAYPEE BROTHERS

- Minor infiltrates in patchy distribution—not conforming to primary endpoint consolidation
- Small areas of atelectasis.

- *Primary endpoint pneumonia:*
  - Includes either endpoint consolidation, or pulmonary parenchymal infiltrates in combination with pleural effusion **(Fig. 21.3)**.
  - However, in countries with widespread use of pneumococcal and *H. influenzae* vaccination, children may not show the classical endpoint pneumonia.
  - Hence, there is a revised case definition proposed "presumed bacterial pneumonia" which includes those with abnormal infiltrates on CXR and a serum C-reactive protein (CRP) more than or equal to 40 mg/L.

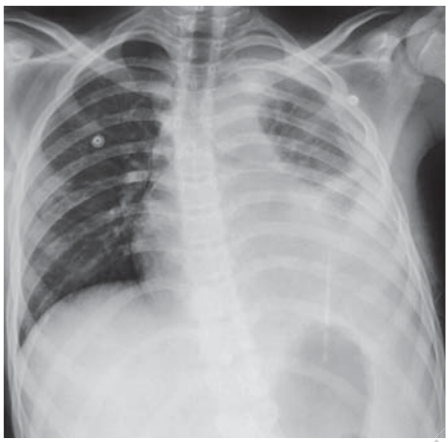

FIG. 21.3: Primary endpoint pneumonia. Left sided consolidation with pleural effusion.

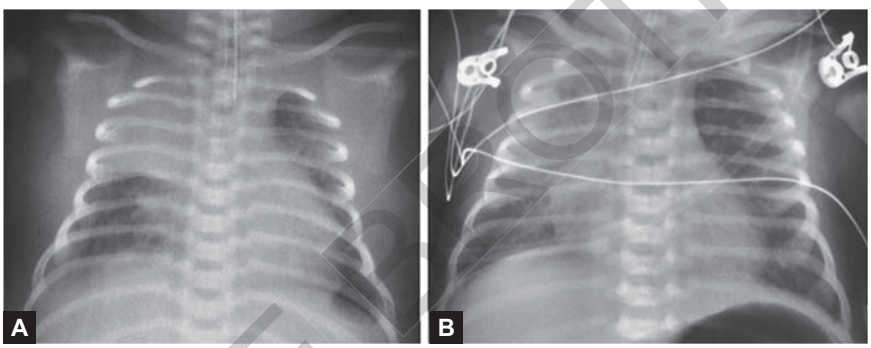

FIG. 21.4A AND B: Neonatal pneumonia acquired in utero. Two different neonates: (A) RUL consolidation; (B) Patchy consolidation in right upper zone and mid zone.

IMAGING FINDINGS

- Broadly, as in adults, imaging patterns in children can be divided into consolidation, interstitial pattern, and bronchopneumonia.
- The imaging findings can vary according to the age.

Neonates

- Neonatal pneumonia acquired in utero or through maternal genital tract reveals consolidation or ground-glass pattern with air bronchogram. The distribution is unilateral or bilateral asymmetric **(Figs. 21.4A and B)**.
- If bilateral, diffuse, asymmetric opacities are seen; these suggest hematogenous spread of infection. This pattern is difficult to differentiate from respiratory distress syndrome (RDS) **(Figs. 21.5A and B)**.
- Meconium aspiration syndrome is an important differential which shows more scattered distribution of the areas of consolidation, more toward periphery, away from hilum with hyperinflation **(Fig. 21.6)**.
- Postnatal aspiration is suspected when the opacities are located in the dependent areas, more frequently on the right side.

JAYPEE BROTHERS

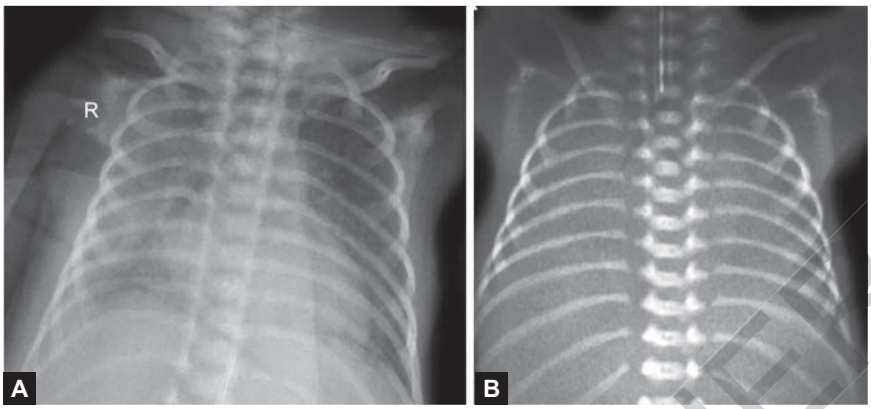

FIGS. 21.5A AND B: Neonatal pneumonia and respiratory distress syndrome (RDS). (A) Neonatal pneumonia with a more homogeneous distribution suggesting hematogenous spread; (B) RDS. Similar homogeneous opacification of both lungs "whiteout lung"; but lung volume is reduced.

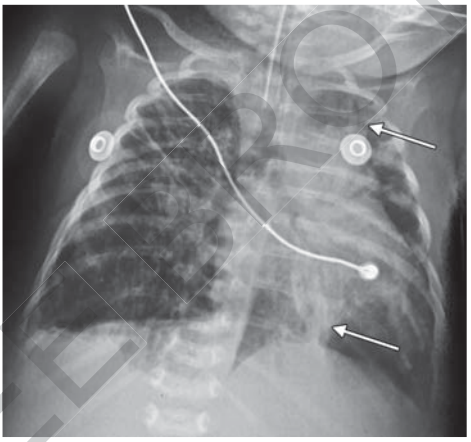

FIG. 21.6: Meconium aspiration syndrome. Both lungs are hyperinflated. Patchy areas of atelectasis (arrows).

Infants and Older Children

Numerous findings are advocated for distinction of viral from bacterial pneumonia but this distinction is often difficult particularly with atypical bacterial pneumonia. These are discussed further.

Imaging Patterns

- *Consolidation **(Figs. 21.7 and 21.8)**:*
  - A *lobar consolidation,* when unilateral and accompanied by pleural effusion, implies bacterial etiology.
  - "Lobar infiltrate" is suspected when one or more prominent air bronchograms are seen in the periphery (more than second generations beyond main stem bronchi). These may be seen with

JAYPEE BROTHERS

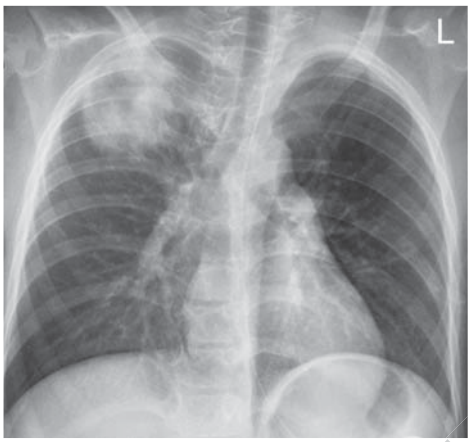

FIG. 21.7: Consolidation in right upper zone.

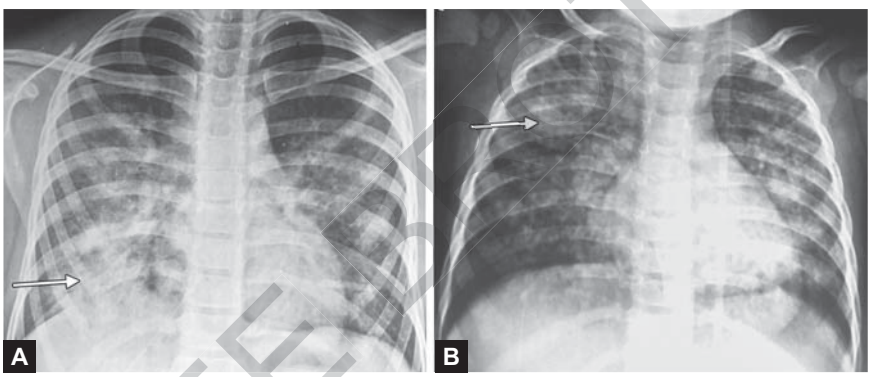

FIG. 21.8A AND B: Combined patterns of bronchopneumonia and consolidation (arrows) in 2 patients.

bacterial pneumonia, viral infections, and other causes of airway obstruction causing atelectasis such as mucus plugging. Unilateral dense lobar infiltrates favor bacterial etiology.

- Presence of pneumatoceles or lung abscess raises suspicion of *Staphylococcus aureus* or gram-negative bacteria, or severe pneumococcal infection. Pneumatoceles also develop in *Pneumocystis jirovecii* infection but seldom encountered in immunocompetent children. *Staphylococcus aureus* often spreads to lungs from other sites of infection such as pyoderma.
- *Round pneumonia*: Seen with *Streptococcus pneumoniae* and *S. aureus* infections.

- *Bronchopneumonia:*
  - Bronchopneumonia can be caused by both viruses and bacteria (especially *H. influenzae*, *M. pneumoniae* and *Chlamydophila*)
  - In this pattern bilateral "infiltrates" may be seen.

JAYPEE BROTHERS

- *Interstitial pattern **(Fig. 21.9)**:*
  - Severe viral LRTI are frequently associated with bronchiolitis. CXR shows generalized hyperinflation with linear streaky, parahilar opacities (representing bronchial wall thickening): *Interstitial pattern.*
  - However, this distinction on the basis of imaging alone is not always reliable.
- *Adenopathy:*
  - Presence of hilar and mediastinal adenopathy
    - With unilateral consolidation, pleural effusion, and cavitation—*Mycobacterium tuberculosis **(Fig. 21.10)***
    - Lower lobe distribution of infiltrates, cystic fibrosis (CF)
    - Combined interstitial pattern, and hilar nodes—*M. pneumoniae.*

Bacterial versus Viral Pneumonia

Differences between viral and bacterial pneumonia are listed in **Table 21.2 (Figs. 21.11A and B)**.

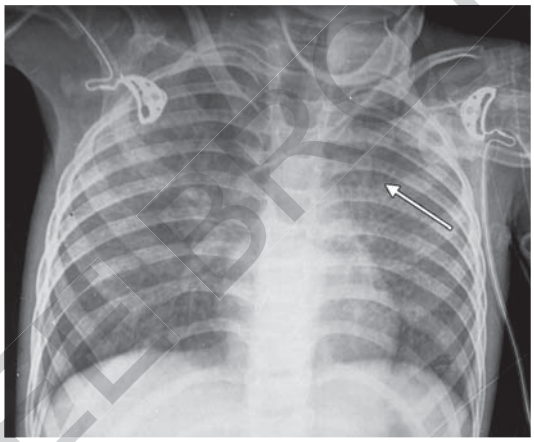

FIG. 21.9: Interstitial pattern in viral pneumonia. Note the prominent "dark bronchus" sign (arrow).

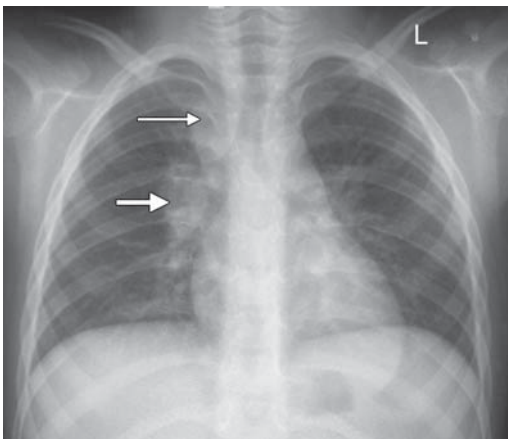

FIG. 21.10: Primary tuberculosis. Right paratracheal (thin arrow) and right hilar (thick arrow) lymphadenopathy. The parenchymal focus is not identifiable.

JAYPEE BROTHERS

TABLE 21.2: Differences between viral and bacterial pneumonia.	
Viral pneumonia	**Bacterial pneumonia**
Hyperinflation	Lobar consolidation or infiltrate
Parahilar, peribronchial infiltrates	Pleural effusion
Atelectasis (segmental or lobar)	Cavitation, pneumatoceles
Hilar adenopathy	Round pneumonia

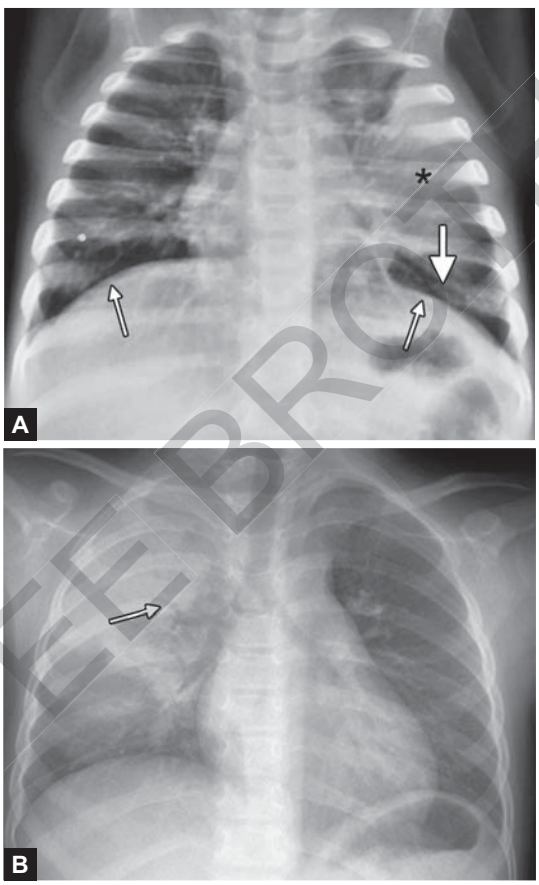

FIGS. 21.11A AND B: Viral vs. bacterial pneumonia. (A) Viral pneumonia. Hyperinflated lungs, as manifested by flattening of diaphragm domes (thin arrows)—left upper lobe consolidation (asterisk) with areas of atelectasis in left lower lobe (thick arrow); (B) Bacterial pneumonia. Right upper and midzone consolidation with air bronchogram (arrow).

LONG-TERM SEQUELAE OF PEDIATRIC PNEUMONIA

- Occurrence of pneumonia, especially in its severe form, may leave sequelae which are often the cause of chronic refractory disorders in adulthood. This is primarily so in children less than 3 years of age. The sequelae are worse in those episodes requesting hospitalization.

JAYPEE BROTHERS

- *Long-term sequelae include:*
  - Restrictive lung function, most common, likely due to fibrotic sequelae which may be parenchymal or pleural
  - Airway disorders
  - Bronchiectasis—localized or diffuse
  - *Obstructive lung function:* Particularly following adenoviral infection
  - Increased risk of adulthood asthma and chronic obstructive pulmonary disease (COPD).

Postinfectious Obstructive Bronchiolitis (Figs. 21.12 to 21.14)

Synonym: Swyer–James syndrome or Swyer–James–MacLeod syndrome.

- Postinfectious obliterative or constrictive bronchiolitis refers to subepithelial inflammation with resultant fibrosis and irreversible narrowing of the bronchiole.
- This may follow LRTI in early childhood with the most frequently implicated organism being adenovirus; other organisms include *Mycoplasma pneumoniae* or infrequently measles and influenza virus.
- The affected lung does not grow, and due to reflex vasoconstriction showing diminished vascularity.

Imaging findings:

- Imaging findings are of a small, lucent lung. Though classically described as unilateral, the condition can be bilateral.
- The ipsilateral pulmonary artery is small.
- The lung shows air trapping on expiration, lack of gradient attenuation in dependent areas with or without bronchiectasis.



FIG. 21.12: Bronchiolitis obliterans after viral pneumonia. Follow-up CXR after 6 months. Hyperinflation and patchy atelectasis.

JAYPEE BROTHERS

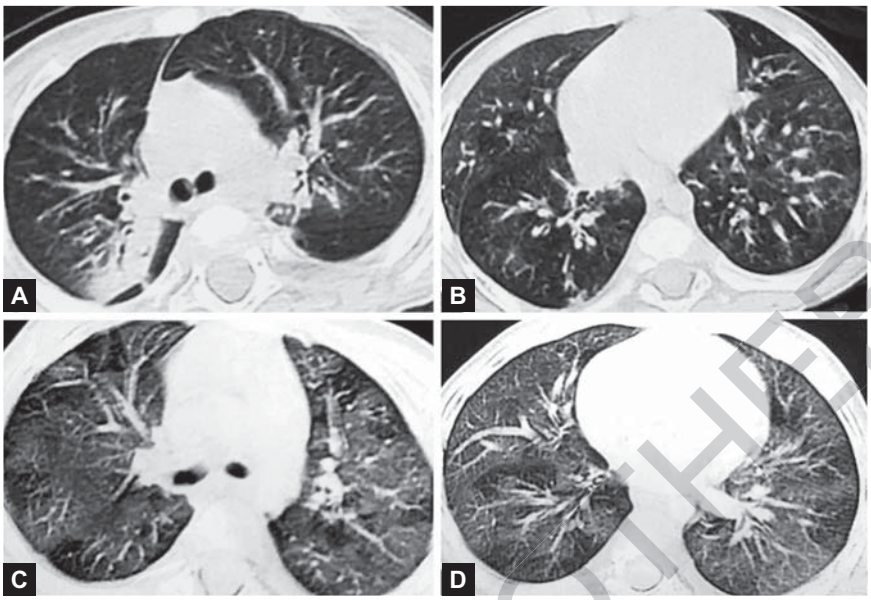

FIGS. 21.13A TO D: Bronchiolitis obliterans after viral pneumonia. (A and B) CT during acute viral pneumonia episode. Right upper lobe consolidation (arrow) and both lower lobe peribronchial thickening; (C and D) Follow-up CXR after 6 months. Patchy areas of air trapping (arrows).

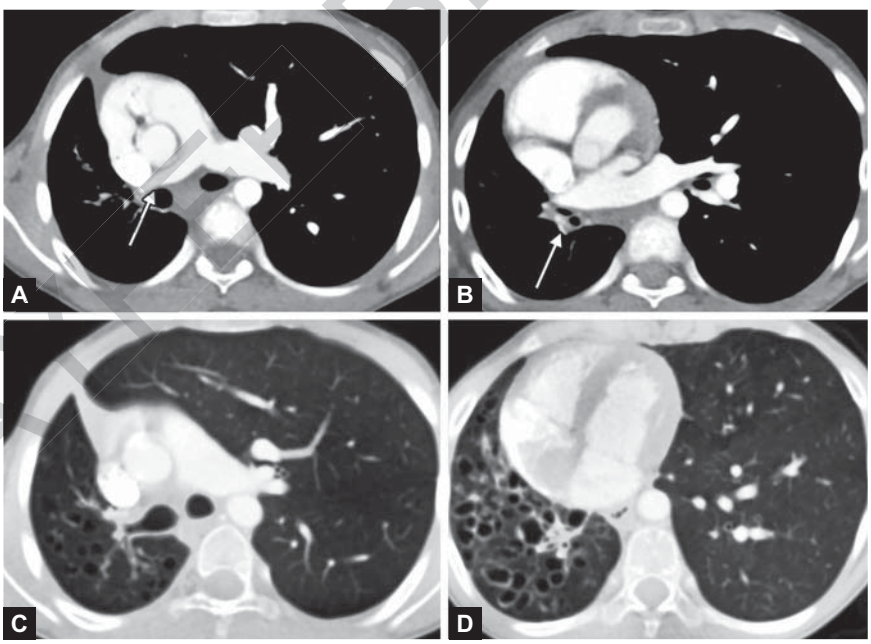

FIGS. 21.14A TO D: Swyer–James syndrome. (A) 10-year-old child with recurrent chest infections since infancy. Right pulmonary artery smaller in caliber compared to left pulmonary artery (arrow in A). Right pulmonary veins thinner in caliber (arrow in B). Right main bronchus of normal caliber (C); Extensive bronchiectasis in right lung (D).

JAYPEE BROTHERS

CONCLUSION

Imaging in neonatal and pediatric lower respiratory tract infections relies largely on chest radiographs, with CT being used for detection of complications.

REFERENCES

1. Cherian T, Mulholland EK, Carlin JB, et al. Standardized interpretation of pediatric chest radiographs for the diagnosis of pneumonia in epidemiological studies. Bull World Health Organ. 2005;83(5):353-9.
2. Standardization of interpretation of chest radiographs for the diagnosis of pneumonia in Children. World Health Organization Pneumonia Vaccine Trial Investigators' Group; 2001.

JAYPEE BROTHERS

for detailed information on radiology books, visit our website www.ejaypee.com, for detailed information on radiology books, visit our website www.e

Clinico Radiological Series
Imaging of Chest Infections

Salient Features

- This handbook focuses on core imaging and management issues in chest infections which is a common concern among radiologists and physicians.
- Extensive focus on optimization and systematic interpretation of imaging modalities.
- Unique arrangement of sections having a combined clinical and radiological perspective of the disease.
- Chapters contributed by reputed experts from Radiology, Pulmonology, Pathology, and Microbiology.
- High-quality images and illustrations with detailed description of the disease entities.
- Reporting template and test yourself sections: A unique feature of this book which will be helpful for residents for self-appraisal.
- Pattern-wise approach according to the key radiological abnormality guide to reach a particular diagnosis.
- Provides tables of close radiological differentials.
- Aims to become a "ready reference" for all the radiologists and physicians involved in this field.

Ashu Seith Bhalla MD MAMS FICR is a Professor of Radiodiagnosis and Interventional Radiology at the All India Institute of Medical Sciences (AIIMS), New Delhi, India. She is a reputed radiologist with special interest in thoracic, interventional, and head and neck radiology with over 20 years of experience in the field. She has over 300 publications, has authored numerous chapters in books, and is on the editorial boards of several journals. She has a passion for teaching and is extensively involved in teaching programs all over the country.

Manisha Jana MD DNB FRCR is a Professor of Radiodiagnosis and Interventional Radiology at the All India Institute of Medical Sciences (AIIMS), New Delhi, India. She has special interest in pediatric and general radiology and nurtures a love for teaching. She has published above 200 articles in reputed journals, has written many book chapters, and is actively involved in teaching and research activities in the institute.

Buy from ejaypee

JAYPEE BROTHERS

Shelving Recommendation
RADIOLOGY

ISBN 978-93-7545-260-7