r detailed information on cardiology books, visit our website www.ejaypee.com, for detailed information on cardiology books, visit our website www.ejaypee.com

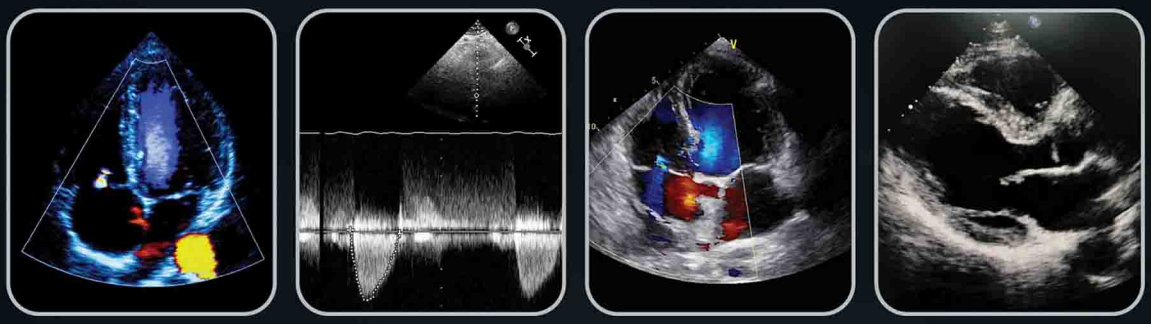

ECHOCARDIOGRAPHY SIMPLIFIED

A PRACTICAL APPROACH



Keshav Sharma

JAYPEE

Contents

CHAPTER 1: **M-mode, Two-dimensional, Doppler Measurements** **1**

CHAPTER 2: **Doppler Principle** **15**

CHAPTER 3: **Systolic Function** **23**

CHAPTER 4: **Diastolic Function** **33**

CHAPTER 5: **Introduction to Right Ventricular Function** **39**

CHAPTER 6: **Dyssynchrony** **41**

CHAPTER 7: **Evaluation Prosthetic Heart Valves** **45**

CHAPTER 8: **Valvular Stenosis Assessment** **49**

CHAPTER 9: **Valvular Regurgitation Assessment** **62**

CHAPTER 10: **Practical Tips and Tricks in Echocardiography** **76**

Index **79**

1 M-mode, Two-dimensional, Doppler Measurements

INTRODUCTION

Echocardiography is the cornerstone of noninvasive cardiac imaging and provides comprehensive information about cardiac structure, function, and hemodynamics. This chapter introduces the foundational concepts of two-dimensional (2D) imaging, M-mode, and Doppler modalities essential for routine echocardiographic evaluation. Each modality contributes unique information—2D imaging depicts cardiac anatomy, M-mode provides precise measurements of motion and wall thickness, while Doppler techniques quantify flow velocities, gradients, and pressure estimations.

Through standardized imaging windows and measurement techniques, echocardiographers can reliably assess ventricular size, systolic and diastolic function, valvular morphology, and intracardiac hemodynamics. **Figures 1 to 26** illustrate the standard views and measurement methods discussed throughout this chapter.

MODALITIES OF ECHOCARDIOGRAPHY AND THEIR USES

Two-dimensional Imaging

Two-dimensional imaging is the backbone of echocardiography and provides real-time visualization of cardiac structures, chamber dimensions, wall thickness, and valvular morphology.

Parasternal Long Axis View

The parasternal long axis view (PLAX) view is obtained from the parasternal window and is commonly the starting point of examination. It helps assess left ventricle (LV) cavity size, wall thickness, left ventricle outflow tract (LVOT), aortic root, LA size, and morphological evaluation of mitral and aortic valves **(Fig. 1)**.

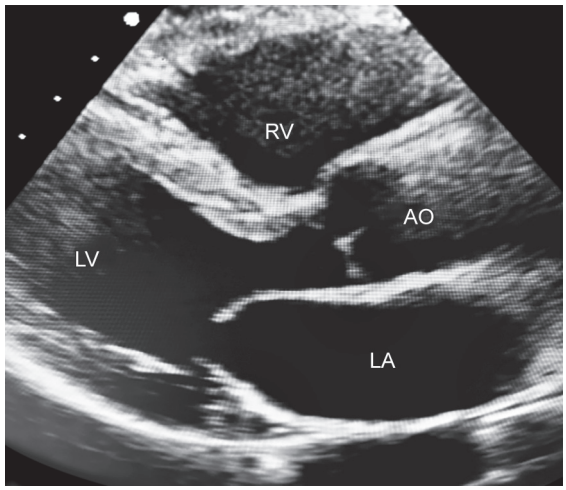

Fig. 1: Parasternal long axis view (PLAX).

(AO: aorta; LA: left atrium; LV: left ventricle; RVOT: right ventricle outflow tract)

JAYPEE BROTHERS

Left Ventricle Outflow Tract Diameter Measurement

The LVOT diameter is measured from the PLAX view, 2–5 mm below the aortic valve annulus during mid-systole **(Fig. 2)**.

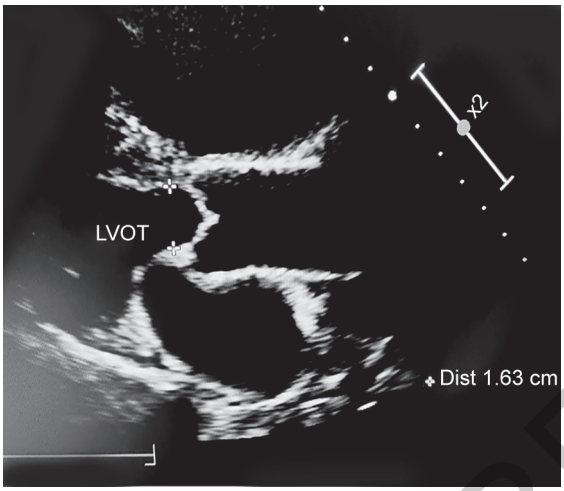

Fig. 2: Left ventricle outflow tract (LVOT) diameter measurement in parasternal long axis view (PLAX) view.

Accurate stroke volume calculation requires that *LVOT diameter and LVOT VTI* be measured at the same anatomical location.

Simpson's Biplane Method of Discs

It is used for calculation of LV volumes and ejection fraction using apical four-chamber and two-chamber views **(Figs. 3A and B)**. Endocardial borders must be well visualized. Papillary muscles and trabeculations are excluded from the tracing.

Automatically calculate ejection fraction by the following formula:

$$EF = \frac{EDV - ESV}{EDV \times 100}$$

Limitation: Good endocardial border delineation.

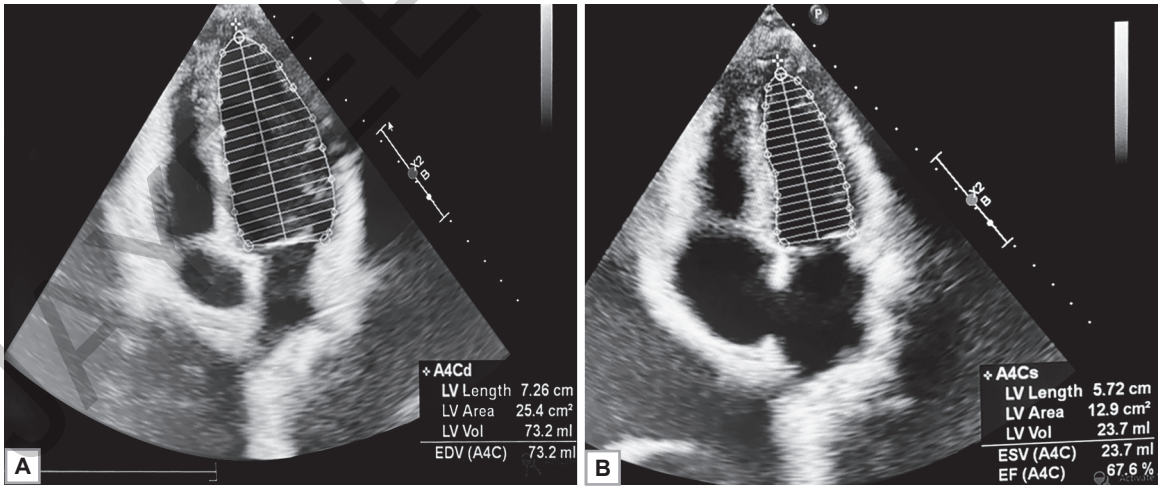

Figs. 3A and B: Apical four-chambers view demonstrate Simpson's method for calculation of LV volume and ejection fraction.

JAYPEE BROTHERS

Planimetry of Mitral Valve Area

Planimetry is performed in the parasternal short axis (PSAX) view at the mitral valve (MV) level during mid-diastole. The mitral opening appears as a "fish-mouth" structure.

Zoom to the image **(Fig. 4)**. This method becomes challenging in heavily calcified valves.

Aortic valve planimetry may also be performed at the PSAX aortic level **(Fig. 5)**.

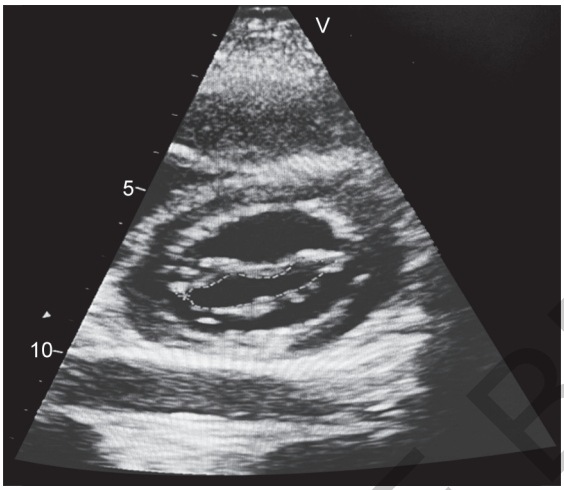

Fig. 4: Parasternal short axis (PSAX) view showing mitral valve (MV) area by planimetry.



Fig. 5: Parasternal short axis (PSAX) aortic level showing aortic valve (AV) area by planimetry.

Estimates Orifice Area of the Aortic Valve

Aortic valve area estimation by planimetry shown in **Figure 5**.

M-MODE IMAGING

M-mode provides high temporal resolution and is used for precise measurements of LV cavity size, wall motion, and timing of cardiac events. The cursor must be placed *perpendicular* to the interventricular septum and posterior wall **(Fig. 6)**.

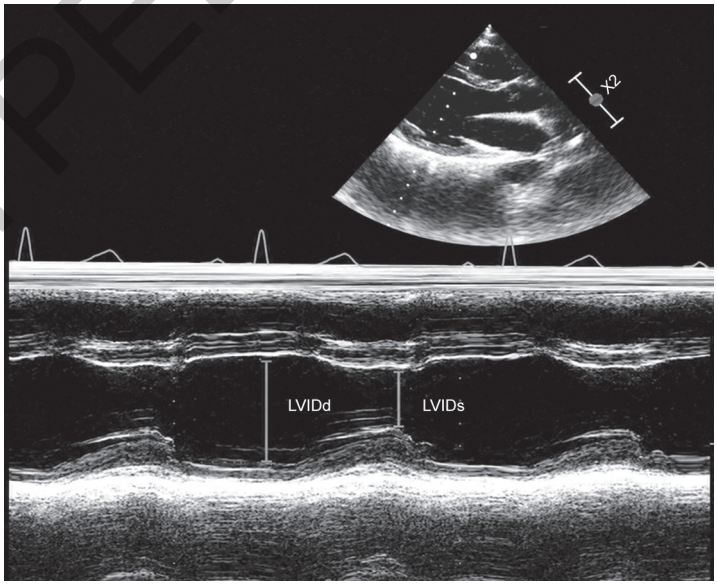

Fig. 6: Parasternal long axis view (PLAX) for left ventricle (LV) cavity size and ejection fraction assessment.

JAYPEE BROTHERS

DOPPLER MODALITIES

Continuous Wave Doppler

Continuous wave (CW) Doppler measures the highest velocity along the entire ultrasound beam and is ideal for assessing stenotic gradients, pulmonary pressures, and high-velocity jets such as ventricular septal defect (VSD), LVOT obstruction, and valvular lesions. It utilizes two separate transducers to transit sound and another to receive sound **(Fig. 7)**.

Pulsed Wave Doppler

Pulsed wave (PW) Doppler samples velocities at specific locations and is used for: Mitral inflow E/A, LVOT, and right ventricle outflow tract (RVOT), velocity time integral (VTI) **(Figs. 8A to D)**.

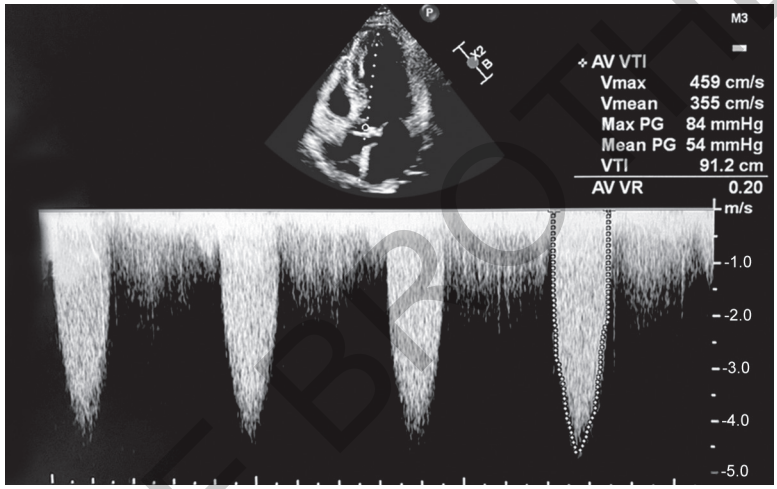

Fig. 7: Continuous wave (CW) Doppler measuring peak and mean gradients.

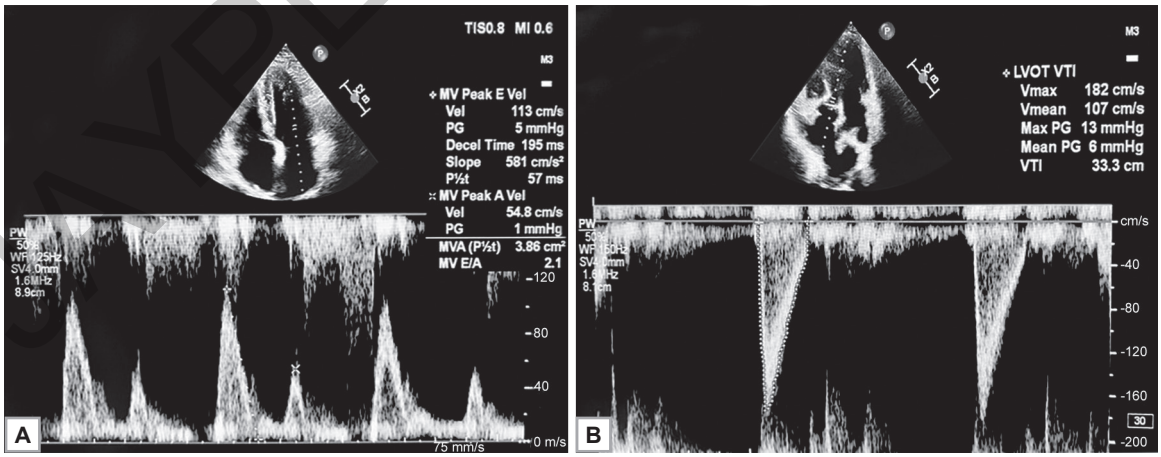

Figs. 8A to D: *Continued*

JAYPEE BROTHERS

Continued

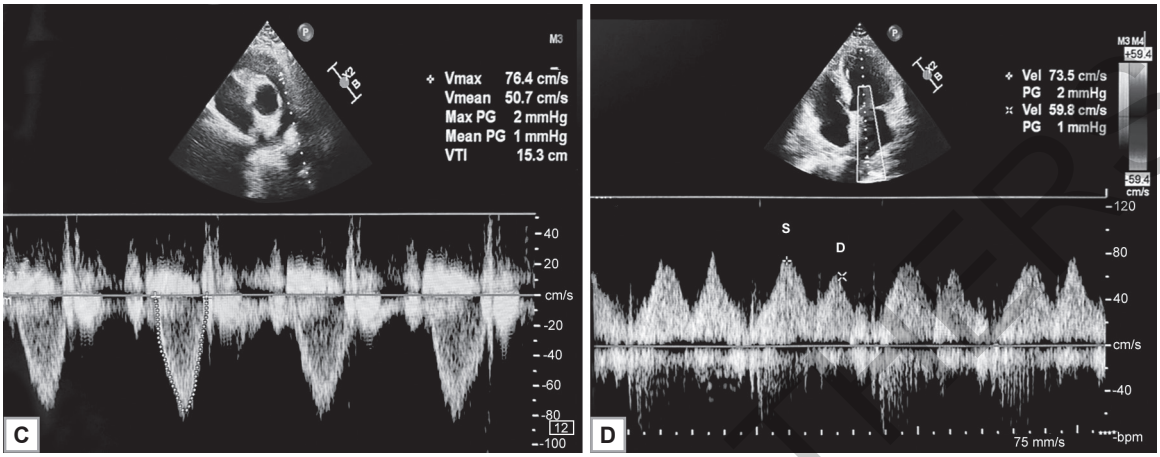

Figs. 8A to D: Pulsed wave (PW) Doppler–Mitral inflow (E & A waves) and pulmonary venous flow.

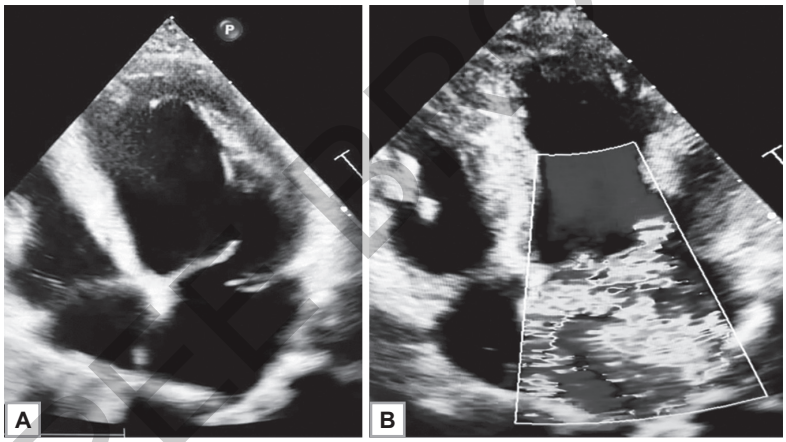

Figs. 9A and B: Color Doppler showing severe mitral regurgitation (MR) due to flail posterior mitral leaflet (PML). ***(For color version, see Plate 1)***

Color Flow Mapping

Color Doppler is used to detect valvular regurgitation and abnormal jets. Severe mitral regurgitation (MR) due to flail posterior mitral valve leaflet (PML) is shown in **Figures 9A and B**.

TECHNICAL CONCEPTS

Important Definitions

- *Leading edge:* An edge of echo which is toward the transducer is leading edge to leading edge (all M-mode study)
- *Trailing edge:*
  - Each echocardiography (echo) has a finite width.
  - An edge of echo, which is toward the transducer.
  - Leading edge to leading edge (all M-mode study)
  - An edge of echo, which is away from the transducer is the trailing edge to leading edge (all 2D study)

Resolution

Resolution is the ability to identify two different objects lying close to each other.

JAYPEE BROTHERS

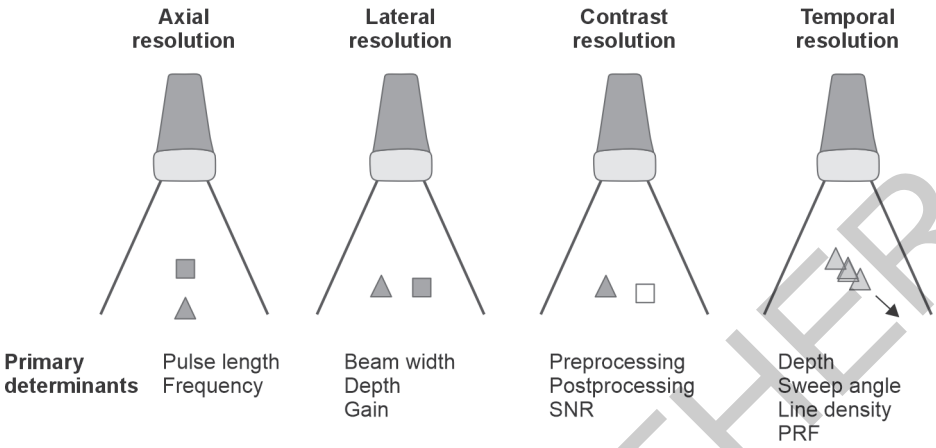

Fig. 10: The four principal types of ultrasound image resolution—axial, lateral, contrast, and temporal resolution—and their primary determinants. Axial resolution depends mainly on pulse length and transducer frequency, lateral resolution on beam width, depth, and gain, contrast resolution on signal-to-noise ratio (SNR) and image processing, and temporal resolution on depth, sweep angle, line density, and pulse repetition frequency (PRF).

Penetration and Frequency

Penetration is the depth at which ultrasound travels.

Higher frequency = better resolution, poor penetration

Lower frequency = deeper penetration, poor near-field resolution **(Fig. 11)**.

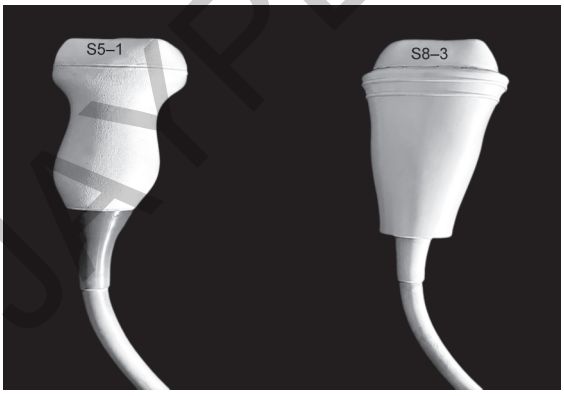

Fig. 11: Different frequency transducers (S5–1 and S8–3 MHz).

Frequency of Transducers

Transducer frequency refers to the number of ultrasound waves emitted by the probe per second, measured in megahertz (MHz). It determines image resolution and tissue penetration. Higher-frequency transducers (e.g., 5–12 MHz) provide superior spatial resolution but have limited penetration, whereas lower-frequency transducers (e.g., 1–5 MHz) offer greater penetration at the expense of image resolution."

For adult transthoracic echocardiography, a phased-array transducer with a frequency range of approximately 2–5 MHz is commonly used. Pediatric and vascular imaging often utilize higher-frequency probes to obtain better image detail.

Two-dimensional Echocardiography—Backbone of Echocardiography

Parasternal window: Probe positioned at the left sternal border (3rd–4th ICS). Used for PLAX view. Mostly echocardiographers begin their examinations from the parasternal window **(Fig. 12)**.

JAYPEE BROTHERS

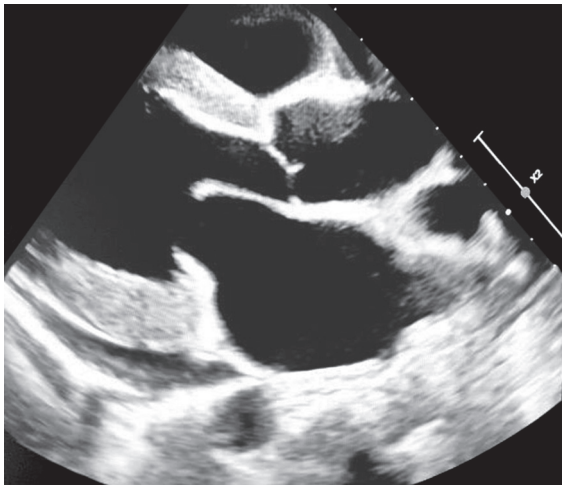

Fig. 12: Parasternal long axis view (PLAX) view.

Apical Window

Probe placed at the cardiac apex pointing toward the left shoulder. Used for apical four-chamber (A4C) view **(Fig. 13)**.

Subcostal Window

This lies below the xiphisternum in the epigastrium where the patients lie on their back with their stomach relaxed. Very useful in patient with chronic obstructive pulmonary disease (COPD). Used to assess pericardial effusion, right ventricle (RV) inflow, and septal defects **(Fig. 14)**.



Fig. 13: Apical four-chamber view.

Suprasternal Window

- Position the patient lying down with a pillow behind their shoulders so they can tilt their head back.
- Turn the patient's face to their left shoulder.
- Place the transducer in the suprasternal notch.
- Angle the transducer toward the patient's left shoulder.
- Gradually rotate the marker clockwise toward the left shoulder.

It is used to evaluate the aortic arch and great vessels **(Fig. 15)**.

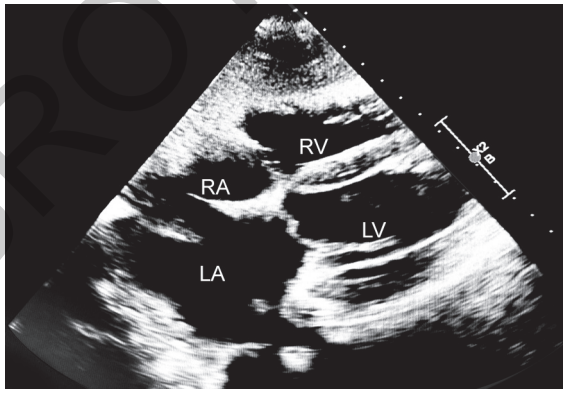

Fig. 14: Apical four-chamber view at subcostal window.

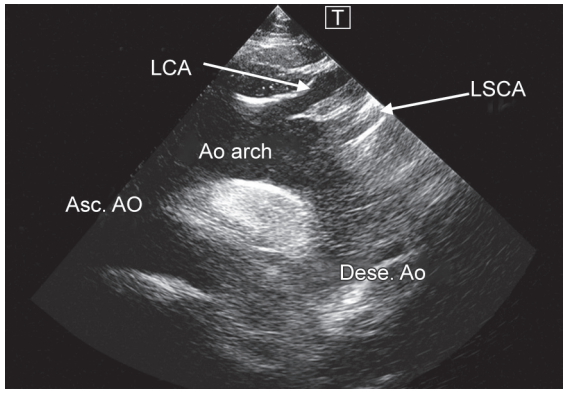

Fig. 15: Suprasternal long-axis view of the aortic arch.

(Ao arch: aortic arch; Asc. Ao: ascending aorta; Dese. Ao: descending aorta; LCA: left carotid artery; LSCA: left subclavian artery)

JAYPEE BROTHERS

Most echocardiographers begin their examination from this view, everyone preferred this method to measure left ventricle cavity size, wall thickness and mainly used to estimate the ejection fraction. Put the M-mode cursor just below the MV tip. Remember, avoid this method if the M-mode cursor cannot be placed or aligned perpendicular but this method is not possible to obtain in every patient and unsuitable for the most clinical situations. Moreover, LVOT, aorta, sinus of Valsalva, sinotubular junction, LA, and RV measurement can be assessed from this view. MV and aortic valve can be judged morphologically also from this view. Right coronary cusp (RCC) of the aortic valve can see top toward the septum and non-coronary cusp (NCC) toward the base of anterior mitral leaflet (AML) of MV whereas AML and posterior mitral leaflet as A2 and P2 can see between the LA and LV. This view is also good to see pericardial effusion right anterior and posterior **(Fig. 16)**.

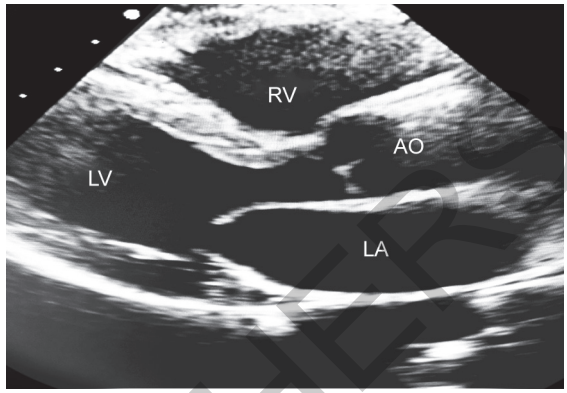

Fig. 16: Parasternal long axis view (PLAX) view with anatomical labels. Used for left ventricle (LV) size, wall thickness, left ventricular outflow tract (LVOT), aorta, left atrium (LA), right ventricle (RV), and valve morphology assessment.

Parasternal Short Axis View (at Aortic Level)

To obtain PSAX view to rotate the probe 90° clockwise they give you an impression of LA, IAS, RA, TV, RV, PV, aortic all cusps, and little adjust the probe to identify bifurcation of pulmonary artery (to obtain an optimal view not always easy).

What to Record?

- 2D images
- *Color flow*: Aortic, tricuspid, pulmonary valve, and sometimes inter atrial septum
- *Doppler*: Tricuspid and pulmonary valve

What Do You See?

Aortic valve: It lies in center with classic Y shape (in normal three cusps)—left coronary cusp (LCC) on right toward pulmonary valve, RCC toward the TV, and NCC can see bottom **(Figs. 17A and B)**.

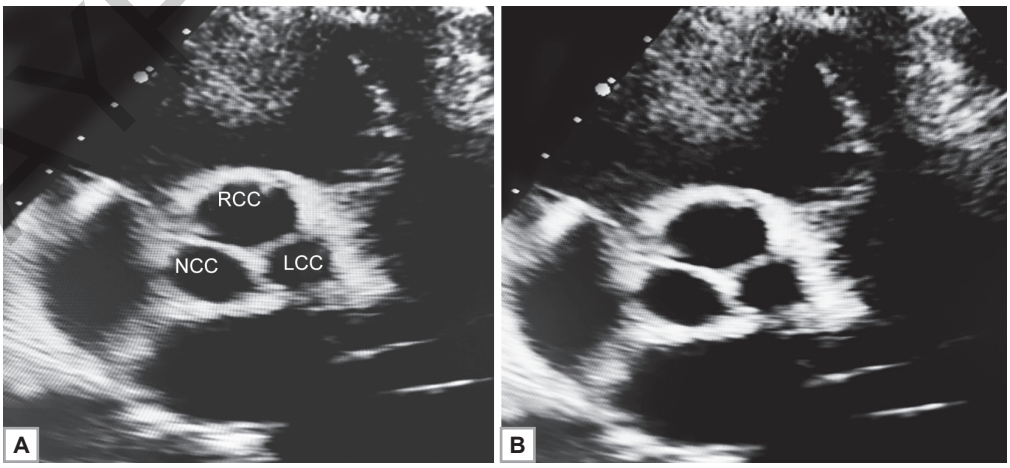

Figs. 17A and B: Parasternal short axis (PSAX) view at the aortic valve level. Shows the classic "Mercedes-Benz" pattern of atrioventricular (AV) cusps.

JAYPEE BROTHERS

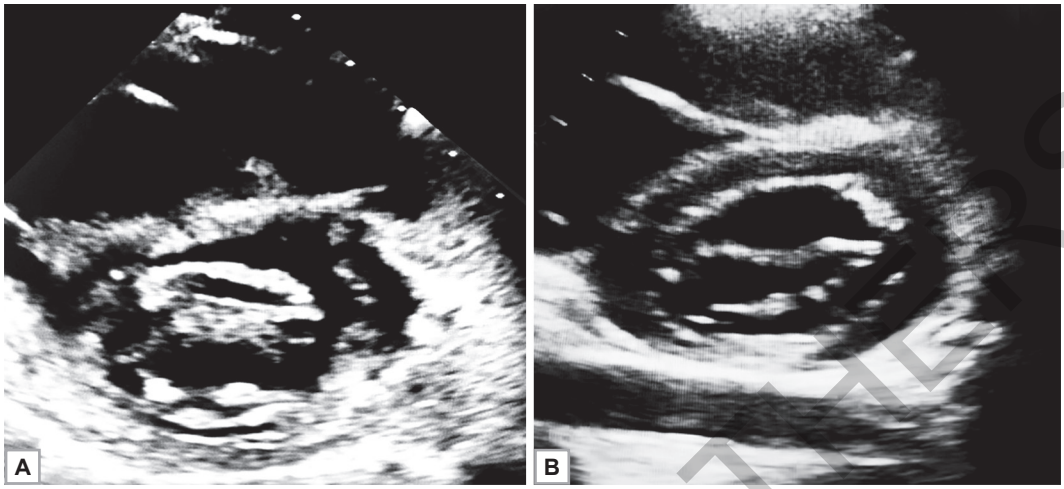

Figs. 18A and B: Fish-mouth appearance of mitral valve (MV) in parasternal short axis (PSAX). Used for MV planimetry and scallop identification (A1–A3, P1–P3).

Parasternal Short View (At Mitral Valve)

Fish mouth appearance of the MV from the PSAX aortic view to PSAX view of the MV rock the probe slightly toward the cardiac apex but not always easy to obtain with stenosis and thickened MV **(Figs. 18A and B)**.

What to Record?

- 2D images, consider 2D planimetry if stenosis lesion
- Consider color flow across MV if regurgitation
- All three scallops as A1, A2, A3, and P1, P2, P3 can be seen only in this view.

What Do You See?

Mainly used in the planimetry area of MV and morphology of leaflets.

Parasternal Short Axis (at Ventricle View)

To obtain the PSAX ventricular view, move the probe from the PSAX MV level slightly toward the apex until both papillary muscles become clearly visible.

This view is used to evaluate the mid left ventricular (LV) cavity, LV walls, and papillary muscles.

What to Record?

- *2D images* at the papillary muscle level for assessment of LV size and LV mass.
- *M-mode imaging* for measurement of left ventricular dimensions.
- *Speckle tracking imaging* for assessment of myocardial mechanics.

What Do You See?

Left ventricle: The short axis view displays the septal, anterior, lateral, and inferior walls in a clockwise orientation. It is useful for measuring LV size, assessing wall thickness, and evaluating regional function of the mid ventricular of the segments.

The RV appears superior to the anterior LV wall and can be assessed for size, systolic function, and overall hemodynamics **(Figs. 19A and B)**.

JAYPEE BROTHERS

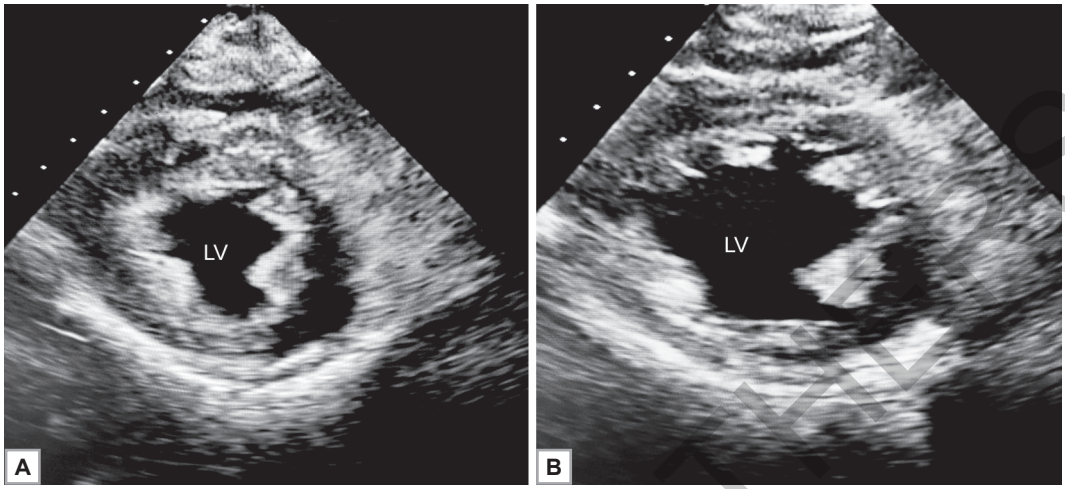

Figs. 19A and B: Parasternal short axis (PSAX) view at papillary muscle level. Used to assess mid-left ventricle (LV) cavity, walls, and papillary muscles.

Apical Four-chamber View

In the apical window, hold the probe with the indicator pointing toward there couch. Position the probe as close to the left ventricular (LV) apex as possible, after obtaining the image, adjust the focus to achieve the optimal LV size and shape. In a true apical view, the LV will appear at is its maximum length.

The optimal apical four-chamber image should include both ventricles, both atria and clear visualization of both the mitral and tricuspid valves. The interventricular septum aligned vertically in the center of the image.

What to Record?

- 2D image
- Color flow mapping
- CW and PW Doppler
- Consider the Doppler of the right upper pulmonary vein
- Consider tissue Doppler imaging of the right and left ventricle
- Speckle tracking

What Do You See?

- The A1, A2, and P2, scallops of the MV are visualized.
- 2D imaging is used to assess leaflet motion.
- Color flow mapping helps identify any mitral regurgitation.
- The Doppler sample volume should be placed accurately and aligned parallel to the direction of flow.
- Tissue Doppler imaging of the lateral and septal annulus is performed to evaluate diastolic function.
- *Tricuspid valve*: Lateral and septal leaflets displayed. Doppler and tissue Doppler are possible.
- Color flow mapping will show regurgitation.
- Tricuspid annulus phase systolic excursion (TAPSE) by M-mode to estimate systolic function.
- *Left and right atrium*: Both atria and inter-atrial septum can be seen. Pulmonary veins in LA and vena cava may be seen, used to measure atrial volume.
- *Left ventricle*: View to study global and regional LV function, septum, apex and lateral wall are displayed. Good to assess 2D volume if the endocardial border looks prominent. Qualitative assessment of left ventricle hypertrophy, hypertrophy cardiomyopathy, flail valve and parachute valve, not good view to assess prolapse valve.

JAYPEE BROTHERS

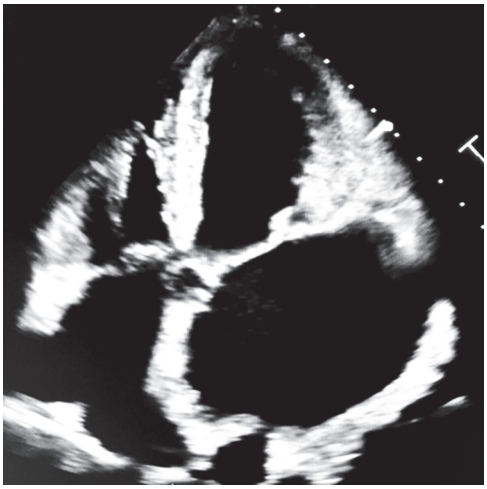

Fig. 20: Apical four-chamber view. Ideal for chamber evaluation, MV/TV assessment, diastology, tricuspid annular plane systolic excursion (TAPSE), and pulmonary veins.

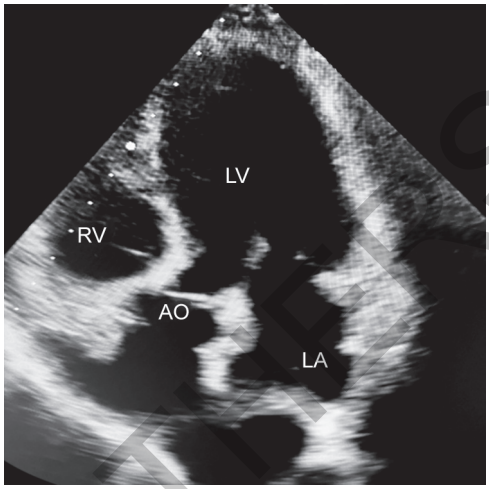

Fig. 21: Apical five-chamber view. Used to assess left ventricle outflow tract (LVOT), aortic valve, and Doppler alignment.

- *Right ventricle*: This view evaluates the size and function of the right ventricle. Assessment is often done in comparison with the left ventricle. Additionally, tissue Doppler imaging or M-mode of the tricuspid annular free wall can be used to measure RV systolic function more accurately.
- *Pericardium*: Important view to assess size and location of pericardial fluid **(Fig. 20)**.

Apical Five-chamber View

What to Record?

- 2D imaging
- Color flow mapping across the aortic valve
- CW and PW Doppler assessment of aortic valve and LVOT

What Do You See?

- *Aortic valve*: The right coronary and non-coronary cusps may be visualized, although they can be difficult to distinguish. Evaluate for the presence of aortic regurgitation using color Doppler.
- *Left ventricle outflow tract*: Apply color flow mapping to detect aortic regurgitation or any turbulent flow suggestive of LVOT obstruction **(Fig. 21)**.

Apical Two-chamber View

What to Record?

- 2D imaging
- Color flow and Doppler across the MV
- Tissue Doppler imaging

What Do You See?

Left ventricle: The inferior wall appears on the left side of the screen and the anterior wall on right. This view is valuable for assessing regional wall motion. It is also suitable for calculating left ventricular volumes and performing tissue Doppler measurements.

Mitral valve: The commissural typically displays the P3, A2, and P1 scallops from left to right, allowing accurate evaluation of leaflet motion and coaptation.

Left atrial appendage: Occasionally, the left atrial appendage can be seen, appearing as a thumb-like structure on the right side of the MV in this view **(Fig. 22)**.

JAYPEE BROTHERS

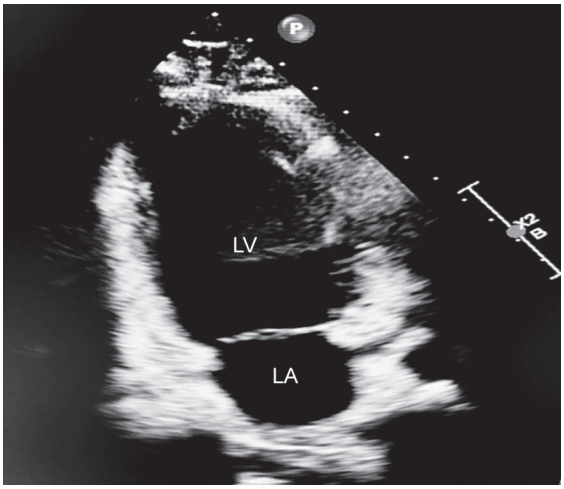

Fig. 22: Apical two-chamber view. Best for evaluating anterior and inferior walls and mitral valve (MV) commissural view.



Fig. 23: Apical three-chamber view. Also called left ventricle outflow tract (LVOT) or apical long axis view. Excellent for atrioventricular (AV) and mitral valve (MV) assessment.

Apical Three-chamber View

How to Obtain the View?

From the two-chamber view rotate the probe anticlockwise by approximately 135° until LVOT and aortic valve come into view.

What to Record?

- 2D image
- *Additional imaging consideration*: Tissue Doppler and speckle tracking imaging to evaluate left ventricular function.
- Color flow and Doppler measurements across aortic valve, provided the alignment is appropriate.
- Color flow and Doppler interrogation across the MV to assess for regurgitation.

What Do You See?

- *Left ventricle*: It provides an excellent view of the interventricular septum on the right side of the image, and the apex and inferolateral wall on the left side.
- *Aortic valve*: The RCC is visualized on the right, while the non-coronary cusp appears on the left side. Use color Doppler to evaluate aortic for regurgitation.
- *Mitral valve*: The A2 and P2 scallops of MV clearly seen. Color Doppler assesses mitral regurgitation.
- *Left atrium*: The left atrium is situated posterior to the MV **(Fig. 23)**.

Subcostal or Subxyphoid View

Very useful view to study of pericardial effusion, assess RV inflow and screens for septal defect also sometimes alternative window for parasternal view if PLAX view not possible. If it is difficult to get an image, ask a patient to take a deep breath in.

What to Record?

- 2D image
- *Color flow mapping*: Tricuspid and septa (atrial and ventricle)

What Do You See?

- *Right ventricle:* Both free wall and septum seen. Wall thickness can be measured with good alignment for color flow mapping of septal defects.
- *Right atrium:* Good view to look at the right ventricle inflow as close. May see Eustachian valve and entry of inferior vena cava and color flow mapping to see septal atrial defect.

JAYPEE BROTHERS

- *Tricuspid valve:* Can be used for color flow mapping of regurgitation.
- *Pericardium:* Excellent view to assess size and depth of effusion.
- *Left ventricle*: Septum and lateral wall seen.
- *Mitral valve:* Little extra information provided.
- *Left atrium:* Good view to find a thrombus **(Fig. 24)**.

Inferior Vena Cava View

From the subcostal position, rotate the probe anticlockwise. As you rotate, the inferior vena cava (IVC) should appear as a long, tubular structure running horizontally across the screen. If there is uncertainty about whether the structure is the aorta instead of the IVC, use color Doppler or PW Doppler. IVC shows low velocity venous flow. Aorta shows high velocity pulsatile arterial flow.

What to Record?

- 2D images during inspiration and expiration (five loops may be required)
- M-mode measurements with respiration
- PW Doppler assessment in a properly aligned hepatic vein, if needed

What Do You See?

- *Inferior vena cava*: It is used to assess diameter during inspiration and expiration for estimating right atrial pressure.
- *Liver and hepatic veins*: These structures drain into the inferior vena cava and may be used for Doppler assessment measure. If right atrial pressures are elevated, hepatic veins may appear dilated **(Fig. 25)**.

Abdominal Aorta

What to Record?

- 2D image
- Color flow mapping to identify

What Do You See?

Aorta may see aneurysm, dissection flap or plaque **(Fig. 26)**.

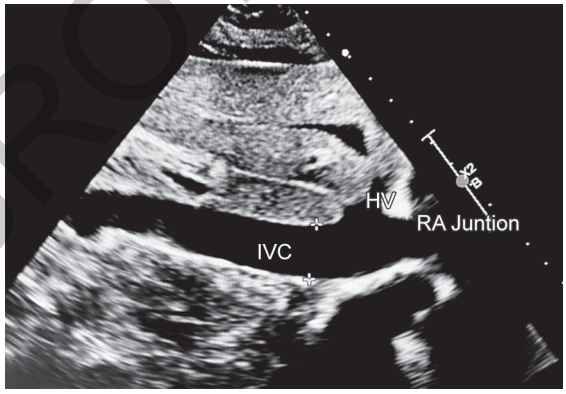

Fig. 25: Inferior vena cava (IVC) long-axis view. Used to estimate right atrium (RA) pressure by assessing IVC diameter and collapsibility.

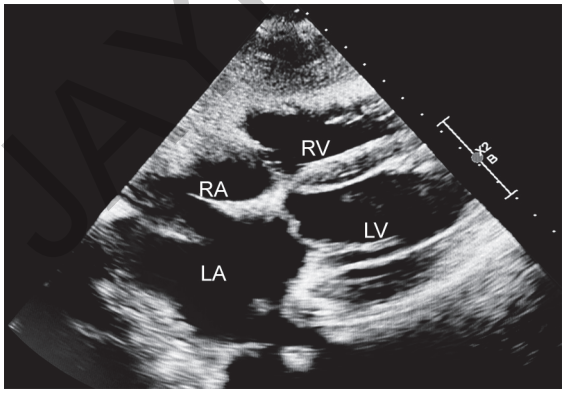

Fig. 24: Subcostal long-axis view. Useful for septal defect screening and pericardial effusion assessment.

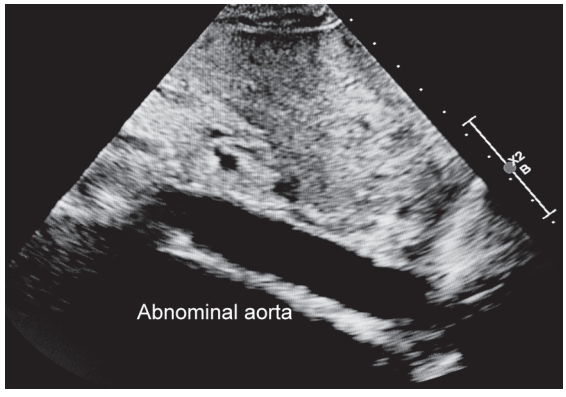

Fig. 26: Subcostal abdominal aorta view. Simple assessment for aneurysm or dissection.

JAYPEE BROTHERS

CONCLUSION

Accurate echocardiographic assessment depends on proper image acquisition, probe positioning, and correct Doppler alignment. 2D imaging provides structural clarity, M-mode offers precise measurements, and Doppler modalities quantify hemodynamics. Mastery of parasternal, apical, subcostal, and suprasternal windows forms the basis for routine and advanced echocardiography.

This chapter provides essential guidelines and figure-based explanations **(Figs. 1 to 26)** to help echocardiographers perform consistent, reproducible, and clinically meaningful cardiac evaluations.

JAYPEE BROTHERS

for detailed information on cardiology books, visit our website www.ejaypee.com, for detailed information on cardiology books, visit our website www.ejaypee.co

ECHOCARDIOGRAPHY SIMPLIFIED
A PRACTICAL APPROACH

Salient Features

- Simplified explanation of echocardiography fundamentals
- Designed especially for beginners, students, and clinicians
- Practical, clinically oriented approach
- Step-by-step understanding of key echocardiographic concepts
- Real-world insights from 12 years of clinical experience
- Clear and structured presentation



Keshav Sharma is an experienced Cardiac Sonographer with over a decade of hands-on expertise in noninvasive cardiology, specializing in echocardiography. A graduate in Cardiac Care Technology, he is deeply passionate about cardiac imaging and education. His practical clinical experience and commitment to teaching inspired him to write this book to simplify echocardiography for beginners, students, and clinicians, helping them build strong fundamentals with confidence.

Buy from ejaypee

JAYPEE BROTHERS

Shelving Recommendation
CARDIOLOGY

ISBN 978-93-7545-283-6