ailed information on obstetrics & gynecology books, visit our website www.ejaypee.com, for detailed information on obstetrics & gynecology books, visit our website www.ejaypee.com

Obstetrics & Gynecology

VOLUME 15

Dasgupta's Recent Advances in Obstetrics and Gynecology

Editor
Nandita Palshetkar

Co-Editors
Pratik Tambe
Rohan Palshetkar

JAYPEE

Contents

1. Preconception Care..... 1
Mrinalini, Ashok Kumar
- Components of Comprehensive Preconception Care *2*
- Evidence-Based Benefits of Preconception Care *4*
- Barriers to Effective Preconception Care Implementation *5*
- Emerging Trends and Future Directions in Preconception Care *6*
- Antenatal care *7*

2. Thyroid Disorders in Pregnancy 10
Durga Shankar Dash, G Prasanna
- Physiological changes in thyroid during pregnancy *10*
- Thyroid disorders in pregnancy *11*
- Current Investigations protocols *11*
- Hyperthyroidism *12*
- Postpartum thyroiditis *14*
- Hypothyroidism *14*

3. Newer Methodology Induction of Labor 19
Parag Biniwale, Archana Dwivedi
- Definition *19*
- Statistics *20*
- Indications *20*
- Contraindications *21*
- Preinduction Assessment *22*
- Prediction of Successful Induction *23*
- Methods *23*
- Nonpharmacological Methods *24*
- Mechanical Methods *24*
- Regimens for Cervical Ripening *25*
- Stripping of Membranes/Hamilton Maneuver *27*
- Maternal Observations for any type of Induction of Labor *27*
- Induction of labor: Newer Insights *29*

4. Current Management of Hyperglycemia in Pregnancy 34
Charmila Ayyavoo, Jayam Kannan
- Classification *34*
- Management of Gestational Diabetes Mellitus *34*
- Medical Therapy in Gestational Diabetes Mellitus *35*
- Diabetes in pregnancy *36*
- Postpartum care *37*

5. Modern Algorithm for Obesity Management 39
Pratik Tambe, Deepti Gupta
- Implications of Obesity *39*
- Indian Society of Assisted Reproduction Obesity Algorithm 2024 *39*
- Caution and Caveats *47*

6. Implications of Newborn Screening 50
Shamik Ghosh, Biswajyoti Guha
- Metabolic Disorders *50*
- Endocrine Disorders 50
- Hemoglobin Disorders *50*
- Cystic Fibrosis *51*
- Immune System Disorders *51*
- Hearing Loss *51*
- Critical Congenital Heart Defects *51*
- Other Rare Conditions (In Expanded Screening Panels) *51*
- Conclusion *51*
- Newborn Screening Programs in India *51*
- Implications of Newborn Screening *53*

7. Modern Guidelines for Postpartum Hemorrhage Management ... 58
Sheela Mane
- Definition and Classification of Postpartum Hemorrhage *58*
- Enhanced Assessment and Early Detection *59*
- Updated Prevention Strategy with Active Management of the Third Stage of Labor *59*
- Bundle-based Therapeutic Response *60*
- Inclusion of Tranexamic Acid *61*
- Mechanical and Nonsurgical Interventions *61*
- Sequential Escalation: Innovations in Surgical Management *62*
- Advanced Resuscitation and Massive Transfusion Protocols *63*
- Indian Adaptations and Federation of Obstetric and Gynecological Societies of India Updates *64*

8. Cervical Cancer Vaccination 70
Krishnendu Gupta, Pratik Tambe
- Human Papillomavirus and Cervical Cancer Link *70*
- World Health Organization Strategy *70*
- Available Vaccines *71*
- Efficacy Data *71*
- Recommended Schedules *72*
- Safety Profile *72*
- Global Impact *72*
- Current Status of Vaccination in India *72*
- Other Challenges *72*
- Expert Review *73*
- Initial Limited Rollout *73*
- Single Dose Vaccine *74*
- Future Directions *75*

9. Robotics in Gynecology 77
Aswath Kumar, Shameema Anvarsadath, Megha Jayaprakash
- Training and Credentialing *77*
- Robotic Systems and Instrumentation *78*
- Patient Positioning and Safety Considerations *83*
- Port Placement and Docking *84*
- Robotic Laparoendoscopic Single-site Surgery *85*
- Additional Applications of Robotic Surgery *88*
- Robotic Surgery in Infertility Practice *89*
- Assisted Reproductive Technology *91*
- Male Infertility Applications *91*
- Artificial Intelligence in Robotic Surgery *92*
- Complications of Robotic Surgery *92*
- Advantages and Limitations *92*

10. Oral Gonadotropin-releasing Hormone Antagonists 96
Rohan Palshetkar, Nandita Palshetkar
- Mechanism of Action and Pharmacology *96*
- Major Oral Gonadotropin-releasing Hormone Antagonists *96*
- Clinical Applications *97*
- Dosing Regimens *98*
- Safety and Monitoring *98*
- Comparison with Other Therapies *98*
- Evidence Summary *98*

11. Ovulation Induction Regimen with Letrozole 100
Sadhana Gupta, Ayushi Agrawal Gupta
- Letrozole: Evolution of Drug as Ovulation Induction Agent *100*
- Pharmacokinetics of Letrozole *100*
- Letrozole versus Clomiphene Citrate as Ovulation Induction Agent *101*
- Letrozole Use in Different Etiologies of Female Infertility *102*
- Assisted Reproductive Technology *102*
- Dosage of Letrozole *103*
- Current Evidence for Role and Place of Letrozole in Female Infertility *104*
- Safety of Letrozole *105*
- Key Points 106

12. Fertility-enhancing Laparoscopic Surgeries 110
Bhaskar Pal, Subash Mallya
- Laparoscopic Management of Endometriosis *110*
- Laparoscopic Management of Tubal Factor Infertility *111*
- Laparoscopic Myomectomy and Fertility *111*
- Laparoscopic Treatment of Benign Ovarian Cysts *112*
- Severe Adhesions 112

13. Dienogest for Management of Endometriosis 114
T Ramani Devi
- Pharmacology and Mechanism of Action *114*

- Clinical Efficacy in Pain Reduction *114*
- Effect on Endometrioma Size *115*
- Bleeding Pattern and Quality of Life *115*
- Comparison with Medroxyprogesterone Acetate *115*
- Safety and Long-term Use *115*

14 Laparoscopic Morcellation: Alternatives 117
Parul Kotdawala, Mala Raj
- Contained Power Morcellation *117*
- In-bag Extracorporeal Manual Morcellation *118*
- Transvaginal Contained Morcellation *118*
- Mini-laparotomy or Intact Extraction 118

15. Pre-assisted Reproductive Technology Hysteroscopy.....120
Rohan Palshetkar
- Concept and Rationale *120*
- Indications *120*
- Common Intrauterine Abnormalities *121*
- Evidence Supporting Selective Pre-ART Hysteroscopy *121*
- Therapeutic Interventions *122*
- Complications *122*

16. Management of Thin Endometrium 124
Sonia Malik
- Definition *124*
- Etiology *124*
- Pathophysiology *125*
- Diagnostic Work-up *126*
- Management Strategy *126*
- Practical Clinical Approach *128*

17. Stem Cell Therapy in Assisted Reproductive Technology 130
Nandita Palshetkar, Prabhu Chandra Mishra
- Types of Stem Cells Investigated in Assisted Reproductive Technology *130*
- Mechanisms of Action *131*
- Applications in Female Infertility *131*
- Applications in Male Infertility *132*
- Safety, Limitations, and Ethical Considerations *132*

18. Stepwise Devascularization 134
S Sampathkumari
- Anatomical Basis *134*
- Indications *134*
- Principles of Stepwise Devascularization *134*
- Surgical Steps *135*
- Outcomes and Fertility Considerations *135*

19. Cesarean Scar Ectopic Pregnancy 137
Ashok Kumar
- Pathophysiology *137*
- Classification *137*
- Risk Factors *138*
- Clinical Presentation *138*
- Diagnosis *138*
- Complications *139*
- Management *139*
- Cesarean Scar Ectopic Pregnancy in Assisted Reproductive Technology Practice *140*
- Prognosis and Recurrence *140*

Index 143

CHAPTER 9

Robotics in Gynecology

Aswath Kumar, Shameema Anvarsadath, Megha Jayaprakash

INTRODUCTION

The concept of automated machines replacing human labor dates back to ancient philosophy, with Aristotle speculating about mechanized substitutes for human work. Early forms of automation were documented as far back as the 12th and 13th centuries. In 1495, Leonardo da Vinci conceptualized a humanoid mechanical figure, often regarded as a precursor to modern robotic design.[1]

The term *robot* originates from the Czech word *robota*, meaning forced labor or service, popularized by Karel Čapek in his 1921 play *Rossum's Universal Robots*. The discipline of *robotics* was later defined by Isaac Asimov in his 1942 short story *Runaround*.

Modern robotic development advanced with the creation of the first robotic arm at Rancho Los Amigos Hospital in California. Foundational research from Stanford University and the Stanford Artificial Intelligence Laboratory significantly influenced industrial robotic systems. A landmark development was Dr John Adler's application of robotics in stereotactic neurosurgery (CyberKnife) in 1997.[2]

In 2000, Intuitive Surgical introduced the da Vinci robotic surgical system, which subsequently received FDA approval. Since then, robotic technology has continued to evolve, incorporating artificial intelligence, three-dimensional visualization, nanotechnology, and enhanced microsurgical precision.

TRAINING AND CREDENTIALING

Formalized training frameworks for robotic surgery were established in 2007 by the Society of American Gastrointestinal and Endoscopic Surgeons (SAGES) in collaboration with the Minimally Invasive Robotic Association (MIRA). Robotic platforms equipped with dual consoles enable structured training, simulation, and rehearsal of patient-specific procedures, thereby reducing complication rates and shortening learning curves.[3]

The European Board and College of Obstetrics and Gynecology (EBCOG) has outlined detailed standards for robotic surgical practice, emphasizing comprehensive theoretical and practical training for all operating room

JAYPEE BROTHERS

personnel. Initial cases require direct supervision by experienced robotic surgeons, with continued indirect supervision. Indirect supervision should be done for at least the first 10 simple (ESGE Level 1-3) and 20 complex (ESGE Level 4) cases per surgeon.[4]

Virtual reality simulators such as dV-Trainer®, da Vinci Skills Simulator®, and ProMIS® allow surgeons to develop proficiency in specific robotic skills. The Society of European Robotic Gynecological Surgery (SERGS) is actively developing standardized curricula for safe robotic-assisted gynecological surgery.

ROBOTIC SYSTEMS AND INSTRUMENTATION

The da Vinci robotic system, approved in 2000, remains the most widely used platform, with multiple iterations including Standard, S, Si, X, Xi, and SP models. The Xi system, introduced in 2014, offers enhanced flexibility, overhead arm architecture, and improved access to both pelvic and upper abdominal fields without repositioning the patient cart.

The system comprises three primary components: (1) The surgeon console, (2) patient-side cart, and (3) vision cart. The surgeon console provides a high-definition, three-dimensional magnified view of the operative field and allows intuitive control of EndoWrist instruments using master controllers and foot pedals. Dual-console functionality facilitates collaborative surgery and training **(Figs. 1 to 4)**.

The patient cart **(Figs. 5 to 7)** houses robotic arms that articulate around fixed pivot points, ensuring stability and safety. The vision cart **(Fig. 8)** contains image processing equipment, illumination systems, and monitors that deliver up to 10× magnified stereoscopic images **(Fig. 9)**.



Fig. 1: Surgeon's console.

JAYPEE BROTHERS



Fig. 2: Surgeon working on the console.



Fig. 3: Master controllers.



Fig. 4: Foot switch panel.

JAYPEE BROTHERS



Fig. 5: Patient cart.



Fig. 6: Robotic arms.

EndoWrist instruments, measuring 8 mm in diameter, offer seven degrees of freedom, surpassing the range of motion of the human wrist. The system automatically tracks instrument usage and functionality, enhancing safety and efficiency **(Figs. 10 to 12)**.

The latest model (Xi) is similar in many aspects to the Si model. Main differences are:

- It has an overhead system to allow all the arms to move together.
- The overhead arms are lightweight and easier to maneuver.

JAYPEE BROTHERS



Fig. 7: Patient cart with draped arms.



Fig. 8: Vision cart and robotic assistant.

- As all the trocars are placed in a straight line at or above the umbilicus, operations in pelvis and upper abdomen can be done without moving the patient cart.
- As the endoscope trocar is 8 mm in Xi, it can be introduced through any port.

JAYPEE BROTHERS



Fig. 9: Overall view in the OR.



Figs. 10A and B: Dexterity of robotic instruments.

- The camera and endoscope are targeted to the surgical field by a laser targeting system and the other arms are targeted automatically to get best possible spatial orientation by pressing targeting button (semiautomated docking).
- Xi system allows rotation of the robotic arms after undocking them from the pelvic position without the need to rotate the operating table. Once the arms are rotated 180°, they can be docked again to access upper abdomen or aortic field.

Firefly® fluorescence imaging, available in Si and Xi models, utilizes near-infrared technology and indocyanine green (ICG) dye to enhance visualization of vascular and lymphatic structures. This technology is particularly useful in oncological and complex pelvic surgeries.

JAYPEE BROTHERS



Figs. 11A and B: Robotic instruments.



Fig. 12: Robotic ports with cannula and instruments.

PATIENT POSITIONING AND SAFETY CONSIDERATIONS

Robotic pelvic procedures typically require steep Trendelenburg positioning with dorsal lithotomy. Place the patient in such a way that the buttocks reach the edge of the table and the sacrum has padded support. Use padded stirrups to support the ankle and foot. The thighs should be at the level of the

JAYPEE BROTHERS

table. The hip flexion should be between 60 and 170°, hip abduction <90°, and knee flexion between 90 and 120°.[5] Prolonged positioning may result in complications such as corneal abrasions, airway edema, cerebral edema, ischemic optic neuropathy, and peripheral nerve injuries.[6-9]

Careful attention to patient positioning is essential to prevent nerve compression injuries, particularly involving the brachial plexus and lower extremity nerves. Preventive strategies include the use of anti-slip materials, proper padding, correct limb alignment, and secure arm positioning.

PORT PLACEMENT AND DOCKING

Port placement varies between da Vinci Si and Xi systems. The Si model typically uses a central 12-mm optical port with lateral robotic ports placed approximately 10 cm apart. The Xi system allows linear port placement with 8-mm trocars, facilitating multiquadrant access.

The endoscope is introduced through a Visiport at the umbilicus or above it. The other metal trocars 8 mm diameter can be inserted under direct vision at a distance of 8–10 cm from one another and from the camera trocar to enable easy docking and to prevent collision. In cases where adhesions are expected, entry is done through the Palmer's point **(Figs. 13A and B)**.[10]

Docking involves attaching robotic arms to trocars after port placement, commonly performed via side docking for pelvic procedures. Once all the ports are in place, the robotic arms are attached to the ports **(Fig. 14)**.

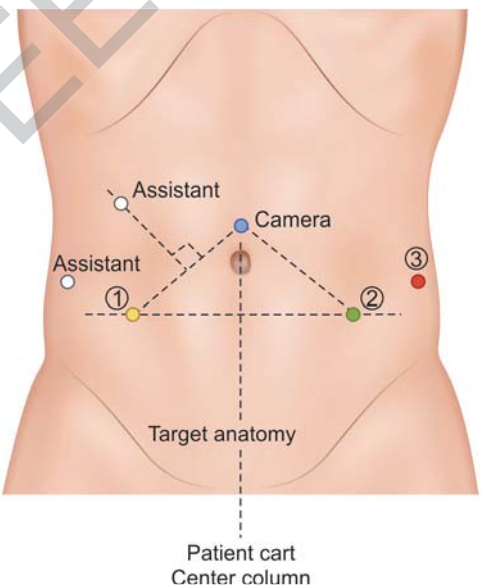

Fig. 13A

JAYPEE BROTHERS

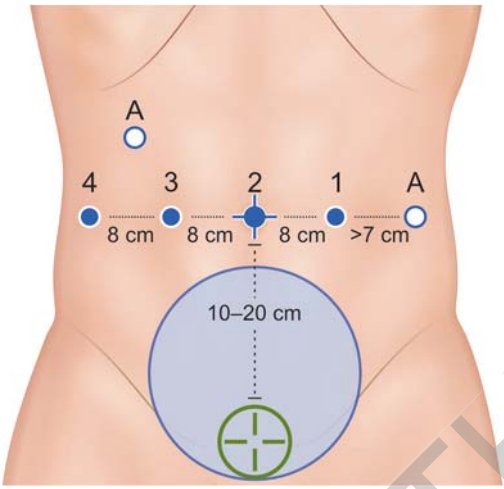

Fig. 13B

Figs. 13A and B: (A) Recommended port positions in DaVinci Si system and (B) Recommended port positions in Davinci Xi system.



Fig. 14: After docking the robot.

ROBOTIC LAPAROENDOSCOPIC SINGLE-SITE SURGERY

This is a new form of MIS (minimally invasive surgery) where single incision laparoscopic surgery equipment is used along with advanced robotic technology.[11]

It overcomes some of the obstacles faced in laparoendoscopic single-site surgery (LESS) like lack of triangulation and collision between instruments while preserving the advantages of SILS (single incision laparoscopic surgery) or SPA (single port access) like less vessel injuries, less hematomas and infections, better cosmesis, less pain, and less hospital stay.

JAYPEE BROTHERS

Single-site robotic surgery utilizes a multichannel umbilical port, offering improved cosmesis but requiring meticulous closure to minimize hernia risk.

Robotic Simple Hysterectomy

The first robot-assisted hysterectomy was described in 2001, followed by approval of the da Vinci® Surgical System by the US Food and Drug Administration in 2005.[12]

Advantages of Robotic Surgery

Compared with conventional laparoscopy, robotic surgery offers several advantages, including a surgeon-controlled stable camera platform, improved ergonomics, three-dimensional visualization, tremor filtration, and enhanced instrument dexterity. The intuitive alignment of instrument movement with the surgeon's hand motions improves precision. Additional benefits include the availability of a dual-console system that facilitates collaboration and surgical training, as well as a relatively shorter learning curve.

Overall, robotic surgery is associated with reduced hospital stay, lower transfusion requirements, minimal perioperative complications, and decreased conversion rates to laparotomy. It is particularly advantageous in obese and morbidly obese patients, where conventional laparoscopy may be technically challenging.[13] Limitations of robotic surgery include the absence of tactile (haptic) feedback, physical separation of the surgeon from the patient, and higher procedural costs.

Eligibility

The majority of patients are suitable candidates for robotic surgery unless limited by significant medical comorbidities. There are no absolute contraindications specific to the robotic approach.

Preoperative Preparation and Surgical Technique

Following appropriate patient positioning, a uterine manipulator and indwelling urinary catheter are placed.

Pneumoperitoneum is established using carbon dioxide at a pressure of approximately 15–20 mm Hg, either using a Veress needle or by an open (Hasson) method. Port placement follows, with the camera port positioned 8–10 cm cephalad to the uterine fundus. After a complete abdominal survey, the remaining ports are introduced under direct visualization, and the robotic system is docked.

Typically, two 8-mm robotic ports and one assistant laparoscopic port are used. Monopolar scissors are placed through the right paraumbilical port, bipolar forceps through the left pelvic port, and a robotic grasper (ProGrasp™) through the right pelvic port. A fourth robotic arm may be employed in

JAYPEE BROTHERS

complex cases. The patient must be placed in a deep Trendelenburg position prior to docking, as repositioning is not possible once docking is complete.

After elevating the uterus, the ureters are identified bilaterally. The round ligaments are coagulated and divided **(Fig. 15)**. If adnexectomy is planned, the posterior leaf of the broad ligament is incised, and the infundibulopelvic ligament is isolated, coagulated, and transected. The uterovesical fold is developed by incising the anterior leaf of the broad ligament, with countertraction provided by the fourth robotic arm if required.

The uterine vessels are skeletonized, coagulated, and divided following posterior peritoneal incision down to the level of the uterosacral ligaments. The uterine manipulator is advanced to elevate the cervix, and colpotomy is performed, allowing removal of the specimen **(Fig. 16)**. Vaginal cuff closure is

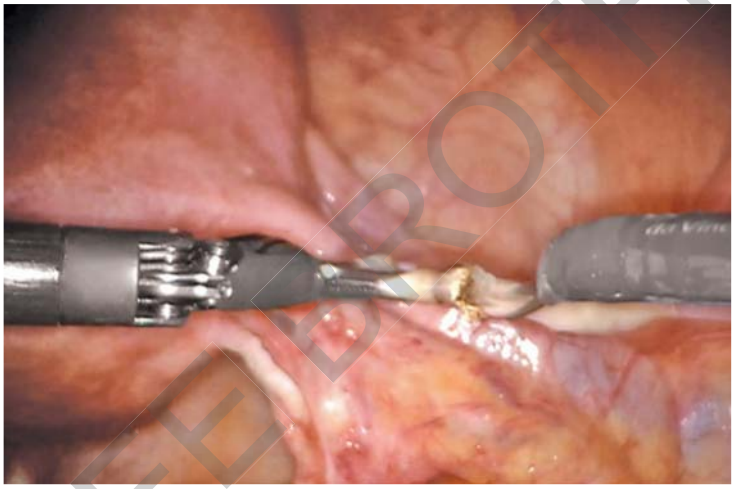

Fig. 15: Division of round ligaments.

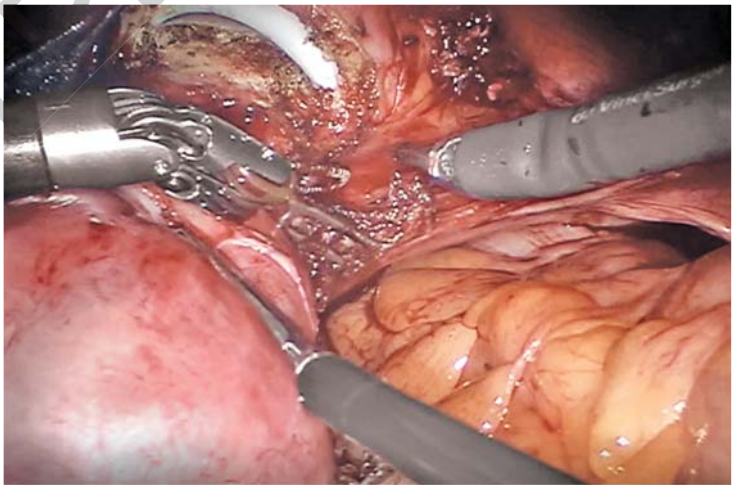

Fig. 16: Opening of vault.

JAYPEE BROTHERS

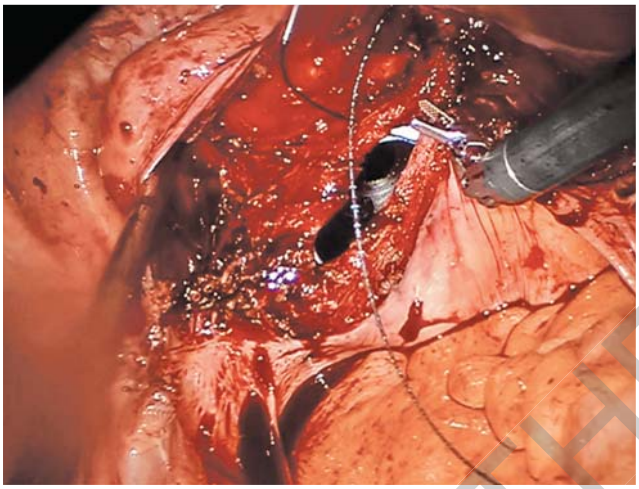

Fig. 17: Intracorporeal suturing of vault.

usually achieved using a barbed suture **(Fig. 17)**. After ensuring hemostasis, instruments are withdrawn, the robot is undocked, and all ports are removed under vision. Fascial closure of the rectus sheath is performed at the camera and assistant port sites.

Postoperative Care

Oral intake may be initiated on the day of surgery once the patient is stable for 4–6 hours. The urinary catheter is typically removed on the first postoperative day, and patients may be discharged the same day. Abstinence from sexual intercourse is advised for a minimum of 6 weeks to reduce the risk of vaginal cuff dehiscence or evisceration.

ADDITIONAL APPLICATIONS OF ROBOTIC SURGERY

Beyond benign indications for hysterectomy, the enhanced magnification and visualization afforded by robotic platforms allow comprehensive evaluation and management of both genital and extragenital endometriosis. Robotic tubal reanastomosis (sterilization reversal) demonstrates pregnancy outcomes comparable to those achieved with in vitro fertilization. Robotic sigmoid vaginoplasty for vaginal agenesis avoids laparotomy or laparoscopic stapling and reduces anastomotic complications.

The first robotic Type III radical hysterectomy with pelvic lymph node dissection for cervical cancer was reported by Sert and Abeler in 2006.[14] Sentinel lymph node mapping for cervical and endometrial cancers can be effectively performed using robotic assistance. The robotic platform's superior ergonomics, dexterity, magnification, and shorter learning curve make it particularly well suited for pelvic lymphadenectomy. Following completion

JAYPEE BROTHERS

of lateral, medial, and deep dissections, lymphatic tissue is retrieved using an Endo bag through the laparoscopic port or vaginal vault if hysterectomy has been performed.

For para-aortic lymphadenectomy, port placement is similar to that used for pelvic lymphadenectomy. When combining para-aortic dissection up to the renal veins with pelvic surgery using the da Vinci® S or Si systems, patient rotation by 180° after undocking is required before redocking over the shoulders. In contrast, with the da Vinci® Xi system, only robotic arm repositioning is necessary, eliminating the need for patient rotation.

Magrina et al. compared outcomes in 67 patients undergoing robotic-assisted staging for endometrial cancer with matched cohorts undergoing conventional laparoscopy ($n = 37$), vaginal hysterectomy with laparoscopic nodal dissection ($n = 47$), and laparotomy ($n = 99$). No significant differences were observed in the number of para-aortic lymph nodes retrieved ($p = 0.56$) or recurrence rates ($p = 0.16$) across the four groups.[15] Similarly, 3-year disease-free survival (83.2% vs. 88.4%; $p > 0.05$) and overall survival rates (93.3% vs. 93.6%; $p > 0.05$) were comparable between robotic-assisted and conventional laparoscopic staging approaches.[16]

In another study, Magrina et al. evaluated surgical and oncologic outcomes in 76 women with advanced-stage ovarian cancer treated by robotic surgery (25 cases), laparoscopy (27 cases), or laparotomy (119 cases). Robotic and laparoscopic approaches were favored over laparotomy for patients requiring Type I and II debulking, although robotic procedures had longer operative times. Laparotomy remained preferable for patients requiring Type III debulking. Overall survival was influenced by the completeness of cytoreduction rather than the surgical approach employed.[17]

Robot-assisted laparoscopic trachelectomy was first reported in 2008 and has since been demonstrated to be safe, precise, and reproducible. Approximately 100 cases have been documented in the literature, with oncologic outcomes comparable to those achieved using alternative surgical techniques.[18,19]

Robotic approaches are also widely used for sacrocolpopexy and high uterosacral ligament suspension in the management of pelvic organ prolapse.

ROBOTIC SURGERY IN INFERTILITY PRACTICE

Robotic-assisted surgery has become an important modality in managing infertility-related conditions requiring meticulous dissection and suturing in anatomically complex areas. Procedures such as myomectomy, endometriosis excision, tubal reanastomosis, isthmocele repair, abdominal cerclage, and fertility-preserving oncologic surgeries benefit from enhanced visualization and precision.

JAYPEE BROTHERS

Myomectomy

In 2004, Advincula et al. described the first case series of robot-assisted laparoscopic myomectomy (RALM), and subsequent studies have established its safety and efficacy.[20-23] Robotic-assisted myomectomy facilitates complex suturing and precise dissection, particularly in large or posterior fibroids. Studies demonstrate reduced blood loss, shorter hospitalization, and comparable fertility outcomes when compared with open and conventional laparoscopic approaches, albeit with longer operative times and higher costs.[24,25]

Endometriosis

Advanced-stage endometriosis may benefit from robotic assistance due to superior visualization and dexterity. LAROSE trial, which was a multicenter, randomized, controlled trial, failed to demonstrate improved perioperative outcomes between robotic and conventional laparoscopy.[26] Though many studies showed robotic approach is better in stages III and IV, it was found to have no extra benefit in stag 1 and 2.[27] Some retrospective studies reported good outcomes compared to conventional surgery in resection of endometriosis involving bowel, bladder, and ureters[28] and in removal of hypogastric plexus.

Tubal Reanastomosis

Robotic microsurgical tubal anastomosis provides magnification comparable to microsurgical techniques, allowing precise handling and suturing of fallopian tubes with outcomes similar to open surgery.[29,30]

Isthmocele and Cesarean Scar Pregnancy

Robotic repair of isthmocele has shown promising results in improving myometrial thickness, reducing symptoms, and restoring fertility. Among 20 patients with infertility, 15 became pregnant and 14 had full-term live births. Among the nine patients who had surgery for disabling symptoms, five had no persistent symptoms, three reported global improvement, and one failed to improve.[31] Combined hysteroscopic and near-infrared-guided techniques further enhance precision.[32] Robotic approaches have also been successfully applied in selected cases of cesarean scar pregnancy.[33,34]

Abdominal Cerclage

Robot-assisted cervical cerclage (RACC), performed either during pregnancy or as an interval procedure, has reported success rates exceeding 85%. It offers obstetric outcomes comparable to laparotomy, with reduced surgical morbidity. Emerging techniques, including intraoperative ultrasound guidance, continue to refine this approach.[35]

JAYPEE BROTHERS

Fertility Preservation

Robotic technology has expanded fertility preservation options in gynecologic oncology and assisted reproductive medicine. Robot-assisted radical trachelectomy with pelvic lymphadenectomy is a well-established fertility-sparing procedure for selected patients with early-stage cervical cancer. Ovarian transposition performed prior to pelvic radiotherapy, particularly when combined with oncologic surgery, effectively reduces the risk of treatment-induced premature ovarian insufficiency and benefits from the precision and ergonomics of robotic assistance.[36]

Ovarian tissue transplantation, although still considered experimental in prepubertal patients, offers a fertility preservation strategy for individuals unable to delay gonadotoxic therapy. Robot-assisted orthotopic transplantation using extracellular matrix scaffolds has been described, allowing rapid revascularization without vascular reanastomosis and potentially improving graft survival through enhanced visualization and surgical dexterity.[37]

ASSISTED REPRODUCTIVE TECHNOLOGY

In assisted reproductive technologies, the integration of robotics and artificial intelligence has addressed several limitations of conventional approaches, including procedural variability, high dependence on operator expertise, and inefficiencies in laboratory workflows. Robotic systems have demonstrated potential in automating embryo culture, monitoring, cryopreservation, sperm selection, intracytoplasmic sperm injection, and oocyte denudation, thereby improving standardization, reducing errors, and enhancing clinical outcomes. Collectively, these advancements highlight the growing role of robotic and AI-assisted platforms in improving the effectiveness, safety, and accessibility of fertility preservation and assisted reproduction.

MALE INFERTILITY APPLICATIONS

The incorporation of robotic assistance subinguinal microsurgical varicocelectomy has been shown to achieve comparable clinical outcomes while offering additional advantages such as the absence of reported complications and a significantly reduced operative duration.[38] The robotic platform also facilitates real-time intraoperative use of a micro-Doppler ultrasonography probe, enhancing vascular identification and preservation. In a study by McCullough et al., patients undergoing robotic-assisted varicocelectomy demonstrated significant improvements at 3 months of follow-up, including increases in median total and free testosterone levels, sperm concentration, and testicular volume.[39]

Testicular sperm extraction (TESE) remains the gold-standard surgical technique for sperm retrieval in men with nonobstructive azoospermia

JAYPEE BROTHERS

secondary to primary testicular failure. Microsurgical TESE (mTESE), performed under high magnification using an operating microscope, yields sperm retrieval rates approximately 1.5 times higher than those achieved with conventional TESE. Parekattil and Gudeloglu reported their experience with 12 robot-assisted TESE (ROTESE) procedures performed between 2009 and 2012, with no perioperative complications. They noted improved ease of tissue handling and dissection, as well as enhanced surgeon ergonomics, when robotic assistance was utilized.[40]

Beyond sperm retrieval, robotic-assisted microsurgery has shown encouraging results in other procedures for male infertility, such as vasectomy reversal. Reported benefits include shorter operative times, setup durations comparable to conventional microsurgical techniques, and reduced dependence on a highly skilled microsurgical assistant, owing to the availability of an additional robotic arm.[41]

ARTIFICIAL INTELLIGENCE IN ROBOTIC SURGERY

Artificial intelligence is poised to further transform robotic surgery by enabling data-driven surgical planning, real-time intraoperative decision-making, and automated execution of repetitive tasks. AI-enhanced simulation platforms offer realistic, risk-free training environments. Ethical, legal, and regulatory considerations regarding data security, accountability, and validation remain critical as AI integration advances.[42]

COMPLICATIONS OF ROBOTIC SURGERY

The rate of complications possibly related to robotic-specific risk factors is low. Most early publications on robotic surgery showed a complication rate similar to laparoscopic surgery.

However, in addition to facilitating the performance of gynecological surgery in complex procedures and high-risk patients, recent studies have shown a potential of better perioperative outcome following robotic surgery even in low-risk patients when performed by highly trained surgeons.

ADVANTAGES AND LIMITATIONS

Advantages

- Superior 3D visualization and instrument dexterity
- Reduced blood loss, postoperative pain, and recovery time
- Improved ergonomics and precision

Limitations

- High capital and maintenance costs
- Longer operative times during early learning phases
- Limited availability in low-resource settings

JAYPEE BROTHERS

CONCLUSION

Robotic-assisted surgery represents a significant advancement in gynecological and reproductive surgery, offering clear benefits over open surgery and selected advantages over conventional laparoscopy. While cost and training requirements remain challenges, ongoing technological advancements and integration of AI are expected to improve efficiency, accessibility, and outcomes. As experience grows and costs decline, robotic surgery is likely to become an increasingly integral component of modern gynecological practice.

REFERENCES

1. Pasek A. Renaissance robotics: Leonardo da Vinci's lost knight and enlivened materiality. Grad J Vis Mater Cult. 2014;7:1-25.
2. Adler JR Jr, Chang SD, Murphy MJ, Doty J, Geis P, Hancock SL. The Cyberknife: a frameless robotic system for radiosurgery. Stereotact Funct Neurosurg.1997;69:124-8.
3. Herron DM, Marohn M, SAGES-MIRA Robotic Surgery Consensus Group. A consensus document on robotic surgery. Surg Endosc. 2008;22:313-25.
4. EBCOG. (2014). Standards of care for women's health in Europe. [online] Available from https://eeca.unfpa.org/sites/default/files/pub-pdf/Standards%20of%20Care%20for%20Gynaecology%20Services.pdf. [Last accessed December, 2025]
5. Barnett JC, Hurd WW, Rogers RM Jr, Williams NL, Shapiro SA. Laparoscopic positioning and nerve injuries. J Minim Invasive Gynecol. 2007;14(5):664-72.
6. Gainsburg DM. Anesthetic concerns for robotic-assisted laparoscopic radical prostatectomy. Minerva Anestesiol. 2012;78(5):596-604.
7. Warner MA, Martin JT, Schroeder DR, Offord KP, Chute CG. Lower extremity motor neuropathy associated with surgery performed on patients in a lithotomy position. Anesthesiology. 1994;81(1):6-12.
8. Warner MA, Warner DO, Harper CM, Schroeder DR, Maxson PM. Lower extremity neuropathies associated with lithotomy positions. Anesthesiology. 2000;93(4):938-42.
9. Romanowski L, Reich H, McGlynn F, Adelson MD, Taylor PJ. Brachial plexus neuropathies after advanced laparoscopic surgery. Fertil Steril. 1993;60(4):729-32.
10. Kho RM, Hilger WS, Hentz JG, Magtibay PM, Magrina JF. Robotic hysterectomy: technique and initial outcomes. Am J Obstet Gynecol. 2007;197(1):113.e1-4.
11. Balaphas A, Hagen ME, Buchs NC, Pugin F, Volonté F, Inan I, et al. Robotic laparoendoscopy single site surgery: a transdisciplinary review. Int J Med Robot Comput Assist Surg. 2013;9:1-11.
12. Cadiere GB, Himpens J, Germay O, Izizaw R, Degueldre M, Vandromme J, et al. Feasibility of robotic laparoscopic surgery: 146 cases. World J Surg. 2001;25:1467-77.
13. Nawfal AK, Orady M, Eisenstein D, Wegienka G. Effect of body mass index on robotic-assisted total laparoscopic hysterectomy. J Minim Invasive Gynecol. 2011;18:328-32.
14. Sert BM, Abeler VM. Robotic-assisted laparoscopic radical hysterectomy (Piver type III) with pelvic node dissection–case report. Eur J Gynaecol Oncol. 2006;27:531-3.

JAYPEE BROTHERS

15. Magrina JF, Zanagnolo V, Giles D, Noble BN, Kho RMC, Magtibay PM. Robotic surgery for endometrial cancer: comparison of perioperative outcomes and recurrence with laparoscopy, vaginal/laparoscopy and laparotomy. Eur J Gynaecol Oncol. 2011;32(5):476-80.
16. Cardenas-Goicoechea J, Shepherd A, Momeni M, Mandeli J, Chuang L, Gretz H, et al. Survival analysis of robotic versus traditional laparoscopic surgical staging for endometrial cancer. Am J Obstet Gynecol. 2014;210:160.e1-e11.
17. Magrina JF, Zanagnolo V, Noble BN, Kho RM, Magtibay P. Robotic approach for ovarian cancer: perioperative and survival results and comparison with laparoscopy and laparotomy. Gynecol Oncol. 2011;121(1):100-5.
18. Persson J, Kannisto P, Bossmar T. Robot-assisted abdominal laparoscopic radical trachelectomy. Gynecol Oncol. 2008;111:564-7.
19. Johansen G, Lönnerfors C, Falconer H, Persson J. Reproductive and oncologic outcome following robotic-assisted laparoscopic radical trachelectomy for early stage cervical cancer. Gynecol Oncol. 2016;141(1):160-5.
20. Advincula AP, Song A, Burke W, Reynolds RK. Preliminary experience with robot-assisted laparoscopic myomectomy. J Am Assoc Gynecol Laparosc. 2004;11:511-8.
21. Advincula AP, Xu X, Goudeau S, Ransom SB. Robot-assisted laparoscopic myomectomy versus abdominal myomectomy: a comparison of short-term surgical outcomes and immediate costs. J Min Inv Gyn. 2007;14(6):698-705.
22. Sinno AK, Fader AN. Robotic-assisted surgery in gynecologic oncology. Fertil Steril. 2014;102:922-32.
23. Bedient CE, Magrina JF, Noble BN, Kho RM. Comparison of robotic and laparoscopic myomectomy. Am J Obstet Gynecol. 2009;201:566.e1-5.
24. Sangha R, Strickler R, Dahlman M. Myomectomy to conserve fertility: seven-year follow-up. J Obstet Gynaecol Can. 2015;37:46-51.
25. Asmar J, Even M, Carbonnel M, Goetgheluck J, Revaux A, Ayoubi JM. Myomectomy by robotically assisted laparoscopic surgery: results at foch hospital, Paris. Front Surg. 2015;2:40.
26. Soto E, Luu TH, Liu X, Magrina JF, Wasson MN, Einarsson JI, et al. Laparoscopy vs. Robotic Surgery for Endometriosis (LAROSE): a multicenter, randomized, controlled trial. Fertil Steril. 2017;107:996-1002.
27. Nezhat C, Lewis M, Kotikela S, Veeraswamy A, Saadat L, Hajhosseini B, et al. Robotic versus standard laparoscopy for the treatment of endometriosis. Fertil Steril. 2010;94:2758-60.
28. Oliveira MAP, Raymundo TS, Pereira TD, Souza RJ, Lima FV, De Wilde RL, et al. Robotic Surgery for Bladder Endometriosis: A Systematic Review and Approach. J Clin Med. 2023;12:5416.
29. Patel SPD, Steinkampf MP, Whitten SJ, Malizia BA. Robotic tubal anastomosis: surgical technique and cost effectiveness. Fertil Steril. 2008;90:1175-9.
30. Bedaiwy MA, Barakat EM, Falcone T. Robotic tubal anastomosis: technical aspects. JSLS. 2011;15:10-5.
31. Cardaillac C, Salmon C, Vaucel E, Gueudry P, Lavoue V, Nyangoh Timoh K, et al. Robot-assisted laparoscopy repair of uterine isthmocele: a two-center observational study. Int J Gynaecol Obstet. 2023;160:244-8.
32. Walker Z, Gargiulo A. Near-infrared and hysteroscopy-guided robotic excision of uterine isthmocele with laser fiber: a novel high-precision technique. Fertil Steril. 2023;120:1081-3.

JAYPEE BROTHERS

33. Hoffmann E, Vahanian S, Martinelli VT, Chavez M, Mesbah M, Nezhat FR. Combined Medical and Minimally Invasive Robotic Surgical Approach to the Treatment and Repair of Cesarean Scar Pregnancies. JSLS. 2021;25:e2021.00039.
34. Wang HF, Chen HH, Ting WH, Lu HF, Lin HH, Hsiao SM. Robotic or laparoscopic treatment of cesarean scar defects or cesarean scar pregnancies with a uterine sound guidance. Taiwan J Obstet Gynecol. 2021;60:821-6.
35. Smith RB, Brink J, Hu C, Gerkin R, Perlow JH, Mourad J. Robotic transabdominal cerclage vs laparotomy: a comparison of obstetric and surgical outcomes. J Minim Invasive Gynecol. 2020;27:1095-102.
36. Morice P, Thiam-Ba R, Castaigne D, Haie-Meder C, Gerbaulet A, Pautier P, et al. Fertility results after ovarian transposition for pelvic malignancies treated by external irradiation or brachytherapy. Hum Reprod. 1998;13:660-3.
37. Oktay K, Bedoschi G, Pacheco F, Turan V, Emirdar V. First pregnancies, live birth, and *in vitro* fertilization outcomes after transplantation of frozen-banked ovarian tissue with a human extracellular matrix scaffold using robot-assisted minimally invasive surgery. Am J Obstet Gynecol. 2016;214:94.e1-9.
38. Parekattil SJ, Brahmbhatt JV. Robotic approaches for male infertility and chronic orchialgia microsurgery. Curr Opin Urol. 2011;21(6):493-9.
39. McCullough A, Elebyjian L, Ellen J, Mechlin C. A retrospective review of single-institution outcomes with robotic-assisted microsurgical varicocelectomy. Asian J Androl. 2018;20(2):189-94.
40. Parekattil SJ, Gudeloglu A. Robotic assisted andrological surgery. Asian J Androl. 2013;15(1):67-74.
41. Douroumis K, Spartalis E, Stravodimos K, Levis PK, Tsourouflis G, Dimitroulis D, et al. Robotic-assisted microsurgery in andrology: a systematic review. Asian J Androl. 2023;25:454-61.
42. Wang R, Pan W, Jin L, Li Y, Geng Y, Gao C, et al. Artificial intelligence in reproductive medicine. Reproduction. 2019;158:R139-54.

JAYPEE BROTHERS

for detailed information on obstetrics & gynecology books, visit our website www.ejaypee.com, for detailed information on obstetrics & gynecology books, visit our website www.ejay

Dasgupta's Recent Advances in Obstetrics and Gynecology-15

Dasgupta's Recent Advances in Obstetrics and Gynecology is the premier textbook covering the most recent updates in the field aimed at postgraduate students and those who wish to be abreast of developments in our specialty.

The postgraduate curriculum has undergone several changes over the past few decades. There is greater emphasis on modern methodology of management incorporating the latest algorithms and the newest guidelines which are being published regularly. This volume includes clinically relevant topics which are authored by some of the seniormost and most sought-after teachers in the country.

With the enormous pressure of clinical work, postgraduate students often do not have much time to research topics, hunt for references, and sift through the mountains of published evidence to imbibe the most relevant information which is essential for them during the examinations. We hope that this book will be a useful compendium for postgraduate students and readers who wish to keep themselves updated with the latest evidence.

Nandita Palshetkar MD FCPS FICOG FRCOG (UK) is a Professor Emeritus, Department of Obstetrics and Gynecology, DY Patil School of Medicine, Navi Mumbai, Maharashtra, India. She is the Past President of FOGSI (Federation of Obstetric and Gynaecological Societies of India), Representative to FIGO (International Federation of Gynecology and Obstetrics) and also the Co-chair of the REI (Reproductive Endocrinology and Infertility) Committee AOFOG (Asia Oceania Federation of Obstetrics and Gynecology). She has been the President of the Indian Society of Assisted Reproduction—ISAR (2022–2024); Association of Maharashtra Obstetric and Gynaecological Societies—AMOGS (2020–2022); FOGSI (2019–2020); Mumbai Obstetric and Gynaecological Society—MOGS (2016–2017); Indian Association of Gynaecological Endoscopists—IAGE (2017–2018); and Maharashtra Chapter of ISAR–MSR (2016–2018). She is the Founder and Medical Director of Bloom IVF, Heading 11 in vitro fertilization (IVF) centers all over India. She has delivered over 112 orations and given over 1,000 talks at national and international conferences. She has written over 147 textbook chapters, edited several books, and published papers in national and international journals. She has received 54 National and International awards including the Bharat Gaurav Award at the House of Commons in the UK. She is an Infertility Specialist, Lilavati Hospital IVF Centre, Mumbai. Most recently, in 2021, received the prestigious Fellowship of the Royal College of Obstetricians and Gynaecologists, honoring her exemplary work in women's health.

Pratik Tambe MD FICOG FICRM FICMCH FIAOG is an Assisted Reproductive Technology (ART) Consultant and Gynecological Endoscopic Surgeon. He holds a Diploma in Advanced Laparoscopic Surgery from France and has trained in Assisted Reproduction in Belgium and Clinical Embryology in the UK and Singapore.

He is currently the Secretary of the Indian College of Obstetricians and Gynecologists (ICOG) and a Governing Council Member of the Indian College of Reproductive Medicine (ICRM). He is also a Managing Committee Member of the Mumbai Obstetrics and Gynecological Society (MOGS), Indian Society for Assisted Reproduction (ISAR), and Maharashtra Chapter of ISAR (MSR). He has previously served as the Chairperson, FOGSI and AMOGS Endocrinology Committees and a Governing Council member, ICOG.

He is a peer reviewer for JOGI and has edited 35 books, 3 FOGSI Focuses and Handbooks, 11 Key Practice Points, and contributed 100+ chapters to several publications. He has organized over 800+ CMEs nationwide and spoken at 1,000+ national and international events. He is also a recipient of 36 MOGS, AMOGS, FOGSI, and ISAR Prizes and Awards.

Rohan Palshetkar MS (Obs & Gyne) FRM BDRME ADRME is an ART Consultant and Endoscopic Surgeon. He is a Professor, Department of Reproductive Medicine, DY Patil Medical College, Mumbai, Maharashtra, India, and is also the Unit Head of DY Patil Bloom IVF and Opera House Bloom IVF, Mumbai.

He is currently the Chairperson of the FOGSI Young Talent Promotion Committee; First Joint Secretary, AMOGS (All Maharashtra Association of Obstetrical and Gynaecological Societies), Joint Treasurer of Maharashtra Chapter of IAGE and the Managing Committee Member of ISAR (Indian Society of Assisted Reproduction), Maharashtra Chapter of ISAR and MOGS (Mumbai Obstetric and Gynaecological Society). He has delivered the ISAR YUVA Oration, MSR Yuva Oration and the FOGSI Kamini Rao Yuva Oration. Besides this, he has delivered several talks and contributed several publications for FOGSI and MOGS. He has multiple publications and delivered over 150 talks. He is the Recipient of the Asia and Oceania Federation of Obstetrics and Gynaecology Young Gynaecologist Award. He has won the prestigious FOGSI Corion, Shanti Yadav Award, Kumud Tamaskar and Praveen Mehta Awards for his research papers. He has also won the best Youth Council Member Award for MOGS twice. Besides his academic awards, he has received the Times Network India Healthcare Award and has also received the We for Stree Puraskar at the hands of the Governor of Maharashtra, Honorable Bhagat Singh Koshyari.

Shelving Recommendation
OBSTETRICS & GYNECOLOGY

ISBN 978-93-7545-531-8

Buy from ejaypee

JAYPEE BROTHERS