nformation on dermatology books, visit our website www.ejaypee.com, for detailed information on dermatology books, visit our website www.ejaypee.com

SPOTTERS IN DERMATOLOGY



Editors
Vikas Pathania
Shekhar Neema

Assistant Editor
Sampoorna Raj Choudhary

Foreword
Maj Gen (Dr) Manas Chatterjee, VSM

JAYPEE

Contents

1. **Acanthosis Nigricans** 1
   Durga Madhab Tripathy
2. **Acne Vulgaris** 6
   Gyanesh Rathore
3. **Acneiform Eruptions** 13
   Akanksha Gupta
4. **Acne Scars** 18
   Anwita Sinha
5. **Mycetoma** 26
   Prachi Verma, Diksha Garg
6. **Angiokeratomas** 32
   Shaifu Palani
7. **Androgenetic Alopecia** 36
   Anand Mannu
8. **Alopecia Areata** 42
   Debatraya Paul
9. **Cutaneous Amyloidosis** 51
   Sampoorna Raj Choudhary
10. **Congenital Melanocytic Nevus** 56
    Sanoj
11. **Darier Disease** 62
    Surbhi Rajput
12. **Discoid Lupus Erythematosus** 68
    Sivasankari M
13. **Dermatophytosis** 75
    Siddharth Mani, Prachi Verma
14. **Erythrasma** 87
    Devyani Sapra
15. **Hidradenitis Suppurativa** 91
    Anand Mannu

16. **Ichthyosis** 96
Debatraya paul

17. **Keloids and Hypertrophic Scars** 107
Durga Madhab Tripathy

18. **Longitudinal Melanonychia** 113
Siddharth Mani

19. **Lymphangioma Circumscriptum** 119
Shaifu Palani

20. **Lichen Planus** 123
Vikas Pathania, Richa Kumar

21. **Melasma** 129
Gyanesh Rathore

22. **Molluscum Contagiosum** 136
Sunmeet Sandhu

23. **Nonmelasma Facial Melanosis** 142
Vikas Pathania

24. **Nonmelanoma Skin Cancer** 151
Senkadhir Vendhan, Smriti Sharma

25. **Neurofibromatosis** 159
Karthi Kishore

26. **Nevus of Ota** 165
Bhavni Oberoi

27. **Onychomycosis** 170
Durga Madhab Tripathy

28. **Palmoplantar Keratoderma** 179
Senkadhir Vendhan

29. **Port-wine Stain (Nevus Flammeus)** 184
Shaifu Palani

30. **Pyogenic Granuloma (Lobular Capillary Hemangioma)** 189
Sanoj

31. **Pityriasis Versicolor** 194
Devyani Sapra

32. **Rosacea** 199
Afreen Ayub

33. Cicatricial Alopecia **208**
Sivasankari M

34. Trachyonychia **215**
Sampoorna Raj Choudhary

35. Tuberous Sclerosis Complex **220**
Karthi Kishore

36. Vascular Nevi **226**
Sanoj

37. Vitiligo **235**
Bhavni Oberoi

38. Nongenital Cutaneous Warts **244**
Sunmeet Sandhu

39. Xeroderma Pigmentosum **252**
Sanoj

Index ***257***

23 Nonmelasma Facial Melanosis

Vikas Pathania

Nonmelasma facial melanosis includes a broad group of conditions presenting with hyperpigmentation over the face but not following the typical centrofacial/malar pattern of melasma. Common differentials asked in examinations/spotters include:

- Lichen planus pigmentosus (LPP)
- Facial acanthosis nigricans (FAN)
- Pigmentary contact dermatitis (PCD)
- Nevus of Ota/nevus of Hori
- Exogenous ochronosis
- Periorbital melanosis
- *Less commonly*: Postinflammatory hyperpigmentation and ashy dermatosis

While examining, the following points should be kept in mind:

1. Morphology, color, and texture of lesions:
   - *LPP:* Slate-gray to brown macules/patches; smooth surface; ill-defined; may be reticulate.
   - *PCD (Riehl's melanosis):* Smoky brown/gray pigmentation; usually diffuse; may show mild scaling; often symmetric.
   - *FAN:* Dirty-brown velvety thickening; accentuated skin markings; typically coarse texture.
   - *Exogenous ochronosis:* Blue-black pigmentation with "caviar-like papules."
   - *Nevus of Ota/Hori:* Slate-blue dermal pigmentation—mottled and speckled
2. Characteristic location of these lesions:
   - *LPP:* Face (forehead and temples), neck, and flexures. Often, photoexposed areas.

JAYPEE BROTHERS

- *PCD:* Upper cheeks, periorbital area, and forehead—sites exposed to fragranced cosmetics/hair dyes.
- *FAN:* Perioral, perinasal areas, and forehead.
- *Exogenous ochronosis:* Malar and zygomatic areas—where hydroquinone is applied.
- *Nevus of Ota:* Periorbital region + scleral pigmentation.
- *Nevus of Hori:* Bilateral malar involvement (adult onset).

3. Ancillary findings such as nail, hair, and mucosal lesions:
   - *LPP:* May have classical LP lesions elsewhere; nail ridging; oral Wickham striae.
   - *PCD:* Usually, no systemic findings; history of cosmetic exposure.
   - *FAN:* Often associated with obesity, insulin resistance; look for acanthosis elsewhere (neck and axillae).
   - *Nevus of Ota:* Scleral and conjunctival pigmentation.
   - *Exogenous ochronosis:* No mucosal or nail findings; strong history of hydroquinone use.
4. Dermoscopy of lesions showing characteristic patterns and level of pigmentation epidermal/dermal/mixed.



FIGS. 1A TO D: *Clinical images*: Facial hyperpigmentation showing different etiologies and patterns. (A) Lichen planus pigmentosus; (B) Pigmented contact dermatitis (C) and (D) Facial acanthosis nigricans involving forehead and malar area respectively

JAYPEE BROTHERS

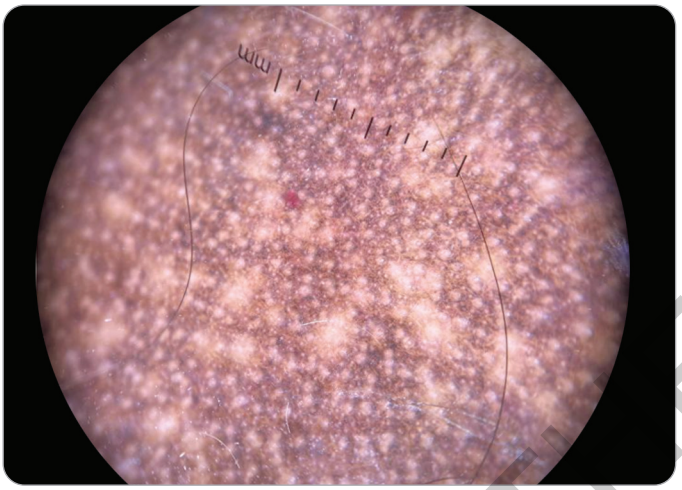

FIG. 2: *Dermoscopy image*: Lichen planus pigmentosus (LLP) showing diffuse brownish background pigmentation with multiple slate-gray to brown dots and globules arranged in a speckled pattern and accentuation around follicular openings, consistent with dermal melanophages in LPP.

Questions to the Patient

1. **Onset and duration?** Helps to distinguish congenital versus acquired causes and identifies rapidly evolving conditions such as PCD, LPP, or late-onset dermal melanoses like nevus of Hori.
2. **Any history of itchy/hyperpigmented lesions elsewhere in the body or mucosa?** LPP and ashy dermatosis
3. **Use of cosmetics/topical depigmenting cream?** Pigment contact dermatitis and exogenous ochronosis
4. **History of photoexacerbation/photosensitivity?** Poikiloderma of civatte, actinic LP and pigment contact dermatitis
5. **Any preexisting lesions?** Postinflammatory hyperpigmentation
6. **Any history of systemic associations [diabetes, coronary artery disease (CAD), and obesity]?** Acanthosis nigricans
7. **History of red raised scaly lesions over the scalp and face?** Seborrheic melanosis
8. **Any drug history?** Drug-induced melanosis
9. **Does the patient scratch or rub on these lesions?** (Frictional melanosis)
10. **Dietary habits?** (vitamin B12 deficiency)
11. **Any history of fever and joint pain before the onset?** (Post-chikungunya)
12. **Occupation of the patient?** (Photoexacerbation and metal-induced pigmentation)
13. **History of mucosal pigmentation?** (Addison's disease and LPP)
14. **Associated hair and nail changes?** (Endogenous ochronosis, LPP, and drug-induced)
15. **History of liver disease/jaundice?** (Hemochromatosis)

JAYPEE BROTHERS

Questions by the Examiner

1. What is the differential diagnosis of nonmelasma facial melanosis?

Ans. Lichen planus pigmentosus, pigmented contact dermatitis, postinflammatory hyperpigmentation, exogenous ochronosis, ashy dermatoses, acanthosis nigricans, maturational hyperpigmentation, periorbital hyperpigmentation, seborrheic melanosis, friction melanosis, drug-induced hyperpigmentation, post-chikungunya pigmentation, erythrose peribuccale pigmentaire de brocq, poikiloderma of civatte, idiopathic macular eruptive pigmentation, pigment demarcation line, Hori nevus, nevus of Ota, actinic lichen planus, erythromelanosis follicularis faciei et colli, macular amyloidosis, metal-induced pigmentation, and hemochromatosis.

2. Dermal melanocytosis is seen in which all conditions?

Ans. Naevi of Ota and ito, Hori nevus (ABNOM-acquired bilateral nevus of Ota-like macules), Mongolian spots, and blue nevus.

3. Name some mixed epidermal–dermal melanosis.

Ans. Postinflammatory hyperpigmentation, Riehl melanosis, and poikiloderma of civatte.

4. What are the systemic causes of diffuse facial pigmentation?

Ans. Systemic sclerosis, hemochromatosis, Addison's disease, vitamin B12 deficiency, and obesity (facial AN).

5. How will you differentiate the facial melanosis based on the color of the lesions?

Ans. Dark brown to gray-LPP, bluish gray-erythema dyschromicum perstans (EDP), bronze discoloration-hemochromatosis, coppery red-clofazimine, bluish black-minocycline, slate gray-amiodarone, and deep brown—vitamin B12 deficiency.

Lichen Planus Pigmentosus

1. What is the basis of diagnosis?

Ans.

- *Clinically*: Young to middle-aged adults—phototypes III–VI
- Irregularly shaped or oval, brown to gray—brown macules and patches which favor sun-exposed areas and intertriginous zone
- *Dermoscopy*: Brown to slate-gray dots and globules, accentuation of pseudoreticular pigment network, pigment accentuation around follicular, and eccrine openings, "arcuate"/"hem-like" patterns.

2. What are the common areas of involvement in LPP?

Ans. Lichen planus pigmentosus most commonly begins on the face, especially the preauricular areas and temples, and may extend to the forehead, lateral face, and neck. It frequently involves the upper extremities, upper back, and chest. Flexural/intertriginous areas (axillae, groin, and inframammary

JAYPEE BROTHERS

region) are also commonly affected. Generalized involvement occurs in some patients.

3. What are the histopathological features of LPP?

Ans. Epidermal atrophy, basal cell vacuolation, band-like/perivascular lymphoid infiltrate in the upper dermis, and dermal melanophages.

4. What are the morphological variants of LPP?

Ans. Diffuse, reticulate, blotchy, follicular patterns, and the unilateral linear variant.

5. What are the associations of LPP?

Ans. Lichen planus pigmentosus is associated with other lichen planus variants, frontal fibrosing alopecia, atopy, autoimmune thyroiditis, vitiligo, and alopecia areata.

6. How will you manage this case?

Ans. Management of LPP includes strict photoprotection; topical tacrolimus, corticosteroids, and retinoids; systemic agents such as short-course steroids, low-dose isotretinoin, dapsone, or mycophenolate; and, in resistant cases, low-fluence Q-switched neodymium-doped yttrium aluminium garnet (Nd:YAG) laser. Counseling and trigger avoidance are essential.

Pigmented Contact Dermatitis

1. What is the basis of diagnosis?

Ans. Pigmentary contact dermatitis is diagnosed clinically by brownish-gray perifollicular macules over the face—especially forehead and temples—extending to neck and chest, with a history of cosmetic or airborne allergen exposure, supported by dermoscopy showing gray dots/clods and pseudoreticular pattern.

2. What are the other names of PCD?

Ans. Riehl melanosis, melanodermatitis toxica, pigmented cosmetic dermatitis, and photocontact facial melanosis.

3. What is its etiopathogenesis?

Ans. It is caused by a type IV hypersensitivity reaction to allergens in cosmetics or airborne agents in genetically predisposed individuals, with ultraviolet (UV) radiation acting as a major cofactor, leading to interface dermatitis and pigment incontinence.

4. What are the allergens involved in PCD?

Ans. Hair dyes, cosmetics, fragrances, textiles, occupational allergens, and drugs.

5. What will you see in histopathology?

Ans. Early stages—liquefaction degeneration of the basal layer of the epidermis, and a perivascular or band-like dermal infiltrate with

JAYPEE BROTHERS

pigmentary incontinence. Later—epidermis appears normal, but abundant melanophages are present in the upper dermis with minimal inflammatory infiltrate.

6. How will you treat this patient?

Ans. Contact cause can be identified and avoided along with sun protection. Cosmetic camouflage also effectively conceals persistent pigmentation. Treatment includes:

Topical	Oral	Lasers	Combination therapies
• Hydroquinone • Corticosteroids • Calcineurin inhibitors • Retinoids • Vitamin C • Azelaic acid • Chemical peels (trichloroacetic acid, glycolic acid, and salicylic acid peels)	• Oral glycyrrhizin compound • Vitamin C • Oral tranexamic acid • Mycophenolate mofetil	• Q-switched Nd-YAG 1064 nm • Intense pulse light systems • Picosecond alexandrite laser • Nonablative fractional thulium fiber laser	• 1064 nm QSNY lasers (parameters: 2.0 j/cm^2) thrice weekly + 4% HQ cream • 250 mg of TXA + three weekly QSNY laser + 4% HQ cream • Oral glycyrrhizin 150 mg daily + 100 mg of vitamin C daily + 30% peels with salicylic acids every 2 weeks

Ashy Dermatoses

1. What is the basis of diagnosis?

Ans.

- *Clinically*: Young adults, females with intermediate skin types, gray, bluish or brown (ash-like) macules and/or patches on the trunk, extremities, and face. Erythematous border that fades over time.
- *Dermoscopy*: Shows linear distribution of blue-gray dots and globules over structureless areas.

2. What are the findings in histopathological examination (HPE)?

Ans. Active lesions—increased epidermal pigment (variable), vacuolar basal cell degeneration with pigment incontinence, dermal melanophages, and perivascular lymphohistiocytic infiltrate. Inactive lesions—the number of melanophages in the superficial dermis is increased with little or no inflammation.

3. What are the other names of ashy dermatosis?

Ans. Erythema dyschromicum perstans, ashy dermatosis of Ramirez or erythema chronicum figuratum melanodermicum, and dermatosis cenicienta.

JAYPEE BROTHERS

4. First described by whom?

Ans. Ramirez in 1957, referring to affected individuals as los cenicientos ("the ashen ones").

5. What are the associations of EDP?

Ans. Toxins (ammonium nitrite, cobalt, radiocontrast, and pesticides), drugs (ethambutol, penicillin, benzodiazepines, and chlorothalonil), whipworm infection, and human immunodeficiency virus (HIV).

6. What is the etiopathogenesis of EDP?

Ans. EDP has an unknown cause, but is believed to result from a cell-mediated immune reaction to an ingestant, contactant, drug, toxin, or microorganism, leading to interface dermatitis and pigment incontinence.

7. What is the treatment of EDP?

Ans. No standard treatment for EDP; resolves spontaneously in 50% of prepubertal patients, but is more recalcitrant in adults.

Topical	Systemic
Topical corticosteroids	Systemic corticosteroids
Hydroquinone and tretinoin	Oral dapsone and oral clofazimine
• 0.1% tacrolimus ointment • Narrowband UV-B phototherapy	Doxycycline, griseofulvin, and antimalarials

Postinflammatory Hyperpigmentation

1. What is the basis of diagnosis?

Ans. PIH is diagnosed clinically by the presence of hyperpigmentation in the exact location of a prior inflammatory lesion, especially in darker skin types (III–VI).

2. What is PIH?

Ans. Acquired circumscribed hyperpigmentation in sites of prior inflammation or injury.

3. What are the types of PIH?

Ans. Epidermal (tan to dark brown) and dermal (blue-gray).

4. What is the etiopathogenesis of PIH?

Ans. PIH results from inflammation-induced melanocyte stimulation, causing epidermal melanin deposition, and from basal layer damage leading to dermal pigment incontinence and long-standing melanophages.

5. How will you assess the severity?

Ans. The severity of PIH is proportional to the severity of the inflammation and the degree of basement membrane disruption.

JAYPEE BROTHERS

6. What is the course of the disease?

Ans.

- *Epidermal PIH*: Fades over months to years.
- *Dermal PIH*: Takes years to resolve or may become permanent

7. How will you treat?

Ans.

- Sun protection prevents accentuation of the pigmentation by UV exposure.
- Topical hydroquinone (2–4%) may lead to lightening over 3–6 months
- Topical retinoid and corticosteroid, together with hydroquinone, are more effective than monotherapy.
- Topical azelaic, α-hydroxy, L-ascorbic, tranexamic, and kojic acids as well as cysteamine, arbutin, liquorice extracts, mequinol, niacinamide, N-acetyl glucosamine, and soy are additional potential therapeutic options.
- Laser therapy (e.g., 1927-nm nonablative fractional thulium fiber laser, Q-switched Nd:YAG, ruby, and alexandrite lasers) for dermal pigment.

Exogenous Ochronosis

1. What is the basis of diagnosis?

Ans. Asymptomatic blue-black and gray-black hyperpigmented macules are characteristic. Found on the face (malar, temples, and lower cheeks), posterolateral neck, back, and extensor skin of the extremities. Later stages include progressive hyperpigmented colloid milium ("caviar-like lesions), papulonodular lesions, and areas of scarring.

Dermoscopy: Oval to oblong pattern of blue-gray globules with patchy areas of erythema and telangiectasia. Brown amorphous areas, confetti-like depigmentation seen as white dots and obliteration of follicular openings.

2. What are the causes?

Ans. Prolonged use of skin-lightening products, most commonly those containing hydroquinone and also resorcinol, phenol, mercury, and picric acid.

3. What is the etiopathogenesis?

Ans. Use of medications such as hydroquinone, which forms a homogentisic acid polymer-like substance during their metabolism.

4. What are the features in HPE?

Ans. Yellow–brown banana-shaped fibers are seen in the papillary dermis. Homogenous, edematous dermal collagen and altered elastic fibers resembling solar elastosis.

JAYPEE BROTHERS

5. How will you differentiate endogenous versus exogenous ochronosis?

Ans.

Exogenous	Endogenous
• Gray-brown or blue-black macules with h/o prolonged usage of hydroquinone • Face, neck, back, and the extensor surfaces of the limbs • No hyperpigmentation of cartilage, sclerae, or conjunctivae occurs	• Most frequent is darkening of the ear cartilages and of the sclerae and conjunctivae • Brown mottled pigmentation of the face neck and trunk • Pigmentation of the palmar and plantar skin-rare

6. How will you treat?

Ans.

- Stopping the offending medication
- Broad-spectrum sunscreen and sun avoidance
- Topical retinoids, α-hydroxy acids, and corticosteroids
- Ablative methods such as erbium:YAG and carbon dioxide lasers, combined with dermabrasion
- QS ruby (694 nm), QS alexandrite (755 nm), and QS Nd:YAG (1064 nm) lasers
- Combining an ablative carbon dioxide laser with an Nd:YAG laser

JAYPEE BROTHERS

for detailed information on dermatology books, visit our website www.ejaypee.com, for detailed information on dermatology books, visit our website www.

SPOTTERS IN DERMATOLOGY

Spotters in Dermatology is a Focused Handbook crafted for MD/DNB residents and examiners, addressing the practical demands of the spotter segment—where rapid visual recognition, concise description, and clinical reasoning converge under time pressure. Each topic is structured to examination format, covering lesion description, differentials, key histopathology, dermoscopy, management points, and examiner-style questions that mirror real viva expectations. Designed from day-to-day academic experience, it offers high-yield spotters, standardized evaluation cues, and practical recall tools. This work serves as a ready reckoner for last-minute preparation and a reliable framework for consistent assessment.

Vikas Pathania is a Senior Advisor and Head of Dermatology at Base Hospital, Lucknow, Uttar Pradesh, India. He is an alumnus of the Armed Forces Medical College, Pune. He was awarded Lt Gen KS Masters Silver medal for academic excellence in MD Dermatology. He is the recipient of Prof BN Banerjee Gold Medal for the best original paper in year 2011. He has been awarded Force Commanders Commendations at Indian Field Hospital, Level-III, UN Mission in Congo, Africa (MONUC 2007) and (MONUSCO 2016) and GOC in C commendation in 2025 for exceptional and meritorious service. He received *AVISHKAAR* innovation award in 2020 for his innovations in hair restoration surgery. He has more than 60 publications, multiple book chapters, and over 50 national and international presentations. He serves as an Assistant Editor of the Journal of Cutaneous and Aesthetic Surgery and Section Editor for the Indian Journal of Dermatology, Venereology, and Leprosy, and is a reviewer for several leading journals including JAAD, The Lancet, and Annals of Medicine. Hair restoration, vitiligo surgery, nail surgery, dermoscopy, and emerging applications of artificial intelligence (AI) in dermatology are his interest areas. He is an avid runner and has successfully completed more than 15 marathon and half-marathons.

Shekhar Neema is an alumnus of Armed Forces Medical College. He excelled in MBBS with 10 distinctions and was awarded President Gold Medal for the best academic record in year 2006. He is a Gold Medal recipient from MUHS in MD Dermatology. He has done ISD fellowship at Ludwig Maximilian University, Munich. He has been awarded Dr LN Sinha Memorial Award in 2023 and is an International Psoriasis Council Fellow for the year 2024. He is Associate Editor of Indian Journal of Dermatology, Venereology, and Leprosy. He is a co-editor of books titled "Dermoscopy in Darker Skin" and "Nail Disorders—A Comprehensive Approach", Handbook of Biologics and Biosimilars in Dermatology, Atlas of Leprosy, and IADVL Handbook of Anecdotal Therapy and Pearls. He has more than 150 publications in indexed journals and has authored more than 30 chapters in various textbooks. Immunodermatology, dermatotherapeutics, dermatosurgery, and dermoscopy are his special interest areas. He has been a Professor at Armed Forces Medical College, Pune, and is currently working at Base Hospital, Lucknow, Uttar Pradesh, India.

Shelving Recommendation
DERMATOLOGY

ISBN 978-93-7545-561-5

Buy from ejaypee

JAYPEE BROTHERS