ed information on critical care books, visit our website www.ejaypee.com, for detailed information on critical care books, visit our website www.ejaypee.com

Complimentary Online 40 Videos (Duration 2 hours 26 minutes)

Intervention for Intensivists



Editors
Puneet Khanna
Anjaleekrishna K

JAYPEE

Contents

Section 1: Foundations of Intensive Care Procedures

1. **Multidisciplinary Patient Care Team in the Intensive Care Setting 3**
   Haritha Damarla, Anjaleekrishna K
2. **Preparation and Prerequisites for Interventional Procedures in Intensive Care Unit 8**
   Anjaleekrishna K, Puneet Khanna

Section 2: Airway Management

3. **Airway Management in the Intensive Care Unit..... 17**
   Nirmal Shanmugam, Puneet Khanna
4. **Cricothyroidotomy 28**
   Vishnu Narayanan MR, R Afshan
5. **Tracheostomy in the Intensive Care Unit 36**
   Anjaleekrishna K
6. **Bronchoscopic Procedures in Intensive Care: Therapeutic and Diagnostic 46**
   Mahendran T Kurup, Puneet Khanna

Section 3: Hemodynamic Monitoring and Cardiovascular Procedures

7. **Arterial Line Access and Monitoring 57**
   Vikas Saini, Anas Valiyaparambath
8. **Central Venous Catheterization—Techniques and Care 65**
   Richa Saroa, Sanjeev Palta, Avneet Singh, Shuchi, Sukhpuneet Virk
9. **Hemodialysis Catheter 73**
   Gurudarshan S, Puneet Khanna
10. **Intraosseous Access in Intensive Care Unit..... 79**
    Sandeep Sahu, Indu Lata
11. **Pulmonary Artery Catheter..... 87**
    Kulbhushan Saini, Arshdeep Singh
12. **Temporary Transvenous and Transcutaneous Pacemaker 93**
    Kulbhushan Saini
13. **Intra-aortic Balloon Pump in the Intensive Care Unit..... 103**
    Ajeetviswanath, Stuti Gupta

14. The REBOA Catheter 112
Ajay Singh, Soumya Sarkar

Section 4: Thoracic and Abdominal Procedures

15. Pericardiocentesis 119
Shitij Chaudhary, Nirmal Ghati

16. Resuscitative Thoracotomy 127
Srirupa Mandal, Soumya Sarkar

17. Intercostal Drain Placement 131
Balaji Rajaram, Nithin Maheshwaran, Nikhil PJ Theckumparampil

18. Thoracentesis 141
Tanvi M Meshram, Darshana Rathod

19. IVC Filter in the Intensive Care Unit 146
Siddhavivek Majage, Rajathadri Hosur Ravikumar

20. Extracorporeal Membrane Oxygenation and Extracorporeal Life Support 156
Mrudula BS

21. Lung Biopsy 168
Amit Kumar Malviya, Sandeep Kumar, Rajneesh Kumar Srivastava

22. Enteral Access 175
Rakshith M Adiga, Mridul Dhar

23. Percutaneous Endoscopic Gastrostomy 187
Mudit Kotwal, Soumya Jagannath Mahapatra

24. Paracentesis in Clinical and Critical Care Practice 196
Akhil Kant Singh, Abhas Munda

25. Intra-abdominal Hypertension/Abdominal Compartment Syndrome 205
Karthiga R, Shanmuga Sundaram M

26. Diagnostic Peritoneal Lavage 212
Nitin Rai

Section 5: Neurological Procedures

27. Intracranial Pressure Monitoring 225
Jasper Rathinam, Shalini Nair

28. Lumbar Puncture 235
Ajeet Kumar, Devarakoda Prithvi

29. External Ventricular Drain 247
Himanti, Puneet Khanna

Section 6: Miscellaneous Procedures

30. Urinary Catheterization: Basic to Atypical Reservoirs 263
Baby Pegu

31. Fracture Management: Reduction, Immobilization, and Splinting 268
Arpit Sahu, Kushagra, Subhadip Sanyal

32. Fasciotomies 273
Sushant Soren, Brijesh Kumar Singh, Kajal Mishra, Asuri Krishna

33. Wound Care for Intensivists 284
Darshana Rathod, Ankur Sharma, Shilpi Karmakar

34. Extended Focused Assessment with Sonography in Trauma 294
Sachith Raju, Venkata Ganesh

35. Point-of-Care Ultrasonography 299
Madhurjya Baishya

36. Renal Replacement Therapy in Intensive Care Unit 310
Shashikant Sharma, Aditya Anand

Index 321

CHAPTER 5

Tracheostomy in the Intensive Care Unit

Anjaleekrishna K

ABSTRACT

Tracheostomy is widely used in intensive care, perioperative setup, and trauma care. Indications and techniques are variable and extensively studied and implemented in either setup. We present herein recommendations on indications and contraindications for tracheotomy, tracheotomy techniques, modalities of tracheotomy, management of patients undergoing tracheotomy, and decannulation in intensive care setup. Both surgical and percutaneous techniques have shown beneficial in weaning critically ill patients from mechanical ventilation.

INTRODUCTION

Tracheostomy is a common intervention performed in operation theaters, emergency rooms, intensive care units, and trauma setup, for establishing and maintaining a secure airway. It is most frequently performed in critically ill patients requiring prolonged ventilation, airway obstruction, or management of excessive secretions. While endotracheal intubation remains the primary method for short-term airway control, tracheostomy offers several advantages in long-term ventilatory support, including improved patient comfort, reduced sedation requirements, and enhanced potential for communication and rehabilitation.

The timing of tracheostomy remains a topic of debate. Conventionally, the procedure was delayed until after 10–14 days of intubation, but recent studies suggest that early tracheostomy, within 7–10 days, may reduce ICU stay and ventilator associated complications. The TrachMan trial of 2013 found no significant mortality difference between early and late tracheostomy but highlighted benefits in terms of sedation reduction, improvement on delirium, and early mobilization.

Two main techniques are used in the ICU—open surgical tracheostomy (OST) and percutaneous dilatational tracheostomy (PDT). OST, described by Chevalier Jackson, involves placement of a tracheostomy tube (TT) in the trachea after performing dissection of pretracheal fascia and creating an opening in the trachea under direct vision, and can be performed both in ICU or operation theater (OT). PDT, introduced by Ciaglia in 1985, is where TT is placed in the trachea after creating an opening in the trachea by blunt dissection of pretracheal soft tissue with the help of Seldinger technique. PDT often performed under bronchoscopic guidance is increasingly preferred due to its bedside feasibility and lower infection rates. However, OST may still be necessary in high-risk patients with difficult anatomy or coagulopathy. Complications can arise during or after the procedure such as bleeding, pneumothorax, or late onset tracheal stenosis. Proper technique, patient selection, and post-tracheostomy care are crucial to minimizing risks. Additionally, tracheostomy facilitates ventilator weaning by improving respiratory mechanics and allowing use of speaking valves, which enhance patient communication.

JAYPEE BROTHERS

This chapter examines the indications, timing, techniques, preparation, and complications of ICU tracheostomies, along with best practices for post-procedural management including weaning. Further management such as optimal cuff care, TT changes, and weaning approaches are typically directed by individual expertise and institute preferences.

INDICATIONS AND CONTRAINDICATIONS

Although there is considerable variation in the timing of tracheostomy, late versus early, the first and foremost indication of tracheostomy inside ICU is the anticipation that the patient will remain intubated for a longer period of time. Early tracheostomy has shown benefit in patients of traumatic brain injury and stroke. **Box 1** gives a list of suggestive indications for tracheostomy in ICU patients, and it is to be noted that these are separate from emergency tracheostomy used as front of neck access (FONA) in trauma and emergency.

While the indications to tracheostomy are more or less specific, there are only two absolute contraindications that are infection at the local site and refusal to consent for the procedure. As most of the indications are nonemergent in ICU scenario, all the other indications become relative in the sense that they can be corrected or improved before the procedure. **Box 2** gives a list of the relative contraindications that depend on operator experience and airway management expertise.

BOX 1: Indications of tracheostomy.

- Prolonged ventilation
- Weaning from ventilator support
- Tracheobronchial toileting and secretion management
- Upper airway obstruction (surgery, trauma, foreign body, tumor, and OSA)
- Permanent airway control in malignancies or trauma
- To improve comfort and mobilization on mechanical ventilation
- Neurologic conditions such as spinal cord injury or stroke

TIMING OF TRACHEOSTOMY

We already discussed the widely accepted definition of when to call the tracheostomy early (done within 7–10 days of intubation) (ET) versus late (done beyond 10 days) (LT). In addition to the timing, we shall also compare the preferences for scenarios for each and review some findings of systematic review comparing both. An umbrella review of systematic reviews of clinical trials in critical care patients published in 2025 provides an updated synthesis of evidence comparing ET and LT in ICU patients requiring prolonged mechanical ventilation.

- It showed that ET significantly reduced ICU length of stay by an average of 3–5 days as compared to LT. Stay duration in the hospital was also shorter with ET with less pronounced difference suggesting there are other factors beyond tracheostomy timing that influences overall hospitalization duration.

BOX 2: Contraindications for tracheostomy.

Absolute:

- Refusal to consent
- Local site infection

Relative:

- Coagulopathy
- Altered neck anatomy—mass, short neck, restricted neck extension, and overlying blood vessels
- Unstable cervical spine
- Morbid obesity
- Patients on ventilator support with high PEEP (FiO_2 requirement >50%, PEEP >10 cmH_2O)
- Hemodynamic instability
- Raised intracranial pressure

JAYPEE BROTHERS

- Patients undergoing ET had a shorter duration of mechanical ventilation, likely due to earlier facilitation of weaning and reduced sedation needs. However, the difference was not as substantial indicating patient-specific factors play a more crucial role.
- No statistically significant difference was found in the ICU or 30-day mortality between ET and LT groups.
- Ventilator-associated pneumonia (VAP) rates were lower with ET, probably owing to the reduced aspiration risk and better secretion management.
- No significant difference in major complications such as bleeding or tracheal stenosis was noted while comparing ET with LT, reinforcing the safety of both when performed by experienced clinicians.
- A significant reduction was noted in the sedation requirements of ET patients, allowing for earlier patient mobilization and rehabilitation.
- Improved comfort and communication via speaking valves or uncuffed or fenestrated tubes were noted with ET.

Despite the offered advantages (summarized in **Box 3**), the lack of mortality benefit suggests that timing should be individualized rather than protocolized. Factors such as underlying pathology, neurological recovery potential, and risk of prolonged ventilation should guide decision-making even in the recommendations for ET in patients requiring prolonged ventilation.

BOX 3: Advantages of early tracheostomy.

- Improve weaning from mechanical ventilation
- Facilitate airway suctioning and secretion management
- Decrease sedative and muscle relaxant requirement to maintain orotracheal intubation
- Early mobilization, oral nutrition, and rehabilitation
- Lower ventilator-associated pneumonia (VAP) risk

COMPLICATIONS

As for all procedural management, there are possible immediate complications that can occur with the procedure such as bleeding and loss of airway, with additional delayed complications, that carry long-term risk such as tracheal stenosis. Mortality associated with tracheostomy is as low as 0–0.7%. Time-dependent classification of complications can be summarized as given in **Table 1**. Techniques to manage these are named alongside.

PREPARATION

Tracheostomy, whether performed bedside or surgically, requires meticulous patient selection, preoperative assessment, and equipment preparation to ensure safety and efficacy.

Patient Selection

A critical step includes identifying individuals likely to benefit from prolonged mechanical ventilation, airway protection, secretion management, with severe neurological injury, prolonged respiratory failure, or upper airway obstruction. Correction of coagulopathy, caution to unstable cervical spine injuries, and resolution of active neck infections can render an earlier unsuitable candidate, suitable for the procedure.

Preprocedural Investigations

Standard preoperative laboratories such as complete blood count, metabolic panel, and coagulation profile are checked. Chest and cervical radiographs can be demanded as warranted by the clinical assessment. Ultrasonography of neck can expose the presence of abnormal vascular structures and false tracts that can guide the procedure. Blood gas analysis can guide management in patients with high ventilator dependence.

JAYPEE BROTHERS

TABLE 1: Complications associated with tracheostomy and management.

Immediate	*Early delayed*	*Late delayed*
Occurs at the time of procedure	Occurs in the first few days after procedure	Occurs due to long standing tracheostomy tubes
• Bleeding (0.1–5%)—controlled with sutures, cautery, tube tamponade • Loss of airway and hypoxia—use of bronchoscope (FOB) as a guide to avoid false tracts, high flow nasal air supply, paraoxygenation, OST with ETT in situ • Pneumothorax (0.2%), pneumomediastinum, subcutaneous emphysema, posterior tracheal injury (1.6%)—FOB-guided procedures, capnography guidance • Recurrent laryngeal nerve palsy	• Infection (1.5–4%)—sterile technique, routine trach care, minimal sutures, PDT over OST • Tube occlusion and hypoxia—regular suctioning, and chest physiotherapy • Granulation tissue—cuff pressure management, use of cuffless trach tubes • Inadvertent decannulation—reinsertion (should not be replaced via the stoma if within 5 days of tracheostomy)	• Tracheal stenosis (1.7%) • Tube change complications • Decannulation failure

(ETT: endotracheal tube; FOB: fiberoptic bronchoscopy; OST: open surgical tracheostomy; PDT: percutaneous dilatational tracheostomy)

Preparation

- Any enteral feed is withheld for at least 6 hours to avoid risk of aspiration.
- Prophylactic or therapeutic anticoagulation if ongoing is continued or withheld as per risk–benefit ratio.
- Suctioning of orotracheal/nasotracheal tube is done if present.
- Sedation and muscle relaxants are chosen to prevent coughing, unwanted movement, and rise in intracranial pressure. Analgesics (fentanyl, remifentanil, midazolam, ketamine, and dexmedetomidine) can also be used without paralysis depending on patient hemodynamics. Local anesthetic for infiltration (1–2% lignocaine with 1:100,000 epinephrine) in case of PDT is prepared. For OST, anesthesia team will decide upon general anesthesia or local infiltration depending on patient factors.
- Standard monitors are observed such as blood pressure, capnography, plethysmography, and ECG.
- All equipment as required are prepared either bedside for PDT—fiberoptic bronchoscope, PDT kits (like Ciaglia Blue Rhino Advanced Percutaneous Tracheostomy set, Blue Dolphin kit), ultrasound machine (USG); or for OST—adequate lighting, Bovie cautery, sutures, suction, tracheal dilators, tracheal hooks, scissors, and scalpels **(Fig. 1)**.
- Emergency airway cart should be kept by stand.

Positioning

Positioning is done in the supine position with full neck and upper chest exposed, with a shoulder roll between the scapulae to provide Rose position. In those patients with unstable cervical spine, manual in line stabilization (MILS) is performed while extension as much as allowable with the help of sandbags and tape.

Skin is prepared using 0.5% chlorhexidine or betadine with all other aseptic precautions including hand hygiene. Draping is done to expose the target area and secured.

JAYPEE BROTHERS

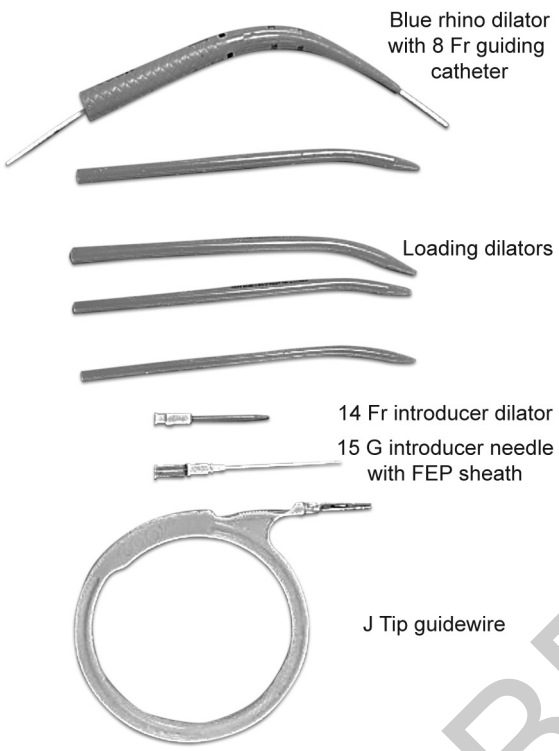

Fig. 1: Equipment setup for both percutaneous dilatational tracheostomy (PDT) and open surgical tracheostomy (OST). *(For color version, see Plate 2).*

PROCEDURE

Percutaneous Dilatational Tracheostomy

The *Ciaglia* technique, first used in 1985, is the original technique of PDT, making a skin incision, introducing a needle into the trachea, and dilating the opening with sequentially larger dilators to allow insertion of a TT. This is usually done in the space between the cricoid cartilage and first tracheal ring. Modifications of the *Ciaglia* technique include the use of lower tracheal rings and the use of a single, curved dilator. The *Griggs* guidewire-dilating forceps technique involves placing a guidewire through a skin incision followed by a dilating forceps like a grooved Howard-Kelly forceps. The *Fantoni* technique uses a needle inserted between the tracheal rings and directed cranially. With a guidewire directed toward the oral cavity, dilatation is done with a conic cannula over the guidewire through the oral cavity.

Classic Seldinger's Technique

The most widely used Ciaglia technique uses single-dilator kits. These include the Ciaglia Blue Rhino G2 Advanced Percutaneous Tracheostomy Kit (Cook Medical, Bloomington, IN), the Portex ULTRAperc Single-Stage Dilator (Smiths Medical, Minneapolis, MN), and the Dolphin BT Ciaglia Balloon-Assisted Tracheostomy Introducer (Cook Medical, Bloomington, IN).

- After positioning the patient as described, the anatomic landmarks are identified either by palpation method or with the help of USG.
- The skin and subcutaneous tissues are infiltrated with 2% lidocaine with 1:100,000 epinephrine two fingerbreadths below the identified cricoid cartilage.
- A 1.5-cm horizontal skin incision is made, and the subcutaneous tissues are bluntly separated with a curved artery forceps. The strap muscles or thyroid gland are not retracted.
- FOB is advanced through the ETT until its tip is aligned with the distal end of the ETT. If performing the procedure through laryngeal mask airway, the FB is advanced until the cricoid is visualized.
- FOB and ETT are withdrawn together slowly until the skin incision.
- After attaching a syringe to the 16 or 17-G introducer needle, this assembly is inserted via the incision site at a 45° angle in the midline in the caudad direction.
- When advancing the needle forward, entry into the trachea can be confirmed by aspiration of free air in the syringe.
- The needle is withdrawn, leaving the overlying catheter sheath. Placement in the trachea is

JAYPEE BROTHERS

again confirmed by aspiration through the syringe.
- A guidewire is placed through the catheter sheath.
- The sheath is removed and replaced by a 14-French introducer dilator to enlarge the tracheal aperture sufficiently and removed.
- A 12-French guiding catheter is inserted and left in place along with the guidewire.
- The single dilator is advanced over this unit several times, if necessary, until resistance is minimal.
- The chosen depth of dilatation depends on the size of the cannula to be inserted.
- The loading dilator is inserted into the TT.
- The dilator is replaced by the preloaded TT which is advanced into the trachea.
- The guidewire, guiding catheter, and dilator are removed and replaced by the inner cannula.
- The ventilatory apparatus is connected to the tracheostomy and secured at the four corner sutures.
- When ventilation is adequate, the ETT is removed while examining the vocal folds.
- A postoperative chest radiograph is obtained to rule out pneumothorax.

Special Concerns

- Always confirm access into the trachea by air bubble aspiration
- Maintain safety positioning marks of the guidewire, guiding catheters, and dilator during the dilating procedure to prevent trauma to the posterior wall of the trachea
- TT should fit snugly to the dilator for insertion.
- Generous lubrication of the surface of the dilator enhances fit and placement of the TT.
- In the event of accidental decannulation within 5 days of the procedure, it is advised to reintubate the patient orally rather than through the stoma.
- In a patient with a thick neck, a longer TT should be used to prevent accidental displacement of the tube into the pretracheal soft tissue.

Use of USG and FOB in PDT

Advantages to the use of FOB during PDT are multiple while there are some anticipated drawbacks such as increase in the duration and cost of procedure, carbon dioxide retention, and difficulty in ventilation via the ETT. The benefits include:

- Ease of performance of FOB
- Lowered risk of false passage, pneumomediastinum, pneumothorax, and subcutaneous emphysema
- Early detection and suctioning of blood and secretions
- Proper needle placement between the second and third tracheal rings
- Prevention of injury to the posterior tracheal wall.

Ultrasonography (USG) acts as a useful tool to identify the anatomy of airway, blood vessels, and surrounding structures such as the thyroid gland and isthmus.

Open Surgical Tracheostomy

Open surgical tracheostomy is a systematic, reliable procedure for establishing a secure airway, particularly in patients with complex anatomy or in emergency situations. It involves a stepwise dissection and controlled tracheal entry, with careful postoperative management to minimize complications. It is among the oldest surgical procedures, with evidence of its practice dating back to ancient Egypt around 3600 BC and references in early Indian and Greek texts. Major advances occurred in the 19th and 20th centuries, including the refinement of surgical technique by Chevalier Jackson in 1909, which emphasized meticulous postoperative care and significantly

JAYPEE BROTHERS

reduced mortality. The mid-20th century saw the procedure become integral in managing respiratory failure during polio epidemics, facilitated by the development of mechanical ventilation and intensive care units.

Technique

- The patient is usually intubated and under general anesthesia, but local anesthesia can be used if the patient is awake (like in Ludwig angina).
- Position the patient supine with neck extended to expose the anterior neck and identify and mark anatomical landmarks: thyroid notch, cricoid cartilage, and sternal notch.
- Mark a skin incision in the midline of the anterior neck, typically 1–2 cm inferior to the cricoid cartilage. The incision can be horizontal or vertical, about 3 cm in length.
- Incise through the skin and platysma muscle
- Identify and separate the strap muscles (sternohyoid and sternothyroid) along the midline raphe and retract them laterally to expose the trachea
- Identify the thyroid isthmus and ligate or retract it if necessary to expose the trachea
- Use a cricoid hook to elevate the larynx and trachea into the surgical field
- Identify the second and third tracheal rings, avoiding the first ring to reduce risk of stenosis
- Create a tracheal window by making an incision between the second and third rings
- The incision can be a horizontal slit or a square window; care is taken not to rupture the endotracheal tube cuff.
- Suction secretions generously to maintain a clear field
- The endotracheal tube is withdrawn slightly under surgeon's direction.
- Insert the TT gently into the tracheal opening, rotating it into place if needed
- Inflate the cuff of the TT
- Confirm correct placement by bilateral chest expansion, auscultation, and capnography (end-tidal CO_2)
- The cricoid hook is then removed.
- Secure the tube with sutures and ties or Velcro straps
- Apply a sterile tracheostomy dressing
- Post-procedure care:
  - Connect the tube to the ventilator circuit.
  - Obtain a chest X-ray to exclude complications such as pneumothorax.
  - Monitor airway pressures, oxygen saturations, and ventilator settings.

SPECIAL SCENARIOS

Tracheostomy in Obstetric Patients

Tracheostomy in obstetric patients presents unique challenges due to physiological changes in pregnancy and the need to balance maternal and fetal safety. Some key concerns include airway management complexity, coagulation changes, procedural and postoperative risks of preterm labor and infection, plan of delivery mode, anesthetic challenges, and risk of long-term complications.

Pregnancy-induced mucosal edema and weight gain can obscure anatomical landmarks, increasing technical difficulty. Elevated oxygen demand and reduced functional residual capacity heighten the risk of rapid desaturation during procedures. Hypercoagulability in pregnancy raises bleeding risks during tracheostomy, particularly in emergent settings. Surgical stress or anesthesia may precipitate preterm delivery. Prophylactic corticosteroids are often administered to enhance fetal lung maturity if early delivery is anticipated. Immunological adaptations in pregnancy may increase susceptibility to stomal infections. Meticulous wound care and antibiotic prophylaxis are critical. Although vaginal delivery is possible, it requires

JAYPEE BROTHERS

careful monitoring of intrathoracic pressure changes during labor, which may displace the TT. Cesarean section is preferred in cases of severe airway compromise or high risk of tube dislodgment. Apneic techniques (like THRIVE) or intermittent intubation may be needed during procedures, with heightened vigilance for aspiration risks due to delayed gastric emptying in pregnancy. Long-term complications like tracheal stenosis with prolonged intubation or tracheostomy might complicate future pregnancies.

Collaboration between obstetricians, anesthesiologists, surgeons, and neonatologists is essential to optimize outcomes. Preoperative planning should include fetal monitoring and contingency plans for emergent delivery.

Tracheostomy in Bariatric Patients

Tracheostomy in bariatric patients poses different challenges due to anatomical and physiological factors, with recent research highlighting strategies to mitigate risks and improve outcomes. Anatomical difficulties are prime, with obesity obscuring neck landmarks (thyroid cartilage and cricoid membrane), and increasing technical complexity suggested by the prolonged operative times (54.9 vs. 39.6 minutes in nonobese patients) due to difficulty in dissection and positioning. The presence of thick pretracheal soft tissue often necessitates extended-length TT to prevent dislodgment. The higher rates of accidental decannulation (13.7% vs. 5.6% in nonobese patients), often linked to Bjork flap modifications and complications, including TT obstruction and extratracheal placement, also add to the liability. Class III obesity [body mass index (BMI) >40 kg/m^2] correlates with higher rates of postoperative complications or death. These patients are at increased infection risk due to poor wound healing and compromised immunity.

Factoring in these challenges, different advances are in place like the use of wire-reinforced silicone TT with adjustable flanges to reduce displacement risk in patients with thick pretracheal tissue and extended-length tubes as standard for BMI >40. USG and videoendoscopy improve safety during PDT in obese patients, reducing reliance on open surgical methods. Even though morbidly obese patients experience delayed tracheostomy timing but no increased 30-day mortality, early multidisciplinary planning is advocated to optimize timing.

During the procedure, use of ramped positioning and videolaryngoscopy enhance airway visualization. Bjork flap creation and cervical lipectomy improve tube stability. Postoperative protocols emphasizing tube securement (sutured flanges, Velcro ties) need to be in place. Prophylactic antibiotics and nutritional optimization are needed to reduce infection risks. Recent studies underscore the importance of early intervention and specialized equipment to address anatomical challenges in this population.

Tracheostomy in Pediatric Patients

Pediatric ICU tracheostomies present distinct challenges as mortality rates range from 8 to 20%, driven by comorbidities like congenital anomalies, neurological impairment, and infections. Tube obstruction (7.69%) and accidental decannulation (16.1%) are life-threatening complications with smaller airways and dynamic growth increasing the procedural risks. Infants (<1 year) face higher stenosis risks due to narrower tracheal diameters. Emergent tracheostomies in conditions such as subglottic stenosis or Down syndrome require precise surgical skill to avoid false passages or pneumothorax.

Discharge planning requires training caregivers in tube management, suctioning, and emergency protocols. Up to 32.3% of patients are discharged with TT in situ. New research supports a shift from upper airway obstruction (49.2%) to prolonged mechanical ventilation (50.8%) as

JAYPEE BROTHERS

primary indications. ET (median 11 days) has shown to reduce ICU stay in ventilated children although final call requires individualized decisions. Opting for bedside PDT with USG guidance to minimize or transfer, sedation and anesthesia concerns make it difficult. Customized pediatric tubes with inner cannulas that reduce TT blocks and Mini-tracheostomy kits improve care and outcomes.

Successful decannulation rates reach 76% with endoscopic airway assessments and gradual downsizing. Predictors include resolution of primary pathology and adequate cough reflex. Prolonged tube dependency in neuromuscular diseases (e.g., spinal muscular atrophy) complicates decannulation. Multidisciplinary teams (ENT, ICU, respiratory therapists, and caregivers) reduce complications such as tracheoinnominate fistula (1.6%) and lower readmission rates.

KEY POINTS

- Bedside PDT is now commonly performed by intensivists and pulmonologists, not just surgeons, allowing for more timely and accessible procedures in the ICU.
- Multidisciplinary tracheostomy teams (including intensivists, nurses, speech therapists, and others) have been shown to reduce adverse events, ICU/hospital length of stay, and time to decannulation, while improving communication and patient outcomes.
- Recent large trials (e.g., TracMan, SETPOINT2) show that early tracheostomy (within 3–7 days) does not significantly reduce mortality or VAP compared to late tracheostomy, but it may reduce sedation requirements and facilitate earlier oral intake and liberation from mechanical ventilation in select populations.
- Delayed tracheostomy is associated with increased risk of subglottic stenosis, particularly highlighted during the COVID-19 pandemic.
- There is greater focus on safe discharge from ICU, ensuring appropriate equipment, training, and standards are maintained in all care settings for patients with tracheostomies.
- Tracheostomy in obstetric patients presents unique challenges due to physiological changes in pregnancy and the need to balance maternal and fetal safety.
- Use of RAMP, videolaryngoscopy and FOB, Bjork flap creation, cervical lipectomy, special long TT, role of prophylactic antibiotics, and nutritional optimization make ET in bariatric patients safer despite difficulty in anatomy and technique.

SUGGESTED READING

1. Barrera SC, Sanford EJ, Ammerman SB, Ferrell JK, Simpson CB, Dominguez LM. Postoperative Complications in Obese Patients After Tracheostomy. OTO Open. 2020;4(3):2473974X20953090.
2. Bathwal R, Dongol K, Dutta H, Neupane Y. Tracheostomy among Children Admitted in the Pediatric Intensive Care Unit of a Tertiary Care Centre. JNMA J Nepal Med Assoc. 2023;61(267):852-5.
3. Boni A, Tonietto TA, Rihl MF, Viana MV. Early versus late tracheostomy in critically ill patients: an umbrella review of systematic reviews of randomised clinical trials with meta-analyses and trial sequential analysis. BMJ Open Respir Res. 2025;12(1):e002434.
4. Chanana C, Kumar S, Malhotra N, Sharma JB, Roy KK. Pregnancy followed by caesarean delivery in a patient with tracheostomy and gastrostomy after corrosive acid ingestion. Arch Gynecol Obstet. 2007;275(4):295-6.
5. Cheung NH, Napolitano LM. Tracheostomy: epidemiology, indications, timing, technique, and outcomes. Respir Care. 2014;59(6):895-915; discussion 916-9.
6. Cramer JD, Graboyes EM, Brenner MJ. Mortality associated with tracheostomy complications in the United States: 2007-2016. Laryngoscope. 2019;129(3):619-26.
7. El Solh AA, Jaafar W. A comparative study of the complications of surgical tracheostomy in morbidly obese critically ill patients. Crit Care. 2007;11(1):R3.
8. Huang HY, Huang CY, Li LF. Prolonged Mechanical Ventilation: Outcomes and Management. J Clin Med. 2022;11(9):2451.

JAYPEE BROTHERS

9. Javed H, Olanrewaju OA, Ansah Owusu F, Saleem A, Pavani P, Tariq H, et al. Challenges and Solutions in Postoperative Complications: A Narrative Review in General Surgery. Cureus. 2023;15(12):e50942.
10. Karparvar Z, Goldenberg D. Introduction: the history of tracheotomy. In: Seidman PA, Sinz EH, Goldenberg D, (Eds). Tracheotomy Management: A Multidisciplinary Approach. England: Cambridge University Press; 2011. pp. 1-11.
11. Kerns AK, Mahoney R, Deeds K, Boone-Edwards K, Ross M, Siegel B. A Quality Improvement Plan for Implementing an Innovative Organization System for Pediatric Airway Patients. J Pediatr Intensive Care. 2020;11(2):120-3.
12. Kumar P, Kumar S, Hussain M, Singh R, Ahmed W, Anand R. Comparison of percutaneous tracheostomy methods in ICU patients: Conventional anatomical landmark method versus ultrasonography method - A randomised controlled trial. Indian J Anaesth. 2022;66(Suppl 4):S207-S212.
13. Lee M, Wilson H. (2021). Complications of tracheostomy. Shanghai Chest. 2021;5:42.
14. Liew WJ, Negar A, Singh PA. Airway management in patients suffering from morbid obesity. Saudi J Anaesth. 2022;16(3):314-21.
15. Lin WC, Chen CW, Wang JD, Tsai LM. Is tracheostomy a better choice than translaryngeal intubation for critically ill patients requiring mechanical ventilation for more than 14 days? A comparison of short-term outcomes. BMC Anesthesiol. 2015;15:181.
16. Marra A, Vargas M, Buonanno P, Iacovazzo C, Coviello A, Servillo G. Early vs. Late Tracheostomy in Patients with Traumatic Brain Injury: Systematic Review and Meta-Analysis. J Clin Med. 2021;10(15):3319.
17. Marullo L, Izzo G, Torino A, D'Elia A, Vessicchio L, Ferraro F. Tracheostomy in obese patients: the best tube choice issue. Crit Care. 2014;18(Suppl 1):P320.
18. Mehta AK, Chamyal PC. Tracheostomy complications and their management. Med J Armed Forces India. 1999;55(3):197-200.
19. Merola R, Iacovazzo C, Troise S, Marra A, Formichella A, Servillo G, et al. Timing of Tracheostomy in ICU Patients: A Systematic Review and Meta-Analysis of Randomized Controlled Trials. Life (Basel). 2024;14(9):1165.
20. Miller EJ, Huning EY. Subglottic tracheal stenosis complicating pregnancy: A case report. Obstet Med. 2022;15(3):205-7.
21. Mishra P, Sharma S, Otiv M, Kapadia M. Pediatric tracheostomy: indications and outcomes from Indian tertiary care centre. Int J Otorhinolaryngol Head Neck Surg. 2019;5(3):750-4.
22. Pierson DJ. Tracheostomy from A to Z: historical context and current challenges. Respir Care. 2005;50(4):473-5.
23. Raimonde AJ, Westhoven N, Winters R. Tracheostomy. In: StatPearls [Internet]. Treasure Island (FL): StatPearls Publishing; 2025.
24. Sachdev A, Chaudhari ND, Singh BP, Sharma N, Gupta D, Gupta N, et al. Tracheostomy in Pediatric Intensive Care Unit-A Two Decades of Experience. Indian J Crit Care Med. 2021;25(7):803-11.
25. Sutt AL, Caruana LR, Dunster KR, Cornwell PL, Anstey CM, Fraser JF. Speaking valves in tracheostomised ICU patients weaning off mechanical ventilation--do they facilitate lung recruitment? Crit Care. 2016;20:91.
26. Tanaka A, Uchiyama A, Kitamura T, Sakaguchi R, Komukai S, Matsuyama T, et al. Association between early tracheostomy and patient outcomes in critically ill patients on mechanical ventilation: a multicenter cohort study. J Intensive Care. 2022;10(1):19.
27. Whitmore KA, Townsend SC, Laupland KB. Management of tracheostomies in the intensive care unit: a scoping review. BMJ Open Respir Res. 2020;7(1):e000651.
28. Young D, Harrison DA, Cuthbertson BH, Rowan K; TracMan Collaborators. Effect of early vs late tracheostomy placement on survival in patients receiving mechanical ventilation: the TracMan randomized trial. JAMA. 2013;309(20):2121-9.
29. Yousef A, Soliman SI, Solomon I, Panuganti BA, Francis DO, Pang J, et al. Impact of Obesity on Timing of Tracheotomy: A Multi-institutional Retrospective Study. Laryngoscope. 2024;134(11):4674-81.

JAYPEE BROTHERS

for detailed information on critical care books, visit our website www.ejaypee.com, for detailed information on critical care books, visit our website www.ejay

Intervention for Intensivists

Salient Features

- Simplified stepwise procedure
- Ultrasonography- and Fiberoptic Bronchoscope-guided procedure videos
- Latest guidelines incorporated
- Examination-oriented headlines
- Easy QR code access.



Puneet Khanna MD is a Professor, Department of Anesthesiology, Pain Medicine, and Critical Care, All India Institute of Medical Sciences (AIIMS), New Delhi, India. He did his MD and Senior Residency from AIIMS, New Delhi and after a brief stint as an Assistant Professor at the Postgraduate Institute of Medical Education and Research (PGIMER), Chandigarh, he came back to his alma mater. He is extremely passionate about his work and has a keen interest in academics and research. He has close to 300 publications in both national and international journals to his credit.



Anjaleekrishna K MD is a Senior Resident, Department of Anesthesiology, Pain Medicine, and Critical Care, All India Institute of Medical Sciences (AIIMS), New Delhi, India. She completed her MBBS from AIIMS, Bhopal and MD (Anesthesiology) from AIIMS, New Delhi. She is passionate about academics, teaching, and research, with special interests in airway management, pediatric anesthesia, and perioperative medicine. Her research focuses on postoperative cognitive dysfunction, delirium, and difficult airway management in special clinical scenarios. She has received the Koreanesthesia Research Grant and several awards for scientific presentations. She has contributed to multiple academic books and educational resources and is a regular Contributor to the Indian Society of Anaesthesiologists' Clinical Newsletter. Beyond her clinical and academic pursuits, she has been actively involved in institutional and professional initiatives promoting medical education and academic excellence.

Shelving Recommendation
CRITICAL CARE

ISBN 978-93-7806-132-5

9 789378 061325

Buy from ejaypee

JAYPEE BROTHERS