omy books, visit our website www.ejaypee.com, for detailed information on anatomy books, visit our website www.ejaypee.com, for detailed information on anatomy books

Inderbir Singh's HUMAN EMBRYOLOGY

BEST SELLER Since 50 Years

With Clinically Integrated Approach

Free Book 'One Stop Resource for All Your Exam Needs'

As per the Revised Competency-based Medical Education Curriculum (NMC)

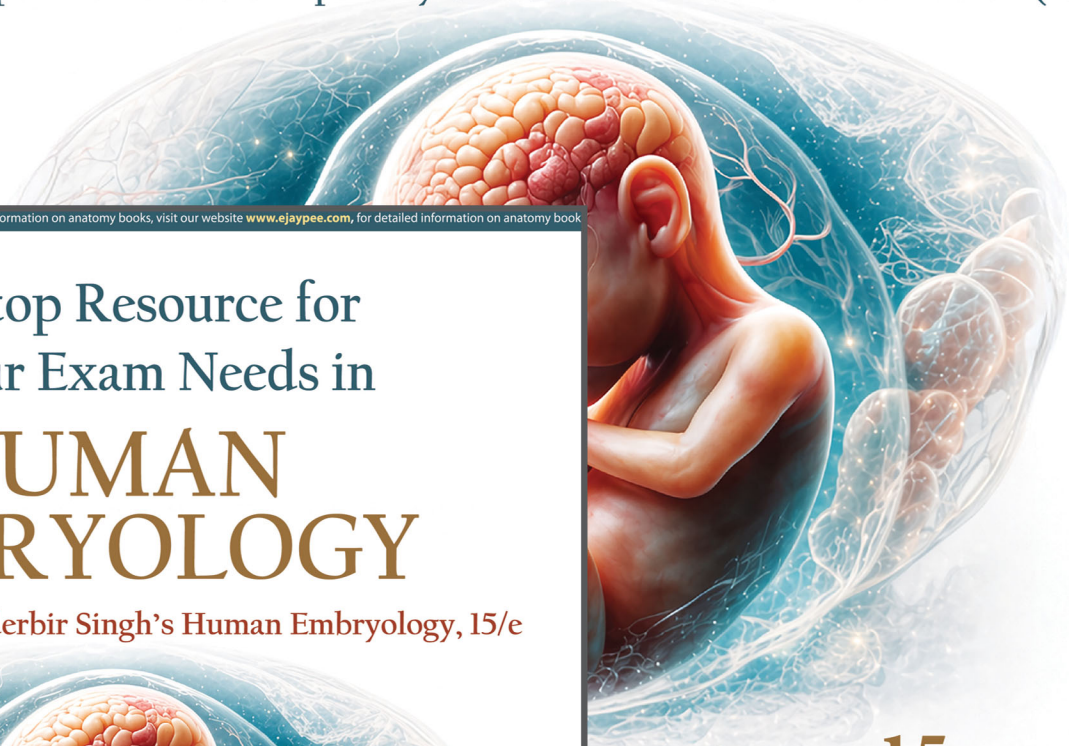

natomy books, visit our website www.ejaypee.com, for detailed information on anatomy books, visit our website www.ejaypee.com, for detailed information on anatomy book

One Stop Resource for All Your Exam Needs in HUMAN EMBRYOLOGY

Complementary to Inderbir Singh's Human Embryology, 15/e



Edited by Raveendranath Veeramani

- Frequently asked previous year theory questions with answers
- Reasoning type questions
- Multiple choice questions

JAYPEE

...amani

15th Edition

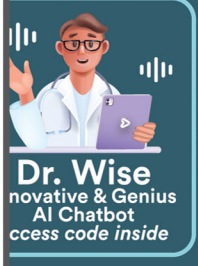

Dr. Wise
novative & Genius
AI Chatbot
ccess code inside

JAYPEE

Contents

Chapter 1: Some Preliminary Considerations 1

- What is Embryology? *1*
- Reproduction *1*
- Development and Stages of Human Life *2*
- Pregnancy/Gestation, Trimesters, Viability *2*
- Basic Processes in Embryology *4*

Chapter 2: Molecular Aspect of Embryology 7

- Chromosomes *7*
- Karyotyping *10*
- Lyon Hypothesis and Sex Chromatin *11*

Cell Cycle and Cell Division *12*

- Cell Cycle *12*
- Cell Division *12*
- Mitosis *12*
- Meiosis *14*
- Molecular Control of Development of Embryo *15*

Chapter 3: Gametogenesis, Ovarian and Menstrual Cycle 19

- Structure of a Mature Spermatozoon *19*
- Spermatogenesis *20*
- Oogenesis *22*
- Ovarian Cycle *23*
- Menstrual Cycle *26*
- Hormonal Control of Ovarian and Uterine Cycles *29*

Chapter 4: First Week of Development 35

- Overview of First Week of Development *35*
- Fertilization *35*
- Test Tube Babies/In Vitro Fertilization *39*
- Sex Determination *39*
- Cleavage *39*
- Implantation *41*
- Changes in the Endometrium of the Uterus *44*

Chapter 5: Second Week of Development 48

- Events of Second Week of Development *48*
- Changes in the Embryoblast *48*
- Changes in the Trophoblast *50*

Chapter 6: Third Week of Development 58

- Overview of Third Week of Development *58*
- Changes in the Germ Disc or Embryonic Area *58*
- Formation of Primitive Streak *59*
- Gastrulation *60*
- Formation of Notochord *60*
- Formation of the Neural Tube *62*
- Formation of Intraembryonic Mesoderm (Third Germ Layer) *63*
- Changes in the Trophoblast *66*

Chapter 7: Embryonic Period (Fourth to Eighth Week) of Development 68

- Growth of the Embryo and its Age Determination *68*

Embryonic Period *69*

- Folding of Embryo *69*
- Derivatives of Germ Layers *73*

Chapter 8: Fetal Period of Development, Prenatal Diagnosis and Teratology 77

- Fetal Period *77*
- Determining the Age of a Living Fetus *78*
- Teratology and Birth Defects *79*
- Prenatal Diagnosis of Fetus *80*
- Fetal Therapy *81*

Chapter 9: Fetal Membranes, Placenta and Twinning 85

- Fetal/Extraembryonic Membranes *85*
- Placenta *88*
- Mutual Relationship of Amniotic Cavity, Extraembryonic Coelom and Uterine Cavity *93*
- Multiple Births and Twinning *94*

Chapter 10: Basic Tissues of the Body 101

- Epithelia *101*
- Connective Tissue *102*
- Muscular Tissue *111*
- Nervous Tissue *113*

Chapter 11: Integumentary System (Skin and its Appendages, Mammary Gland) 118

- Skin *118*
- Appendages of Skin *120*
- Mammary Glands *122*

Chapter 12: Branchial Apparatus (Pharyngeal Arches, Endodermal Pouches and Ectodermal Clefts) 126

- Pharyngeal or Brachial Arches *126*

- Derivatives of the Skeletal Elements 128
- Nerves and Muscles of the Arches 128
- Fate of Ectodermal Clefts 130
- Fate of Endodermal Pouches 131
- Pharyngeal Membranes 132
- Development of Palatine Tonsils 132
- Development of the Thymus 132
- Development of Parathyroid Glands 132
- Development of the Thyroid Gland 133

Chapter 13: Skeletal and Muscular System 138

Skeletal System *138*

- Axial Skeleton 138
- Appendicular Skeleton 143

Muscular System *145*

- Skeletal Muscle 145
- Development of Muscular System 146

Chapter 14: Face, Nose and Palate 150

- Development of Face 150
- Development of Nose 155
- Development of the Palate 156

Chapter 15: Alimentary System—I: Oral Cavity, Salivary Glands and Pharynx 161

- Development of Mouth 161
- Development of Teeth 162
- Development of Tongue 165
- Development of Salivary Glands 167
- Development of Tonsils 168
- Development of Pharynx 168

Chapter 16: Alimentary System—II: Gastrointestinal Tract 171

- Derivatives of All Three Segments of the Primitive Gut 173
- Development of Individual Parts of Gut 173
- Rotation of the Gut 183
- Fixation of the Gut 184

Chapter 17: Liver and Biliary Apparatus; Pancreas and Spleen 189

Liver and Biliary Apparatus *189*

- The Liver 189
- Gallbladder and Biliary Passages 191

Pancreas and Spleen *192*

- Pancreas 192
- Spleen 195

Chapter 18: Body Cavities and Diaphragm 200

- Body Cavities 200
- Diaphragm 206

Chapter 19: Respiratory System 211

- Overview of Respiratory System Development 211
- Development of Larynx 212
- Development of Trachea 213
- Development of Lungs 214

Chapter 20: Cardiovascular System 219

Heart *219*

- Development of Heart Tube 219
- Development of Various Chambers of Heart 220
- Exterior Shape of Heart 228
- Layers of Cardiac Wall 229
- Valves of the Heart 230
- Conducting System of Heart 231
- Pericardial Cavity 231

Development of Blood Vessels *233*

- Development of Arteries 233
- Development of Veins 240

Fetal Circulation *248*

- Changes in the Circulation at Birth 250

Lymphatic System *251*

Chapter 21: Urogenital System 258

- Intermediate Mesoderm 258
- Cloaca 259

Urinary System *259*

- Development of Kidneys 259
- Absorption of Lower Parts of Mesonephric Ducts into Cloaca 262
- Development of the Ureter 262
- Development of the Urinary Bladder 262
- Development of Urethra 264
- Development of the Prostate 266

Genital System *266*

- Female Genital System 266
- Development of External Genitalia 269
- Development of Gametes Producing Organs 272
- Fate of Mesonephric Duct 277

Chapter 22: Nervous System 283

- Neural Tube and its Subdivisions 283
- Development of Brain 283

- Neural Crest Cells *285*
- Spinal Cord *288*
- Medulla Oblongata *290*
- Pons *291*
- Midbrain *292*
- Cerebellum *293*
- Cerebral Hemisphere *293*
- Autonomic Nervous System *301*

Chapter 23: Pituitary, Pineal and Adrenal Glands 306

- Hypophysis Cerebri/Pituitary Gland *306*
- Pineal Gland/Epiphysis Cerebri *307*
- Adrenal Gland/Suprarenal Gland *307*

Chapter 24: The Eye and Ear 310

- Development of the Eye *310*
- Development of the Ear *317*

Chapter 25: Chromosomal and Genetic Abnormalities 325

- Chromosomal Abnormalities *325*
- Allele *328*
- Gene Polymorphism and Mutation *328*
- Punnett Square *329*
- Inheritance of Genetic Disorders *329*
- Genetic Counseling *333*

Index* *335

4

CHAPTER

First Week of Development

COMPETENCIES COVERED/LEARNING OUTCOMES

The student should be able to:

AN77.4	Describe the stages and consequences of fertilization.
AN77.5	Enumerate and describe the anatomical principles underlying contraception.
AN77.6	Describe teratogenic influences: fertility and sterility, surrogate motherhood, social significance of "sex- ratio".
AN78.1	Describe cleavage and formation of blastocyst.
AN78.2	Describe the development of trophoblast.
AN78.3	Describe the process of implantation and common abnormal sites of implantation.
AN78.5	Describe decidual reaction; abortion and pregnancy test.

JAYPEE BROTHERS

As discussed in Chapter 1 about the stages of human development, the germinal period is most crucial for human embryonic development. This stage spans from the first to the third week of development. It begins with fertilization and includes the initial cell divisions and differentiation of the germ layers.

We will discuss the embryonic development during the first week, second week and third week in detail in separate chapters.

OVERVIEW OF FIRST WEEK OF DEVELOPMENT

Ovum is released from ovary and in case of absence of spermatozoon in the uterine tube, it degenerates, and menstrual cycle goes on. But in case sperm penetrates the ovum, fertilization happens, and series of events takes place to form the zygote.

Human embryonic development starts from the stage of fertilization. During the first week of embryonic development, following series of events occur until the fertilized ovum is implanted in the uterus:

1. **Fertilization:** The process begins with the fertilization of the ovum by a sperm cell, forming a ***zygote***. This typically occurs in the ampulla of the fallopian tube.
2. **Cleavage:** The zygote undergoes rapid mitotic divisions, known as ***cleavage***, without increasing in size, resulting in a cluster of smaller cells called ***blastomeres***.
3. **Morula formation:** By day 3–4 postfertilization, the cells compact into a solid ball known as the ***morula*.**
4. **Blastocyst formation:** Around day 5–6, the morula develops into a ***blastocyst***, consisting of an inner cell mass ***(embryoblast)*** and an outer cell layer (the ***trophoblast***, which will form the placenta).
5. **Implantation:** By the end of the first week, the blastocyst reaches the uterus and begins the process of implantation into the endometrial lining, which will provide it with the necessary nutrients for further development.

These stages are critical for establishing the foundation for all subsequent development and successful pregnancy.

Changes in ovum from maturation to fertilization are shown in **Figure 4.1**.

FERTILIZATION

Definition

Fertilization is the process of fusion of mature/highly differentiated male gamete (spermatozoon) and female gamete (ovum) to form the undifferentiated diploid mono-nucleated single cell, the zygote.

Human fertilization is a complex process and involves many steps. Male and female gametes must undergo several biological processes before fertilization occurs.

Site and time of fertilization is shown in **Figure 4.2**.

Stages of Fertilization

The process of fertilization takes place in three major steps which are:

1. Gametes approximation
2. Fusion of gametes with completion of meiosis II
3. Formation of zygote and results of fertilization

Gametes Approximation

- **Transport of spermatozoon:** After spermatozoa deposition, uterine contraction is stimulated by

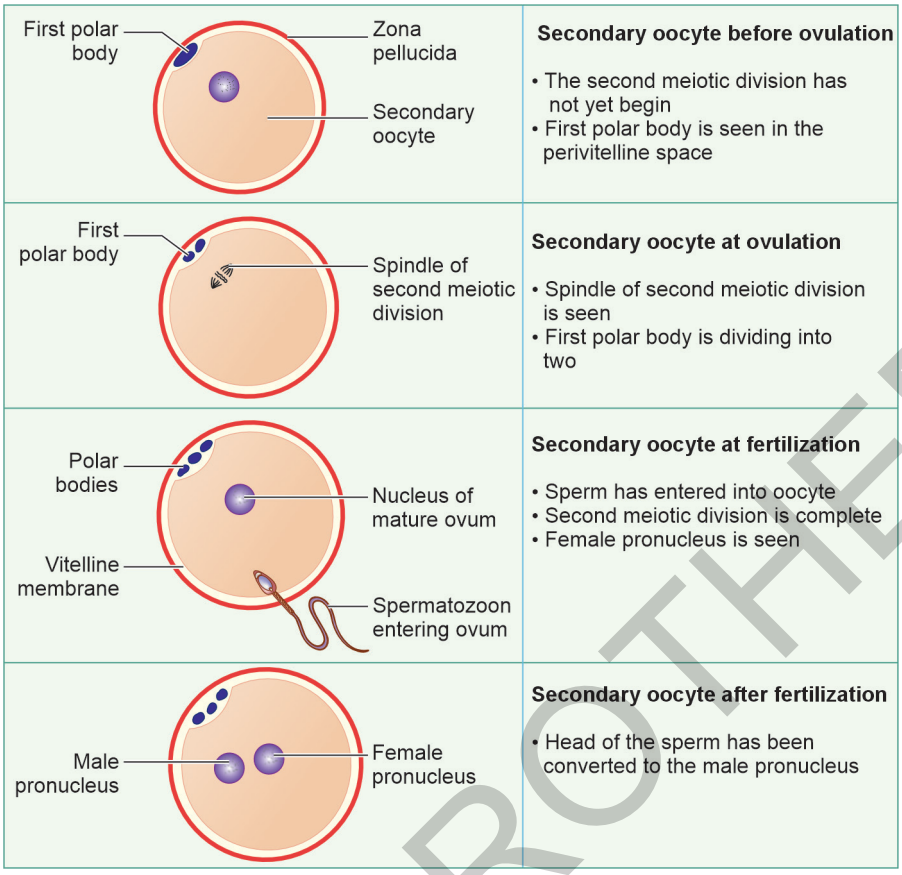

FIG. 4.1: Stages of maturation of ovum during different phases.

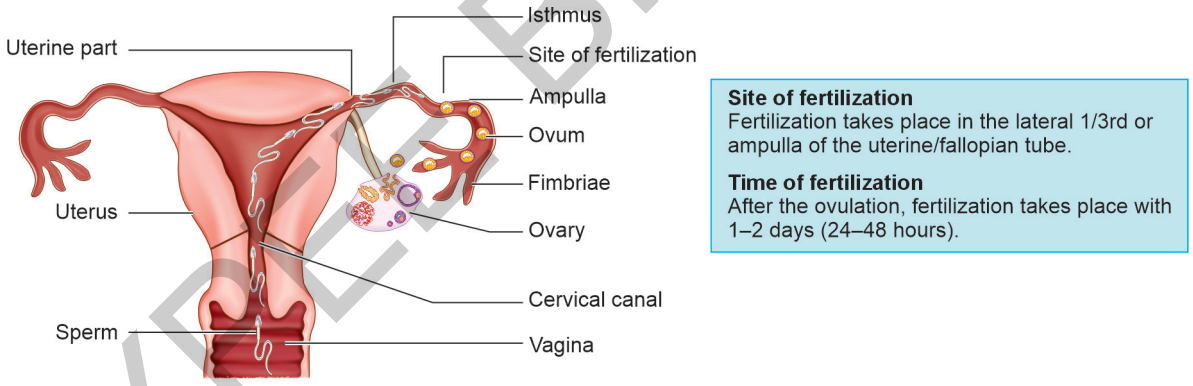

FIG. 4.2: Path taken by the sperm (red), and ovum (blue), site and time of fertilization.

prostaglandins in the semen and oxytocin released during the coital reflex. Most spermatozoa die within 24 to 48 hours after ejaculation and they are gradually reduced in number by constrictions at the cervix and uterine ostium. Approximately 200–500 million sperm are deposited in the female reproductive tract, but only about 300–500 reach the site of fertilization. The spermatozoa are attracted to the ovum by the method of chemotaxis, i.e., release of certain chemical by the follicular cells of ovum.

- **Transport of ovum:** In contrast to spermatozoa, the ciliary beats and rhythmic muscular contractions of the uterine tube are responsible for transcoelomic migration of ovum from the surface of ovary into the ampulla of uterine tube. The ovum released during ovulation remains viable for 24–48 hours. If fertilization does not occur, it degenerates.

Typically, both sperm and the oocyte reach the ampulla of the fallopian tube as shown in **Figure 4.2**.

- **Capacitation** is a series of physiological changes that spermatozoon undergoes to acquire the ability to fertilize an egg. This process occurs in the uterus or uterine tube.As already discussed in Chapter 2, capacitation is important for ***acrosome reaction***.
- Specific proteins and signaling pathways are activated during capacitation, leading to changes in sperm motility patterns, known as ***hyperactivation.***

JAYPEE BROTHERS

- Hyperactivated sperm exhibit a more vigorous and erratic swimming pattern, which helps them navigate the female reproductive tract and penetrate the zona pellucida.

Fusion of Gametes

The ovum has three primary barriers that sperm must penetrate to achieve fertilization:

1. Corona radiata
2. Zona pellucida
3. Vitelline membrane

For spermatozoon to penetrate the ovum, four processes are involved as discussed below **(Figs. 4.3A to D)**.

- **Acrosome reaction:** During the acrosome reaction, enzymes such as hyaluronidase, acrosin and acid phosphatase are released from the acrosome, a cap-like structure covering the sperm head. These enzymes cause the disintegration of the covering of sperm head which comprises of nuclear envelope, acrosomal membrane and plasma membrane. It occurs when sperms come in contact with corona radiata of the oocyte.
- **Barriers disintegration:**
  - *Corona radiata:* Penetration of the first barrier relies on the release of hyaluronidase from the sperm's acrosome. Tubal mucosal enzymes and the movements of the sperm's tail also assist sperm in penetrating the corona radiata. The

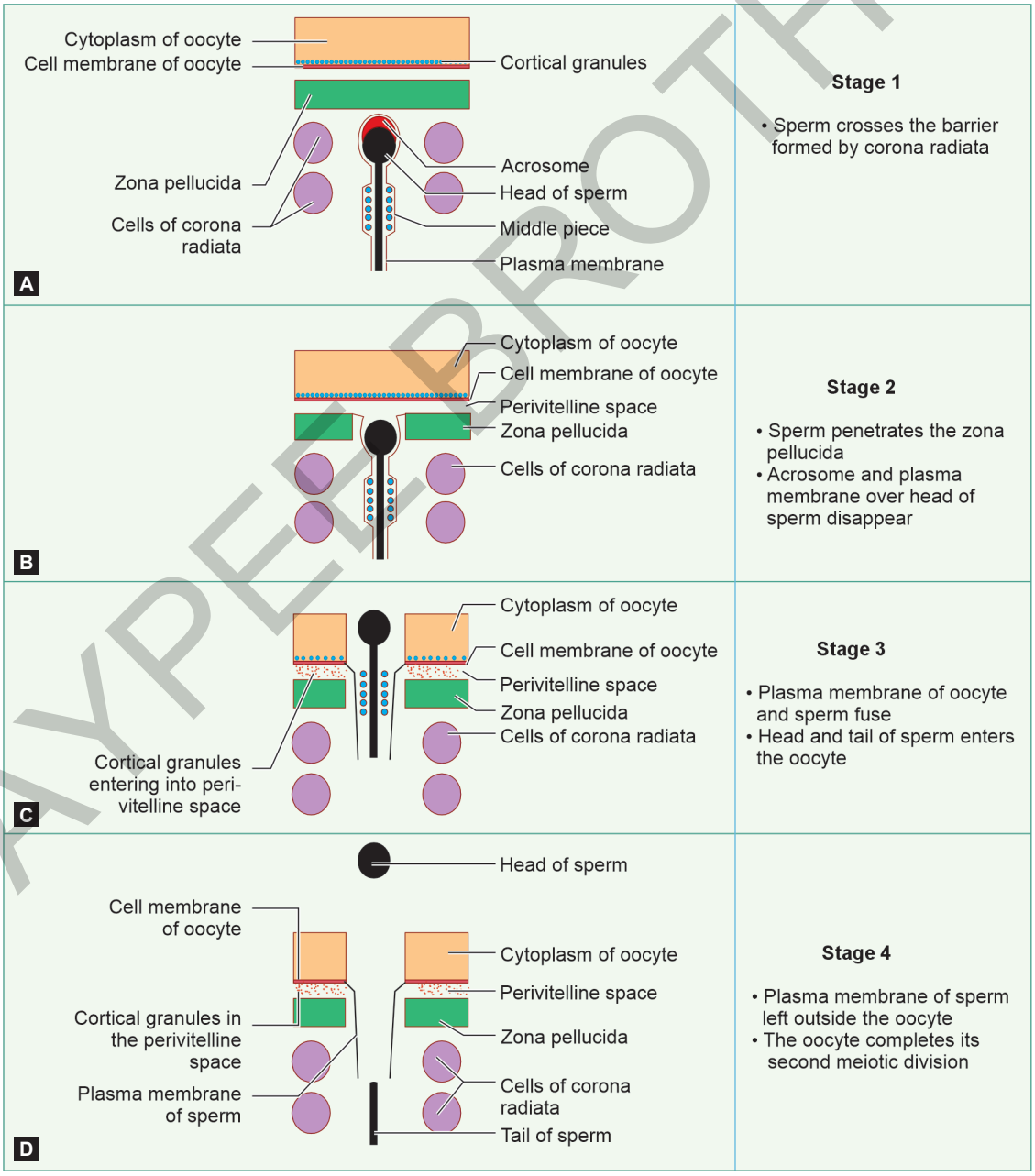

FIGS. 4.3A to D: Stages in penetration of a spermatozoon into an ovum.

JAYPEE BROTHERS

hyaluronidase enzyme digests the cells of the corona radiata, enabling the sperm to enter the ovum.

- *Zona pellucida:* Glycoproteins on the sperm head bind to glycoproteins on the ovum's zona pellucida, specifically to Zp3 and Zp2 receptors. Acrosin then dissolves the zona pellucida around the sperm head. The zona pellucida is altered due to lysosomal enzymes released by the oocyte's plasma membrane, a process known as ***the zona reaction***. Alterations in plasma membrane of oocyte and zona pellucida ensures that no other spermatozoon enters the oocyte, thus preventing ***polyspermy***.
- *Vitelline membrane:* When a spermatozoon contacts the oocyte, their plasma membranes fuse together, likely at species-specific receptor sites. Fusion is initiated by the disintegrin peptide released from the sperm head, while integrin peptides are present in the vitelline membrane. This fusion process typically takes about 30 minutes.

NOTE

Upon the entry of a single sperm, a cascade of cellular processes known as the ***cortical reaction*** occurs. This reaction aims to create an impermeable zona pellucida, preventing ***polyspermy***. Cortical granules are released and secrete serine proteases, peroxidases, and glycosaminoglycans. These enzymes work to cleave protein connections, removing receptors, and to harden the vitelline envelope. Additionally, they attract water into the perivitelline space, creating a gap to form the hyaline layer.

- **Calcium wave in oocyte:** Upon sperm entry into the oocyte, it triggers the release of calcium ions from intracellular stores within the oocyte, such as the endoplasmic reticulum. The calcium wave spreads throughout the oocyte in a wave-like fashion, signaling various cellular processes essential for fertilization, including the completion of meiosis, activation of the oocyte, and initiation of embryo development.
- **Fusion of nucleus:** Only the sperm head and midpiece enter the ovum, while the tail, plasma membrane and remaining parts are left outside. ***The sperm's mitochondria, located in the midpiece, are typically degraded, ensuring that only maternal mitochondria are passed on to the offspring***. With nuclear fusion, following events occur:
  - The entry of the sperm into the ovum triggers the ***completion of the second meiotic division*** in the ovum, which had been arrested at metaphase II during ovulation.
  - This division results in the ***formation of the female pronucleus*** and the extrusion of the second polar body, which is a small cell containing excess genetic material.
  - After the sperm enters the ovum, its nuclear envelope disintegrates, and the chromatin decondenses resulting in ***formation of the male pronucleus***.
  - The fusion of the male and female pronuclei forms a single diploid nucleus with 46 chromosomes resulting in ***formation of zygote***, which contains complete set of genetic material.

NOTE

The first polar body may also divide during meiosis II, creating two smaller polar bodies. Therefore, the total number of polar bodies formed is typically three.

Formation of Zygote and Results of Fertilization

With fertilization of male and female gamete, zygote is formed. This undergoes cleavage to form the multicellular structures. From what we have discussed so far, the results of fertilization are as follows:

- Fertilization results in completion of second meiotic division of ovum and release of the second polar body.
- The ovum's nucleus becomes the female pronucleus, and the sperm's head becomes the male pronucleus **(Fig. 4.4A)**. These pronuclei lose their nuclear membranes, and their 23 haploid chromosomes each combine resulting in fusion to form 23 pairs, totaling 46 diploid chromosomes **(Fig. 4.4B)**.
- Determination of chromosomal sex takes place.
- The fertilized ovum (zygote) begins to divide into several cells (i.e., it undergoes cleavage). After fertilization and formation of 46 chromosomes, it undergoes mitotic division to form a two-cell embryo **(Fig. 4.4C)**.

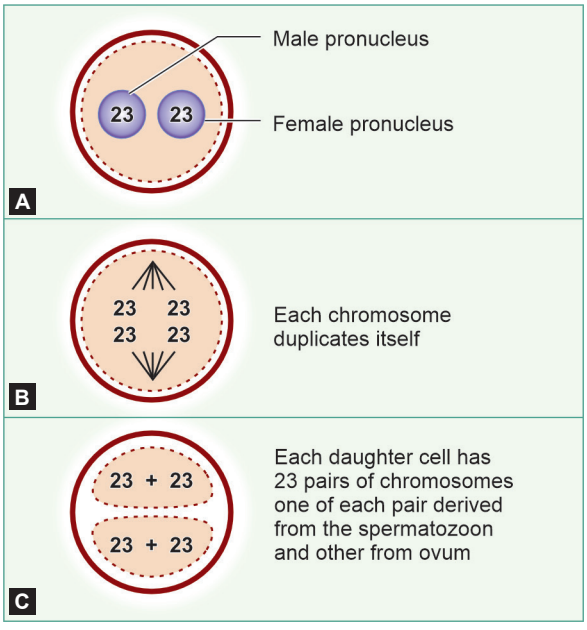

FIGS. 4.4A to C: Behavior of chromosomes during fertilization. The female pronucleus has 22 + X chromosomes. The male pronucleus may have 22 + X or 22 + Y chromosomes.

JAYPEE BROTHERS

The important points to note at this stage are that:

- The two daughter cells are still surrounded by the zona pellucida **(Figs. 4.1 and 4.3)**
- Each daughter cell is much smaller than the ovum.
- With subsequent divisions, the cells become smaller and smaller until they acquire the size of most cells of the body.

Clinical Importance

- **Fertility:** The ability to conceive a child or become pregnant is called fertility.
- **Sterility:** Sterility refers to the absolute inability to conceive or induce conception after one year of regular, unprotected sexual intercourse. Unlike infertility, which implies a reduced ability to conceive, sterility indicates a complete lack of reproductive capacity.
- **Infertility:** Infertility is the inability to conceive a child after one year of regular, unprotected sexual intercourse. Unlike sterility, infertility suggests a reduced or impaired ability to achieve pregnancy, which may be due to factors affecting either partner, such as ovulatory disorders, sperm abnormalities, tubal blockage, or other reproductive system dysfunctions. Infertility can sometimes be treated or managed with medical interventions.
- **Surrogacy:** Surrogacy is a method of assisted reproduction where a woman, known as a surrogate, carries and delivers a child for another person or couple. This process can be beneficial for individuals who are unable to conceive or carry a pregnancy to term. There are two main types of surrogacy: traditional and gestational.

Further Information

Gestation and expected date of delivery: The gestation period, commonly referred to as pregnancy, lasts about 40 weeks from the first day of the last menstrual period (LMP) to childbirth. This period is divided into three trimesters and involves the development and growth of the fetus from a single cell to a fully formed baby.

Expected date of delivery (EDD): The EDD is typically calculated by adding 280 days (or 40 weeks) to the first day of the LMP. This method, known as Naegele's rule, assumes a regular 28-day menstrual cycle. The EDD is an estimate. Most of births occur within a two-week period before or after the EDD.

EDD = LMP + 280 days ± 7 days

Menstrual age (gestational age): Based on the first day of the last menstrual period (LMP).

Fertilization age (fetal developmental age): Typically, 14 days less than gestational age, starting from the day of fertilization.

TEST TUBE BABIES/IN VITRO FERTILIZATION (IVF)

The so-called test tube babies are produced by the technique of ***in vitro fertilization*** (***in vitro*** = outside the body, as against ***in vivo*** = within the body). This technique is being increasingly used in couples who are not able to achieve fertilization due to many medical reasons and this form of fertilization is assisted reproductive technique (ART).

Gonadotropins are administered to the woman to stimulate growth of follicles in the ovary. Just before ovulation, the ovum is removed (using an aspirator) and is placed in a suitable medium. Spermatozoa are added to the medium. Fertilization and early development of the embryo take place in this medium. The process is carefully monitored, and when the embryo is at the 8-cell stage it is put inside the uterus. Successful implantation takes place in about 20% of such trials.

The reasons for using the technique can be as follows:

- The number of spermatozoa may be inadequate (usually about 2–5 mL of semen is ejaculated. Each milliliter contains about 100 million spermatozoa. If the count of spermatozoa is less than 20 million per mL, there may be difficulty in fertilization).
- There may be inadequate motility of spermatozoa.
- There may be obstruction of the uterine tube.
- There may be absence of ovulation.

SEX DETERMINATION

Ova contain 22 + **X** chromosomes. However, the spermatozoa are of two types. Half of them have 22 + **X** chromosomes and the other half of them have 22 + **Y** chromosomes. We speak of these as '**X**-bearing', or '**Y**-bearing', spermatozoa. An ovum can be fertilized by either type of spermatozoon. If the sperm is **X**-bearing, the zygote has 44 + **X** + **X** chromosomes and the offspring is a girl. If the sperm is **Y**-bearing the zygote has 44 + **X** + **Y** chromosomes and the offspring is a boy.

Thus, the sex of a child is determined at the time of fertilization. It will now be clear that one chromosome of each of the 23 pairs is derived from the mother and the other from the father.

NOTE

Social sex ratio refers to the ratio of males to females in a population, influenced by biological factors, cultural and social practices. The primary sex ratio at conception is biologically determined (by X- or Y-bearing sperm) but variations in sex ratio at birth may reflect differential survival during embryonic and fetal development.

CLEAVAGE

The two-cells formed as described above undergo a series of divisions **(Fig. 4.5A)**. One-cell divides first so that we have a '3-cell' stage of the embryo **(Fig. 4.5B)** followed by a '4-cell' stage **(Fig. 4.5C)**, a '5-cell' stage, etc. This process of subdivision of the ovum into smaller cells is called ***cleavage***. The zygote undergoes its first mitotic division, resulting in two ***blastomeres***. Continued mitotic divisions lead to 4, 8, and so on, blastomeres.

As cleavage proceeds the ovum comes to have 16 cells. It now looks like a mulberry and is called the ***morula*** **(Fig. 4.5D and Table 4.1)**. It is still surrounded by the

JAYPEE BROTHERS

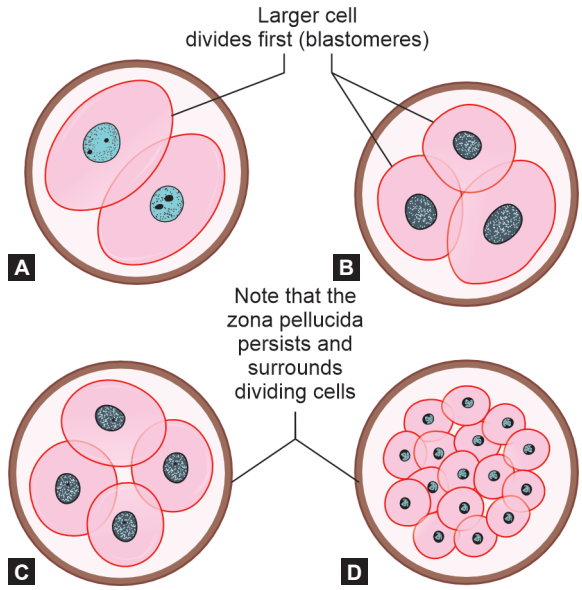

FIGS. 4.5A to D: Some stages in segmentation of the fertilized ovum: (A) Two-cell stage; (B) Three-cell stage; (C) Four-cell stage; (D) Morula.

TABLE 4.1: Relationship of cleavage stages and fertilization.

Cleavage stage	Time after fertilization when it can be observed
One-cell stage	<24 hours (not visible as it stays for a very short period)
Two-cells stage	24–36 hours
3–4 cells stage	36–48 hours
5–8 cells stage	48–72 hours
9–16 cells stage	72–96 hours

zona pellucida. If we cut a section across the morula, we see that it consists of an ***inner cell mass*** that is completely surrounded by an outer layer of cells. The cells of the outer layer will later give rise to a structure called the ***trophoblast*** **(Fig. 4.6A)**.

The inner cell mass gives rise to the embryo proper and is, therefore, also called the ***embryoblast***. The cells of the trophoblast help to provide nutrition to the embryo.

During 32–64 cells stage and between 4th to 5th day, some fluid passes into the morula from the uterine cavity, and partially separates the cells of the inner cell mass from those of the trophoblast **(Fig. 4.6B)**. As the amount of fluid increases, the morula acquires the shape of a cyst. The cells of the trophoblast become flattened, and the inner cell mass gets attached to the inner side of the trophoblast on one side only **(Fig. 4.6C)**.

The morula has now become a ***blastocyst***. The cavity of the blastocyst is the ***blastocoele***. That side of the blastocyst to which the inner cell mass is attached is called the ***embryonic or animal pole***, while the opposite side is the ***abembryonic pole***.

The trophoblast divides into the one in contact with embryoblast known as ***polar trophoblast*** (30 cells) and the rest of it lining the wall of blastocyst is known as ***mural trophoblast*** (69 cells).

The zona pellucida starts thinning on the 4th day and disappears by the 5th day postfertilization, initiating the attachment of trophoblastic cells to the uterine epithelium for implantation on the 6th or 7th day. This is known as ***hatching of blastocyst***.

NOTE

Cleavage plays a important role in maintaining the nucleus-to-cytoplasm (N/C) ratio by rapidly increasing the number of cells while the overall size of the embryo remains unchanged, ensuring proper distribution of cytoplasmic components among smaller cells.

Function of the Zona Pellucida

- **Prevents premature implantation:** It prevents the embryo from implanting into the epithelium of uterine tube and uppermost endometrium during its travel through the tube.
- **Glycoproteins (ZP1, ZP2, ZP3, ZP4):**
  - *ZP2:* Plays a crucial role in sperm binding, gamete recognition, penetration, and prevention of polyspermy.
  - *ZP Glycoproteins:* Induce the acrosomal reaction, allowing species-specific sperm penetration.
  - *Holds blastomeres together:* Maintains the integrity of the early embryo.
  - *Immunological barrier:* Lacks histocompatibility antigens, preventing maternal immune response against the genetically different embryo. After the disappearance of zona pellucida various

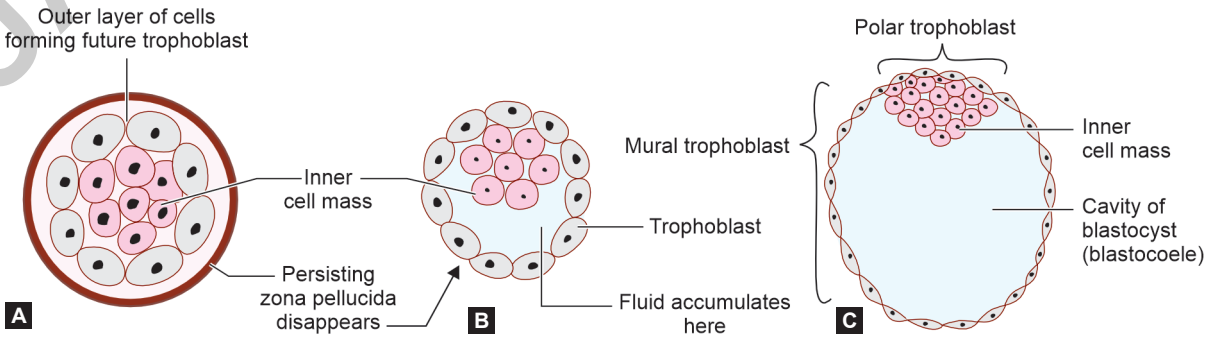

FIGS. 4.6A to C: Formation of blastocyst.

JAYPEE BROTHERS

immunosuppressive cytokines and proteins are produced by the implanting embryo. This blocks the recognition of the embryo as a foreign tissue to the mother.

- *Disappears before implantation:* Allows the blastocyst to attach to the uterine endometrium for further development.

Clinical Importance

Contraceptive Methods

It is the use of various artificial methods or techniques to prevent pregnancy (contraception). The different contraceptive methods are:

- **Temporary**
  - *Physical/barrier technique*
    - *Male condom*—A sheath made of latex or polyurethane which is often used with a chemical spermicide to increase effectiveness by killing sperm.
    - *Female condom*—A pouch made of polyurethane or nitrile that is inserted into the vagina before intercourse.
    - *Others*—diaphragm, cervical cap, can be used with spermicide.
  - *Chemical method*—use of contraceptive pill, to prevent ovulation in the female.
    - *Use of intrauterine device*—intrauterine insertion of copper that prevents implantation of fertilized ovum.
- **Permanent/surgical method**—male/female sterilization (vasectomy/tubectomy). This is permanent method of sterilization.

IMPLANTATION

Definition and Implantation Period

Implantation is the process of attachment of a blastocyst to the uterine endometrium and its subsequent invasion, or embedding, into the uterine lining. This occurs between the 6th and 12th days following fertilization, i.e., it start late in first week and continues till mid of second week of development.

Process of Implantation

To understand the process of implantation, it is divided into two phases:

1. Events preliminary to fertilization
2. Stages of implantation.

Processes Preceding Implantation (Fig. 4.7)

By day 3 or 4, zygote is developed into the blastocyst as discusses previously.

- **Blastocyst formation:** The morula develops into a blastocyst, consisting of an inner cell mass and an outer trophoblast layer.
- **Zona pellucida thinning:** The zona pellucida begins to thin.
- **Zona pellucida disappearance:** The zona pellucida disappears, allowing the blastocyst to hatch.
- **Blastocyst hatching:** By day 5–6 the blastocyst hatches from the zona pellucida, enabling direct interaction with the uterine lining.

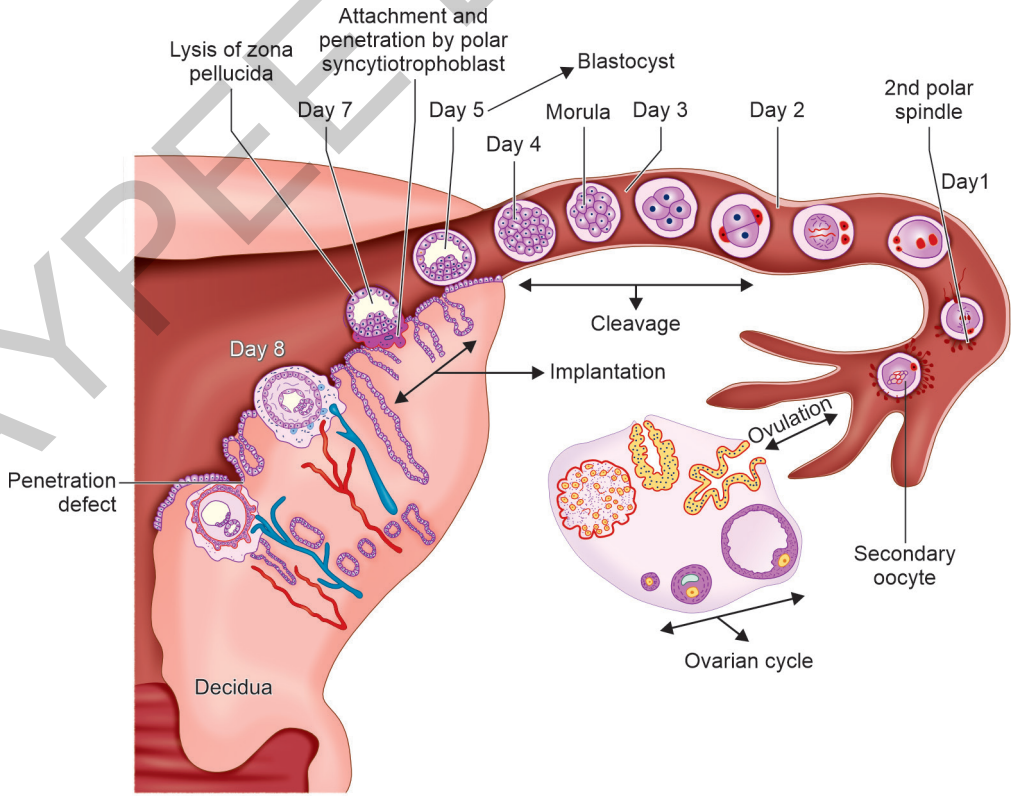

FIG. 4.7: Various processes before and during implantation—ovulation, fertilization, cleavage, blastocyst, trophoblast differentiation, decidual change, hatching of blastocyst, penetration defect.

JAYPEE BROTHERS

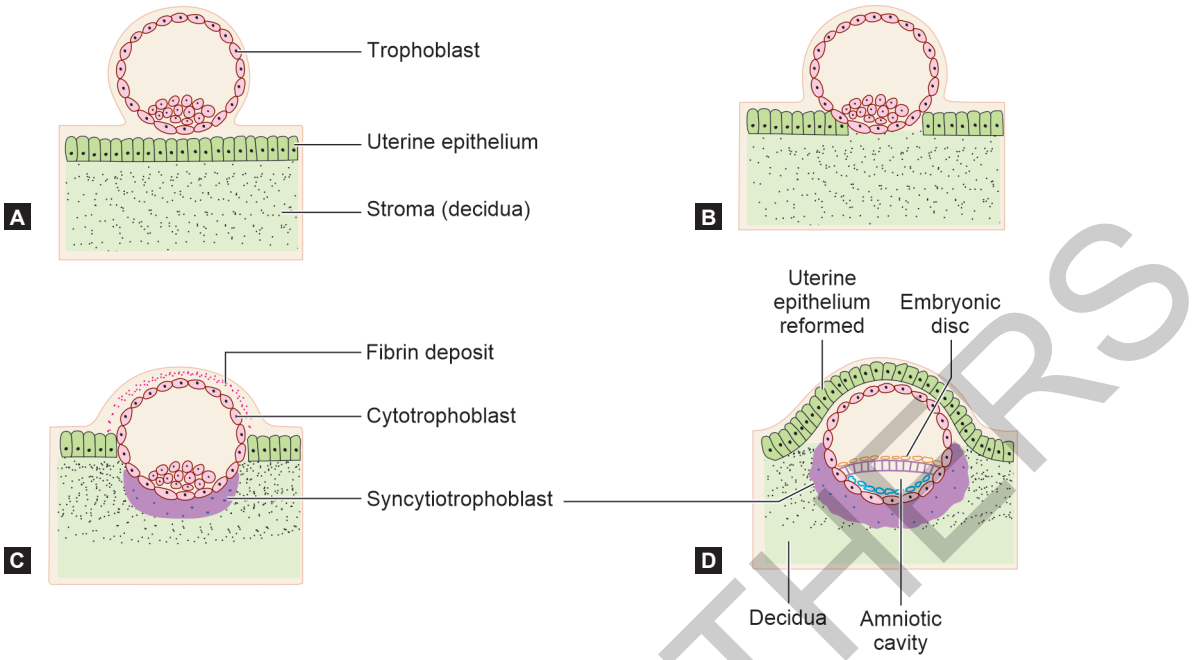

FIGS. 4.8A to D: Stages of implantation: (A) Hatching blastocyst; (B) Adhesion of blastocyst to uterine epithelium; (C) Penetration of blastocyst through uterine epithelium and erosion of endometrium; (D) Closure of penetration defect and differentiation of trophoblast and embryoblast.

Stages of implantation

- **Decidual reaction:** It refers to the changes in the endometrial stroma as the morula reaches the uterus during the secretory phase.
- **Hatching of blastocyst:** The zona pellucida thins and disappears by the 6th day, allowing the blastocyst to hatch. This thinning is due to action of enzyme trypsin **(Fig. 4.8D)**.
- **Adhesion of polar trophoblast to columnar uterine epithelium:** Trophoblastic cells which have tendency to stick, adhere to the uterine endometrium. On the 6th day postfertilization, zona pellucida disappears and it initiates the attachment of polar trophoblastic cells to the columnar uterine epithelium **(Figs. 4.8A and B)**.
- **Penetration of blastocyst through uterine epithelium:** The trophoblastic cells have got the penetrating/burrowing nature. The polar trophoblastic cells penetrate the uterine epithelium, creating a passage for the blastocyst **(Fig. 4.8C)**.
- **Erosion of the endometrium:** Proteolytic enzymes from trophoblast and uterine epithelium erode the endometrium, embedding the blastocyst deeper and deeper into the uterine mucosa till the whole of it comes to lie within the thickness of the endometrium.
- **Trophoblast differentiation:** By the 8th day, the trophoblast differentiates into cytotrophoblast (inner layer composed of mononucleated cells, divide actively) and syncytiotrophoblast layers (outer layer composed of multinucleated cells formed by fusion of cytotrophoblasts cells).

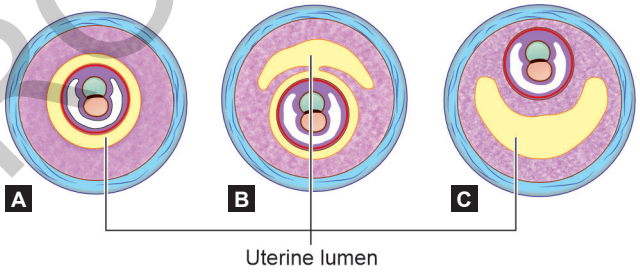

FIGS. 4.9A to C: Types of implantation: (A) Central; (B) Eccentric; (C) Interstitial.

- **Closure of penetration defect in uterine epithelium:** By the 9th day, a fibrin plug forms to close the defect in the uterine epithelium **(Fig. 4.8D)**.
- **Completion of embedding:** By 12th day of fertilization, the blastocyst is fully embedded and establishes a nutritive relationship with maternal blood vessels.

Types of Implantation (Figs. 4.9A to C)

1. **Central implantation:** Blastocyst is implanted in the uterine cavity, e.g., carnivores—cow.
2. **Eccentric implantation:** Blastocyst is implanted in the uterine crypt, e.g., mouse.
3. **Interstitial implantation:** Blastocyst is implanted in the endometrium of uterine wall. This is the type of implantation in guinea pig and human.

Clinical Importance

Normal and Abnormal Sites of Implantation

- **Normal site of implantation:** The upper part of body of uterus in midsagittal plane, in the posterior wall (55%) or in the anterior wall (45%) **(Fig. 4.10)**.

JAYPEE BROTHERS

- **Abnormal sites of implantation (Fig. 4.10)**
  - Lower uterine segment: If the implantation is in the lower uterine segment, it is called placenta previa.
  - Extrauterine:
    - Tubal implantation: This is most common cause of abnormal implantation after uterine. The various parts of fallopian tube involved in order of frequency are: (1) Interstitial, (2) Ampulla, (3) Isthmic.
    - Abdominal implantation: It is rare. It can be primary (implantation in relation to mesentery) or secondary (re-implantation of ruptured tubal or ovarian pregnancy).
  - Ovarian implantation: It is rare and can cause teratoma.

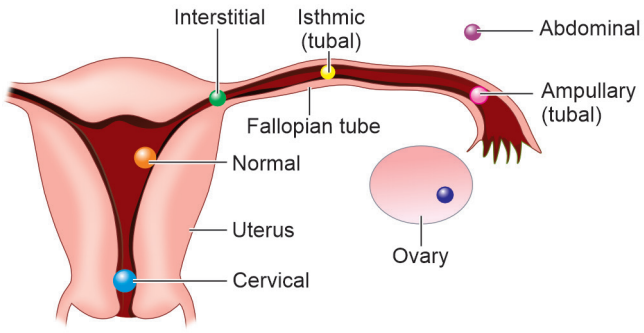

FIG. 4.10: Normal and abnormal sites of implantation: Normal site of implantation in the upper uterine segment; Abnormal sites of implantation are: tubal, interstitial, cervical, abdominal and ovary.

Clinical correlation

Placenta Previa

Introduction: Placenta previa occurs when the placenta implants low in the uterus, covering the cervix partially or completely, leading to complications like severe bleeding during pregnancy and delivery. It is one of the most common causes of antepartum hemorrhage.

Embryological basis

- **Implantation site:** Normally, the blastocyst implants in the upper uterus. In placenta previa, it implants near or over the cervix.
- **Trophoblast invasion:** Abnormal lower segment implantation affects trophoblastic invasion and the establishment of uteroplacental blood supply.
- **Chorionic villi formation:** Chorionic villi form in the lower uterine segment, resulting in a low placental position.
- Mechanisms leading to placenta previa are previous uterine scar, abnormal endometrial lining, and multiple gestations.

Diagnosis is done by ultrasonography.

Clinical implications

Placenta previa increases risks of antepartum hemorrhage, preterm birth, and cesarean delivery. Early diagnosis via ultrasound is crucial for management and safe delivery planning.

Ectopic Pregnancy

- This results from abnormal sites of implantation, i.e., extrauterine pregnancies.
- Ectopic pregnancies do not progress and usually result in death of the embryo. Rarely does this embryo develop to full term.
- The most common ectopic pregnancy is tubal pregnancy with a 95% incidence. Tubal pregnancies are terminated by medical intervention. If it is permitted to progress, it can result in rupture of uterine tube with severe internal bleeding.
- Other types of ectopic pregnancies are abdominal, ovarian.

Clinical Importance

Abortion

Definition

The termination of pregnancy before the fetus is viable outside the womb, typically defined as before 20 weeks of gestation.

Types

- **Spontaneous abortion (miscarriage):** Natural loss of pregnancy due to various reasons including genetic abnormalities, infections, or maternal health issues.
- **Induced abortion:** Deliberate termination of pregnancy through medical or surgical means.

Causes

- **Genetic factors:** Chromosomal abnormalities in the fetus.
- **Maternal health:** Conditions such as anatomical alterations, diabetes, thyroid disorders, and infections.
- **Lifestyle factors:** Smoking, alcohol use, and exposure to harmful substances.

Symptoms

Vaginal bleeding, cramping, and pain in the lower abdomen.

Management

- **Medical management:** Use of medications such as misoprostol and mifepristone.
- **Surgical management:** Procedures like dilation and curettage (D and C) or vacuum aspiration.

Pregnancy Tests

Pregnancy tests are essential diagnostic tools used to confirm pregnancy by detecting specific hormones produced during early embryonic development.

Hormonal basis

- **Human chorionic gonadotropin (hCG):** hCG is the key hormone detected in pregnancy tests.
- Produced by the trophoblast cells of the developing embryo shortly after fertilization.
- Levels of hCG rise rapidly in the early weeks of pregnancy, doubling approximately every 48–72 hours.

Types of pregnancy tests

- **Urine pregnancy test:**
  - Most common and convenient method.
  - Can be performed at home or in a clinical setting.
  - Detects the presence of hCG in the urine.
  - Typically positive as early as 10–14 days after conception (around the time of the missed menstrual period).
- **Blood pregnancy test:**
  - Conducted in a clinical laboratory.
  - More sensitive and can detect lower levels of hCG compared to urine tests.
  - Can confirm pregnancy as early as 7–10 days after conception.

JAYPEE BROTHERS

- **Two types:**
  1. **Qualitative hCG test:** Confirms the presence or absence of hCG.
  2. **Quantitative hCG test:** Measures the exact level of hCG in the blood, useful for tracking the progress of early pregnancy or diagnosing potential complications.

CHANGES IN THE ENDOMETRIUM OF THE UTERUS

After implantation, the endometrial features resembling the secretory phase are enhanced by human chorionic gonadotropin (hCG) secreted by syncytiotrophoblast cells. By the 17th or 18th day of the menstrual cycle, corresponding to the 5th day postfertilization and implantation, the uterine endometrium becomes markedly modified, edematous, and vascular, termed ***decidua***.

Decidua

Definition

Decidua refers to the functional and specialized endometrial lining (stratum compactum) of the uterus during pregnancy after implantation, supporting the embryonic development.

Decidual Reaction

Under the influence of maternal progesterone and the hCG, stromal cells of the endometrium undergo decidualization, becoming enlarged, vacuolated and glycogen and lipid rich. These cells are called *decidual cells.* The intercellular substance increases, and it gives edematous appearance. The decidualized endometrium provides structural support and a nutrient-rich environment for embryonic development during early pregnancy. The decidual reaction is a defensive mechanism to protect the endometrium.

Types/Subdivisions of Decidua (Fig. 4.11)

- **Decidua basalis/serotina:** Found adjacent to the implanted blastocyst, forms the maternal part of the placenta. The maternal blood vessels (spiral arteries) proliferate in the region of decidua basalis and are filled with blood and dilate to form sinusoids. The decidua basalis is also referred to as the ***decidual plate***, and is firmly united to the chorion.
- **Decidua capsularis/reflexa:** The part of endometrium that surrounds the conceptus, becoming compressed as the conceptus expands.
- **Decidua parietalis/vera:** The part of decidua that lines the remainder of the uterine cavity.

Fate of Decidua

As the conceptus enlarges during development, the decidua capsularis enlarges into the uterine cavity and finally fuses with decidua parietalis during 3rd month of pregnancy thus obliterating the uterine cavity. At the end of pregnancy, the decidua is shed off, along with the placenta and membranes. It is this shedding off which gives the decidua its name (c.f. deciduous trees).

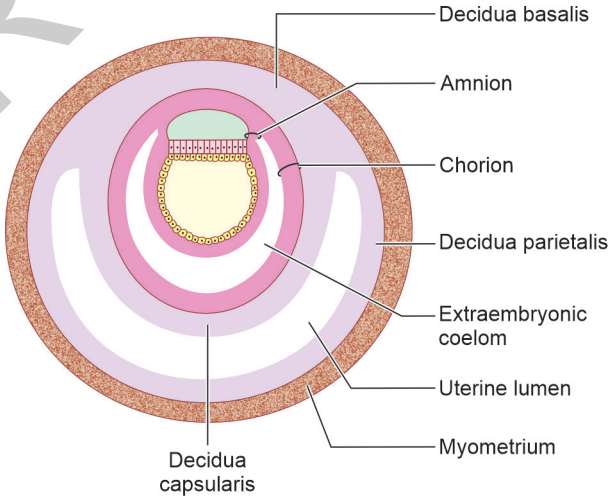

FIG. 4.11: Subdivisions of decidua—basalis, capsularis, parietalis.

Case Based Learning

Embryological Basis of Case of Infertility

Patient details: *A 32-year-old woman married for 6 years, and regular menstrual cycles presented with her husband for consultation regarding infertility. They have been trying to conceive for the past 4 years without success and have not used any contraceptive methods. A detailed physical examination of both partners is conducted, and the following investigations are recommended to identify the cause of infertility.*

- **Seminal analysis of the male:** It is done to assess the male's fertility potential by evaluating the quantity and quality of sperm. Key parameters include sperm count, motility, morphology, and pH of semen. Embryologically, spermatogenesis occurs in the seminiferous tubules of the testes, and any disruption in this process can lead to abnormalities in sperm parameters.
- **Transvaginal ultrasound for antral follicle count (AFC) of the female:** It is done to assess the number and size of antral follicles in the ovaries. Antral follicles are small fluid-filled sacs within the ovaries that contain immature eggs. The number of antral follicles

JAYPEE BROTHERS

is a direct indicator of a woman's ovarian reserve and fertility potential. Each menstrual cycle, a cohort of antral follicles is recruited, but typically only one reaches maturity and ovulates.

- **Laparoscopy for tubal patency in the female:** The fallopian tubes play a crucial role in the transportation of the oocyte from the ovary to the uterus and in the process of fertilization. Any blockage or structural anomaly in the tubes can prevent the sperm from reaching the egg or the fertilized egg from reaching the uterus.
- **Blood test for anti-Müllerian hormone (AMH) levels in the female:** It is done to evaluate ovarian reserve and provide an estimate of the remaining egg supply, which can be critical in planning fertility treatment. AMH is produced by granulosa cells of preantral and small antral follicles. It reflects the size of the remaining egg supply or ovarian reserve. AMH levels provide insight into the functional status of the ovaries and their capacity to produce viable eggs.
- **Karyotyping of both partners:** Karyotyping examines the chromosomal composition of individuals. Chromosomal abnormalities, such as aneuploidies, translocations, or inversions, can lead to infertility, miscarriages, or congenital anomalies.

Case Findings and Recommendations

- **Seminal analysis:** Normal sperm count and morphology but reduced motility.
- **Transvaginal ultrasound (AFC):** An antral follicle count of 6, indicating a reduced ovarian reserve.
- **Laparoscopy:** No significant blockage.
- **AMH levels:** Low, suggesting diminished ovarian reserve.
- **Karyotyping:** Both partners have normal karyotypes.

Advice to the couple: Given the reduced sperm motility, low antral follicle count, and diminished ovarian reserve, the couple should be advised to consider assisted reproductive technologies (ART), such as in vitro fertilization (IVF). IVF can bypass the issues with sperm motility and reduced ovarian reserve by directly fertilizing the eggs in the laboratory and transferring the resulting embryos into the uterus. The couple should also be counseled about the potential for using intracytoplasmic sperm injection (ICSI) during IVF to enhance fertilization success given the sperm motility issue.



HIGHLIGHTS

- **Fertilization**
  - It is the process of fusion of male and female gametes resulting in the formation of single celled zygote.
  - It takes place in the ampulla of the uterine tube.
  - It involves the biological processes of completion of meiotic division of ovum, fusion of male and female pronuclei and initiation of mitotic cell division of zygote.
  - The process of fertilization has three stages and it involves four processes.
- **Cleavage**—the series of divisions the fertilized cell undergoes.
- **Morula**—the 16 cell stage of fertilized ovum. It has an inner cell mass (embryoblast) covered by an outer layer of cells (trophoblast).
- **Blastocyst**—reorganized cells of morula (blastomeres) into an inner cell mass (embryoblast) covered by an outer layer of cells (trophoblast). Fluid filled cavity (blastocyst) separates the two.
- **Polar bodies** are the byproducts of oocyte during the two meiotic divisions.
- **Parthenogenesis** is asexual reproduction without fertilization.
- **Contraception** is an artificial method or technique to prevent pregnancy.
- **In vitro fertilization (IVF)** is a form of artificial reproductive technique (ART).
- The process of attachment of developing embryo to the uterine endometrium is called **implantation**. The type of implantation in the human being is called interstitial implantation as the embryo gets buried in the substance of endometrium.
- **Decidua** is the functional stratum of uterine endometrium after the implantation of blastocyst.



Summary

- Events taking place during the first week of germinal period is summarized in **Flowchart 4.1**.
- Process of implantation is summarized in **Flowchart 4.2**.

JAYPEE BROTHERS

FLOWCHART 4.1: Events taking place during the first week of germinal period.

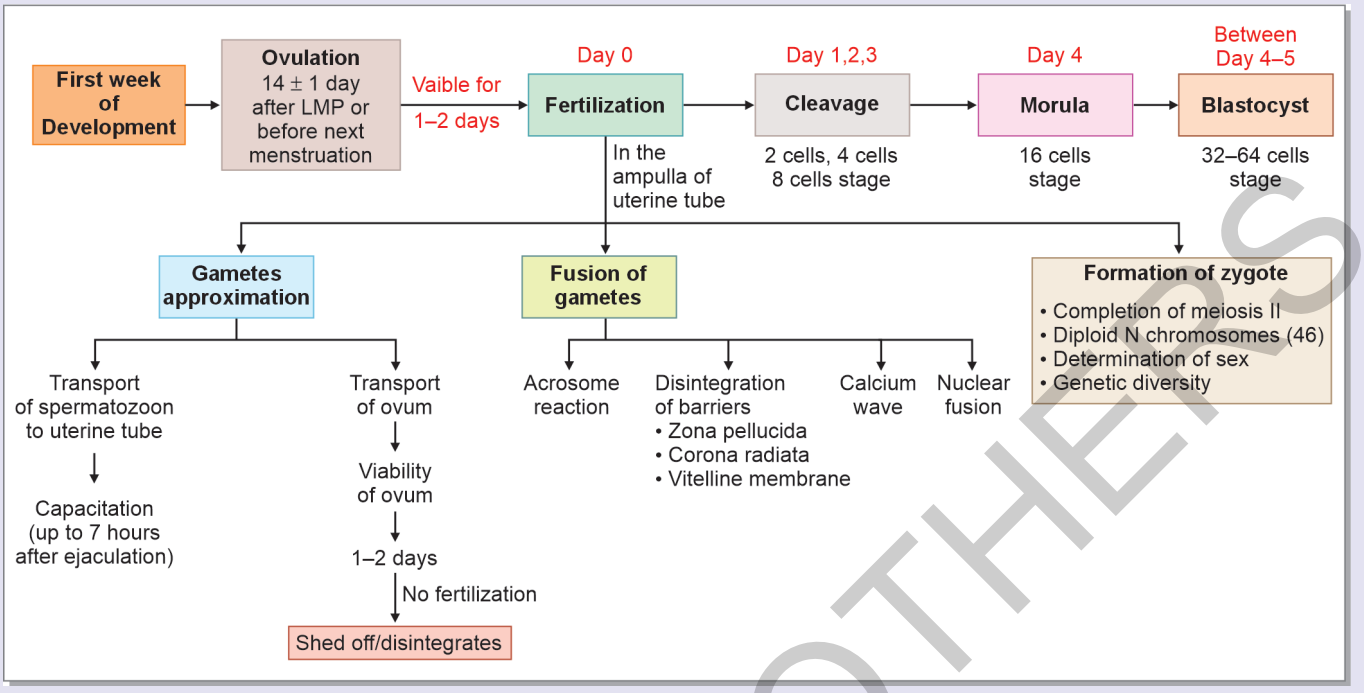

FLOWCHART 4.2: Process of implantation.

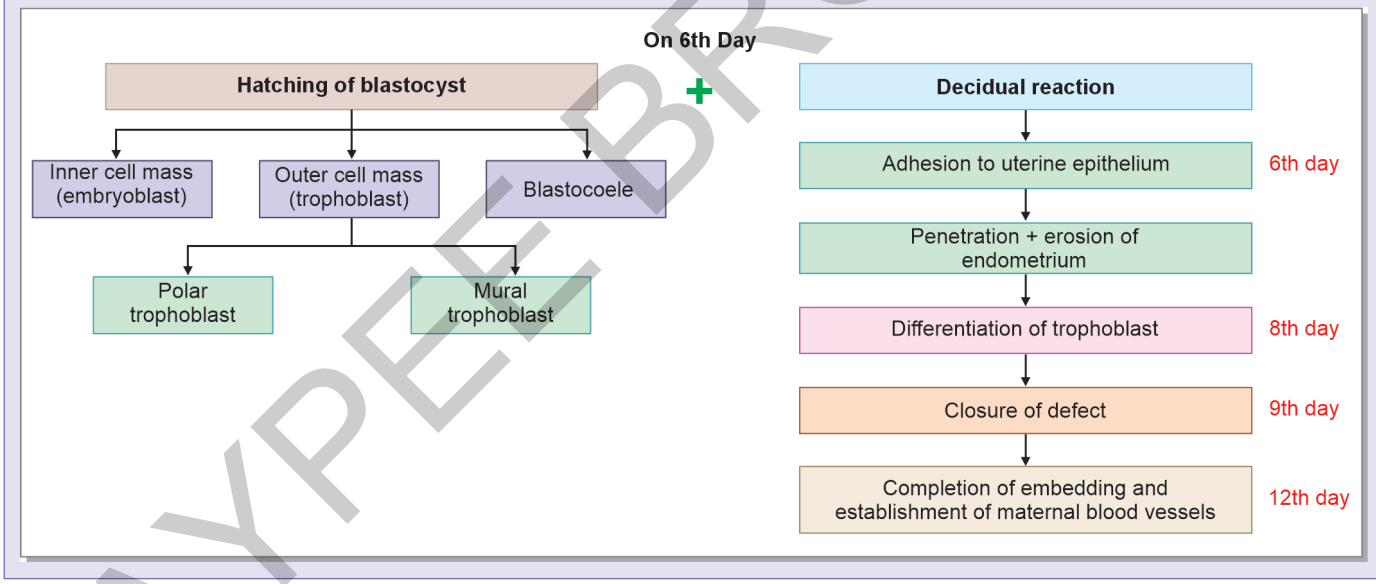

TEST YOUR UNDERSTANDING

REVIEW QUESTIONS

1. Define fertilization.
2. Describe the stages involved in fertilization.
3. What is capacitation?
4. What is acrosome reaction?
5. Explain in vitro fertilization.
6. Describe cleavage.
7. Write short notes on blastocyst.
8. Write short notes on morula.
9. Write short notes on implantation.
10. What are the abnormal sites of implantation?
11. Explain the decidual reaction.
12. What are the different types of decidua?

JAYPEE BROTHERS

EXPLAIN WHY? (REASONING QUESTIONS)

1. Failure of capacitation can result in infertility.
2. Zona pellucida is crucial in preventing ectopic pregnancies.
3. Dysfunction of trophoblast cells can lead to placenta previa.
4. Cortical reaction is most important step to prevent polyspermy.
5. Fallopian tube is most common site for abnormal implantation.

MULTIPLE CHOICE QUESTIONS

1. The correct order of barriers through which the sperm has to pass through are:
A. Zona pellucida, vitelline membrane, corona radiata
B. Zona pellucida, corona radiata, vitelline membrane
C. Vitelline membrane, corona radiata, zona pellucida
D. Corona radiata, zona pellucida, vitelline membrane

2. Haploid nuclei that are fusing at fertilization are called:
A. Centrioles
B. Nucleoli
C. Pronuclei
D. None of the above

3. The first week of human development is characterized by the formation of all of the following, *except*:
A. Inner cell mass
B. Hypoblast
C. Blastocyst
D. Yolk sac

4. During a viva, examiner ask the medical student about the changes in uterus of pregnant woman to support embryo implantation. What term describes the changes in the endometrium to support implantation?
A Ovulation
B. Menstruation
C. Decidual reaction
D. Fertilization

5. A 29-year-old woman experiences sharp lower abdominal pain and spotting. She is diagnosed with an ectopic pregnancy. Where does an ectopic pregnancy most commonly implant?
A. Cervix
B. Uterine cavity
C. Fallopian tube
D. Ovary

6. A couple is undergoing fertility treatment and asks about how long after fertilization does the zygote reach the blastocyst stage and prepare for implantation?
A. 24 hours
B. 2–3 days
C. 4–5 days
D. 6–7 days

7. Which of the following events marks the completion of the fertilization process and the formation of a zygote?
A. Penetration of the zona pellucida by the sperm
B. Fusion of the male and female pronuclei
C. Release of the secondary oocyte from the ovary
D. Capacitation of the sperm in the female reproductive tract

8. During fertilization, which enzyme released by the acrosome of the sperm allows it to penetrate the zona pellucida surrounding the oocyte?
A. Trypsin
B. Hyaluronidase
C. Acrosin
D. Lipase

9. What critical process occurring in the female reproductive tract enables sperm to acquire the ability to fertilize an oocyte?
A. Acrosome reaction
B. Capacitation
C. Cortical reaction
D. Zygote formation

Answers: 1. D 2. C 3. B 4. C 5. C 6. C 7. B 8. C 9. B

JAYPEE BROTHERS

for detailed information on anatomy books, visit our website www.ejaypee.com, for detailed information on anatomy books, visit our website www.ejaypee.com, for detailed

Inderbir Singh's
Human Embryology

Salient Features

- Content is thoroughly updated and aligned with the revised curriculum by the National Medical Commission (NMC) which is presented in a comprehensive yet concise manner, making them accessible and relevant to students.
- High-quality, detailed line diagrams which are easily reproducible in exams accompany the text to enhance understanding of complex concepts.
- Integration of clinical correlations throughout the text is provided, connecting embryological concepts to clinical practice.
- Clear and concise timelines are given helping students grasp the chronological progression of embryogenesis.
- Simplified flowcharts and summaries at the end of chapter aid in quick revision during examinations.
- Self-assessment questions, reasoning questions, and MCQs are given enabling students to evaluate their understanding and prepare for exams.
- Free book is given with this edition containing frequently asked university exam questions with answers, reasoning type questions, and additional MCQs as ready reckoner for various examinations.

Raveendranath Veeramani MBBS MD (Anatomy) is a distinguished medical graduate and anatomist from St John's Medical College, Bengaluru, Karnataka, India. His comprehensive training includes cadaveric dissection, histology, embryology, and neuroanatomy. His outstanding academic performance earned him multiple awards, including gold medals in anatomy, physiology, biochemistry, medicine, surgery, and pediatrics, as well as the Dr Percival Fernandez Award for "Best Postgraduate" at St John's Medical College. Additionally, he received the Curis Remuneror award for excellence in anatomy. Renowned for his dedication to teaching human anatomy, he has received numerous accolades during his academic career, including the "Excellence in Anatomy Award 2018" from CIMCON Foundation in association with the World Organization of Family Doctors. He is a committed educator with more than 15 years of experience, having taught undergraduate medical, nursing, and paramedical students as well as postgraduate trainees in anatomy, surgery, cardiology, and neurosurgery.

Currently, he is an Additional Professor, Department of Anatomy, Jawaharlal Institute of Postgraduate Medical Education and Research (JIPMER), Puducherry, India. He has published around 50 articles in international and national peer-reviewed journals and serves on the International Advisory Board of Elsevier Global 3D Anatomy. His research interests focus on clinical anatomy, including innovative surgical approaches and reverse translational research. He also serves as a reviewer for various anatomy journals and as an examiner for medical undergraduate students from different universities. He is actively involved in guiding and co-guiding doctoral students in anatomy.

diginerve®
A Jaypee Initiative
• Video Lectures • Dr. Wise AI Chatbot
• Question Bank • Notes
Download App

Shelving Recommendation
ANATOMY

ISBN 978-93-7806-213-1
9 789378 062131

Buy from ejaypee
JAYPEE BROTHERS