4th Edition

AIOS READY RECKONER IN OPHTHALMOLOGY

Editors
Namrata Sharma Partha Biswas

Contents

1. **Cornea** 1
   Editor: JK Reddy

2. **Dry Eye and Ocular Surface** 75
   Editor: Somasheila I Murthy

3. **Cataract** 87
   Editors: Jeewan S Titiyal, Sridevi Nair

4. **Glaucoma** 243
   Editors: Krishnadas, S Priyadarshini

5. **Refractive Surgery** 329
   Editors: Chitra Ramamurthy, Shreesha Kumar Kodavoor

6. **Uveitis and Ophthalmic Pathology** 449
   Editor: Jyotirmay Biswas

7. **Retina** 503
   Editor: Mangat R Dogra

8. **Neuro-ophthalmology** 743
   Editor: Rashmin Gandhi

9. **Oculoplasty** 779
   Editor: Kasturi Bhattacharjee

10. **Pediatric Ophthalmology and Strabismus** 971
    Editor: Lav Kochgaway

11. **Community Ophthalmology** 1037
    Editor: Praveen Vashist

Index *1065*

SECTION 3

Cataract

Editors: Jeewan S Titiyal, Sridevi Nair

3.1 Risk Factors for Age-related Cataract 89
SK Gupta

3.2 How do You Grade Age-related Cataract? 90
Gagandeep Singh Brar

3.3 Preoperative Evaluation of Patients with Age-related Cataract 92
Sudesh Kumar Arya

3.4 Macular Function Tests for Patients Undergoing Cataract Surgery 94
Lingam Gopal

3.5 Informed Consent for Cataract Surgery with or without Implantation of an Intraocular Lens 97
Arun K Jain

3.6 How do You Counsel Amblyopic Adult with Cataract before Surgery? 101
Jaspreet Singh Sukhija

3.7 Sterilization of Operating Room 102
Jagat Ram, Sunil Kumar

3.8 Antibiotic Prophylaxis after Cataract Surgery 106
Sushmita Kaushik, Parul Ichhpujani

3.9 What is the Role of Nonsteroidal Anti-inflammatory Drugs in Patients Undergoing Cataract Surgery? 111
Rupal H Trivedi

3.10 Anesthesia for Cataract Surgery 113
Sunil Kumar, Saurabh Saveria

3.11 Phacodynamics 115
Noshir M Shroff, Haripriya Aravind

3.12 What is Torsional Phacoemulsification and its Advantage? 119
Rohit Om Parkash

3.13 Viscoelastics in Phacoemulsification Surgery 121
Jeewan S Titiyal

3.14 Phaco Incision 124
Ravijit Singh

3.15 How to Proceed if Clear Corneal Incision is Ragged and Incompetent? 127
Arup Chakrabarti

3.16 What are the Various Means of Doing Anterior Capsulotomy? 128
Rupal H Trivedi

3.17 How do You Deal with Hard Cataracts during Phacoemulsification? 130
Rohit Om Parkash

3.18 Zero/Minimal Power Phaco 132
Gaurav Luthra

3.19 What are the Causes of Shallowing of Anterior Chamber during Phaco? How to Prevent it? 134
Cyres K Mehta

3.20 Management of Subluxated Cataract 136
Rajiv Choudhary

3.21 The Capsular Bag is Unexpectedly Mobile during Phaco. How to Manage with a Capsular Tension Ring? 138
Tanuj Dada, Pranita Sahay, Vivek Dave

3.22 How will You Manage a Patient of Visually Significant Cataract with Associated Keratoconus? 141
Sudhank Bharti

3.23 Phaco in High Myopia 143
Sudarshan Khokhar

3.24 Posterior Polar Cataract 144
Divya Agarwal

3.25 Microincisional Cataract Surgery Platform: A Great Leap Forward 150
Mohan Rajan, Sujatha Mohan, Ramya Subramanian

3.26 What should be done Differently before Cataract and Glaucoma Surgery? 153
Devindra Sood, Aditi Agarwal

3.27 Which Patients with Cataract Need a Combined Glaucoma Procedure? 155
SS Pandav

JAYPEE BROTHERS

3.28 90 to 100 Degrees of Iridodialysis during Phaco: What to Do? 157
Mahipal Sachdev, Charu Khurana

3.29 What are the Advantages, Indications, and Limitations of Manual Small Incision Cataract Surgery? 159
Ruchi Goel, KPS Malik

3.30 How to Minimize Corneal Endothelial Cell Damage during Phacosection, a Manual Small Incision Cataract Surgery? 161
MS Ravindra

3.31 Contrast Sensitivity in Pseudophakic Patients 164
Ravi Nabh

3.32 How Important is it to Reduce or Eliminate Spherical Aberration after Phacoemulsification? 165
Amit Gupta

3.33 What should be done for a Patient Undergoing Phaco and is Suspected to have Globe Perforation during Procedure? 167
Mangat R Dogra, Gaurav Sanghi

3.34 Are Anterior Chamber IOLs Safe for Implantation? Which Anterior Chamber IOLs should be Implanted? 169
Srikant Kumar Padhy, Neelima Aron

3.35 Iris-Claw Lens—Versatility Combines Safety 173
Ravijit Singh

3.36 Scleral-fixated Intraocular Lens 175
Surg Capt (Dr) Srujana D

3.37 How do you Manage a Patient with Visually Significant Cataract with Associated Uveitis? 183
GS Brar

3.38 What Precautions You Take in Patient of Cataract with Dry Eyes during and after Cataract? 185
KP Chaudhary

3.39 Postoperative Treatment of Uncomplicated Phacoemulsification 187
Tanuj Dada, Pranita Sahay, Vivek Dave

3.40 Following Uneventful Phacoemulsification, the Patient has 4+ Cells and Fibrin on Postoperative Day 1. What should be Done? 188
Reema Bhansal, Amod Gupta, Vishali Gupta

3.41 Postcataract Surgery Cystoid Macular Edema 190
Ramandeep Singh, Atul Arora

3.42 Phacoemulsification in Aniridic Eyes 194
Kasturi Bhattacharjee, S Bobby

3.43 Foldable Intraocular Lenses 196
JS Titiyal, Neelima Aron, Bhavya G

3.44 Management of Astigmatism: Toric Intraocular Lenses 201
Abhay Vasavada, Vaishali Vasavada

3.45 Mix and Match Multifocal Intraocular Lenses 203
Gaurav Luthra

3.46 Management of Descemet's Membrane Detachment 205
Jaspreet Sukhija

3.47 When should an Intraocular Lens be Implanted in the Sulcus or Bag or Captured in the Capsular Bag in a Patient Having Posterior Capsular Tear? 207
Suresh Kr Pandey

3.48 Cataract Surgery in Patients with Vitreoretinal Diseases 208
Pranab Das

3.49 Anterior Chamber Deepening during Phacoemulsification 212
GS Dhami

3.50 Phacoemulsification in Pseudoexfoliation with Small Pupil 215
Abhay Vasavada

3.51 What is the Best Way to Prevent and Manage Postoperative Intraocular Pressure Spikes? 216
Sandeep Saxena, Shilpi Arya

3.52 How do You Manage a Case of Visually Significant Cataract with Associated Fuchs' Endothelial Corneal Dystrophy? 217
Rajesh Fogla

3.53 How Should We Manage Prolonged or Recurrent Uveitis Following Phacoemulsification? 220
Arshee Ahmed, Jyotirmoy Biswas

3.54 Management of Posterior Dislocation of Lens Fragment during Phacoemulsification 223
Pranab Das

3.55 Current Surgical Techniques for Pediatric Cataract Surgery 224
Jagat Ram

3.56 Secondary Intraocular Lens Implantation in Children 227
Ashok Sharma

3.57 Femtosecond Laser-assisted Cataract Surgery 228
Deepali Singhal, Sridevi Nair

3.58 What are the Indications for Nd:YAG Laser Capsulotomy in Posterior Capsule Opacification? 232
Suresh Kr Pandey

3.59 An Update on IOL Power Calculation Formulas 233
Ashok Garg

JAYPEE BROTHERS

3.1 Risk Factors for Age-related Cataract

SK Gupta
Institute of Clinical Research New Delhi
skgup@hotmail.com, skgupta@icriindia.com

INTRODUCTION

Cataract is a condition which is recognized by the opacification of the lens. It may be localized to certain parts or whole of the lens may be affected. It has been found that cataract is a major cause of blindness worldwide, including India **(Fig. 3.1.1)**.

Cataract is a multifactorial disease. The risk factors associated with cataract disease include:

- Socioeconomic status
- Systemic conditions such as dehydration, renal failure, hypertension, low body mass index, and diabetes
- Glaucoma
- *Drugs:* Steroids, cholinesterase inhibitors, spironolactone, nifedipine, analgesics
- Myopia early in life
- Family history of cataract
- Occupational exposure
- Heavy smoking and alcohol consumption
- Use of cheaper cooking fuel
- Working in direct sunlight

RISK FACTORS FOR CATARACT (FIG. 3.1.2)

- Several studies conducted in central and eastern India have reported the role of dehydration caused by diarrhea in cataract formulation.
- Steroids have been implicated as an important cause of posterior subcapsular cataract.
- Glaucoma itself as well as medications such as cholinesterase inhibitors used for treating it have been associated with cataract.
- Environmental stress such as cigarette smoking decreases the levels of superoxide dismutase, glutathione, and glutathione peroxidase in lens and leads to oxidative insult as the mechanism of cataract.
- Patients who had quit smoking 25 years or prior have been found to at a 20% lower risk to develop cataract as compared to current smokers. The risk among past smokers was, however, higher than those who have never smoked.

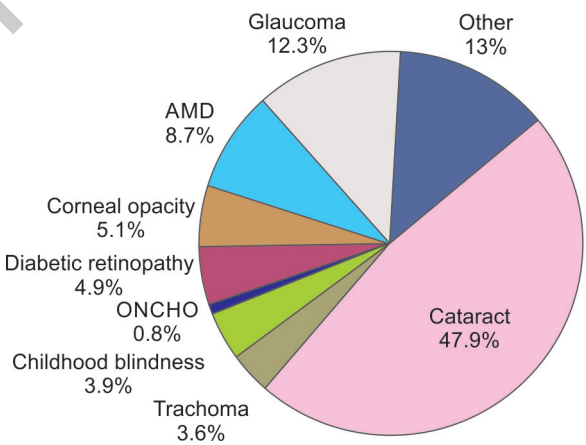

Fig. 3.1.1: Causes of blindness worldwide. (AMD: age-related macular degeneration)

JAYPEE BROTHERS

- The role of alcohol in cataract formation is less clear. But in a study, history of alcohol consumption was significant in univariate analysis.
- An association has been found between hypertension and cataract. Patients with high blood pressure (BP) are more prone to cataract.
- The risk of cataract was higher among people belonging to lower socioeconomic status who used cheaper fuel sources such as cow dung, wood, or coal.

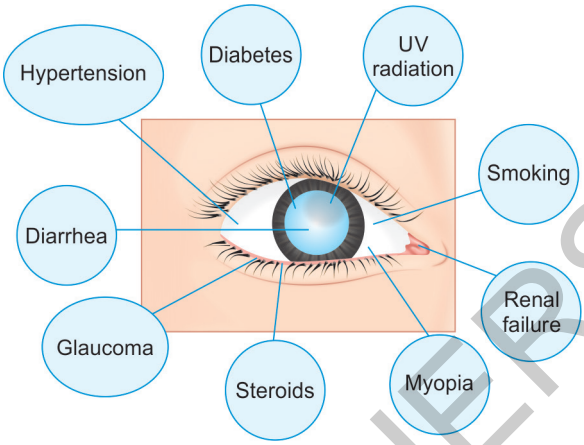

Fig. 3.1.2: Risk factors for cataract.

- Excessive ultraviolet (UV) light exposure is associated with enhanced risk of cataract possibly due to the oxidative stress associated with the depletion of antioxidants.
- Cortical cataract is generally found in female gender which has been attributed to the hormonal difference.
- Reduced estrogen levels in postmenopausal age group may also be a factor and hormone replacement therapy may play a protective role in reducing the incidence of age-related cataract.

EDITOR'S PEARLS

- Age-related cataract is a multifactorial disease. The risk factors for it can be broadly classified into patient-related and environmental factors.
- Important patient-related factors include increased age, ocular comorbidities, metabolic diseases, and genetic influences.
- Major environmental factors include ultraviolet light exposure, lower socioeconomic status, drug exposure, and smoking.

SUGGESTED READING

1. Apple DJ, Ram J, Foster A, Peng Q. Elimination of cataract blindness: a global perspective entering the new millennium. Surv Ophthalmol. 2000;45(Suppl 1):S1-196.

3.2 How do You Grade Age-related Cataract?

Gagandeep Singh Brar
Sangam Netralaya Mohali
gsbrarpgi@yahoo.com

INTRODUCTION

Grading of age-related cataract is important for epidemiological and research purposes as well as for planning surgical intervention. In the days of large incision manual cataract extraction, grading of cataract was probably not that important as far as planning of surgery was concerned; but in today's time of phacoemulsification, grading becomes very important especially grading the extent of nuclear sclerosis.

Lens Opacities Classification System III is the standard for grading age-related cataract.[1] This system can be used for assessment both on a slit-lamp biomicroscopy as well as from anterior segment photographs under full dilatation.

JAYPEE BROTHERS

METHOD OF GRADING

The pupil is dilated for cataract grading unless contraindicated. After dilatation cataract grading is done with 8× magnification view on slit lamp. The Lens Opacities Classification System III (LOCS) grading transparency is placed behind the patient's shoulder, mounted on X-ray view box and cataract grading is matched with transparency. Patients with nuclear cataract are examined under direct focal illumination for nuclear color and opalescence, whereas cases of cortical and posterior subcapsular are examined under retroillumination and matched with LOCS III transparency. For nuclear cataract, nuclear color (NC) as well as nuclear opalescence (NO) is graded from 1 to 6 whereas patients with cortical and posterior subcapsular cataract (P) are graded from 1 to 5 according to increased density of the cataract **(Fig. 3.2.1)**.

In LOCS III:

- *Severe cataract:* Grades NO ≥4 or NC ≥4 for nuclear cataract, C ≥4 for cortical cataract and P ≥2 for posterior subcapsular cataract.
- *Moderate cataract:* 2 ≥ NO <4 or 2 ≥ NC <4 for nuclear opacity, 2 ≥ C <4 for cortical opacity and 1 ≥ P <2 for posterior subcapsular opacity.
- *Mild cataract:* NO <2 or NC <2, C >2 and P >2.

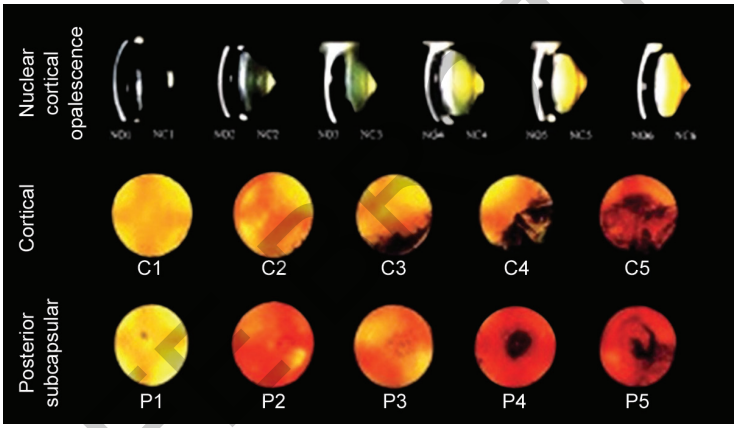

Fig. 3.2.1: Lens opacities classification system III.

NEWER TECHNOLOGIES

- Scheimpflug imaging of the anterior segment of the eye.
- Anterior segment optical coherence tomography (OCT).

The LOCS III criterion as an economic cataract grading system provides data that are in satisfactory concordance with the results obtained using the Pentacam-Scheimpflug system and anterior segment OCT.

EDITOR'S PEARLS

- LOCS III continues to be used as the standard for both research and clinical purposes.
- Objective-automated methods to grade cataract using anterior segment OCT and fundus photography have shown good correlation with LOCS III grading.
- Machine learning and deep learning tools have shown promise in the field of cataract diagnosis and grading.

REFERENCE

1. Chylack LT Jr, Wolfe JK, Singer DM, Leske MC, Bullimore MA, Bailey IL, et al. The Lens Opacities Classification System III. The Longitudinal Study of Cataract Study Group. Arch Ophthalmol. 1993;111(6):831-6.

JAYPEE BROTHERS

3.3 Preoperative Evaluation of Patients with Age-related Cataract

Sudesh Kumar Arya
Government Medical College and Hospital, Chandigarh
aryasudesh@yahoo.co.in

INDICATIONS OF SURGERY

Presence of glare, diplopia, polyopia or decreased contrast sensitivity may be indications for cataract surgery apart from decreased visual acuity for near or distance. The purpose of cataract surgery is to improve vision and its quality so that quality of life improves. Surgery should be planned on the basis of need, occupation, and lifestyle of the patient. Following examinations should be carried out before cataract surgery.

VISUAL ACUITY AND REFRACTION

Distant, near, and intermediate visual acuity (VA) should be recorded with naked eye and with glasses. Power of glasses (POG) should also be checked. If possible refraction should be done in both the eyes to find out the best corrected visual acuity and plan the eye to be operated accordingly.

Dominant eye should be identified before surgery in case the surgeon is planning micromonovision.

External Eye Examination

- Look for deviation of visual axis, eccentric fixation or nystagmus which may be poor prognostic signs even in age-related cataract.
- Pupillary reactions should be carefully checked. Presence of relative afferent pupillary defect may indicate optic nerve disease.
- Enophthalmos, deep set eyes and narrow palpebral aperture may pose problems during surgery. Any eyelid, conjunctival, lacrimal sac, or adnexal infection should be ruled out.
- A thorough examination of fellow eye should be done.

Slit-lamp Examination

Detailed slit-lamp examination is invaluable before any cataract surgery.

- Cornea should be examined for presence of corneal opacity, any irregularity, thinning, ectasia, corneal guttata or any keratic precipitates. Specular reflection should be done to assess the endothelial cell morphology.
- Anterior chamber should be examined for depth and presence of any cells or flare. Gonioscopy is very important in indicated cases to rule out presence of peripheral anterior synechiae or abnormal new vessels in the angle if anterior chamber intraocular lens (IOL) is anticipated.
- Pupillary dilation should be assessed before surgery.
- Presence of posterior synechiae, rubeosis or rigid sphincter may create problem during surgery.
- Lens should be examined for anterior and posterior capsular status, grade of nuclear sclerosis, location of opacity, posterior polar opacity, pseudoexfoliation, phacodonesis, etc. If there is any evidence of zonular weakness, one may plan capsular tension ring or scleral fixated IOLs.
- Vitreous should be examined for presence of any hemorrhage, asteroid hyalosis, opacification or liquefaction.

JAYPEE BROTHERS

Posterior Segment Evaluation

- Fundus examination with 90 D lens or indirect ophthalmoscopy should be done to evaluate the macula, optic nerve, retinal vessels, and retinal periphery. Particular attention should be paid to early macular degeneration/maculopathy which may affect visual result after an otherwise uneventful cataract surgery.
- If media is hazy, ultrasonography B-scan should be done to rule out retinal detachment, vitreous hemorrhage, vitreous opacity, posterior staphyloma, and optic nerve head cupping.

Intraocular Pressure

Intraocular pressure (IOP) should be measured to rule out high IOP. If there is suspicion of glaucoma, diurnal variation/visual field's assessment should be done.

Macular Function Tests

Macular function tests by potential acuity meter, laser interferometry, Maddox rod test, photostress recovery time or blue light entoptoscopy should be performed if media is hazy.

Optic Nerve

Optic nerve should be examined for cupping, along with pallor and other abnormality. Visual-evoked potential should be advised for confirming involvement of optic nerve pathway.

Corneal Pachymetry and Specular Microscopy

Corneal pachymetry and specular microscopy is useful for examining the corneal thickness and endothelium respectively thereby assessing indirectly the function of endothelium.

BIOMETRY

- It is preferable to measure axial length and keratometry by optical biometry methods such as the IOL Master and Lenstar due to their higher accuracy.
- Axial length can also be measured by applanation method either by contact or immersion and keratometry can be measured by a calibrated automated keratometer.

Accurate assessment of keratometry is specifically useful for planning location, size of incision, and type of IOLs especially toric IOLs.

INTRAOCULAR LENS POWER CALCULATION

The accurate power of IOL is calculated by keratometry and axial length measurements using various IOL calculation formulas. The Holladay II formula gives accurate results for all eyes. Sanders–Retzlaff–Kraff (SRK)-II is accurate for eyes with axial length 22–24.5 mm. For axial length beyond these limits, a modified SRK-II is used. Short eyes are calculated with Hoffer Q formula and eyes with axial length >26 mm are calculated by SRK-T formula.

For multifocal IOLs and for the patient who has undergone refractive surgery, different formulae are used for IOL power calculation depending upon the choice of the surgeon.

In postrefractive surgery cases Haigis/Haigis-L formula is chosen. Apart from this you should check various online IOL power calculation site, e.g., American Society of Cataract and Refractive Surgery (ASCRS) online calculator, Doctorhill.com.

GENERAL HEALTH OF THE PATIENT

Systemic evaluation should be done for ascertaining fitness for surgery. One must rule out diabetes mellitus, hypertension, ischemic heart disease, chronic obstructive pulmonary

JAYPEE BROTHERS

disease, history of allergy to drugs, bleeding disorders, and use of anticoagulants or immunosuppressants. Presence of any musculoskeletal disorder such as kyphosis, scoliosis or excessive obesity, head tremors or nodding may pose difficulty during surgery.

EDITOR'S PEARLS

- Accurate biometry and use of appropriate IOL power calculation formula are keys for achieving optimal refractive outcomes after cataract surgery.
- Systemic stability must be carefully evaluated in high-risk patients planned for ophthalmic surgery.
- Clear verbal and written instructions about the operative procedure must be provided to patients in the language of their understanding before surgery.

SUGGESTED READING

1. Bobrow JC, Blecher MH, Glasser DB, Mitchell KB, Rosenberg LF, Isbey EK, III, et al (Eds). Lens and cataract. In: Basic and Clinical Science Course. San Francisco: American Academy of Ophthalmology; 2009. pp. 75-89.

3.4 Macular Function Tests for Patients Undergoing Cataract Surgery

Lingam Gopal
Medical Research Foundation
Sankara Nethralaya, Chennai
drlg@snmail.org

INTRODUCTION

Cataract surgery is the most common ophthalmic surgery performed by ophthalmologists. In view of the high expectation, there is need for proper prognostication. Macular diseases are also common in the age group when cataract surgery is needed. In the presence of media opacity (cataract), the evaluation of the macula by clinical examination may be difficult and can potentially result in less-than-optimal postoperative outcomes. Tests are available to evaluate the macular integrity and function as well as to determine the potential recovery of vision after cataract surgery. It must be emphasized that none of them gives a foolproof prognosis for vision. The errors in estimates can go both ways—under and over estimation.

EYES WITH MILD-TO-MODERATE LENS OPACITIES

Structural Evaluation

- *Direct macular evaluation:* Slit-lamp biomicroscopic evaluation is the best way of evaluating the anatomical integrity of the macula. Posterior polar opacities may however preclude proper evaluation of the same.
- *Optical coherence tomography (OCT):* OCT scanning of the macula gives a very good structural evaluation. Features, such as macular hole, epiretinal membrane, foveal thickening, etc., can be detected. With increasing degree of cataract, the quality of the pictures deteriorates and may fail to give proper information. However, considering the infrared wavelength that is used, OCT can surprisingly give clear pictures even in the presence of significant cataracts.

Functional Evaluation

- *Pinhole acuity:*
  - *Principle:* Pinhole eliminates optical aberrations and improves the vision.

JAYPEE BROTHERS

- *Interpretation:* In the presence of gross opacities, pinhole does not improve the vision. The test is less reliable in eyes with best corrected visual acuity < 6/60. Pinhole potential acuity test was found more predictive than potential acuity meter (PAM) for eyes with best corrected vision better than 6/60.[1]

- *Photo stress test:*
  - *Principle:* The macula is exposed to bright light for 10 seconds (using direct ophthalmoscope light) and the time taken for recovery of original minus one line Snellen's vision is measured.
  - *Interpretation:* Normal recovery time is 20–30 seconds. Prolonged recovery time beyond 50 seconds indicates macular dysfunction.
- *Blue field entoptoscopy:*
  - *Principle:* When patients are made to look at a bright blue light, they notice flying corpuscles. This effect is produced by the white blood cell (WBC) in the perifoveal capillaries and, hence, reflects indirectly the circulation in the macular area.
  - *Interpretation:* 99% of normal subjects visualize at least 15 or more corpuscles seen equally in different quadrants. Abnormal results are indicated by reduced number in one or more quadrants. Reasonable grasp and intelligence is needed to perform the test. Hence, a positive response is of more benefit in interpretation than negative one. This test was found to perform better than two-point discrimination test or Purkinje vascular entopic phenomenon test.[2]
- *Yellow filter test of Koch:* If a transparent yellow filter is placed over reading material, it is noted to improve vision in eyes with macular degeneration but deteriorate the vision in eyes with only cataract.
- *Potential acuity meter:*
  - *Principle:* A miniature visual acuity chart is projected on the retina through areas of clarity in the lens and patient asked to read the letters. Focusing of the chart is done to permit patient to see clearly.
  - *Interpretation:* Best results are achieved in cataracts that have not progressed beyond 6/60 level. In general, if more than four-line improvement is predicted, the prognosis after cataract surgery is likely to be good. A predictive capability of 90% and above has been reported.[3] False-positives have been seen with some maculopathies. In general, it is supposed to underestimate rather than overestimate the recovery.
- *Laser interferometry:*
  - *Principle:* Helium-neon laser provides a collimated beam that is optically split into two. The two beams are projected through clear spaces in the lens to meet behind the lens. This produces interference fringes. The size and orientation of the stripes so produced can be varied.
  - *Interpretation:* The patient is expected to identify correctly the orientation of the stripe as the test is repeated with finer stripes. Unlike the PAM test, focusing is not needed and so the refractive error does not affect the test. However, aphakic eyes are best tested with corrective lens. A conversion table indicates the maximal potential vision. The test tends to overpredict the visual potential in amblyopic eyes.
- *Lotmar visometer:*
  - *Principle:* This test is similar to laser interferometer but uses white light instead of laser and hence is less expensive. Moiré fringes are formed using two rotatable equal gratings. The fringes are split into two coherent beams and projected through pupil.
  - *Interpretation:* Interference stripes formed are similar to laser interferometry and interpretation is also similar. The predictions are in general more optimistic especially with macular diseases.

JAYPEE BROTHERS

- Illuminated *near card assessment:*
  - *Principle:* The device is a handheld instrument containing a brightly illuminated vision chart that is transported across a 7 mm by 38 mm viewing window. Visual angle subtended at 16 inches equals that subtended by a letter at 20 feet.
  - *Interpretation:* Illuminated near card (INC) was found to be more predictive in eyes with comorbid disease, in contrast to interferometers and PAM.
- *Vryghem macular function test:*[4]
  - *Principle:* A simplified method of using near vision chart, the Vryghem test uses the Parinaud's near vision chart, a +8.00 diopter lens and the Heine ophthalmoscope. The vision chart is placed 12 cm from the patient. +8.00 diopter lens is placed over the best distance vision correction in a trial frame. The chart is illuminated with the Heine ophthalmoscope light. Those reading the smallest numbers (Parinaud 1) are expected to be having good macular function.
- Multifocal *electroretinogram (MFERG):* It can potentially indicate the macular function. However, dense cataracts do not permit MFERG.
- *Flicker fusion frequency (FFF) testing:*
  - *Principle:* Cone dominated fovea is sensitive to flicker. Reduced FFF indicates impaired macular function. *The test is considered to be resistant to optical blur.*
  - The modified ophthalmoscopic or Maxwellian view system utilizes a small central flickering stimulus of about 1–4° presented with peripheral retina being suppressed by an annulus of white light.
  - Maxwellian view is ideal for macular testing since it gives pupillary size independent retinal luminance.

EYES WITH DENSE CATARACT

In eyes with dense cataract the approach to assess the potential for visual recovery would be different compared to those with mild-to-moderate cataracts. Here one must contend with the possibility of neither being able to see the macula clinically nor being able to image the same. Sometimes even the status of the retina (attached or detached) may not be possible to evaluate clinically and would need ultrasound examination.

Guidance from History

Perusal of old medical records can be of value to decipher previous notifications of macular diseases. History of poor vision since childhood can be due to amblyopia.

CLINICAL EVALUATION

- *Perception of light and accurate projection:* Although accurate projection is encouraging, it excludes only large retinal detachments and absolute field defects and not macular diseases. Similarly, dense cataracts can so scatter light that inaccurate projection can still be compatible with good visual recovery.
- *Two-point discrimination:* Ability to distinguish two lights close together is a good sign but cannot exclude macular disease.
- *Color perception:* Although ability to identify colors is suggestive of potentially good macular function, macular degeneration is known to exist with good color perception.
- *Pupillary assessment:* This is perhaps the best objective evidence for presence or lack of gross posterior segment disease. Both extensive retinal disease and optic nerve disorders will produce afferent pupillary defect. Even total cataracts are known not to produce afferent pupillary defect if posterior segment is normal. However macular disorders are not excluded even if pupils are brisk.
- *Entopic visualization:* Eber and Friedman described a test where in a light is gently rubbed on closed eye lids to-and-fro against the sclera. This can stimulate Purkinje vascular tree images. While some patients can detect the optic disc shadow and macula, others may not appreciate the detail despite having good macular function. It is most useful to compare between the two eyes.

JAYPEE BROTHERS

- *Maddox rod test:* If light is shone behind a Maddox rod held in front of the eye, a continuous red streak will be made out. A break in the line indicates possible central scotoma. A high index of suspicion is needed to suspect macular problems when there is mismatch between the vision and the degree of cataract. Information from more than one way of evaluation is needed for proper conclusions.

REFERENCES

1. Melki SA, Safar A, Martin J, Ivanova A, Adi M. Potential acuity pinhole: a simple method to measure potential visual acuity in patients with cataracts, comparison to potential acuity meter. Ophthalmology. 1999;106(7):1262-7.
2. Sinclair SH, Loebl M, Riva CE. Blue field entoptic phenomenon in cataract patients. Arch Ophthalmol. 1979;97(6):1092-5.
3. Ing MR. Potential acuity meter to predict postoperative visual acuity. J Cataract Refract Surg. 1986;12(1):34-5.
4. Vryghem JC, Van Cleynenbreugel H, Van Calster J, Leroux K. Predicting cataract surgery results using a macular function test. J Cataract Refract Surg. 2004;30(11):2349-53.

3.5 Informed Consent for Cataract Surgery with or without Implantation of an Intraocular Lens

Arun K Jain
Advanced Eye Centre, PGIMER, Chandigarh
arooonjain@hotmail.com

PATIENT INFORMATION SHEET

A sample consent and patient information brochure is attached:
Name of Patient.....
Age/Sex.....
Patient ID.....
Son/Daughter.....of.....
.....
Address.....Tel.....

WHAT IS A CATARACT?

Cataract is a condition in which the lens in your eye becomes opacified, making it difficult for you to see well enough to carry out your usual daily activities. To correct this, the cataract will need removal with an operation. The natural lens within your eye with a slight cataract, although not perfect, still has some advantages over an artificial lens. In giving permission for cataract extraction with/without implantation of an intraocular lens (IOL) in my eye, I declare that I understand the following information.

BENEFITS AND RISKS OF CATARACT SURGERY

Most people find that their eyesight improves considerably after cataract surgery. However, you should be aware that there exists a small risk of complications, either during or after the operation. If you have any questions, you can clarify with your doctor.

The Procedure

- The purpose of the surgery is to replace the opacified lens (cataract) with an artificial lens (implant) inside your eye.
- This artificial lens, usually made of plastic, silicone, or acrylic material, surgically and permanently placed inside the eye, and hence called an IOL. Eyeglasses may be required in addition to the IOL for best vision.

JAYPEE BROTHERS

- An experienced eye surgeon will carry out the surgery or may supervise a doctor in training who also performs some operations.
- The surgery is performed under a local anesthetic, you will be awake during the operation. Just before the operation, you will be given eyedrops to enlarge the pupil. After this, you will be given an anesthetic to numb the sensations and decrease the movements of the eye. This may consist simply of eyedrops or injecting local anesthetic solution into the tissue surrounding the eye.
- During the surgery you will be asked to keep your head still and lie as flat as possible. The surgery normally takes 15–20 minutes but may take up to 45 minutes.
- Most cataracts are removed by a technique called phacoemulsification, in which the surgeon makes a very small cut into the eye, softens the lens with sound waves and removes the cataract through a small tube. The back layer of the lens is left behind.
- An artificial lens (implant) is then inserted to replace the cataract. After your natural lens is removed, the IOL is placed inside your eye. In rare cases, it may not be possible to implant the IOL you have chosen or any IOL at all. Sometimes a small stitch is put across cut created in the eye. At the end of the operation, a pad or shield may be put over your eye to protect it.

After the Operation

If you have any discomfort, we suggest that you take a pain reliever such as paracetamol or diclofenac. It is normal to have some watery discharge, feel itching, sticky eyelids, and mild discomfort for a while after cataract surgery. After a few days even mild discomfort should disappear.

In most cases, healing will take about 2–6 weeks, after which new glasses will be prescribed by your optician. You will be given eyedrops to minimize inflammation. The hospital staff will provide necessary instructions regarding the use of various medicines and the precautions to be kept in mind for next few days. Certain symptoms could mean that you need *prompt treatment*, including:

- Excessive pain
- Decrease/loss of vision
- Increasing redness of the eye

Likelihood of Improvement of Vision

After the operation you may read or watch TV almost straight away, but your vision may be blurred. The healing eye needs time to adjust so that it can focus properly with the other eye, especially if the other eye has a cataract. The vast majority of patients have improved eyesight following cataract surgery. Please note that if you have another condition, such as diabetes, glaucoma, or age-related macular degeneration your quality of vision may still be limited even after successful surgery.

Possible Complications during the Surgery

- Tearing of the back part of the lens capsule with disturbance of the gel inside the eye that may sometimes result in reduced vision.
- Loss and drop of all or part of the cataract into the back of the eye requiring another surgery which may require general anesthesia.
- Bleeding inside the eye.

Possible Complications after the Surgery

- Bruising of the eye or eyelids
- High pressure inside the eye
- Clouding of the cornea
- Incorrect strength or dislocation of the implant
- Swelling of the retina—macular edema

JAYPEE BROTHERS

- Detachment of retina which can lead to loss of sight
- Infection in the eye, i.e., endophthalmitis, which may lead to loss of sight or even loss of the eye.
- Allergy to the medications used
- Dry eyes symptoms
- New appearance of floaters and/or increase in floaters.
- Risks of cataract surgery include, but are not limited to.

Complications of removing the natural lens may include:

- Hemorrhage (bleeding), rupture of the capsule that supports the IOL and perforation of the eye.
- A cloudy cornea which may or may not settle. This may require further surgery; an acute inflammatory reaction causing pain. This may need further treatment.
- Swelling in the central area of the retina (called cystoid macular edema), which usually improves with time.
- Retained pieces of lens in the eye, which may need to be removed surgically, infection.
- Detachment of the retina, which is definitely an increased risk for highly nearsighted patients, but which can usually be repaired.
- Uncomfortable or painful eye, droopy eyelid, increased astigmatism, glaucoma, and double vision.

These and other complications may occur whether or not an IOL is implanted and may result in poor vision, total loss of vision, or even loss of the eye in rare situations. Additional surgery may be required to treat these complications. Any of these complications may occur, but these complications are now rare.

Complications associated with the IOL may include:

- Increased night glare and/or halo.
- Double or ghost images, and dislocation of the IOL. Multifocal IOLs may increase the likelihood of these problems.
- In some instances, corrective lenses or surgical replacement of the IOL may be necessary for adequate visual function following cataract surgery.

Complications associated with local anesthesia injections around the eye include:

- Perforation of the eye
- Destruction of the optic nerve
- Interference with the circulation of the retina
- Droopy eyelid, respiratory depression, hypotension, and cardiac problems
- In rare situations, brain damage or death

Complications of Surgery in General

As the procedure is generally done under local anesthesia the risk to life is <0.5%.

- If an *IOL is implanted*, it is done by a surgical method. It is intended that the small plastic, silicone, or acrylic IOL will be left in the eye permanently.
- If a monofocal IOL is implanted, either distance or reading glasses or contacts will be needed after cataract surgery for adequate vision.

If complications occur at the time of surgery, the doctor may decide not to implant an IOL in your eye even though you may have given prior permission to do so.

Complications associated with multifocal IOLs. While a multifocal IOL can reduce dependency on glasses, it might result in less sharp vision, which may become worse in dim light or fog. It may also cause some visual side effects such as rings or circles around lights at night. Driving at night may be affected. If complications occur at the time of surgery, a monofocal IOL may need to be implanted instead of a multifocal IOL.

Although you may have opted for phacoemulsification surgery and the same may have been planned by your surgeon after preoperative examination, if during surgery,

JAYPEE BROTHERS

phacoemulsification is found to be unsafe or not feasible, your surgeon will have the liberty to perform surgery by the conventional technique in the interest of patient safety.

Other factors may affect the visual outcome of cataract surgery, including other eye diseases, such as glaucoma, diabetic retinopathy, age-related macular degeneration, the power of the IOL, your individual healing ability, and if certain IOLs are implanted, the function of the ciliary (focusing) muscles in your eyes.

The selection of the proper IOL, while based upon sophisticated equipment and computer formulas, is not an exact science. After your eye heals, its visual power may be different from what was predicted by preoperative testing. You may need to wear glasses or contact lenses after surgery to obtain your best vision. Additional surgeries, such as IOL exchange, placement of an additional IOL, or refractive laser surgery may be needed if you are not satisfied with your vision after cataract surgery.

The results of surgery cannot be guaranteed. If you chose a multifocal IOL, it is possible that not all the near (and intermediate) focusing ability of your eye will be restored. Additional treatment and/or surgery may be necessary. Regardless of the IOL chosen, you may need laser surgery to correct clouding of vision. At some future time, the IOL implanted in your eye may have to be repositioned, removed surgically, or exchanged for another IOL.

Since only one eye will undergo surgery at a time, you may experience a period of imbalance between the two eyes (anisometropia). In the absence of complications, surgery on the second eye can usually be accomplished within 2–4 weeks, once the first eye has stabilized.

Condition and Procedure

The doctor has explained that I have the following condition:
(Doctor to document in patient's own words)
The following procedure will be performed to the .....
.....eye(s):
(Doctor to document which side)

PATIENT CONSENT

- Cataract surgery, by itself, means the removal of the natural lens of the eye by a surgical technique.
- For an IOL to be implanted in my eye, I understand I must have cataract surgery performed either at the time of the IOL implantation or before IOL implantation.
- If my cataract was previously removed, I have been informed that my eye is medically acceptable for IOL implantation.
- I understand that a doctor other than the consultant surgeon may conduct the procedure. I understand this could be a doctor undergoing further training.
- I consent to the administration of anesthesia and to the use of such anesthetics as may be deemed necessary or desirable. I further consent to the administration of such drugs or infusions deemed necessary in the judgment of the medical staff.

The basic procedures of cataract surgery, the reasons for the type of IOL chosen for me, and the advantages and disadvantages, risks, and possible complications of alternative treatments have been explained to me by my ophthalmologist. I understand that if organs or tissues are removed during the surgery, these may be retained for tests for a period of time and then disposed off sensitively by the hospital.

I am fully aware that the surgery is being performed in good faith and that no guarantee or assurance has been given as to the result that may be obtained. I understand that photographs or video footage may be taken during my operation. These may then be used for teaching health professionals. You will not be identified in any photo or video.

Although it is impossible for the doctor to inform me of every possible complication that may occur, the doctor has answered all my questions to my satisfaction.

JAYPEE BROTHERS

Based on Above Information

I undersigned (the patient or nearest relative) hereby give my consent for the operation of left eye/right eye with the full knowledge of possible complications and guarded/poor vision prognosis. I certify that I have read this informed consent/it has been read over to me and explained to me in my mother tongue and all blanks or statements requiring insertion or completion were filled in and any inapplicable paragraphs stricken off before I signed. The doctor has answered all my questions to my satisfaction.

Signature/Thumb Impression of Patient/Parent/Guardian: .....
.....
Name of Patient/Parent/Guardian..... Date.....
A sample consent and patient information brochure is attached:
Name of Patient.....
Age/Sex.....Patient ID.....
Son/Daughter of .....
Address.....Tel. .....

SUGGESTED READING

1. Informed consent for cataract surgery. San Francisco: American Academy of Ophthalmology; 2008.

3.6 How do You Counsel Amblyopic Adult with Cataract before Surgery?

Jaspreet Singh Sukhija
Advanced Eye Centre, PGIMER, Chandigarh
jaspreetsukhija@yahoo.com

INTRODUCTION

Amblyopia is impaired or diminished vision in one or both eyes due to a maldevelopment of visual pathway arising from strabismus, anisometropia, or form deprivation in infancy or childhood. The visual system is thought to be sensitive to visual inputs only during a limited period of time early in life—the critical period of visual development, when it is immature and plastic.

Hence, therapy for amblyopia does not offer promising results for patients over the age of 9–10 years.

INDICATIONS OF CATARACT SURGERY IN AMBLYOPICS

It is of paramount importance to consider these possibilities in a patient with cataract where history is suggestive of amblyopia and as much of the visual input from the amblyopic eye is usually suppressed, so it might be expected that cataract in this eye would not significantly affect the patient's quality of life.

However, patients are frequently symptomatic and request cataract surgery as amblyopic eye is very sensitive at detecting blur (one of the principal effects of cataract) despite reduced visual acuity and contrast sensitivity.

Another indication is a complaint of glare, halos, misty vision, and monocular diplopia.

Diagnosing Amblyopia

1. A history of decreased vision since childhood not fully corrected with refractive aids.
2. Note any misalignment of the eyes which may suggest amblyopia.

JAYPEE BROTHERS

3. Also the cataract density will not correlate to the amount of visual loss. This should raise suspicion that the patient is amblyopic after detailed examination reveals no ocular pathology.
4. Presence of a significant refractive error (hyperopia or high myopia) not correlating with the type of cataract would be another indicator of amblyopia.
5. Significant difference in biometry between two eyes.

Correction of amblyopia in cases with senile cataract is a very remote possibility. Thus, counseling such patients regarding the expected visual gain is extremely important. One needs to trace the previous records and compare the best corrected visual acuity. If a significant deterioration in the visual acuity is noted because of the development of cataractous changes, then the vision is expected to improve after surgery.

The benefits of a surgical intervention in patients with sensory amblyopia are further limited. They must be clearly explained the realistic goals of cataract surgery in their case. There is no investigative tool which can quantify the amount of postsurgical visual gain in amblyopic patients.

In young patients, there still exists potential for good visual gain following cataract surgery as there is a possibility that amblyopia therapy may help them. However, those with senile cataract are expected to benefit the least.

Laser interferometry may provide false positive results in amblyopics.

SUGGESTED READING

1. Hale JE, Murjaneh S, Frost NA, Harrad RA. How should we manage an amblyopic patient with cataract? Br J Ophthalmol. 2006;90(2):132-3.

3.7 Sterilization of Operating Room

Jagat Ram, Sunil Kumar
Grewal Eye Centre, Chandigarh
drjagatram@yahoo.com

INTRODUCTION

Maintenance of asepsis is imperative to ensure safe surgery and to minimize postoperative infection and its disastrous consequences. Postoperative endophthalmitis remains one of the most devastating complications of eye surgery.

Ventilation, cleaning, disinfection, and sterilization are the cornerstones in ensuring operating room (OR) asepsis.

VENTILATION IN OPERATING ROOM

The OR should be well-ventilated and the circulating air should be filtered.

- High efficiency particulate air (HEPA) systems remove most microorganisms ranging in size from 0.5 to 5.0 μm. The principle of ventilation in the OR is the delivery of positive pressure filtered air in a vertical unidirectional flow over the operating table. The current United States Public Health Service minimum requirements for optimum OR air is as follows—temperature between 18°C and 24°C, humidity 55–80%, and 25% changes per hour. Laminar airflow curtains or a radial exponential airflow pattern away from the operating field are especially helpful.
- In the surgical OR providing facilities for most forms of surgery, the recommended bacterial count of air should not exceed $1/ft^3$ ($35.5/m^3$). Air entering the OR from filters should not contain $>0.5/m^3$ of bacteria-containing particles. Furthermore, the bacteria-containing particles of air within 30 cm of the operation site should not exceed $10/m^3$ and should not be $>20/m^3$ in the rest of the OR.

JAYPEE BROTHERS

CLEANING THE OPERATING ROOM

- Cleaning essentially means the removal of foreign matter (e.g., soil and organic matter) from the concerned surface.
- All surfaces should be free from visible dirt. It is normally accomplished with water, mechanical scrubbing, and detergents.
- Cleaning also reduces the bacterial count, though it will not disinfect or sterilize.

DISINFECTION AND STERILIZATION OF THE OPERATING ROOM

- Disinfection is a process of freeing the concerned object of all pathogenic microorganisms which may cause infection during its use.
- Sterilization is a process that eliminates all living organisms from the treated object. It is impractical to attempt to sterilize the entire OR and equipment, therefore current practices concentrate on disinfection. The measures commonly used are discussed below.

Chemical Disinfection

Phenolic Compounds

- Good bactericidal and fungicidal action.
- They are sometimes virucidal but are not sporicidal, except at temperatures over 100°C. They are very stable and remain effective after mild heating and prolonged drying.
- However, these agents are not recommended as high-level disinfectants due to their lack of activity against bacterial spores and lack of published efficacy data of available formulations.
- This class of compounds is used for decontamination of the OR and for noncritical medical and surgical items. The floor and 2 m of OR walls should be mopped with phenolic solution. Similarly, wet mopping of all OR tables, mats, instrument trolleys, stools, chairs, and supply shelves with phenol followed by a wipe down with 70% alcohol is an effective daily decontaminating regimen.

Formaldehyde Fumigation

Formaldehyde is an effective agent commonly used to sterilize OR. The efficacy of the process is uncertain at temperatures <20°C and relative humidity <70%.

- For optimum OR disinfection, formaldehyde fumigation is recommended fortnightly as a routine, and at the end of an operating session of a grossly infected case.
- All apertures in the room should be sealed with adhesive tape prior to fumigation.
- The gas is liberated by spraying or heating formalin or solid paraformaldehyde. For each 1,000 ft^3 of space (28.3 m^3), 500 mL of 40% formaldehyde in 1 L of water is put into an electric boiler or a large bowl placed on an electric hot plate with safety cut-out when boiling dry. The OR is sealed after turning on the boiler or hot plate. After fumigation, the room is kept closed for at least 8–10 hours.
- Subsequently, ammonium solution is introduced and left in the room for a few hours to neutralize the formaldehyde (1 L ammonium solution plus 1 L of water for every liter of 40% formaldehyde used).

Other Methods of Formalin Fumigation

- *Permanganate method:* Five ounces of potassium permanganate for every 1,000 ft^3 of space are placed in a jar and on top of this 10–15 ounces of 40% formalin diluted with an equal amount of water is poured. As soon as the reagents are mixed, a violet effervescence takes place and formaldehyde is set free.

JAYPEE BROTHERS

- *Paraform method:* On heating formalin, the aldehyde changes into the solid polymeride—paraform. Gas is generated by heating paraform tablets. 25–30 tablets are required for every 1,000 ft^3 of space.
- *Formalin spray/vaporizer:* Aeromax vaporizer can be used to fumigate an OR. 250 cc of 40% formalin dissolved in 5,000 cc tap water makes a dilution of 1:20. 1 L of the solution is used per 1,000 ft^3 of space. This is vaporized for over half an hour. Spraying is not a satisfactory substitute for vaporization of formaldehyde by boiling as the fine aerosol has poor penetration.

Bacillocid Rasant

- It is newer and commercially available compound used for surface and environmental decontamination. It has excellent cleansing properties with bactericidal, virucidal, sporicidal, and fungicidal activity.
- *Active ingredients:*
  - Glutaraldehyde 100 mg/g
  - Benzyl-C12-18-alkyldimethylammonium chlorides 60 mg/g
  - Didecyldimethylammonium chloride 60 mg/g.
- *Advantages:*
  - Complete asepsis is achieved within 30–60 minutes.
  - Cleaning with detergent or carbolic acid is not required.
  - Formalin fumigation is not required.
  - Shutdown of operation theater (OT) for 24 hours is not required.

Ecoshield

It is stabilized hydrogen peroxide 11% w/v and 0.01% w/v, diluted silver nitrate solution. It can be used for routine mopping of floors and cleaning of OT equipment. It is also used in the form of hydrogen peroxide vapors (fogging) in the disinfection of OT at the end of routine cases, as well as infected cases.

Alkedol

A new method of fumigation:

- *Ingredients:*
  - 6% formaldehyde
  - 6% glutaraldehyde
  - 5% benzalkonium chloride.

Fogging

- Fogging involves nebulization of a disinfectant in a room until all surfaces are wet, followed by wiping off residual fluid from surfaces by masked and gowned personnel. It is not commonly used in recent times.
- Earlier fogging was carried out using formaldehyde. However, due to its carcinogenic effects it is now seldom used. Commercially available disinfectants such as Ecoshield® are now used for fogging.
- The disinfectant is put in a fogger machine and the machine is switched on for 45 minutes in the sealed OT, following which the room is kept sealed for another 45 minutes. Hydrogen peroxide has the advantage of being safer, less irritating, and has shorter cycle times compared with formalin fumigation.

Ultraviolet Radiation

Daily ultraviolet (UV) irradiation for 12–16 hours is recommended and is to be switched off 2 hours before starting OT.

JAYPEE BROTHERS

Operation Theater Cleaning Schedule

Before surgery:

- Wet mopping with disinfectants must be done in the morning.
- All equipment, OT tables, walls, and floors must be cleaned and sterilized using appropriate methods.

Between operative procedures:

- Cleaning of operation tables and OT equipment with disinfectant solution is recommended.
- In case of spillage of blood/body fluids decontamination with chlorine solution.
- Wastes should be discarded in recommended color-coded plastic bags.
- Soiled gowns must not be disposed inside the OT.

After surgery:

- Linen and waste material is collected in color-coded bags according to hospital waste disposal protocol.
- Soiled linen is collected separately outside the OT to the dirty utility room, where it is disinfected by soaking in clean water with 0.5% bleaching powder solution for 30 minutes before being dispatched to the laundry facility.
- The OT table is cleaned with water and then carbonized with 0.5 chlorine/70% isopropyl alcohol.

OPERATING ROOM ETIQUETTE

A high standard of discipline is necessary for the safe conduct of any surgery. Minimum number of OT personnel should be allowed to enter the OT complex.

- Anyone with overt infection should be barred.
- All persons entering the OR should change into freshly laundered clothing.
- Hair and beards should be clean and well covered by caps and masks. High-filtration disposable masks are to be worn at all times when within the aseptic zone. All persons must wash their hands thoroughly before entering the OR.

OPERATING ROOM WASTE DISPOSAL

Operating room biohazardous waste including infected linen, disposable syringes, and needles, intravenous (IV) drip sets, IV fluids, and infected and diseased excised pathological tissue poses a significant health hazard to the OR personnel and public. Safe disposal is imperative to prevent the spread of infection and possible recycling of hazardous disposable products.

Thus, proper sterilization of OR with maintenance of high OR etiquette and safe OR waste disposal is mandatory to ensure safe surgery and to minimize postoperative infection and its disastrous consequences.

EDITOR'S PEARLS

- Regular surveillance becomes the most critical measure to keep OR infection free. Taking swabs from walls, microscope handles, floor, AC ducts, OR chairs, and even washing soaps for culture must be the standard practice protocol.
- Adequate disposal of all biomedical wastes should be taught to every healthcare personal with routine drills at regular intervals.
- A dedicated infection control team should ensure that the requisite protocols are enforced and adhered to.

SUGGESTED READING

1. ESCRS Endophthalmitis Study Group, European Society of Cataract and Refractive Surgeons. Prophylaxis of postoperative endophthalmitis following cataract surgery: results of the ESCRS multicenter study and identification of risk factors. J Cataract Refract Surg. 2007;33(6):978-88.

JAYPEE BROTHERS

3.8 Antibiotic Prophylaxis after Cataract Surgery

Sushmita Kaushik
Advanced Eye Centre, PGIMER, Chandigarh
sushmita_kaushik@yahoo.com
Parul Ichhpujani
Government Medical College and Hospital, Chandigarh
parul77@rediffmail.com

INTRODUCTION

Cataract surgery is the most common ocular surgery performed in the geriatric population. Although in the current era, endophthalmitis is relatively rare, but the frequency of cataract surgery makes the absolute number of cases significant enough for it to be labeled a public health concern. The incidence rates of acute-onset postoperative endophthalmitis (POE) (presenting within 6 weeks of surgery) range from 0.02 to 0.17%. Given the enormous global volume of cataract surgery, even marginal reductions in POE translate into substantial public health benefit, underscoring the importance of evidence-based and stewardship-conscious prophylactic strategies.

Endophthalmitis prevention is difficult to investigate because of the large number of variables associated with even the most routine form of cataract surgery. Common risk factors for POE include old age, blepharitis, ectropion, rural residence, immunosuppressive conditions (diabetes mellitus), clear corneal incisions, use of silicone intraocular lenses (IOLs), and presence of surgical complications, such as posterior capsular rent.

There is no worldwide established approach to prophylaxis of endophthalmitis as cataract surgeons across the globe have their own preferred practice patterns based on extrapolations of the evolving scientific literature.

PATHOPHYSIOLOGY OF POSTOPERATIVE ENDOPHTHALMITIS

- Bacteria have been found in normal conjunctival flora without the use of antibiotic agents. Organisms present on the eyelid margin, are transferred to the conjunctiva, because of contamination. Diphtheroids, *Staphylococcus epidermidis*, *Staphylococcus aureus, Streptococcus* species (*Streptococci viridans*), *Neisseria*, gram-negative bacilli (often *Moraxella* species), *Propionibacterium acnes*, and rarely, fungi may also be present in the conjunctival cul-de-sac. These observations support preventive strategies aimed at reducing conjunctival microbial load preoperatively and achieving bactericidal intraocular concentrations at the conclusion of surgery.
- Causative pathogens may also arise from tainted intraocular solutions, infected IOLs or surgical instruments, airborne contaminants, and operation theater personnel.
- *Endophthalmitis vitrectomy study (EVS):* EVS reported that gram-positive bacterial infections were more common. Although rare, gram-negative were more virulent and resulted in more dismal outcome.

CHARACTERISTICS OF AN "IDEAL" PROPHYLACTIC ANTIBIOTIC

- Potent against common pathogens
- Favorable pharmacokinetic profile
- Least potential for resistance
- Excellent safety profile
- Preservative-free formulation
- Ease of preparation and application
- Affordable

JAYPEE BROTHERS