bsite www.jaypeebrothers.com, for detailed information on dental books, visit our website www.jaypeebrothers.com

Manual of Temporomandibular Joint

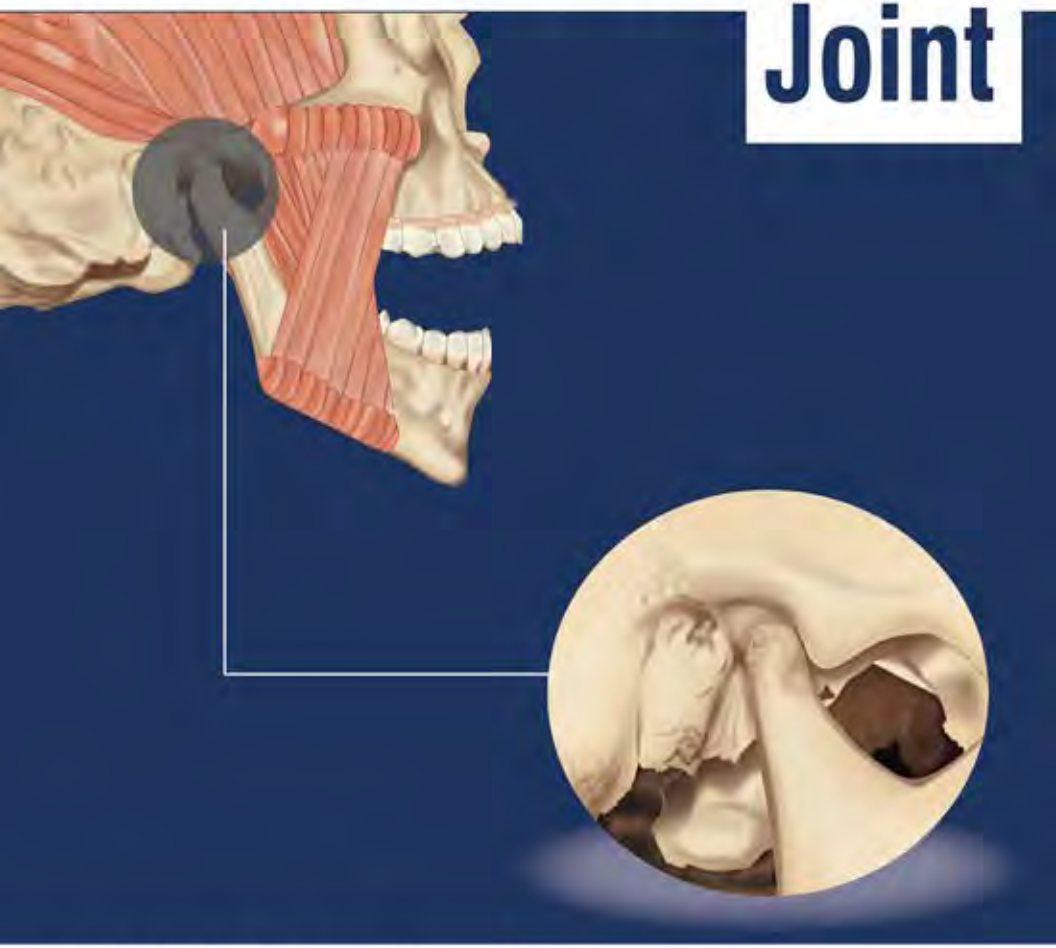

Shivlal M Rawlani

Co-author
Sudhir S Rawlani

Forewords
AJ Pakhan
Rahul R Bhowate

JAYPEE

Contents

1. Introduction 1
Shivlal M Rawlani, Sudhir S Rawlani

2. Embryology and Development of Temporomandibular Joint 4
Shivlal M Rawlani, Sudhir S Rawlani
The transformation of the reptilian jaw to the mammalian 7
Chronological development of the TMJ 10

3. Anatomy of Temporomandibular Joint 15
Shobha Rawlani, Shivlal M Rawlani
Osseous components of TMJ 20
The temporal component of the TMJ 21
Soft tissue components of TMJ 22

4. Articular Disc 31
Shivlal M Rawlani, Sudhir S Rawlani
Disc shape 33
Disc contour 34
Histology of the disc 34
Posterior discal band 35
Anterior discal band 35
Intermediate discal zone 35
Retrodiscal tissue 35
Functions of the articular disc 36
Relationship of the condyle and disc 36
Functional anatomy 37
The retrodiscal pump 37
The synovial membrane 37
Functions of the synovia 38
Synovial fluid 38

5. Temporomandibular Joint Imaging 39
Shivlal M Rawlani, Sudhir S Rawlani
Conventional radiography 40
Computed tomography 48
Arthrography 50
Arthroscopy 51
Nuclear medicine 57

6. Clinical Evaluation of Temporomandibular Joint 59
Shivlal M Rawlani, Shraddha Patel
Chief complaint 59
Pain referring to the TMJ region 61
Masticatory and associated muscles 69
Soft tissue changes 72

7. Temporomandibular Joint Disorders and its Managements 74
Shivlal M Rawlani, Sudhir S Rawlani
Review of classification 75
Myofascial pain disorder 78
Developmental disorders of TMJ 89
Traumatic disorder of TMJ 92
Metabolic disorder 96
Neoplastic disorders 98
Miscellaneous disorders 98
Surgical procedures 99

8. Orthodontic Considerations in Temporomandibular Joint 103
Ranjit Kamble, Jimmy Sangtani
Temporomandibular joint disorders 103
Various definitions of TMDs 105
Etiology of TMD is multifactorial 106
Etiology in relation to orthodontics 112
Classifications of TMD 118
TMD and malocclusion 121
TMD and orthodontics 122
Behavior of TMJ in response to myofunctional treatment 127
Signs and symptoms of TMDs 131
Other signs and symptoms of TMDs 133
Management of TMDs 133
Oral appliances 134
Mode of action 136
Types of splints 136

Management of dental occlusion 138
Management according to type of disorder 140

9. Prosthodontic Considerations of Temporomandibular Joint Disorders 141
Surekha Godbole, Aniket Gupta
Clinical features 141
Definition of TMJ disorder 141
Etiology 142
Classification 145
Measurement of jaw movements 148
Examination of occlusion 149
Occlusal appliance therapy 153
Occlusal splints 153
Functions of splints 154
Uses of splint 154
Types of occlusal splint 155
Splint types 156
Muscle relaxation (MR) appliance 157
Anterior repositioning appliance 161
Anterior bite plane 162
Posterior bite plane 164
Pivoting appliance 164
Soft or resilient appliance 165
Choosing the correct splint 166
What splints cannot do? 167

10. Pediatric Considerations in Temporomandibular Joint Disorders 168
Monika Rawlani
Background 168
Temporomandibular disorder 169
Prevalence of TMD in children and adolescents 169
Etiology of TMD: Development of etiological concepts 170
The multifactorial model 170
Predisposing (or risk) factors for TMDs 172
Systemic factors 173
Clinical findings in TMDs 174
Diagnostic criteria 176
Neoplasms 179
Temporomandibular joint dislocation 179

Myofacial pain 182
Myositis or inflammatory myalgia 182
Myospasm or tonic contraction myalgia 183
Habits 183
Examination for TMDs 185
Recommendations 189

11. Relation of Periodontal Health with Temporomandibular Joint 190
Manohar Bhongade, Sneha Puri
Effect of parafunctional habits on TMJ 190
Effect of bite stability on TMJ 195
Relationship between bone mineral density and TMJ 196
Osseoperception in implants supported prosthesis: TMJ perspective 196
Temporomandibular joint problems and peridontal condition in rheumatoid arthritis 197
Tooth mobility and TMJ 198
Occlusal examination in TMJ disorders 200

12. Temporomandibular Joint Functioning and Conservative Dentistry 202
Manoj Chandak, Rakhi Chandak
Inter-relation of occlusal discrepancies and temporomandibular joint 202
Inter-relation of occlusal discrepancies: Temporomandibular joint disorder and stress 203
Ideal requirements for occlusion in posterior restorations 205
Occlusal considerations in restoring individual teeth 211
Checking the occlusion (Occlusal adjustment) 212

Index 215

CHAPTER

2 Embryology and Development of Temporomandibular Joint

Shivlal M Rawlani, Sudhir S Rawlani

The structures of the temporomandibular articulation have been found to originate from two different blastemas. They are situated at a relatively large distance from one another and grow at different rates. They are, respectively, the condylar blastema and the temporal blastema. The condylar blastema evolves to contribute to formation of the condylar cartilage, the aponeurosis of the external pterygoid muscle, the disc, and the capsular elements of the joint. The temporal blastema develops into the articular structures of the upper level (Figs 2.1A and B).

The condylar blastema forms at the distal end of the mandible, or dentary. The dentary begins to ossify in the symphyseal integument at about seventh week of fetal life, at approximately the 19-mm stage of fetal development. By the time of eight week, or 22-mm stage of fetal development, a significant amount of bone has been laid down in a plate like form lateral to Meckel's cartilage (Fig. 2.2). Meckel's cartilage extends from the midline to the developing chin to the developing middle ear. It is here in the middle ear region, that the malleus and probably incus develop as posterior extension of Meckel's cartilage. The intermediate portion of Meckel's cartilage

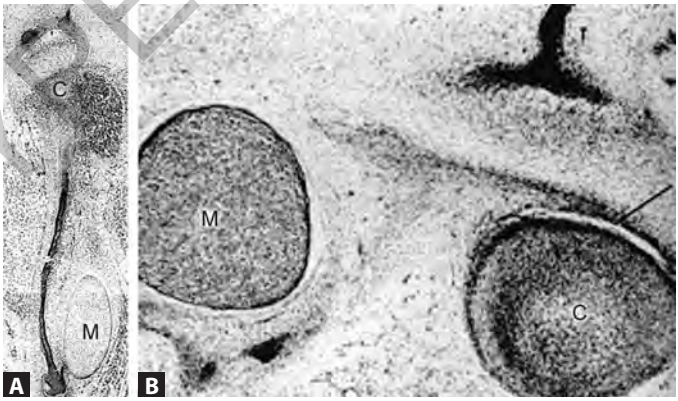

Figs 2.1A and B: Condylar blastema and the temporal blastema

JAYPEE BROTHERS

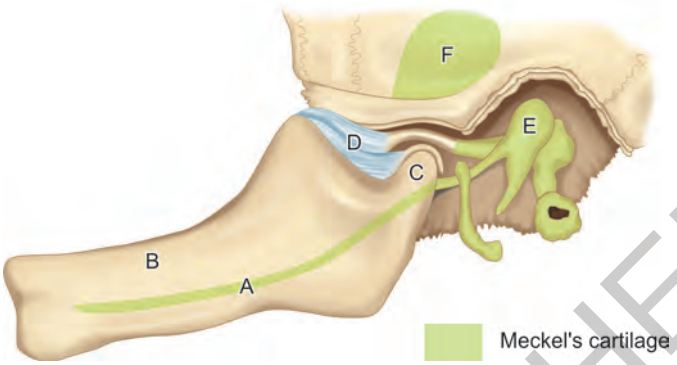

Fig. 2.2: Meckel's cartilage

disappears, but its sheath remains to persist in the formation of the anterior malleolar ligament and the sphenomandibular ligament.

When the embryo has reached the 24-mm stage, the pterygoid and masseter muscles have differentiated. At the superior border of the external pterygoid muscle and just mesial to the masseter muscle there is a layer of mesenchyme which is the anlage of the articular disc.

The condylar cartilage becomes an evident structure by the eleventh week. It is located at the upper end of the posterior border of the developing mandible. As the condyle continues to grow, its articular surface changes its shape. The condylar cartilage shapes the articulating surface of the condyle in a hemisphere by the 50-mm stage of embryonic development. At the same stage the articular disc has flattened, and the plane of the articular surfaces has undertaken a shift of 45 degrees. The joint cavities have not completely formed yet, and the disc and the condyle are not in contact with temporal bone.

At the 55-mm stage the condylar head produces an osseous head, which matures into condylar cartilage by 65-mm stage. This condylar cartilage begins ossification at the 85-mm stage, after which it forms the growth center of the mandible. At the 13th weeks of the embryonic life (90-mm) the lower joint cavity is fairly well formed around the superior surface of the mandibular condyle. The upper part of the joint cavity is also becoming a distinct entity during this period (Fig. 2.3). By the time fetal development has reached fifteen week, the vascular mesenchyme of the condyle cartilage can be seen breaking down. Both joint cavities are formed by this stage.[5] Differentiation continues anteriorly to arrive at a point of full articulation at the 155-mm stage and element of the joint are fully formed at the 190-mm stage. According to Baume, full differentiation of all articular elements occurs at the fourth month of fetal life (Fig. 2.4).

JAYPEE BROTHERS

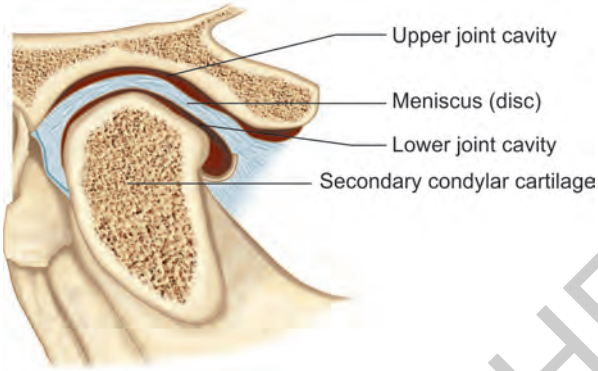

Fig. 2.3: Differentiation of the upper part of the joint cavity

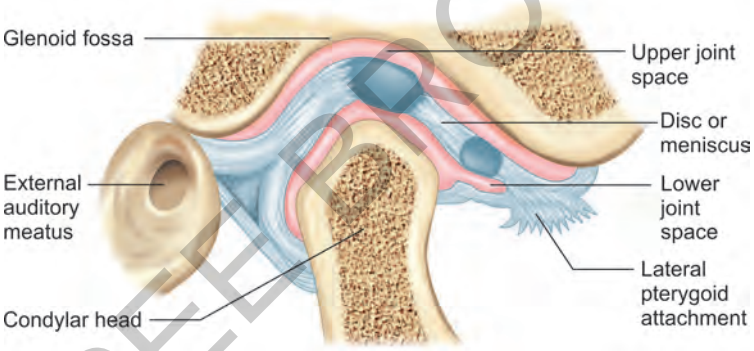

Fig. 2.4: Normal morphology of joint

Kitamura has described development of the innervation of the joint. The joint is innervated by the branches of the auriculotemporal nerve, masseter nerve, and posterior deep temporal nerve, which are the branches of the mandibular portion of the trigeminal nerve. From the fourth fetal month, nerve fibers may be observed in the articular capsule. They appear to reach the articular disc at about the fifth month. At the sixth month the widest distribution within the condyle and disc may be seen. Most of the nerve endings of the fetal temporomandibular joint are free nerve endings, with a few encapsulated, seen around the joint .The nerve fibers in the capsule also innervate the synovial membrane of the joint (Fig. 2.5).

JAYPEE BROTHERS

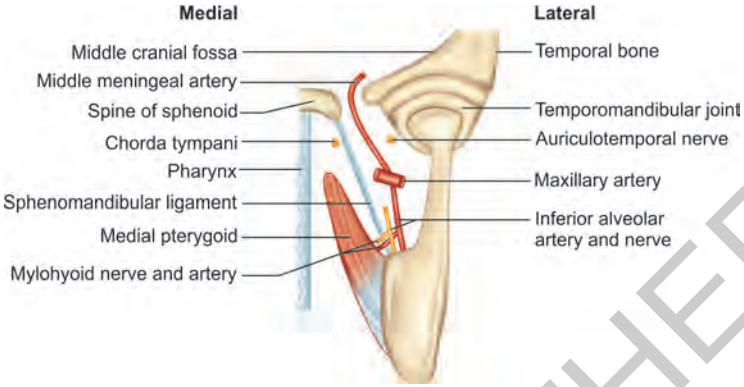

Fig. 2.5: Development of the innervation of the joint

THE TRANSFORMATION OF THE REPTILIAN JAW TO THE MAMMALIAN

The transformation of the reptilian jaw and TMJ to the mammalian one involved mainly the reduction in the number of jaw bones and the direct articulation of the tooth bearing bones to the cranium. It is closely associated with the evolution of the hearing apparatus.

The fishes had little auditory use for ears. In land vertebrates, like reptiles, the *hyomandibular cartilage* which suspended the upper jaw from the skull, had been transformed into a little bone that transmits the sound waves to the inner ear from the external, namely the *stapes*. The reptilian TMJ was formed between the quadrate bone in the upper and the articular bone in the lower jaw. It was a simple joint with only hinge like movements.

In mammals two additional auditory ossicles, the *incus* and *malleus* are added. These new ear bones are derived from the quadrate and the articular bones which intervene between the lower jaw and the skull in the reptiles. By this the dentary became the main teeth bearing bone or the mandible (Fig. 2.5). The mammalian TMJ is between the dentary and the squamosal bones in the cranium. This was the TMJ as we know it today (Figs 2.6A to D). Of the features that are useful in recognizing mammals are the following:

1. Constant warm body temperature (= homeothermic), with body heat produced by internal metabolism (= endothermic).
2. Bones with abundant areas for blood flow.
3. Single lower jaw bone containing a variety of differently shaped teeth (heterodont).
4. Mammary glands.
5. Most give live birth.

JAYPEE BROTHERS

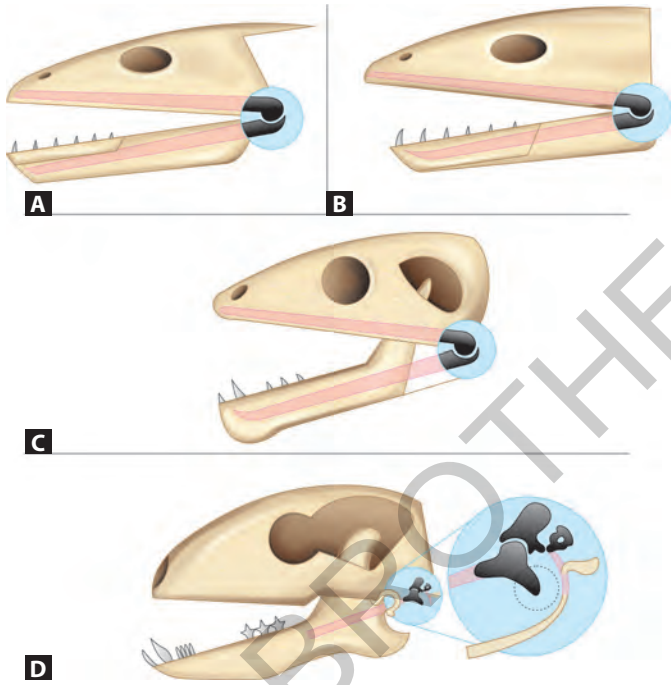

Figs 2.6A to D: The transformation of the reptilian jaw to the mammalian

6. Three inner ear bones.
7. A secondary bony palate, that bone allows you to breathe through your nose while you are chewing food (Fig. 2.7).

The dentary and the maxilla increase greatly in size and in the earlier adult mammals the dentary became the sole bone of the lower jaw and the premaxilla and the maxilla together form the entire subocular surface of the face. The transition from this stage that of man involves mainly the deepening and anteroposterior shortening of these elements.

During the progressive enlargement of the ascending ramus of the dentary in the mammal like reptiles this process finally became so far extended postero-dorsally that its lower corner came near to the squamosal bone of the temporal region. It was prevented from forming a contact with that element by a cushion, bursa or meniscus, derived from the temporal muscle in which it was embedded.

This joint is highly characteristic of mammals and not found in the ancestral lower reptiles and amphibians. As it was formed the old joint at the posterior end of the jaw, between the articular portion of Meckel's cartilage and the quadrate portion of the palatoquadrate, or primary upper

JAYPEE BROTHERS

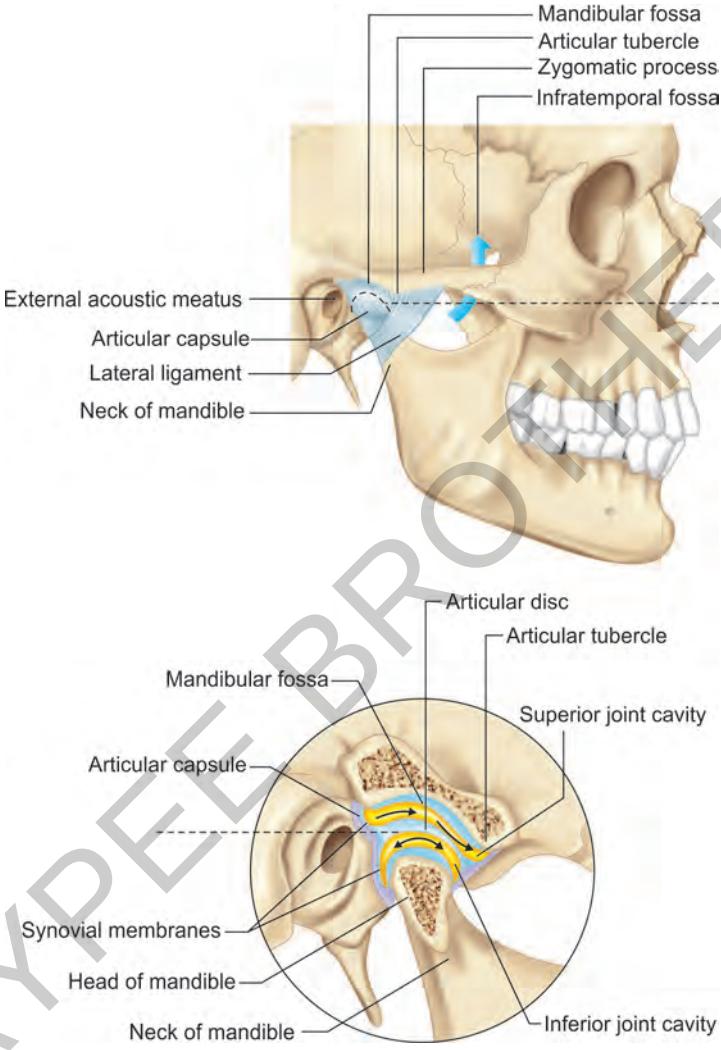

Fig. 2.7: Normal TMJ

jaw, became greatly reduced in size and was transformed into the malleus-incus joint of the auditory ossicles. This transformation made possible the diverse paths of the mandible and the consequent complexity of the occlusal relationships of the teeth seen in the various orders of mammals.

But the fundamental principle of the jaws remained the same. There is always at the bottom a pair of pincers, but at one extreme they may be shears

JAYPEE BROTHERS

with a strictly vertical movement and in the other direction they may become various kind of dental mills with obliquely transverse, rotary or fore and aft movements with the corresponding differences in the occlusal contacts.

Malocclusion arises from the lack of chewing stress with the modern processed diet. This disuse has reduced jaw growth and increased the incidence of occlusal variation. Lack of functional stimulation could explain occlusal changes that were observed: small jaws with normal-size teeth (not normal arches burdened with excessively large teeth), resulting in crowding plus maxillary narrowing.

In 1954, Begg reasoned that the relatively low incidence of malocclusion in Stone Age Man is due to the reduction by more than half an inch in the total length of each of his dental arches. This was caused by tooth attrition so that the smaller crowns (in mesiodistal diameter) could be more easily accommodated into the jaws. The theory has been widely cited since its publication. Begg also argued that retention of unworn occlusal-cusp was not a feature of non-modern societies. Since the cusps wear flat relatively early in life, it is argued that the function of cusps is to guide erupting teeth into proper position and occlusion.

What he is saying is this: The function of cusps is transitory: in their brief functional life, they establish mandibular and condylar position. The argument might continue like this: a flat plane occlusion allows protrusive and lateral movements without cuspal interferences and is therefore less susceptible to TMJ disturbances (especially with shallow condylar fossae). Combined with physiological mesial drift, humans would effectively achieve an increasing retromolar space as they age. The delayed eruption of the third molar seems to be an evolutionary adaptation to interproximal wear of the cheek teeth. It seems that the size of teeth was selected in anticipation of the wear and migration of the dental arcade to create sufficient room for the third molars.

The recent secular trend in increasing impactions does not seem to be a genetic change in humans. It is, instead, merely a response to a soft food diet. Without interproximal wear of the teeth, there simply is not enough room for third molar. Other factors at work with modern soft diets are dental arch width: narrower dental arches that result from disuse also contribute to shorter dental arches with less space available distal to second molars.

CHRONOLOGICAL DEVELOPMENT OF THE TMJ

Function influences form as development and growth of the TMJ proceeds. The TMJ is comprised of three major components: the mandibular condyle, the mandibular fossa, and the associated connective tissue (including the articular disk) (Fig. 2.8). The first evidence of development of the TMJ in humans is seen eight weeks after conception.

JAYPEE BROTHERS

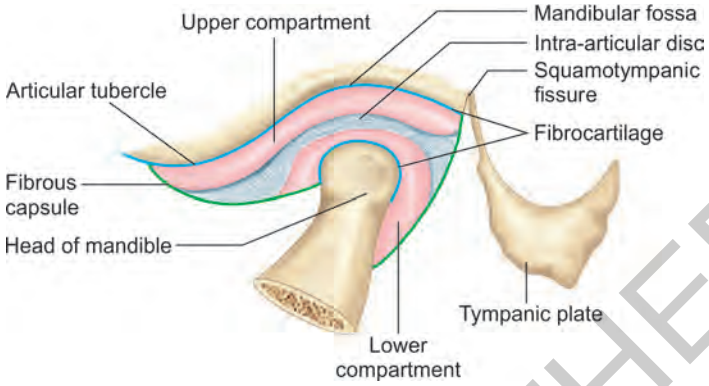

Fig. 2.8: Normal TMJ showing soft tissue component

Birth

1. The joint displays the structural components of the adult joint, but it lies parallel with the occlusal plane instead of several mm superior to it as in the adult.
2. The articular eminence is inferiorly positioned; the fossa is relatively flat and the joint functions as a pure hinge system with no translation.
3. Throughout the fetal life, the fibrous articular surfaces and interposing disc are vascularized and innervated. This will disappear as function induces compression of the disc between the condyle and temporal bone.

Childhood

With the occlusion of the primary dentition at age three, pressure is placed on the joint which results in the change to non-vascularity of the articular surfaces. Before age three, a fall or other trauma to the joint will often result in a hemarthrosis and possible fibrous ankylosis.

Development of the TMJ

During the first decade of life, the mandibular condyle becomes less vascularized and most of the major morphological changes are completed. During the second decade of life, there is continued but progressive slowing of growth. The shape of the mandibular condyle may change significantly during growth with approximately 5% of condyles undergoing radiographic changes in shape (Fig. 2.9).

Temporomandibular Joint

Definitions: Articulation is defined as a loose joining or connecting together so as to allow motion between the parts.

JAYPEE BROTHERS

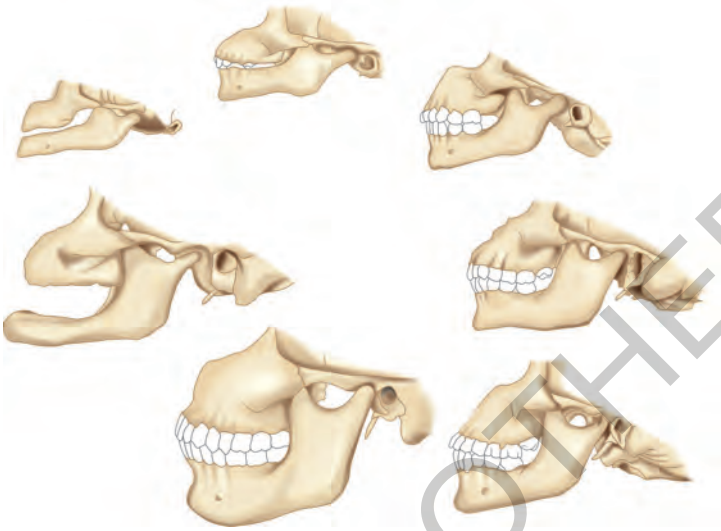

Fig. 2.9: Growth and development of TMJ

When the two objects are the bones of a skeleton, the articulation is called as joint.

Classification of Joint

Mankin and Radin divide joints into three categories

1. Class I—Synarthroses
   An immovable union of connective tissues
   For example, sutures of the cranium.
2. Class II—Amphiarthrosis
   Slight mobility
   For example, facet joints in spinal cord.
3. Class III—Diarthrosis
   Completely movable joint
   For example, shoulder, knees, hips.

Synarthrosis is further divided into

1. Synostosis—Bony union
   For example, sutures of the skull.
2. Gomphosis—Bony components adapted to each other
   Peg adopts to a hole
   For example, tooth in its alveolar socket.
3. Syndesmosis—Components connected by ligament
   For example, tibia and fibula.

JAYPEE BROTHERS

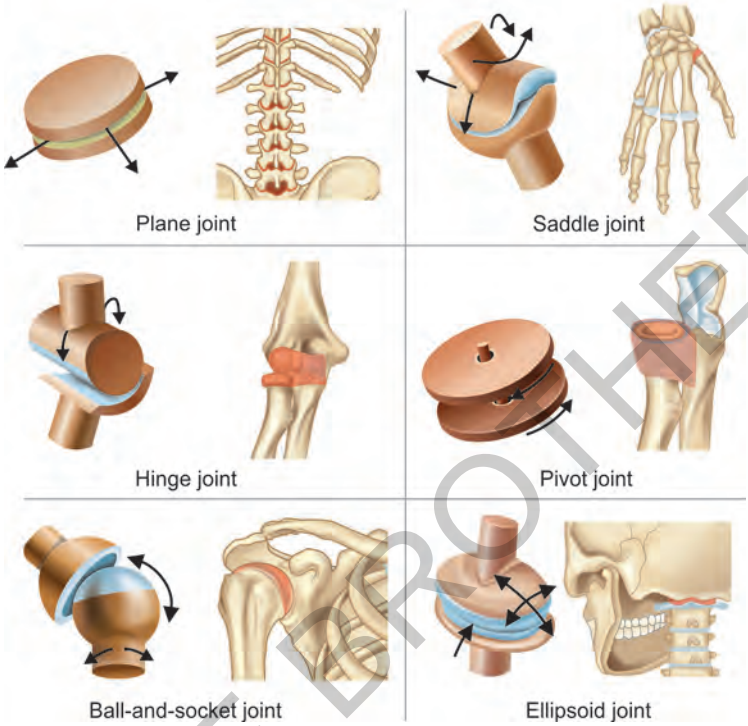

Fig. 2.10: Uniaxial joint

4. Symphysis—Components connected by cartilage in the form I of disc, plate or pad.
   For example, symphysis pubis.
5. Synchondrosis—Components connected by hyaline cartilage.
   For example, first sternocostal joint.

Classification of Diarthrodial Joint

- Based on nature of their movement
- Uniaxial, biaxial and triaxial.

Uniaxial Joints—Allow movement in one plane around a single axis

1. Hinge—Door hinge movement, e.g. interphalangeal joint
2. Pivot —One component shaped like a wing
   Second component shaped to articulate with wing shaped component.
   For example, median atlantoaxial joint.

Biaxial joints—Move in two planes around two axis
For example, carpometacarpal joint of thumb.

JAYPEE BROTHERS

Triaxial joints/Multiaxial joints

Bony components free to move in free planes

1. Plane joint—Has sliding action
   For example, temporomandibular joint
2. Balls socket joint
   For example, hip joint

Ball like convex surface fitting into a concave socket.

JAYPEE BROTHERS

for detailed information on dental books, visit our website **www.jaypeebrothers.com,** for detailed information on den

Manual of
Temporomandibular Joint

Salient Features

- Extensive compilation of literature amalgamated with the vast clinical experience of authors in the field of diagnosis and management of temporomandibular joint disorders over a period of 30 years
- Deals with all aspects of relevant disorders starting from the basic understanding of the anatomy, clinical examination along with conventional and advanced radiological procedures and various disorders and their management under one platform
- Contains lucid and self-explanatory content with many clinical and radiological photographs and diagrammatic representations
- Excellent for deep knowledge, which will help undergraduate and postgraduate dental and medical students of any specialty
- Includes all imaging techniques for temporomandibular region under single platform
- Explanation is in simple language
- Covers all the applied aspects of temporomandibular disorders
- Contains all the aspects of temporomandibular joint including applied aspect under single platform
- Helpful for students preparing for entrance examination.



Shivlal M Rawlani BDS MDS is an eminent clinician and teacher with more than two decades of teaching experience in dentistry. Presently, he is working as Associate Professor, Department of Oral Medicine and Radiology, Sharad Pawar Dental College and Hospital, Datta Meghe Institute of Medical Sciences (Deemed University), Wardha, Maharashtra, India. He worked as Associate Professor and Head, Department of Dentistry, Mahatma Gandhi Institute of Medical Sciences, Wardha. He is the author of *Textbook of Oral and Maxillofacial Imaging Techniques*. He is the co-author of *Textbook of General Anatomy* by Dr Shobha Rawlani. He has to his credit more than 37 national and international publications and research works. He has attended more than 45 workshops and conferences. He has numerous scientific paper presentations at various national and international conferences. He has worked with dedication in Late Shree Baba Amte Leprosy Foundation Center, Chandrapur, Maharashtra, India, for a period of 10 years. He had the privilege of attending an international workshop sponsored by World Health Organization (WHO) at Jaipur on rational use of drug in community. He had the privilege of attending a national conference organized by Health Ministry of India at New Delhi on tobacco cessation. He had the privilege of being invited twice as a Guest Speaker for national continuing medical education (CME) organized by Medical and Dental Colleges. He was also Keynote Speaker at National Zonal Conference at Chikhaldara, Amravati, Maharashtra. He had the privilege of working as Co-coordinator for Fluoride Mapping Program organized by Dental Council of India.



Sudhir S Rawlani BDS MDS is an eminent clinician and good academician. He is working as Assistant Professor, Department of Public Health Dentistry, Dada Saheb Kalmegh Dental College, Nagpur, Maharashtra, India. He is the author of *Textbook of Dental Anthropology*. He has to his credit 5 national and international publications. He has attended more than 10 workshops and national conferences. He won the Best Paper presentation award at National Zonal Conference held at Chikhaldara, Amravati, Maharashtra. He was an active organizing member of postgraduate convention held at Guntur, Andhra Pradesh, India.

Available at all medical bookstores
or buy online at www.jaypeebrothers.com

JAYPEE BROTHERS
Medical Publishers (P) Ltd.
www.jaypeebrothers.com

Join us on facebook.com/JaypeeMedicalPublishers

Shelving Recommendation
DENTISTRY

ISBN 978-93-85891-09-0

9 789385 891090