rics and gynecology books, visit our website www.jaypeebrothers.com, for detailed information on obstetrics and gynecology books

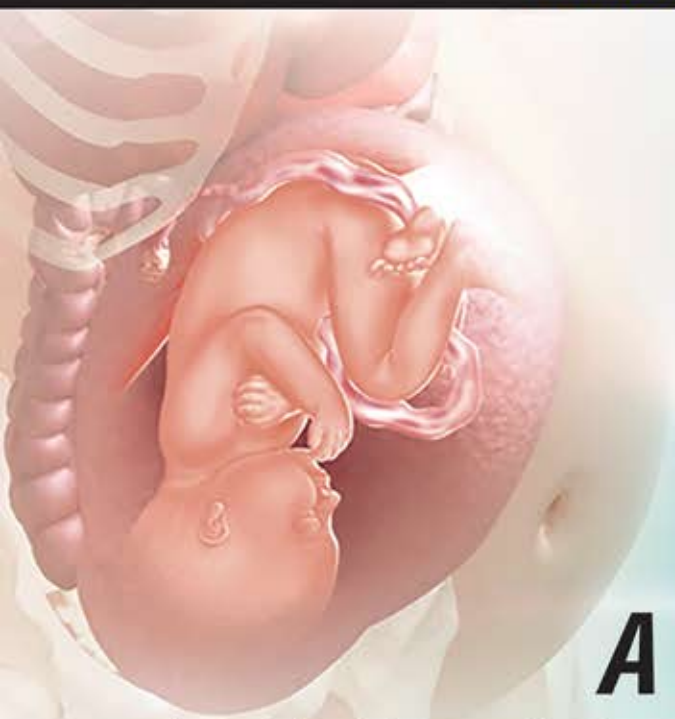

A Practical Guide to

Third Trimester of Pregnancy and Puerperium

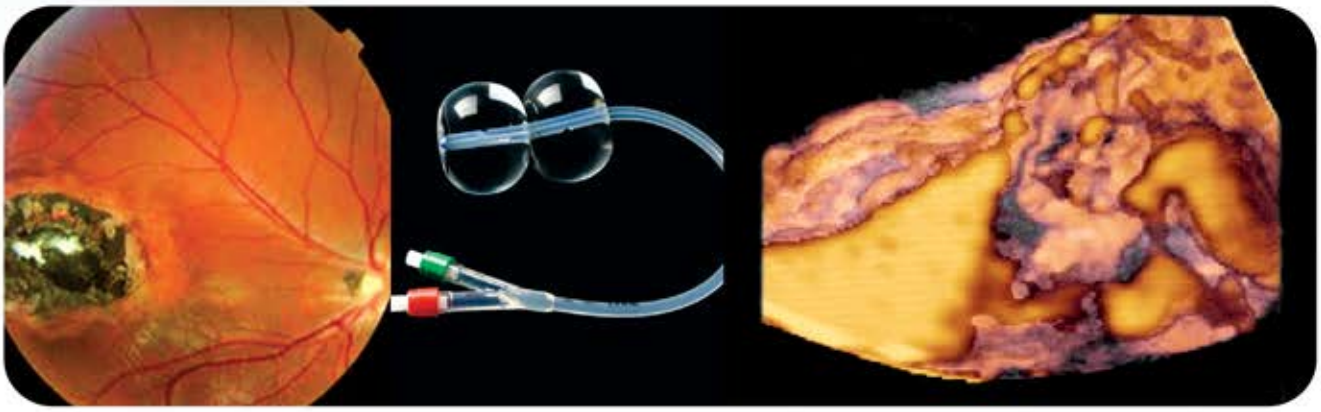

Editor
Alok Sharma

Foreword
Alka Kriplani

JAYPEE

Contents

Section 1: Anatomy and Physiology

1. **Obstetrics Risk Management** 3
   Savita R Singhal, Roopa Malik
2. **Introduction and Physiological Changes** 11
   Parneet Kaur, Atish Singla
3. **Fetal Skull and Maternal Pelvis** 22
   Yogita Dogra
4. **Fetus in Utero** 32
   Kiran Pandey

Section 2: Antepartum

5. **Age and Parity** 45
   Shakuntala Kumar, Pratik Tambe , Amit Tandon
6. **Antepartum Surveillance of Fetal Well-being** 51
   Meenakshi B Chauhan
7. **Imaging in Third Trimester** 62
   Neha Gupta
8. **Pregnancy after Assisted Reproductive Techniques Including Third Party Conception** 74
   Umesh N Jindal
9. **Intra-uterine Fetal Death** 79
   Alka Kuthe

Section 3: Intrapartum

10. **Drugs and Prostaglandins** 95
    Meeta Gupta, Nalneesh Sharma, Kanupriya Jindal
11. **Induction of Labor** 102
    Shailesh Kore, Rashmi Patil, Divya Kadam
12. **Anesthesia and Analgesia** 110
    Kartik Syal
13. **Normal Labor and Vaginal Delivery** 121
    Jyothika A Desai, Thejavathy GV

14. **Fluid Management in Labor** 131
Vandana R Bhuria

15. **Partograph** 139
Tanupriya Dogra

16. **Episiotomy** 145
Laxmi Shrikhande, Surekha Tayade, Rohini Rao

17. **Intrapartum Fetal Surveillance** 150
Surekha Tayade

18. **Abnormal Uterine Action Labor** 160
Jyoti Bindal

19. **Abnormal Labor** 166
Muralidhar V Pai

20. **Operative Vaginal Delivery** 172
Parag Biniwale, Manish Machave, Reeti Mehra

21. **Cesarean Delivery: Recent Advances** 180
Parul J Kotdawala, Girindra Chingtham, Priyangi Purohit

22. **Vaginal Delivery after Cesarean** 191
Kavita Mandrelle, Kanupriya Jain

Section 4: Postpartum

23. **Postpartum Hemorrhage** 199
Sadhana Gupta

24. **Birth Injuries** 209
Charu Mittal

25. **Inversion of Uterus** 218
Kapil Malhotra

26. **Postpartum Collapse** 225
Chanderdeep Sharma, Kewal A Mistry

27. **Massive Obstetric Hemorrhage and Disseminated Intravascular Coagulation** 235
Arti Luthra, Manishi Mittal, Daizy Pathak

28. **Normal Puerperium** 245
Susheela Rani, Charmila Ayyavoo

29. **Abnormal Puerperium and Its Management** 250
Rubina Sohail, Saima Iqbal

30. **Breast-feeding** 260
Nidhika Chhabra

31. **Contraception** 269
Shashwat K Jani, Anu Namgyal

Section 5: Neonate

32. Examination of Newborn **281**
Jiya Lal

33. Neonatal Resuscitation **292**
Ashwani K Sood, Naveen Bajaj

34. Diseases of Fetus and Newborn **301**
Ram K Kaushal

Section 6: Obstetrical Complications

35. Preterm Labor **325**
Parikshit D Tank

36. Premature Rupture of Membranes **334**
Kumud B Gupta, Neerja Jamwal

37. Post-term Pregnancy **343**
Manishi Mittal

38. Placental Adhesive Disorders and Umbilical Cord Abnormalities **351**
Sujata Misra, Saumya Nanda

39. Multiple Gestations **359**
Reena J Wani, Madhuri Mehendale

40. Malpositions **367**
Monica Chauhan

41. Breech and Other Malpresentations **378**
Smiti Nanda, Krishna Dahiya, Monika Dalal

42. Hypertensive Disorders in Third Trimester of Pregnancy and Puerperium **395**
Joshi Suyajna D

43. Disorders of Fetal Growth **416**
Pratap Kumar, Alok Sharma, Geetika G Syal

44. Disorders of Amniotic Fluid **425**
Poonam V Shivkumar, Manisha Rewatkar

45. Third Trimester Bleeding **438**
Uma Pandey, Stephen W Lindow

46. Isoimmunization **447**
Ajay S Dhawle

Section 7: Medical and Surgical Complications

47. Cardiovascular Diseases and Chronic Hypertention **457**
Suman Puri, Sandeep Puri, Kanupriya Jain, Arshdeep Singh, Gurleen Wander

48. Respiratory Diseases **468**
Geetha D Balsarkar, Alok Sharma

49. Gastrointestinal Disorders **478**
Ramaraju H Ediger

50. Liver Diseases **493**
Shashank Shekhar

51. Renal Diseases **501**
Reeti Mehra , Sanjay D Cruz

52. Endocrinal Disorders: Diabetes Mellitus **510**
Reeti Mehra, Yashdeep Gupta

53. Endocrinal Disorders: Thyroid and Parathyroid **524**
Saswati S Choudhury

54. Endocrinal Disorders: Pituitary and Adrenals **431**
Suvarna S Khadilkar, Akanksha Sood

55. Hematological Complications **537**
Veerendrakumar CM, Joshi Suyajna D

56. Immunological Complications **546**
K Aparna Sharma, Alka Kriplani

57. Vascular Complications **555**
Navneet Takkar

58. Thromboembolic Disorders **564**
Pratik Tambe, Pooja K Bandekar

59. Neurological Complications in Third Trimester of Pregnancy **574**
Hema J Shobhane

60. Psychiatric Disorders **582**
Sangeeta T Tajpuriya

61. Dermatological Complications **587**
Mudita Gupta

62. Sexually Transmitted Diseases **605**
Aswath Kumar, Anuradha Sood, Jay Mehta

63. Infectious Complications **612**
Nishi Jaswal

64. Spine and Joint Disorders **627**
Kiran Guleria, Esha Sharma

65. Trauma and Surgical Complications **640**
Bali R Sharma, Keshav Benipal

66. Gynecological Complications **648**
Anita Pal

67. Malignant or Neoplastic Diseases **659**
Niranjan N Chavan, Shubhrita Gupta

68. Oro-dental Care **668**
Nisha Thakur, Narotam K Ghezta, Pratibha Sharma

69. Obesity **675**
Geeta Doppa, Ravikanth O Gowder

70. Human Immunodeficiency Virus **682**
Rashmi Bagga, Parul Arora

Section 8: Miscellaneous

71. Critical Care **693**
Sharda Patra, Indira Prasad

72. Anaphylaxis **702**
Rashmi Bagga, Aashima Arora

73. Blood Component Therapy **706**
Jai B Sharma, Manisha Yadav

74. Sexual Activity Pre- and Postdelivery **712**
Rohini Rao, Divya Yadav

75. Physiotherapy and Yoga in Pregnancy **716**
Geetika G Syal, Alok Sharma, Padam Sharma

76. Domestic Violence **726**
Kawita S Bapat, Pratik Tambe

77. Infection Prevention in Obstetrics **731**
Anuradha Sood, Madhvi Kaistha, Aradhna Sharma, Rajneet Kaur

78. Demography and Vital Statistics **737**
Anjali Mahajan, Alka Kuthe

79. Legal and Ethical Issues **749**
Sangeet K Dhillon, Alka Kuthe

Index ***757***

CHAPTER 3

Fetal Skull and Maternal Pelvis

Yogita Dogra

INTRODUCTION

An understanding of the anatomy of fetal head and maternal pelvis is essential for obstetrical practice. There may be marked variations in anatomical structures in individual women. The maternal passages comprise the bony canal with soft structures which line it and close in its outlet. Since the head presents in such a preponderating proportion of cases, it must be studied in detail and in relation to parturient canal through which it has to pass. As the head is the largest part of fetus, it is more important to know whether greatest diameter of head passes through different planes of the pelvis.

FETAL SKULL

It is formed of vault, face, and base. The vault is composed of soft bones separated by sutures and fontanels. Figures 1 and 2 identify certain regions and landmarks in the fetal skull, which have particular importance for obstetric care because they may form the so-called presenting part of the fetus. The fetal skull is divided into:

- Vertex: a quadrangular area bounded anteriorly by bregma and coronal sutures, behind by the lambda and lambdoid sutures, and laterally by lines passing through parietal eminences
- Brow: an area bounded on one side by anterior fontanel and coronal sutures and on the other side by the root of the nose and supraorbital ridges of either side
- Face: an area bounded on one side by root of the nose and supraorbital ridges and on the other by the junction of the floor of the mouth with neck
- Sinciput is the area lying in front of the anterior fontanel and corresponds to the area of brow
- Occiput is the area between the base of the skull and the posterior fontanel.

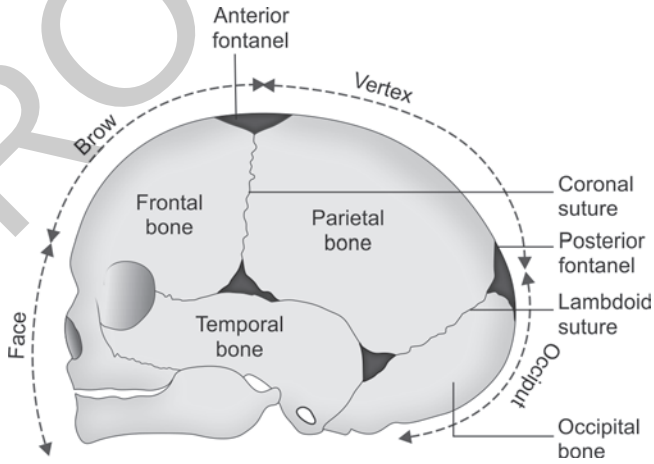

FIG. 1: Bones of the fetal skull—side view facing left.

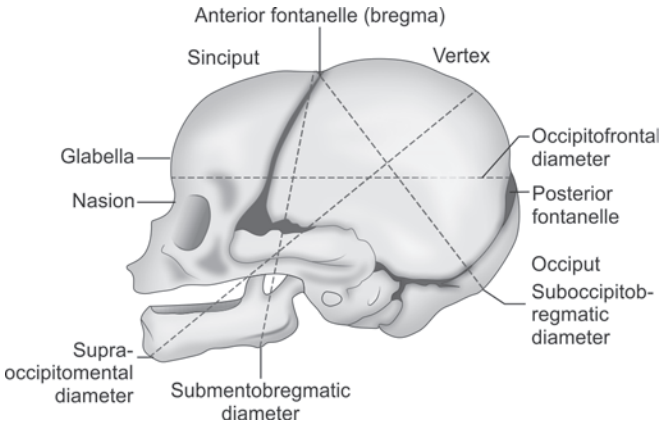

FIG. 2: Lateral view of the fetal skull showing prominent landmarks and anteroposterior diameters.

JAYPEE BROTHERS

Sutures of Obstetrical Significance (Fig. 3)

Sutures of obstetrical significance include:

- Sagittal suture lies between two parietal bones
- Coronal sutures run between parietal and frontal bones on either side
- Frontal suture lies between two frontal bones
- Lambdoid sutures separate occipital bone and two parietal bones.

Clinical Importance

- Permits gliding movement of one bone over the other during molding of the head while head passes through the pelvis during labor
- Position of fontanel and sagittal suture can identify attitude and position of vertex
- In deep transverse arrest, the sagittal suture lies transversely at the level of the ischial spines
- Digital palpation of sagittal suture gives an idea of degree of internal rotation of head and degree of molding of head
- In hydrocephalus, suture separation results in finding of islands of bone in a sea of membranes.

Fontanels

A fontanel is a membrane-filled space created by the joining of two or more sutures. Out of six, only two are of obstetric significance (Fig. 3).

Anterior Fontanel (Bregma)

Diamond-shaped area of unossified membrane formed by junction of four sutures. The anteroposterior (AP) and transverse diameters measure 3 cm × 2 cm each.

- Anteriorly: frontal suture
- Posteriorly: sagittal suture
- Laterally, on both side: coronal suture.

Anterior fontanel ossifies by 18 months after birth.

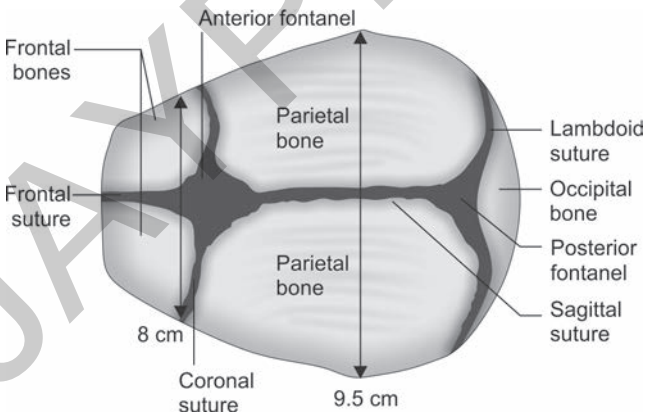

FIG. 3: Regions and landmarks in the fetal skull facing to the left. Notice the average diameters.

Clinical importance

- Degree of flexion can be assessed. On vaginal examination, if it is felt easily, it indicates head is deflexed as in occipitoposterior position
- It helps in molding of head
- Internal rotation of head can be assessed
- Intracranial pressure (ICP) can be roughly assessed after birth. Depression in dehydration and bulging in raised ICP
- Collection of blood and blood transfusion can be performed via superior longitudinal sinus
- Cerebrospinal fluid can be collected from its lateral angles.

Posterior Fontanel (Lambda)

It is Y-shaped triangular depressed area at the junction of three sutures. It measures about 1.2 cm × 1.2 cm.

- Anteriorly: sagittal suture
- Posteriorly: two lambdoid sutures at both sides.

It ossifies at term.

Clinical importance

- From its relation to the maternal pelvis, position of vertex is determined
- Internal rotation can be assessed
- Degree of flexion can be assessed from its position. On vaginal examination, if it is felt easily and anterior fontanel is not felt, this indicates good flexion of the fetal head.

Diameters of Skull

The engaging diameter of fetal skull depends on the degree of flexion of the presenting part. The AP diameters which may be engaged are discussed below (Fig. 2).

Vertex Presentation

- Suboccipitobregmatic: it extends from the nape of the neck to the center of anterior fontanel, measures 9.5 cm:
  - Attitude: complete flexion
  - Clinical importance: the smallest diameter
- Suboccipitofrontal: it extends from the nape of the neck to root of nose, measures 10 cm:
  - Attitude: incomplete flexion
- Occipitofrontal: it extends from the occipital eminence to the root of the nose (glabella), measures 11.5 cm:
  - Attitude: marked deflexion
  - Clinical importance: this engaging diameter may give rise to prolonged labor.

JAYPEE BROTHERS

Brow Presentation

- Mentovertical: it extends from the midpoint of the chin to the highest point on the sagittal suture, measures 14 cm:
  - Attitude: partial extension
  - Clinical importance: baby has to be delivered by cesarean section.

Face Presentation

- Submentovertical: it extends from the junction of the floor of the mouth and neck to the highest point on the sagittal suture, measures 11.5 cm:
  - Attitude: incomplete extension
  - Clinical importance: baby has to be delivered by cesarean section
- Submentobregmatic: it extends from the junction of the floor of mouth and neck to the center of bregma, measures 9.5 cm:
  - Attitude: complete extension
  - Clinical importance: baby has to be delivered by cesarean section

The transverse diameters are (Fig. 3):

- Biparietal diameter: it extends between two parietal eminences, measures 9.5 cm
- Clinical importance: irrespective of position of head, this diameter always engages
- Bitemporal diameter: distance between the anteroinferior ends of the coronal suture, measures 8 cm
- Bimastoid: between tips of mastoid processes, measures 7.5 cm
- Significance: incompressible diameter, it cannot be reduced even by destructive operations
- Supersubparietal: from point placed below one parietal eminence to a point placed above other parietal eminence of opposite side, measures 8.5 cm.

Circumferences of Skull

Circumferences of skull differ according to the attitude of the head (Table 1).

Molding

It is due to compression which the head undergoes during its passage through the resistant birth canal. There is diminution of those diameters most compressed and compensatory elongation of those least compressed. The types of molding and its site in various presentations are shown in figure 4. It is assessed during vaginal examination at two sites—parietal-parietal and parietal-occipital sites. During normal delivery, an alteration of 0.5–1 cm in skull diameter commonly occurs without brain damage. It disappears within few hours after birth. It is a protective mechanism and prevents fetal brain from compression as long as it is not excessive or too rapid.

The degree and direction of molding are determined by a number of factors:

- Size, shape, elasticity, and attitude of the fetal head
- Size and shape of the maternal pelvis
- Presentation and position of the head
- Strength of uterine contractions and duration of labor
- Rate of cervical dilatation and position of the cervix.

TABLE 1: Circumferences of skull

Attitude of the head	Plane of engagement	Circumference
Complete flexion	• Biparietal: suboccipitobregmatic • Shape: almost round	27.5 cm
Deflexed	• Biparietal: occipitofrontal • Shape: oval	34 cm
Incomplete extension	• Biparietal: mentovertical • Shape: bigger oval	37.5 cm
Complete extension	• Biparietal: submentobregmatic • Shape: almost round	27.5 cm

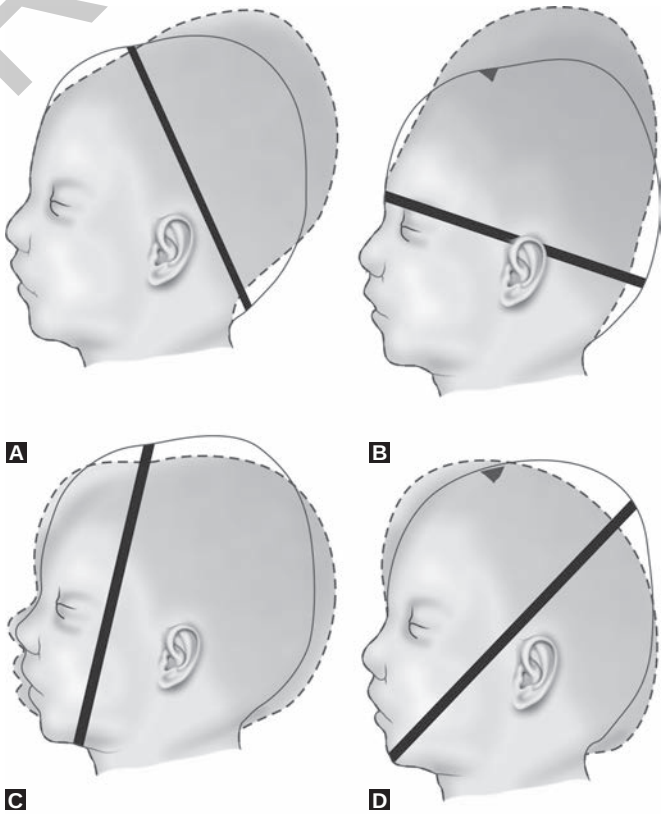

FIGS 4: Types of molding in cephalic presentation shown by dotted line. **A,** head well flexed; **B,** head deflexed (sugar loaf head); **C,** face presentation; and **D,** brow presentation.

JAYPEE BROTHERS

Grades of Molding

- Grade 0: the suture lines are separate
- Grade 1: the suture lines meet
- Grade 2: if the sutures overlap but can be reduced with gentle digital pressure
- Grade 3: when the sutures overlap and are irreducible with digital pressure, it is usually pathological.

Molding occurs relatively easily in the soft head of the premature fetus, whereas the hard inelastic fetal head characteristic of prolonged pregnancy resists alteration in shape.

Clinical importance

- Slight molding is inevitable and beneficial. It enables the head to pass more easily through the birth canal
- Shape of the molding can be used to denote the position of the head occupied in the pelvis
- Extreme molding as in obstructed labor may produce intracranial disturbance in the form of tearing of tentorium cerebelli or subdural hemorrhage.

Caput Succedaneum (Fig. 5)

It is localized area of edema on fetal scalp in vertex presentation due to pressure effect of dilating cervical ring and vaginal introitus. It is usually formed after rupture of membranes and during the first stage of labor.

Characteristics

- It is physiological, present at birth, and disappears within 24–36 h
- It is soft, diffuse, and pits on pressure
- No underlying skull bone fracture
- Not limited by sutures (compared from cephalohematoma).

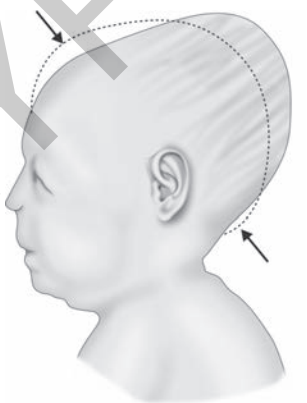

FIG. 5: Formation of caput succedaneum.

Obstetric Importance

- It signifies static position of the head for a long period of time
- Location of caput gives an idea about the position of head occupied in the pelvis and the degree of flexion achieved. In left position, the caput is placed on the right parietal bone and in right position, on left parietal bone
- With increasing flexion, the caput is placed more posteriorly
- In prolonged labor, a large caput suggests disproportion
- Secondary caput succedaneum is formed upon the part of scalp which presents at the vulva and is on the occipital bone near the posterior fontanel.

MATERNAL PELVIS

The bony pelvis is made up of two innominate bones (fusion of ilium, ischium, and pubis)—sacrum and coccyx. The innominate bones are joined to each other at symphysis pubis and to the sacrum by two sacroiliac joints (Fig. 6).

The pelvis is anatomically divided into a false pelvis and a true pelvis.

- False pelvis: it is also known as greater pelvis or pelvis major. Formed by iliac portions of innominate bones and limited above by iliac crests
  - Boundaries (Fig. 7):
    - Posteriorly: lumbar vertebrae
    - Laterally: iliac fossa
    - Anteriorly: anterior abdominal wall
  - Significance: support enlarged uterus during pregnancy.
- True pelvis: it is also known as lesser pelvis or pelvis minor
  - Anteriorly: shallow, formed by symphysis pubis (4 cm)
  - Posteriorly: deep, formed by sacrum and coccyx (11.5 cm).

It is composed of inlet (brim), cavity, and outlet.

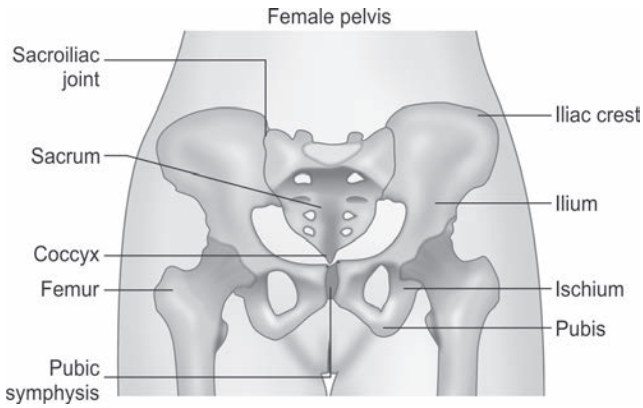

FIG. 6: Bones and joints forming the bony pelvis.

JAYPEE BROTHERS

Pelvic Inlet

Pelvic inlet divides the pelvic cavity into false and true pelvis.

Boundaries: from posterior to anterior on each side (Fig. 8):

- Sacral promontory
- Ala of the sacrum
- Sacroiliac joints
- Iliopectineal lines
- Iliopubic eminencies
- Upper border of the superior pubic rami
- Pubic tubercles
- Pubic crests and upper border of symphysis pubis.

Plane: it is an imaginary flat surface, also called superior strait (Figs 9 and 10).

Inclination: in erect posture, pelvis is tilted forwards. The plane of inlet makes an angle of 55° with horizontal and is called angle of inclination (Fig. 9). Radiographically, it is measured as angle between plane of inlet and body of L5 (135°).

- High inclination: when angle of inclination is increased due to sacralization of L5
  - Significance:
    - Delay in engagement because uterine axis fails to coincide with that of inlet
    - Favors occipitoposterior position
    - Difficulty in descent of head because long birth canal and flat sacrum interferes with internal rotation
- Low inclination: the angle of inclination is lessened due to lumbarization of S1
  - Facilitates early engagement.

Sacral angle: it is the angle between true conjugate and first two pieces of sacrum. Normally, it is greater than 90°. If less, sugg ests funneling of pelvis.

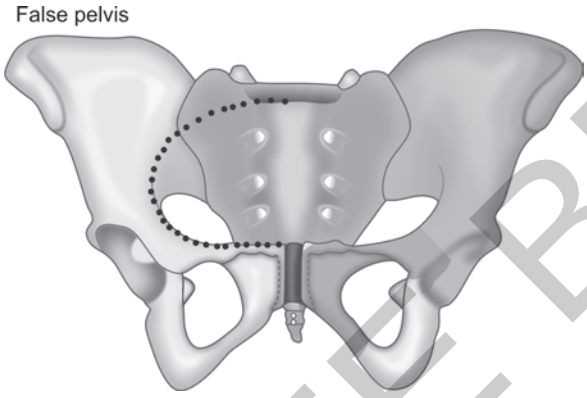

FIG. 7: Pelvic brim dividing the true and false pelvis.

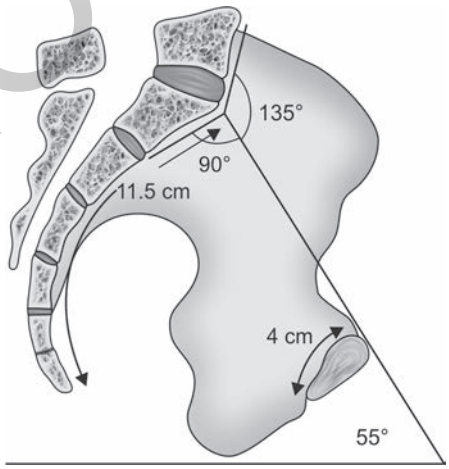

FIG. 9: The plane of inlet, inclination of pelvis and sacral angle.

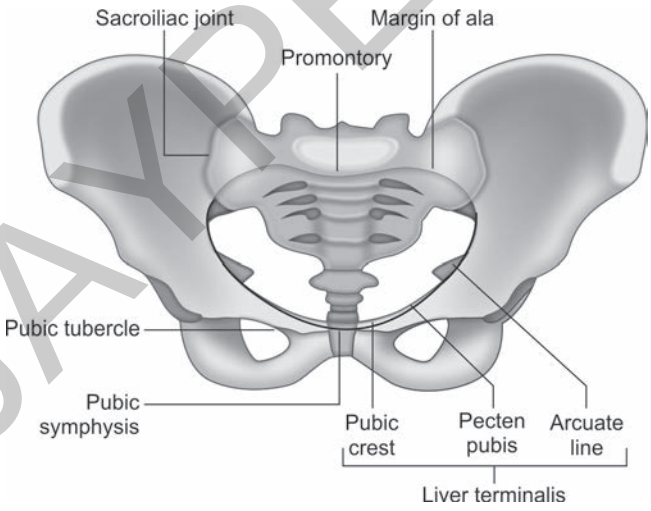

FIG. 8: Pelvic inlet with its boundaries.

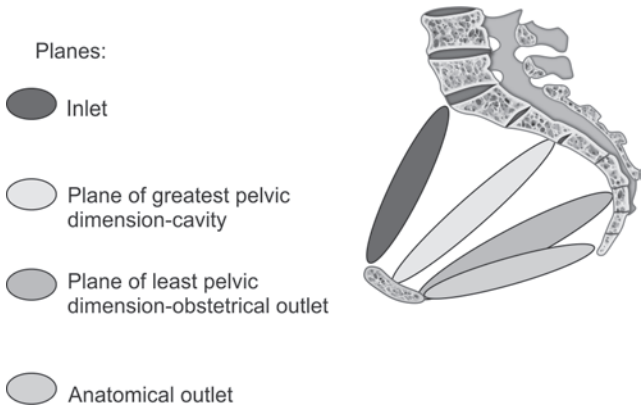

FIG. 10: Planes of pelvis.

JAYPEE BROTHERS

Axis: it is a midperpendicular line drawn to plane of inlet.

Direction: downwards and backwards; it passes from the umbilicus to the tip of the coccyx.

Importance: uterine axis should coincide so that force of uterine contractions spread in right direction.

Diameters of Pelvic Inlet

Anteroposterior diameters (Figs 11 and 12)

- True conjugate (anatomical conjugate, conjugate vera): Distance between midpoint of sacral promontory to the inner margin of upper border of pubic symphysis is 11 cm. Its direct measurement can only be made by X-ray pelvimetry

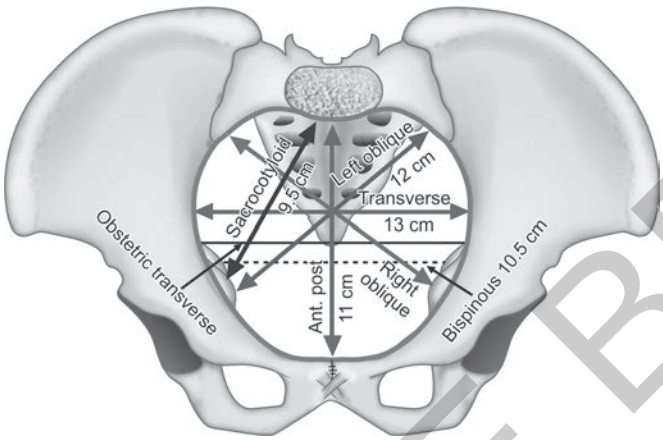

Ant. post, anteroposterior.

FIG. 11: Diameters of the pelvic inlet.

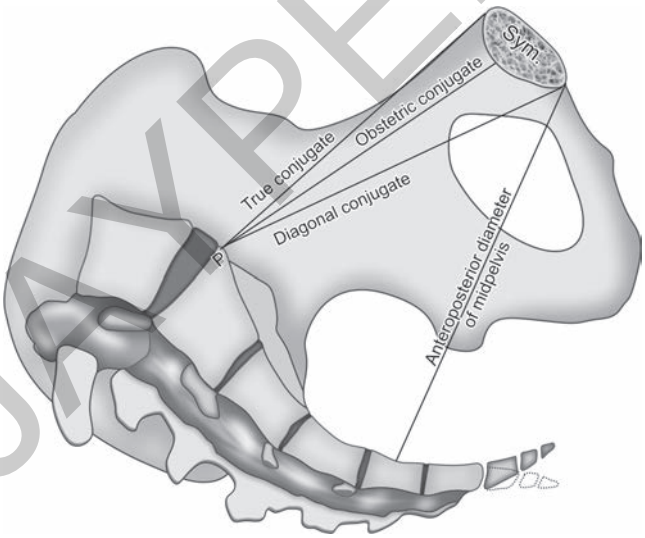

FIG. 12: Anteroposterior diameters of pelvic inlet and midpelvis.

- Obstetric conjugate: distance between midpoint of sacral promontory to prominent bony projection in midline on inner surface of symphysis pubis is 10 cm. It cannot be measured clinically but is calculated by deducing 1.5 cm from diagonal conjugate
- Diagonal conjugate: distance between midpoint of sacral promontory to lower border of symphysis pubis using the tip of the second finger and the point where the index finger meets the pubis is 12 cm (Fig. 13).

Transverse diameter

Distance between the two farthest points on pelvic brim over iliopectineal lines is 13 cm. It lies 4 cm anterior to the promontory and 7 cm behind the symphysis. It is the largest diameter in the pelvis. The head enters the brim through the "available or obstetric transverse" diameter which bisects the AP diameter in the center.

Oblique diameter

Distance between one sacroiliac joint to opposite iliopubic eminence is 12 cm. These are right and left, named according to the sacroiliac joint from which they start.

Sacrocotyloid

Distance between midpoint of sacral promontory to iliopubic eminence is 9.5 cm. It is occupied by the biparietal diameter in a flat pelvis.

Posterior sagittal diameter

It extends from the point of intersection of obstetric conjugate and the transverse diameter to the middle of the sacral promontory (4 cm).

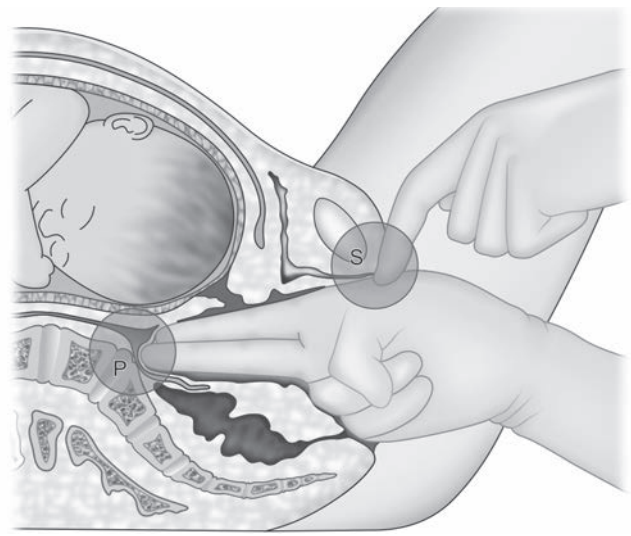

FIG. 13: Vaginal examination to determine the diagonal conjugate.

JAYPEE BROTHERS

Pelvic Cavity

Pelvic cavity is the most roomy zone with almost round shape. It forms a curved canal with a shallow anterior wall measuring 4 cm, deep lateral wall 7.5 cm, and a deep posterior wall measuring 11.5 cm (Fig. 9). It is bounded above by inlet and below by plane of least pelvic dimension.

Plane of Greatest Pelvic Dimension (Fig. 10)

Plane of greatest pelvic dimension extends from midpoint of posterior surface of symphysis pubis to junction of second and third sacral vertebrae.

- Axis: downward direction
- Diameters:
  - Anteroposterior diameter: it measures from the midpoint on posterior surface of symphysis pubis to junction of S2 and S3 (12 cm)
  - Transverse diameter: no precise measurement, as points lie over soft tissues covering sacrosciatic notches and obturator foramen (12 cm).

Pelvic Outlet

Obstetric Outlet

It is anteroposteriorly oval (Fig. 14).

Boundaries

- Above: plane of least pelvic dimension
- Below: anatomical outlet
- Anteriorly: deficient at pubic arch
- Lateral walls: ischial bones
- Posterior wall: coccyx.

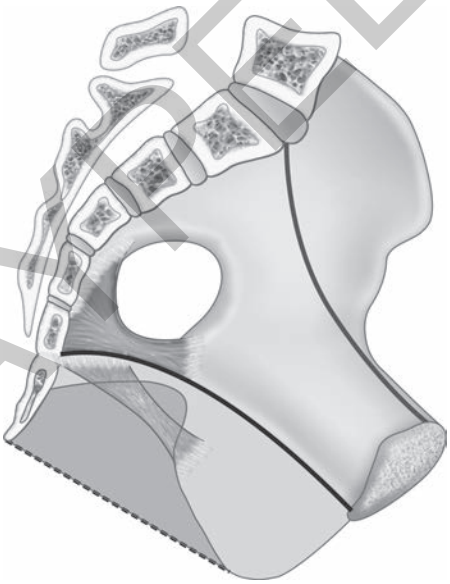

FIG. 14: The boundaries of obstetrical outlet of the pelvis.

Plane

Known as plane of least pelvic dimensions (Fig. 10), it extends from lower border of symphysis pubis to tip of ischial spines and posteriorly to meet the tip of S5. It is the narrowest plane in the pelvis.

At the level of ischial spines:

- The plane of obstetric outlet (plane of the least pelvic dimensions) is at this level
- The levator ani muscles are situated at this level and its ischiococcygeus part is attached to the ischial spines
- The obstetric axis of the pelvis changes its direction
- The head is considered engaged when the vault is felt vaginally at or below this level
- Internal rotation of the head occurs when the occiput is at this level
- Pudendal nerve block is carried out at this level
- The external os of the cervix is located normally
- The vaginal vault is located nearly
- The ring pessary should be applied above this level for treatment of prolapse.

Diameters

- Anteroposterior: it extends from inferior border of symphysis pubis to tip of sacrum (11 cm)
- Transverse diameter (bispinous): distance between tip of two ischial spines (10.5 cm)
- Posterior sagittal: distance between tip of sacrum and midpoint of bispinous diameter (5 cm).

Axis

Direction is almost vertical.

Anatomical Outlet (Bony Outlet)

Anatomical outlet (bony outlet) is diamond shaped.

Boundaries (Fig. 15)

- Anteriorly: lower border of symphysis pubis
- Laterally: ischiopubic rami, ischial tuberosity, sacrotuberous ligament
- Posteriorly: tip of coccyx.

Axis

Downwards and forwards.

Diameters (Fig. 15)

- Anteroposterior: extends from lower border of symphysis pubis to tip of coccyx (13 cm)

JAYPEE BROTHERS

- Transverse diameter (intertuberous diameter): measures between inner borders of ischial tuberosities (11 cm)
- Posterior sagittal: AP distance between sacrococcygeal joint and midpoint of transverse diameter of outlet.

Subpubic angle

- Formed by approximation of two descending pubic rami
- 85° in normal female pelvis
- If angle is less, transverse diameter of outlet will also be less.

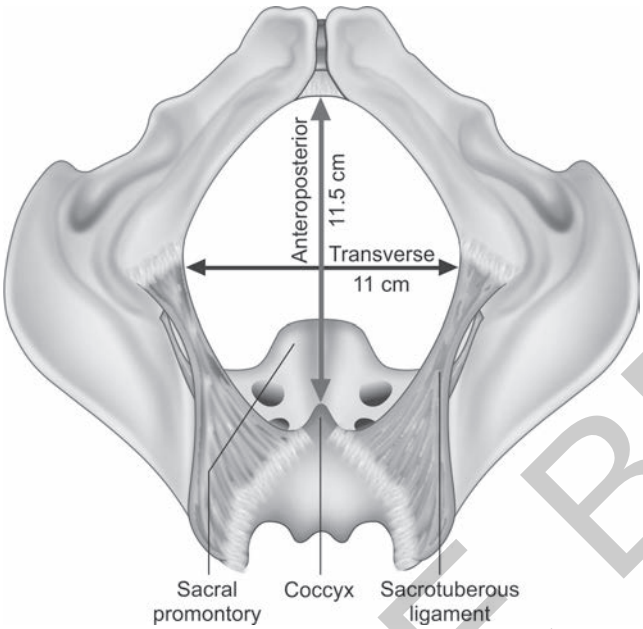

FIG. 15: The boundary of anatomical outlet with its diameters.

Pubic arch

It measures 6 cm in between pubic rami at level of 2 cm below the apex of subpubic arch. Clinically, it is assessed by placing three fingers side by side.

Midpelvis

Segment of the pelvis bounded above by the plane of greatest pelvic dimensions and below by a plane known as midpelvic plane.

Plane (Fig. 16)

Extends from lower margin of symphysis pubis through ischial spines to meet either junction of S4 and S5 or tip of sacrum.

Diameters

- Transverse or bispinous diameter (10.5 cm)
- Anteroposterior (Fig. 13): extends from lower border of symphysis pubis to the point on sacrum at which midpelvic plane meets (11.5 cm)
- Posterior sagittal: extends from midpoint of bispinous diameter to point on sacrum at which midpelvic plane meets (4.5 cm).

Pelvic Axis (Fig. 17)

Anatomical

Also called curve of Carus, it is formed by joining the axes of inlet, cavity, and outlet. It is C-shaped with the concavity directed forwards.

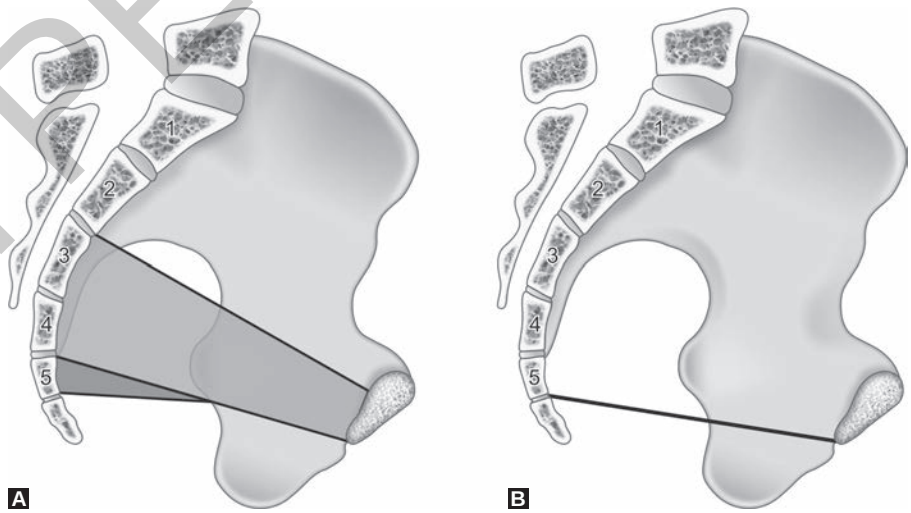

FIG. 16: Midpelvic plane.

JAYPEE BROTHERS

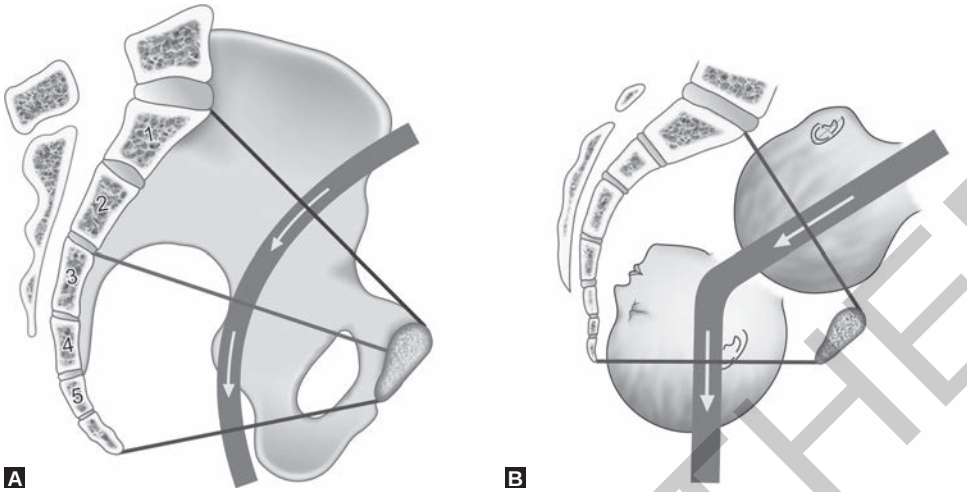

FIGS 17: Pelvic axix. **A,** Curve of Carus; **B,** the actual axis.

Obstetrical

It is through this axis that the fetus negotiates the pelvis.

Direction: downwards and backwards up to level of ischial spines and then abruptly forwards.

Waste Space of Morris

Normally, the subpubic angle is well rounded and if a round disk of diameter 9.5 cm (approximating fetal head) is placed under the subpubic arch, the distance between pubic symphysis and the edge of the disk should not be more than 1 cm. This measurement is the waste space of Morris.

Significance: when it is more than 1 cm, the available AP diameter of the outlet is reduced.

Pelvic Joints

- Symphysis pubis: secondary fibrocartilaginous joint; it has no capsule and no synovial cavity
- Sacroiliac articulation: synovial joint; it has got a capsule and a synovial cavity
- Sacrococcygeal joint: synovial hinge joint.

Physiological Changes in Pelvis in Pregnancy and Labor

During pregnancy, there is remarkable relaxation of pelvic joints. The relaxation of symphysis pubis commences in the first half of pregnancy and increases during the last 3 months.[1] There is increase in width of symphysis pubis, more in multiparas. The upward gliding movement of sacroiliac joint also contributes to the mobility of pelvis at term. AP diameter of the outlet may increase by 1.5–2 cm in lithotomy position. Increase in AP diameter of the inlet during labor is facilitated by rotatory movements of the sacroiliac joints. These changes have been attributed to the success of modified squatting position to hasten second stage of labor.[2] The squatting position may increase the interspinous diameter and pelvic outlet diameters.[3,4]

Muscular Support

The pelvic diaphragm provides considerable support to the pelvic viscera. It is comprised of levator ani (consists of pubococcygeus, puborectalis, and iliococcygeus muscles) and the coccygeus muscle. Vaginal delivery itself is a significant risk factor for damage to the levator ani muscle or to its innervation.[5,6] The pubococcygeus, preferably termed pubovisceral muscle is more commonly damaged.[7,8] Sufficient evidence exists to support that these injuries may predispose to greater risk of pelvic organ prolapse or urinary incontinence.[9-11]

CONCLUSION

During labor, fetus assumes positions and attitudes that are determined in part by the configuration of mother's pelvis. The outcome of labor depends more on the actual pelvic diameters than the shape and type of pelvis. The size, presentation and position of fetus are also important factors in the conduct of labor. Several pelvic diameters can be assessed clinically including diagonal conjugate, prominence of ischial spines, convergence of pelvic side walls, angle of subpubic arch, and sacral curvature. Thus, clinical estimation of adequacy of pelvis can alert the clinician to the possible risk of pelvic dystocia.

JAYPEE BROTHERS

REFERENCES

1. Borell U, Fernstrom I. The movements at the sacro-iliac joints and their importance to changes in pelvic dimensions during parturition. Acta Obstet Gynecol Scand. 1957;36(1):42-57.
2. Gardosi J, Hutson N, B-Lynch C. Randomised controlled trial of squatting in the second stage of labour. Lancet. 1989;2(8654):74-7.
3. Russell JG. Moulding of the pelvic outlet. J Obstet Gynaecol Br Commonw. 1969;76(9):817-20.
4. Russell JG. The rationale of primitive delivery positions. Br J Obstet Gynaecol. 1982;89(9):712-5.
5. DeLancey JO, Kearney R, Chou Q, Speights S, Binno S. The appearance of levator ani muscle abnormalities in magnetic resonance images after vaginal delivery. Obstet Gynecol. 2003;101(1):46-53.
6. Weidner AC, Jamison MG, Branham V, South MM, Borawski KM, Romero AA. Neuropathic injury to the levator ani occurs in 1 in 4 primiparous women. Am J Obstet Gynecol. 2006;195(6):1851-6.
7. Lien KC, Mooney B, DeLancey JO, Ashton-Miller JA. Levator ani muscle stretch induced by simulated vaginal birth. Obstet Gynecol. 2004;103(1):31-40.
8. Margulies RU, Huebner M, DeLancey JO. Origin and insertion points involved in levator ani muscle defects. Am J Obstet Gynecol. 2007;196(3):251.el-5.
9. DeLancey JO, Miller JM, Kearney R, Howard D, Reddy P, Umek W, et al. Vaginal birth and de novo stress incontinence: relative contributions of urethral dysfunction and mobility. Obstet Gynecol. 2007;110(2 Pt 1):354-62.
10. DeLancey JO, Morgan DM, Fenner DE, Kearney R, Guire K, Miller JM, et al. Comparison of levator ani muscle defects and function in women with and without pelvic organ prolapsed. Obstet Gynecol. 2007;109(2 Pt 1):295-302.
11. Rortveit G, Daltveit AK, Hannestad YS, Hunskaar S. Vaginal delivery parameters and urinary incontinence: the Norwegian EPINCONT study. Am J Obstet Gynecol. 2003;189(5):1268-74.

JAYPEE BROTHERS

for detailed information on obstetrics and gynecology books, visit our website www.jaypeebrothers.com, for detailed information o

A Practical Guide to

Third Trimester of Pregnancy and Puerperium

Key Features

- Comprehensive and up-to-date content that is easy to understand in a fluid flow
- Written by experts, this book serves as a practical guide to management of third trimester of pregnancy and its complications
- Incorporates a blend of widely accepted guidelines, practical clinical understanding, and recent advances in the field
- The title begins with introduction and basics of anatomic and physiologic changes during third trimester of pregnancy and the postpartum period
- Further sections cover the antepartum, intrapartum, postpartum, and neonatal management
- Covers obstetrical complications like preterm labor, prelabor rupture of membranes, post-term pregnancy, placental adhesive disorders, and umbilical cord abnormalities
- Expanded coverage on numerous disorders that may be associated with third trimester of pregnancy, including gastrointestinal disorders, endocrinal disorders, thromboembolic disorders, and psychiatric disorders
- This book contains systematic information in a user friendly format, supported by illustrations, tables, figures, and algorithms
- In summary, this book is a practical guide to third trimester of pregnancy for obstetricians and gynecologists.

Alok Sharma
MBBS MD(OBG) MICOG DHA
Registrar, Department of Obstetrics and Gynecology
Kamla Nehru State Hospital for Mother and Child
Indira Gandhi Medical College
Shimla, Himachal Pradesh, India



Available at all medical bookstores
or buy online at www.jaypeebrothers.com

JAYPEE BROTHERS
Medical Publishers (P) Ltd.
www.jaypeebrothers.com

Join us on facebook.com/JaypeeMedicalPublishers

Shelving Recommendation
OBSTETRICS & GYNECOLOGY

ISBN 978-93-85891-29-8

9 789385 891298