ypeebrothers.com, for detailed information on surgery books, visit our website www.jaypeebrothers.com, for detailed information on surgery books

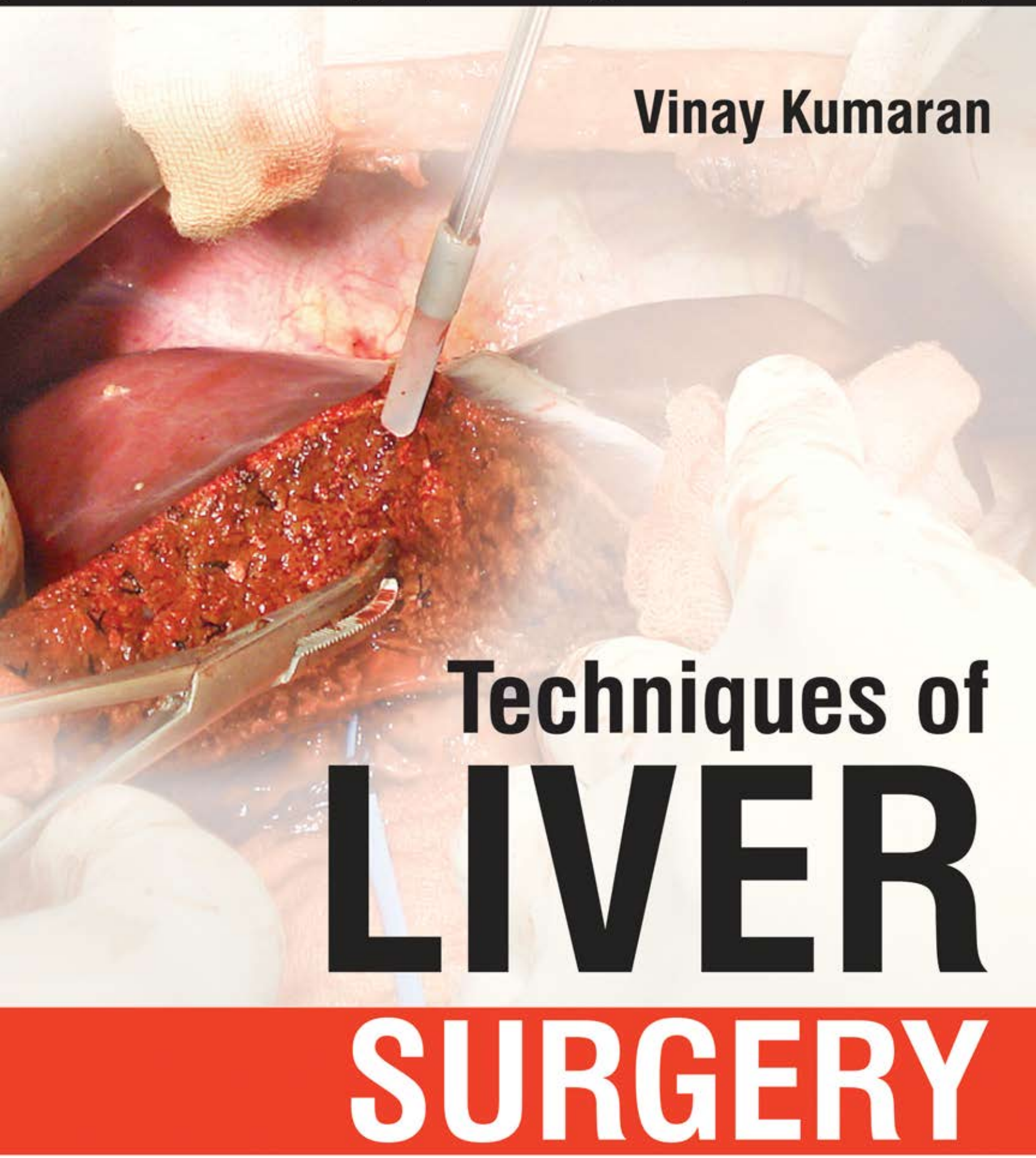

Vinay Kumaran

Techniques of LIVER SURGERY

Foreword
Samiran Nundy

JAYPEE

Contents

1. Indications for Liver Resection 1
Vibha Varma
- Primary Liver Tumor *2*
- Metastatic Liver Tumors *4*
- Indications for Resection in Benign Conditions *6*

2. Techniques for Transection of the Liver 12
Sorabh Kapoor
- Ideal Method for Parenchymal Division *12*
- Techniques for Classification of Transection Methods *13*
- Transcollation RF Technology *15*
- Comparison of Different Transection Methods *17*

3. Operations for Benign Lesions of the Liver 23
Prashantha S Rao, Tanveer Singh
- Hemangioma *23*
- Hepatocellular Adenoma *26*
- Focal Nodular Hyperplasia *27*
- Hydatid Cyst Disease *28*

4. Operations for Carcinoma of the Gallbladder 39
Vibha Varma
- Gallbladder Carcinoma *39*
- Gallbladder Polyps *45*

5. Operations for Carcinoma of the Bile Ducts 47
Vinay Kumaran
- Hilar Cholangiocarcinoma *47*
- Postoperative Care *53*
- Special Issues in Surgery for Cholangiocarcinoma *55*

6. Operations for Hepatocellular Carcinoma 59
Vinay Kumaran
- Treatment Options for Hepatocellular Carcinoma *59*
- Preparation for Surgery *61*
- Postoperative Management *69*

7. Operations for Colorectal Liver Metastases 74
Vinay Kumaran
- Portal Vein Embolization *75*
- Staged Liver Resection *75*

- ❒ Margin of Resection *75*
- ❒ Lymph Node Dissection *76*

8. Liver Transplant: Procurement of the Liver from a Deceased Donor **80**
Sorabh Kapoor
- ❒ Technical Aspects *80*
- ❒ Exposure of Aorta/Iliac Arteries and IVC *82*

9. Liver Transplant: Recipient Hepatectomy **93**
Sorabh Kapoor

10. Liver Transplant: Implantation of a Whole Liver **101**
Sorabh Kapoor
- ❒ Recipient Hepatectomy *101*
- ❒ Portal Dissection *102*
- ❒ Venovenous Bypass *105*

11. Living Donor Liver Transplant: Donor Hepatectomy **112**
Naimish Mehta, Vinay Kumaran
- ❒ Donor Evaluation *112*
- ❒ Psychiatry Assessment *113*
- ❒ Operative Steps *114*

12. Living Donor Liver Transplant: Implantation of the Graft **125**
Barun Nath, Naimish Mehta, Vinay Kumaran
- ❒ Basic Prerequisites to Implantation *125*
- ❒ Steps of Implantation *125*

Index *139*

CHAPTER

3

Operations for Benign Lesions of the Liver

Prashantha S Rao, Tanveer Singh

JAYPEE BROTHERS

INTRODUCTION

Benign liver tumors are common and account for 83% of all hepatic tumors identified on diagnostic imaging or at the time of laparoscopy.[1] Benign liver tumors may arise from either epithelial or mesenchymal cells (Table 3.1). In rare instances, a variety of miscellaneous disorders may masquerade as liver tumors. Hemangiomas and benign cysts constitute more than 50% of all hepatic lesions while focal nodular hyperplasia (FNH), metastatic tumors from a known or unknown primary cancer, hepatic adenomas and hepatocellular carcinomas constitute the remaining common diagnoses.[1] Despite significant advances in diagnostic imaging modalities, the appearance of these lesions on imaging may not be classical always and biopsy or resection may be required in cases in which the diagnosis cannot be confidently made on imaging. The inability to exclude a possible malignancy is the most common indication for surgical intervention in a benign liver tumor.

TABLE 3.1: Benign lesions of the liver

Cell of origin	*Lesion*
Epithelial	
Hepatocellular	Focal nodular hyperplasia (FNH)
	Hepatocellular adenoma
	Nodular regenerative hyperplasia
Cholangiocellular	Biliary adenoma
	Biliary cystadenoma
Mesenchymal	
Endothelial	Hemangioma
Mesothelial	Solitary fibrous tumor (benign mesothelioma)
Adipocyte	Lipoma
	Angiomyolipoma Myelolipoma
Miscellaneous	
Heterotropic tissue	Adrenal, pancreatic, splenic tissues
Others	
	Peliosis hepatis
	Focal fatty infiltration
	Inflammatory pseudotumor
	Chronic abscess

HEMANGIOMA

Hemangiomas are the most common benign tumors of the liver, with frequency in autopsy series ranging from 4 to 20%.[2-4] Liver hemangiomas occur at all ages with a female to male ratio of 3:1.[5,6] In adults, hemangiomas are usually found between the ages of 30–70 years. Small capillary hemangiomas are more common than the larger cavernous variant but are of little clinical significance.

Morphology

Cavernous hemangiomas are considered to be congenital vascular malformations and have no malignant potential; however, their exact pathogenesis is yet unknown. They are often solitary, but multiple lesions may be present in up to 40% cases.[7] They are found in both lobes of the liver with equal frequency and the majority of them are <5 cm in diameter. Giant hemangiomas are those >5 cm in size. Macroscopically they are well-circumscribed, reddish

purple hypervascular lesions and are surrounded by a thin fibrous capsule. Thrombosis may result in inflammatory changes which subsequently lead to fibrosis and even calcification. Microscopically there are large blood-filled spaces lined by endothelial cells and separated by thin incomplete fibrous septa.

Clinical Presentation

Hemangiomas are often incidentally discovered at laparotomy or abdominal radiological investigation for some other cause. Small lesions are generally asymptomatic and if an accurate diagnosis is made then no further therapy is required (Figures 3.1 to 3.3). Even larger lesions are typically asymptomatic unless producing symptoms such as upper abdominal pain, distension or due to mass effect on neighboring structures, hemorrhage or thrombosis. The pain is generally wrongly attributed to the hemangioma and usually another cause can be determined for the abdominal pain. Rarely, symptoms of acute abdomen can be produced by spontaneous rupture with intrabdominal hemorrhage.[8] Another rare but documented presentation which may require resection is of thrombocytopenia due to a thrombosis within a large hemangioma leading to a consumption coagulopathy. This is known as Kasabach–Merritt syndrome.[8] This is more common in children. There are reports of rapid increase in size of cavernous hemangiomas in women taking oral contraceptive pills or during pregnancy. However studies have shown that the growth of hemangiomas and the risk of rupture are similar between pregnant and nonpregnant women.[9,10]

Diagnosis

Liver function tests are usually normal. Thrombocytopenia may be found in patients with Kasabach–Merritt

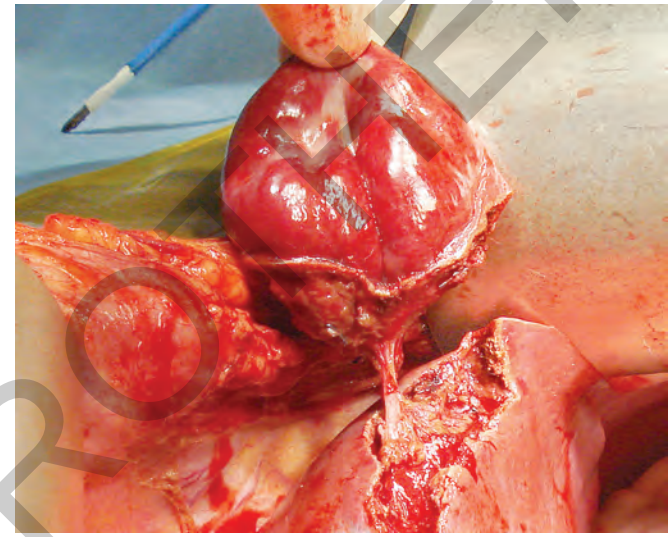

FIGURE 3.2 It is a simple procedure to enucleate the hemangioma. It is firm in consistency and there is very little bleeding. The pedicle of the hemangioma is seen in this picture.

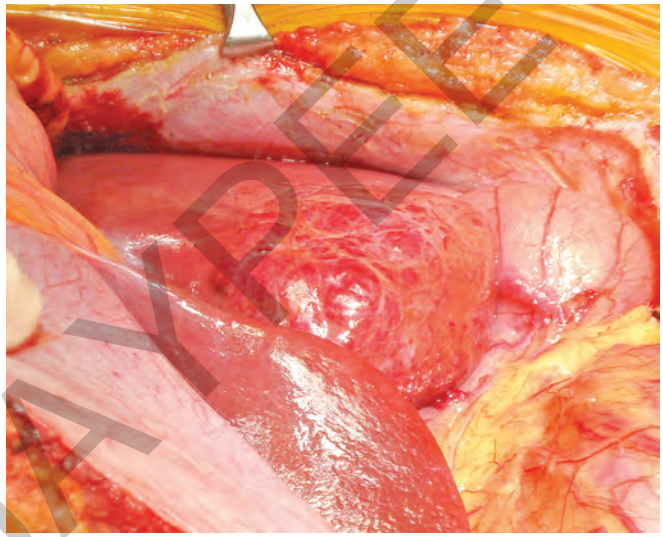

FIGURE 3.1 A rare indication for resection of an asymptomatic hemangioma. This liver donor, planned for right lobe donation was found to have a hemangioma in the left lobe of the liver on preoperative imaging. The concerns were that the hemangioma may rupture during retraction of the left lobe. There was also concern regarding its behavior during rapid regeneration of the left lobe after resection of the right lobe.

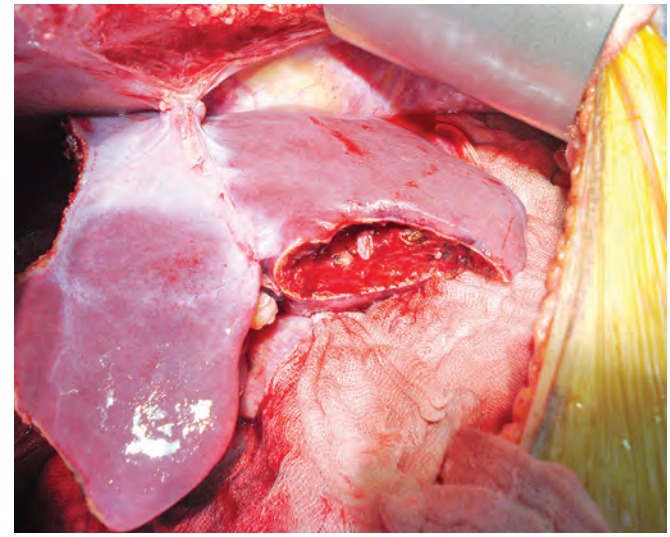

FIGURE 3.3 The donor hepatectomy was completed as usual after enucleation of the hemangioma. The additional morbidity of enucleating the hemangioma is negligible. The volume of the hemangioma must be subtracted when calculating the remnant volume on preoperative imaging.

JAYPEE BROTHERS

syndrome. The typical ultrasound appearance of a hemangioma is that of a well-demarcated, hyperechoic mass with faint acoustic enhancement.[11] On computed tomography (CT) scanning in a plain i.e. noncontrast scan they appear as a well-defined hypodense mass with lobulated borders. Calcification may be seen in 10% of cases.[12] On a triple phase contrast CT scan, they appear showing peripheral nodular enhancement in the arterial phase followed by centripetal enhancement in the delayed phase. Variations may, however, be present and these may cause difficulty in differentiation from other hypervascular liver lesions. Labeled red blood cell scintigraphy using single positron emission tomography (SPECT) is highly specific for hemangiomas. They are seen as a filling defect in the early phase that fills in centripetally in the delayed phase.[13] On Magnetic resonance imaging (MRI) scanning they appear as well-defined homogenous masses that are hyperintense on T2-weighted images. These features are better demonstrated after intravenous gadolinium-contrast administration.[14] Given the reported incidents of hemorrhage after needle biopsy and the significant false negative rate, percutaneous needle biopsy is indicated only in cases of suspected hemangiomas with atypical features.[15]

Management

The natural history of hemangiomas is still not fully understood. The risk of spontaneous rupture and intrabdominal hemorrhage is very low (<1%). Pregnancy or oral contraceptives have not been found to be risk factors for spontaneous rupture. There have been no reports of malignant transformation.

A majority of the patients would be asymptomatic and if a diagnosis is made accurately then they need only counseling and observation. Incidentally detected hemangiomas especially those <15 mm in diameter need not be further investigated unless there is a suspicion of malignancy. There is no treatment for an asymptomatic hemangioma (Figure 3.4), hence prophylactic resection in asymptomatic patients is not recommended.

There is no definite evidence linking growth of hemangiomas with oral contraceptives or pregnancy. There is also no evidence to recommend avoidance of pregnancy in women with hemangiomas.

Patients with persistent pain or symptoms due to pressure on adjacent structures may be considered for surgical management (Figures 3.5 and 3.6). However, before surgery, all other possible causes for the symptoms should be excluded before attributing the symptoms to the hemangioma. The only absolute indication for resection of a hemangioma is the development of complications such as rupture with intrabdominal hemorrhage, rapid change in size resulting in suspicion of a malignant nature of the lesion or development of Kasabach–Merritt syndrome. Patients with rupture and intrabdominal hemorrhage may benefit from preoperative conventional angiography and embolization. A relative indication for resection of a hemangioma would be the inability to exclude malignant nature of the lesion on imaging.

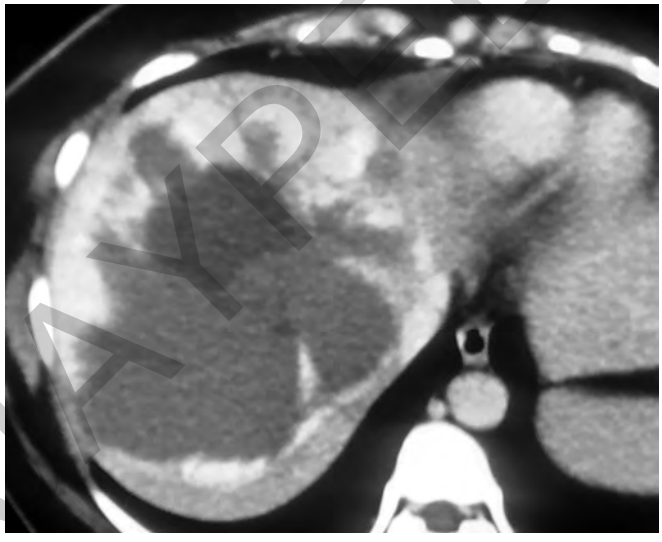

FIGURE 3.4 A large incidentally detected hemangioma in the right lobe of the liver. The CT shows the typical nodular enhancement from the periphery. The patient was asymptomatic and no treatment was offered.

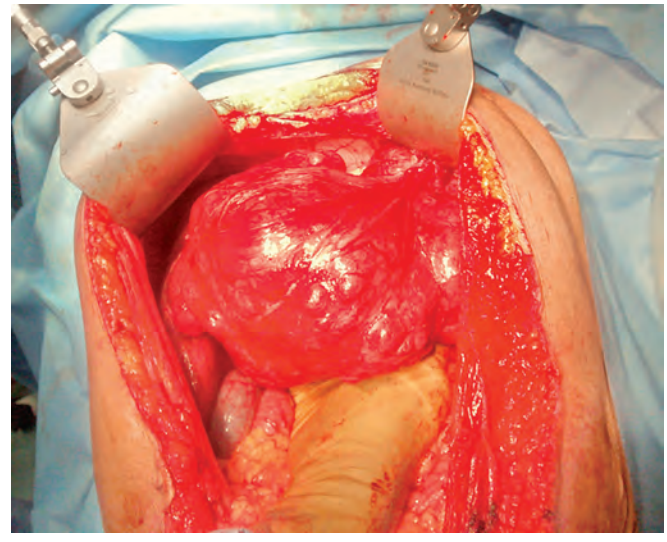

FIGURE 3.5 A large hemangioma of the left lobe of the liver. It was causing discomfort as well as pressure effects on the stomach.

JAYPEE BROTHERS

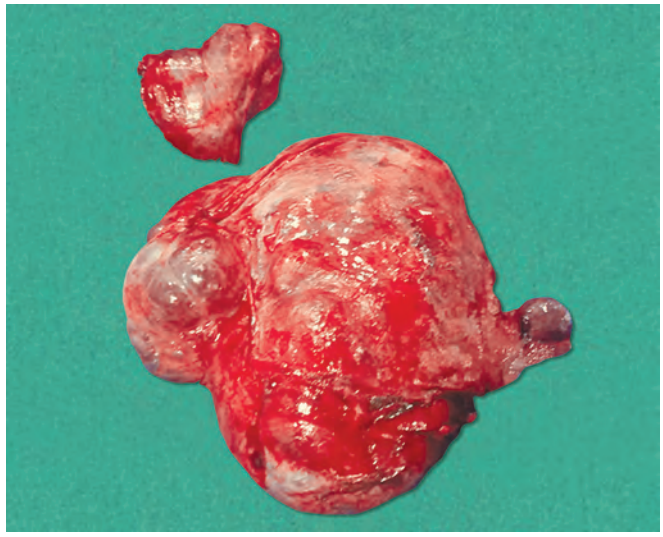

FIGURE 3.6 The resected hemangioma. There was another smaller hemangioma in the caudate. Resection of hemangiomas, either anatomical or by enucleation is usually technically easy.

Once surgery has been planned then nonanatomic resection in the form of enucleation is the preferred technique. However in patients with large lesions occupying a significant portion of a lobe a formal anatomic resection might be a better option. There are also reports of liver transplantation for symptomatic unresectable giant hemangiomas.[16]

Nonsurgical treatment for hemangiomas includes angiography and embolization, hepatic artery ligation, local irradiation and systemic steroids.

HEPATOCELLULAR ADENOMA

Hepatocellular adenoma is benign proliferation of hepatocytes in an otherwise normal liver. It occurs more commonly in women between the ages of 20–40 years with a higher incidence in women taking oral contraceptive medications. It may also be found in males with various series reporting up to 16–20% of adenomas occurring in males.[17]

Morphology

Hepatocellular adenomas commonly present as solitary nodules. On gross examination they range from being white to brown in color. On cut section, they have a fleshy appearance and there may be areas of hemorrhage or necrosis within the lesion. Microscopically they lack a fibrous capsule but there may be a pseudocapsule of compressed liver tissue around the lesion. They are made of benign hepatocytes containing increased glycogen and fat and arranged in cords. The normal arrangement of the hepatocytes with portal tracts is absent. Liver adenomatosis is defined as presence of >10 adenomas within the liver. About 10% to 24% patients may have multiple adenomas in the liver.[18] Malignant transformation can occur but is rare and regression of adenomas after withdrawal of oral contraceptives is also known.

Etiology

There is a strong association between the occurrence of hepatocellular adenoma and the use of oral contraceptives or androgen steroid therapy. The risk for development liver cell adenoma after oral contraceptive medication use is proportional to the hormonal dose (estrogen content of the oral contraceptive used) and the duration of medication.[19,20] Hepatocellular adenomas can also occur in underlying metabolic disorders such as type I glycogen storage disease, iron overload secondary to β-thalassemia and diabetes mellitus.[18,21]

Clinical Presentation

Right upper quadrant fullness or heaviness maybe seen in patients with large hepatocellular adenomas. An important complication of hepatocellular adenomas is their tendency for spontaneous bleeding within the tumor with or without rupture into the peritoneal cavity. The risk of spontaneous bleeding ranges from 20% to 40% with an increased risk of bleeding in patient with tumors >5 cm in diameter, patients taking oral contraceptives and during pregnancy.[22-24] Patients with intraperitoneal rupture and bleeding present with features of acute abdomen with hypovolemic shock. Hepatocellular adenomas also have a 10% risk of malignant transformation with the risk being higher in men, women using oral contraceptives and in patients with large-sized adenomas.[18]

Diagnosis

On ultrasound examination, hepatocellular adenomas are seen as a well-delineated mass with heterogenous echogenicity. The fat and glycogen content of the mass contributes to the hyperechoic nature while the hemorrhagic and necrotic areas contribute to the hypoechoic areas. On plain CT, the hepatocellular adenomas are isodense to the surrounding liver parenchyma or heterogenous due to areas of hemorrhage. On contrast CT scanning, the lesions appear hyperdense and heterogenous in the arterial phase and are isodense or hypodense on the portal venous phase. On MRI scans

JAYPEE BROTHERS

they appear hyperintense or isointense on T1-weighted images due to the fat content and hemorrhage and mildly hyperintense on T2-weighted images.

Treatment

Hepatic adenoma has a different natural history from FNH, since it poses the risk of rupture and bleeding. There is a significant risk of malignant transformation into hepatocellular carcinoma. For these reasons surgical resection is advocated for all hepatic adenomas, as well as cases of diagnostic uncertainty. Some authorities have proposed a less aggressive approach for asymptomatic adenoma depending on the size of the adenoma.[25] Small lesions (<4 cm in diameter) have a low risk of complications and hence can be observed after discontinuation of oral contraceptive use. These patients are followed with serial imaging and alpha-feto protein determinations. Radiofrequency ablation is a possibility, but follow-up data are lacking. For patients with adenomas >4 cm in size the standard of care is surgical resection, which can be achieved by the open approach or laparoscopically. Anatomical resection is the preferred option for resection. Adenomatosis which is associated with glycogen storage disease has been reported as a possible indication for liver transplantation, especially due to the high risk of malignant transformation.[18,26,27] However, definitive evidence in its favor to make liver transplantation as a standard of care is not yet available.

FOCAL NODULAR HYPERPLASIA

Focal nodular hyperplasia (FNH) is the second most common benign hepatic tumor. It is more prevalent in women (about 8:1) and presents in the 3rd to 5th decades of life.[28] No association with oral contraceptive usage or pregnancy has been substantiated.

Morphology

FNH lesions are usually solitary in 80% of cases.[29] Macroscopically, FNH appears well-circumscribed lobulated and light brown in color and lacks a definitive capsule. A distinguishing feature of FNH is the central scar with fibrous septa radiating outward. Within this central scar, a prominent arterial vessel is usually found. Microscopically FNH reveals morphologically normal hepatocytes arranged in thickened plates. The normal lobular arrangement of the hepatocytes is not seen. Kupffer cells and hepatocytes derived biliary ductules are seen at the interface between fibrous bands and nodules but bile ducts are absent. Atypical or non-classic forms of FNH constitute as many as 20% in series of resected cases.[28] These may be telangiectatic FNH, mixed hyperplastic and adenomatous form and FNH with cytological atypia.

Etiology

The pathogenesis of FNH is controversial. Originally FNH was considered a neoplasm, a hamartoma, or a hyperplastic regenerative response to ischemia. Currently FNH is thought to develop as a dysplastic response to malformed vascular structures. This theory is strengthened by an association of FNH with other vascular malformations such as hemangioma, hereditary hemorrhagic telangiectasia and Klippel–Trenaunay syndrome, as well as the case of identically located FNH in identical twins. Hepatocytes within FNH have been described as polyclonal in some studies, further supporting a non-neoplastic origin. A possible association with female hormonal factors is derived from the predominant occurrence in women of child-bearing age. However, no influence of oral contraception on the size, number, or natural history of FNH has been shown in studies.

Clinical Presentation

In most cases, an FNH is asymptomatic and is an incidental finding in imaging performed for some other complaints. In surgical series, one fourth to more than one half of patients are symptomatic. This could be due to symptoms inappropriately attributed to the FNH. Complications such as rupture, bleeding or malignant transformation do not occur in FNH. The clinical findings and laboratory test results are usually normal.

Diagnosis

An ultrasound is often the initial diagnostic evaluation; however the diagnosis of FNH cannot be confidently made for lack of specific signs. FNH can appear hyperechoic, isoechoic, or hypoechoic on conventional ultrasound. Contrast-enhanced ultrasound seems to be more useful in making a diagnosis of FNH due to characteristic vascular imaging features that can be seen. In the initial phase, the FNH appears hypoechoic to isoechoic to the rest of the liver. In the arterial phase, the FNH appears hyperechoic compared, to the remaining liver while the scar remains hypoechoic. A spoke wheel pattern of branching of the arteries can be seen beginning from the central scar and radiating peripherally into the fibrous septa. In the portal phase, the FNH becomes hypoechoic to isoechoic to

JAYPEE BROTHERS

the liver. This is indicative of the FNH being composed of normal hepatocytes and thus retaining the imaging features of normal hepatocytes. The scar, however, may appear hyperechoic in the delayed phase due to accumulation of contrast.

On CT scanning, an FNH appears as an isodense or hypodense lobulated tumor in comparison to the rest of the liver. The central scar may not be easily apparent on a plain CT scan. After contrast administration, the FNH appears hyperdense in the arterial phase. However, the scar remains hypodense and making it more apparent due to the difference in attenuation. In the portal and delayed phases, the FNH parenchyma appears hypodense or isodense to the liver. The scar may appear hypodense to isodense due to delayed accumulation of contrast.

On MRI, a FNH is typically isointense to hypointense on T1-weighted images and isointense to hyperintense on T2-weighted images, with the central scar being hyperintense in T2. After administration of gadolinium contrast, the parenchyma appears hyperintense whereas the central scar appears relatively hypointense. In the delayed phase, the FNH parenchyma returns to its baseline intensity while the scar shows increased signal intensity due to the accumulation of contrast as mentioned earlier. The presence of Kupffer cells in FNH can also be utilized to possibly distinguish FNH from hepatic adenoma by performing MRI using super paramagnetic ion oxide (SPIO) contrast agents due to the uptake and metabolism properties of the Kupffer cells. The same properties can be used while performing scintigraphy with 99m-Tc sulfur colloid.

Angiography demonstrates a "spoked wheel" appearance but is usually not indicated for diagnosis. Biopsy is not advocated due to its low diagnostic yield.

Treatment

FNH has a benign and stable natural history with no malignant potential and usually no symptoms that can be attributed to it. Therefore, when the diagnosis of FNH is certain, then follow-up imaging should be performed after 6 to 12 months. If the lesion remains stable and asymptomatic, no further intervention is required. If there is a doubt in definitive diagnosis of FNH only then resection is indicated. This involves a partial hepatectomy performed either by open approach (Figures 3.7 to 3.16) or if the facilities are available, laparoscopically.

HYDATID CYST DISEASE

Hydatid cyst disease is a zoonotic disease caused by infection with the Cestode (Tapeworm) parasite belonging to the genera *Echinococcus*. There are 4 species of *Echinococcus* which infect man. They are *E. granulosus, E. vogeli, E. oligarthus* and *E. multilocularis* (also known as *E. alveolaris*). Hydatid cyst disease is caused by *E. granulosus* or *E. multilocularis. E. granulosus* is found worldwide in areas where dogs are used to help raise livestock. *E. multilocularis* is predominantly distributed in North America, whereas *E. vogeli* is found scattered in areas of Central and Latin America.

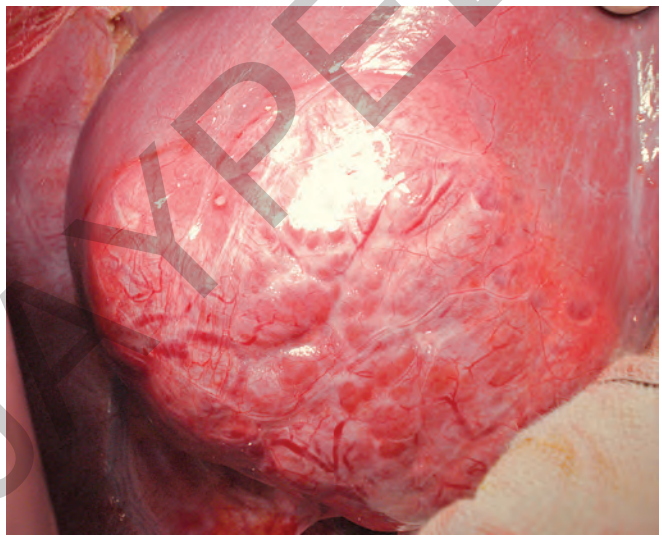

FIGURE 3.7 Focal nodular hyperplasia. Required resection because of atypical imaging findings. HCC could not be conclusively ruled out.

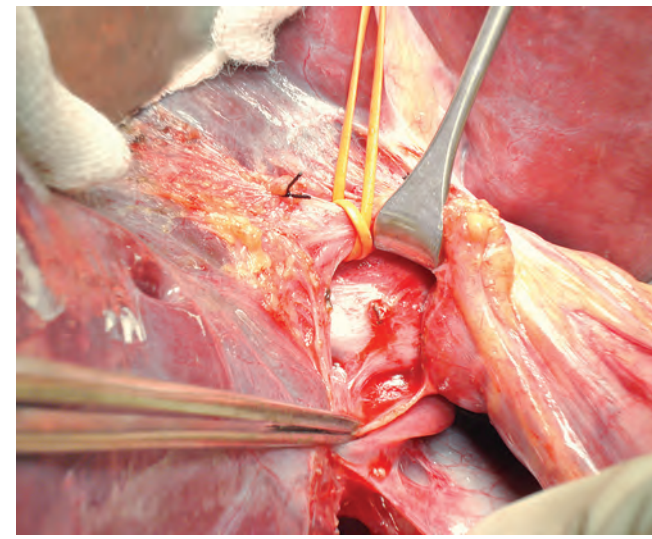

FIGURE 3.8 Vascular inflow control was established. Initially the right hepatic artery was looped.

JAYPEE BROTHERS

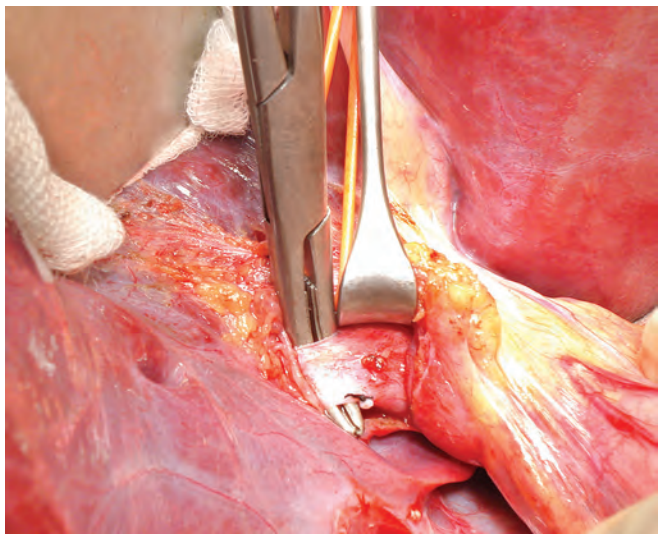

FIGURE 3.9 The right portal vein is also dissected.

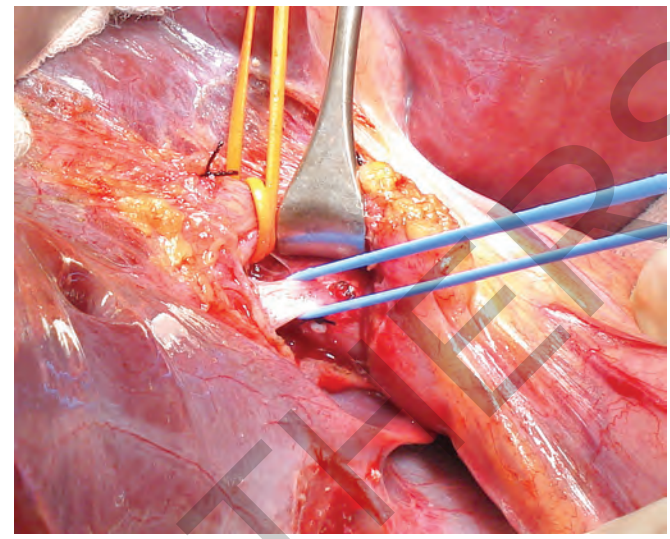

FIGURE 3.10 A sling passed around the right portal vein.

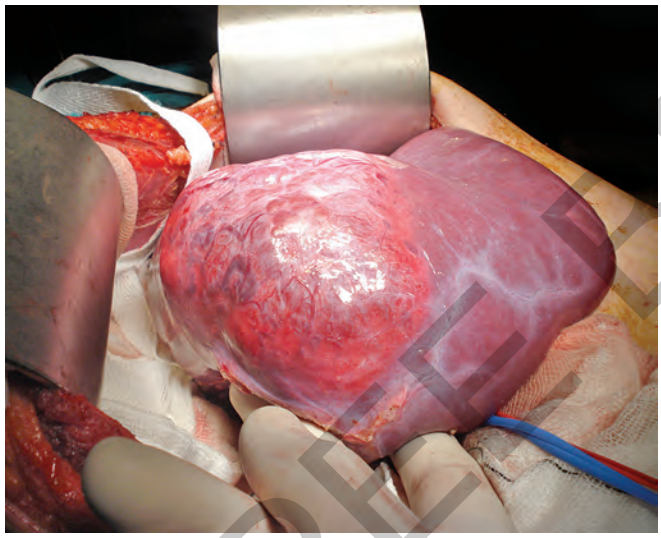

FIGURE 3.11 Traction on the loops assures a relatively avascular resection.

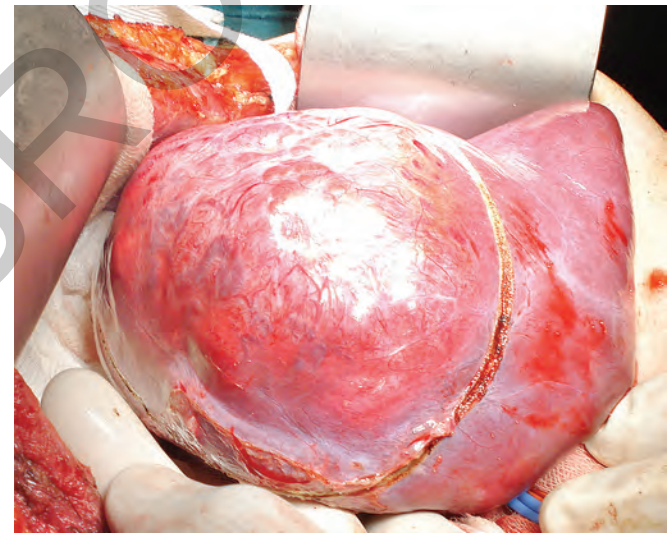

FIGURE 3.12 The transection line is marked. A nonanatomical resection is planned to avoid loss of liver parenchyma.

Life Cycle

The definitive host for the parasite is the dog. In the normal life cycle, the adult parasite is present inside the intestines of the dog. The tapeworm consists of a scolex, containing a rostellum with 20 to 50 hooklets and 4 suckers, a neck and an immature, mature, and gravid proglottid which contains the eggs. These embryonated eggs are passed in the dog feces which infect the sheep, cattle, or other livestock during grazing. These animals constitute the intermediate host for the parasite. The eggs hatch in the small intestine of the animals and liberate oncospheres which penetrate the gut mucosa and migrate through the vessels or lymphatics to distant sites where they form the hydatid cyst. Dogs acquire the infection by consumption of the organs of these animals bearing the hydatid cyst. Humans are an accidental intermediate host as the life cycle of the parasite is not completed by entering into a human host. Human infection occurs by eating vegetables which are contaminated by dog feces containing the embryonated eggs.

JAYPEE BROTHERS

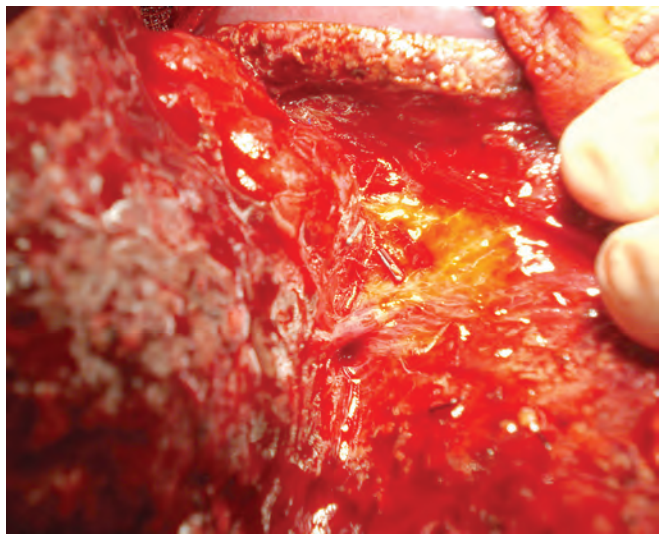

FIGURE 3.13 As the resection progresses the vascular pedicle of the lesion becomes evident and can be divided between ligatures.

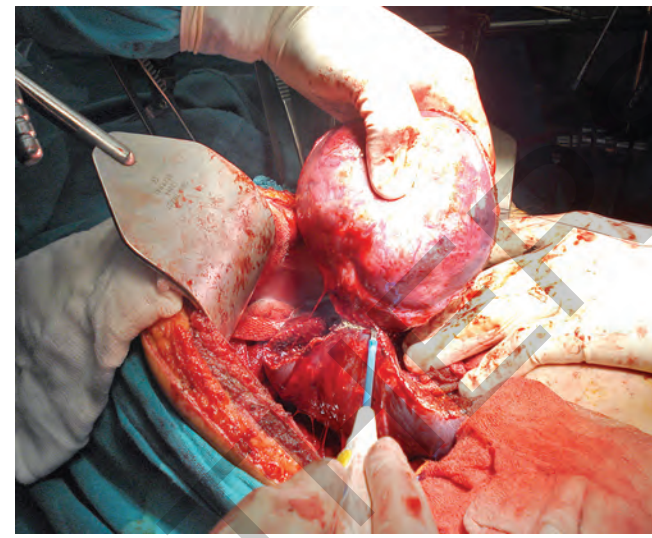

FIGURE 3.14 Resection is nearly complete.

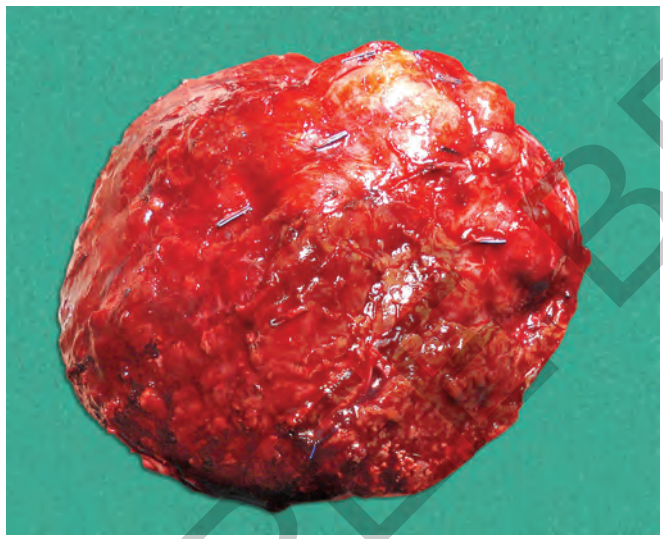

FIGURE 3.15 The specimen

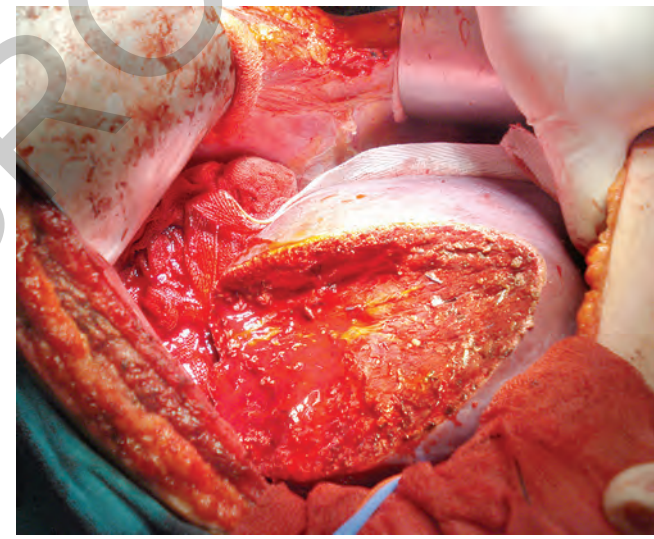

FIGURE 3.16 The surface is inspected for bleeding and bile leaks. Drainage is not mandatory.

Morphology

The liver is the most common location of the hydatid cysts found in a majority (70%) of patients, with the remaining sites being lungs (20%), kidney, spleen, brain, and bone.[30] The hydatid cyst wall consists of three layers, an outer adventitial layer, the intermediate laminated layer which is acellular and an inner germinal layer. The adventitial layer which is the host derived fibrous layer, is formed by the host reaction to the hydatid cyst and forms the pericyst while the intermediate and germinal layers are derived from the parasite itself and constitute the endocyst. The germinal layer forms the brood capsules and secondary or daughter cysts within the primary cyst by endogenic vesiculation and further more thousands of protoscolices are formed within each daughter cyst. The adventitial layer is present in hepatic and splenic hydatid cysts but is lacking in the hydatid cyst within the lungs and brain. A protoscolex is produced asexually within the daughter cyst and develops from the inner layer. Rupture of the hydatid cyst releases the viable protoscolices, which can then form daughter cysts at secondary sites. Human infection occurs

JAYPEE BROTHERS

for detailed information on surgery books, visit our website **www.jaypeebrothers.com,** for detailed information on surgery books, visit our website

Techniques of LIVER SURGERY

The book is written by experienced liver surgeons. It is a sort of "Do It Yourself" for surgeons interested in liver surgery. A basic background of the diseases is provided and patient selection is discussed but most of the book is focussed on techniques. Each author takes up an operation and describes how he/she does it. No attempt is made to comprehensively cover all the possible ways of performing an operation but the technique described is one that works for the author.

The operative photographs and illustrations clarify steps of surgery and illustrate difficult situations and ways to deal with them. This book contains the first detailed description of the "W Technique", a safe and easy technique for performing the hepatic artery anastomosis in living donor liver transplantation. This technique, first presented at the International Liver Transplantation Society meeting in 2014, allows the anastomosis to be performed in a technically simple and reproducible manner even in the presence of considerable luminal disparity without the use of an operating microscope with one of the lowest incidences of hepatic arterial complications in the world.



Vinay Kumaran MBBS MS MCh is Consultant and Head, HPB Surgery and Liver Transplant, Kokilaben Dhirubhai Ambani Hospital and Medical Research Institute, Mumbai, Maharashtra, India. He did his MBBS and MS (Surgery) from Maulana Azad Medical College, New Delhi, India. He was a Senior Resident (Surgery) at the University College of Medical Sciences, New Delhi for 2 years. He did his MCh in Gastrointestinal Surgery from All India Institute of Medical Sciences, New Delhi. He spent 2 years as a Post-Doctoral Fellow at the Marion Bessin Liver Research Center of the Albert Einstein College of Medicine, New York. He worked in Dr Sanjeev Gupta's laboratory on hepatocyte transplantation, liver stem cells, hemophilia and animal models of acute and chronic liver injury. Research work from this period was published in high-impact journals such as Nature Medicine, Gastroenterology, Hepatology, Thrombosis and Hemostasis, etc. He did a fellowship in Transplant Surgery at the Thomas Starzl Transplantation Institute at the University of Pittsburgh Medical Center. The 2 years fellowship included training in liver, kidney, pancreas, small bowel and multivisceral transplantation in adult as well as pediatric (at the Children's Hospital of Pittsburgh) recipients. He stayed on for an optional third year focussing on difficult liver transplants (redo transplants, etc.) and living donor liver transplants. He returned to India in 2007 and joined Sir Ganga Ram Hospital as Consultant, Surgical Gastroenterology and Liver Transplantation. He was a part of the team that performed the first dual lobe liver transplant, the first domino liver transplant, the first combined liver and kidney transplant and the first paired donor exchange liver transplants in India. In 2010, he became Director, Liver Transplant at Sir Ganga Ram Hospital and led the team that performed the first living donor intestinal transplant and the first hepatectomy, ex-situ resection and auto-liver transplantation in India. In 2013, he joined Kokilaben Dhirubhai Ambani Hospital, Mumbai to set up a Center of Excellence for Liver Transplant and Hepatobiliary Surgery. After the successful establishment of the liver transplant program at Kokilaben Hospital, he is in the process of starting pancreas, small bowel and multivisceral transplantation at the center.

Available at all medical bookstores
or buy online at www.jaypeebrothers.com

JAYPEE BROTHERS
Medical Publishers (P) Ltd.
www.jaypeebrothers.com

Join us on facebook.com/JaypeeMedicalPublishers

Shelving Recommendation
SURGERY

ISBN 978-93-85891-56-4

9 789385 891564