rics and gynecology books, visit our website www.jaypeebrothers.com, for detailed information on obstetrics and gynecology book

Comprehensive Video Atlas of Laparoscopic Surgery in Infertility and Gynecology

Nutan Jain



JAYPEE

Forewords
L Mettler
Ceana Nezhat
Robert D Moore

Includes 7 Interactive DVD-ROMs
Containing 75 Videos
Duration 9 hours 49 minutes

Contents

PART 1: INTRODUCTION TO LAPAROSCOPIC SURGICAL TECHNIQUES

1. **Introduction to the Operating Rooms** 3
   Nutan Jain, Vandana Jain, Monika Ranwa
2. **Operation Theater Layout** 5
   Nutan Jain, Vandana Jain, Monika Ranwa
3. **Instruments** 12
   Nutan Jain, Monika Ranwa, Vandana Jain
4. **Preoperative Preparation** 14
   Nutan Jain, Monika Ranwa, Swati Kanawa
5. **Intraoperative Anesthetic Considerations** 16
   Ravindra Kumar, Nutan Jain, Tanya G Singh
6. **Standard Technique of Trocar Placement** 20
   Nutan Jain, Monika Ranwa, Sonika Mann, Shweta Sareen
7. **Extrocation (How to Remove Trocars after Finishing Laparoscopic Surgery)** 24
   Nutan Jain, Monika Ranwa, Shweta Sareen
8. **Postoperative Recovery and Instructions** 26
   Nutan Jain, Monika Ranwa, Sumiti Bansal

PART 2: VIDEOS OF LAPAROSCOPIC SURGERY

SECTION 1: GENERAL LAPAROSCOPIC TECHNIQUES

Video 1: Operating Room Set-up 31
Nutan Jain, Vandana Jain

Video 2: Standard Technique of Port Placement by New Laparoscopic Entry Port (The Jain Point) 33
Nutan Jain, Vandana Jain, Swati Kanawa

Video 3: Chair Laparoscopy 38
Nutan Jain, Sumiti Bansal

Video 4: 1, 2 and V the Way to do Laparoscopic Suturing 40
Nutan Jain, Vandana Jain, Anjali Gupta

SECTION 2: ADNEXAL SURGERY

Video 1: Laparoscopic Management of Bilateral Dermoid Cysts with Posterior Colpotomy 47
Nutan Jain, Vandana Jain
Video 2: Laparoscopic Management of Paraovarian Cyst 49
Nutan Jain, Vandana Jain, Sumiti Bansal
Video 3: Laparoscopic Management of Huge Pseudomucinous Cyst 51
Nutan Jain, Vandana Jain, Monika Ranwa
Video 4: Management of Large Ovarian Cyst with Pregnancy 53
Nutan Jain, Vandana Jain
Video 5: Twisted Ovarian Cyst 55
Nutan Jain, Vandana Jain
Video 6: Laparoscopic Management of Huge Fibroma 57
Nutan Jain, Vandana Jain
Video 7: Cystectomy in a Bag 59
Nutan Jain, Vandana Jain, Monika Ranwa, Swati Kanawa

SECTION 3: ENDOMETRIOSIS

Video 1: Radical Excision of Grade II Endometriosis 63
Nutan Jain, Vandana Jain, Sumiti Bansal
Video 2: Laparoscopic Management of Advance Endometriosis with RV Nodule and Presacral Neurectomy 65
Nutan Jain, Vandana Jain, Monika Ranwa
Video 3: Laparoscopic Management of Extensive Endometriosis 67
Nutan Jain
Video 4: Case Reports (Part 1) of Spontaneous Pregnancies Following DIE Excision 69
Alysson Zanatta
Video 5: Case Reports (Part 2) of Spontaneous Pregnancies Following DIE Excision 72
Alysson Zanatta
Video 6: Laparoscopic Management of Endometriotic Cyst 75
Nutan Jain, Vandana Jain, Monika Ranwa, Ajay Agarwal

SECTION 4: INFERTILITY

Video 1: Management of Polycystic Ovaries 79
Nutan Jain, Vandana Jain, Monika Ranwa
Video 2: Salpingo-Ovariolysis 81
Nutan Jain, Vandana Jain, Shweta Sharma
Video 3: Postsurgical Adhesiolysis 83
Nutan Jain, Vandana Jain, Swati Kanawa
Video 4: Salpingectomy for Hydrosalpinx 85
Nutan Jain, Vandana Jain

SECTION 5: MYOMECTOMY

Video 1: Laparoscopic Management of Anterior Wall Myoma 89
Nutan Jain, Vandana Jain
Video 2: Laparoscopic Management of Posterior Wall Myoma Using (V-Loc Suture) 91
Nutan Jain, Vandana Jain
Video 3: Laparoscopic Management of Multiple Deep Intramural Myomas 93
Nutan Jain, Vandana Jain
Video 4: Laparoscopic Management of Multiple Myomas 95
Nutan Jain, Vandana Jain, Monika Ranwa
Video 5: Myoma with Unicornuate Uterus 97
Nutan Jain, Vandana Jain
Video 6: Management of Broad Ligament Myoma 99
Nutan Jain, Vandana Jain
Video 7: Laparoscopic Myomectomy of Cervical Fibroid with Uterine Artery Ligation at Origin (No Voiceover) 101
Rakesh Sinha, Gayatri Rao, Shweta Raje
Video 8: Posterior Wall Myoma Using (Barb Sutures) 102
Nutan Jain, Vandana Jain

SECTION 6: TOTAL LAPAROSCOPIC HYSTERECTOMY

Video 1: Standard Technique of Total Laparoscopic Hysterectomy 107
Nutan Jain, Vandana Jain, Monika Ranwa
Video 2: Total Laparoscopic Hysterectomy with Adenomyosis 109
Nutan Jain, Vandana Jain, Ajay Agarwal
Video 3: Total Laparoscopic Hysterectomy with Multiple Myoma 111
Nutan Jain, Vandana Jain
Video 4: Total Laparoscopic Hysterectomy with Previous Three Cesarean Sections 113
Nutan Jain, Vandana Jain
Video 5: Total Laparoscopic Hysterectomy with Extensive Endometriosis 115
Nutan Jain, Vandana Jain, Swati Kanawa
Video 6: Total Laparoscopic Hysterectomy with Bilateral Endometriotic Cyst 117
Nutan Jain, Vandana Jain
Video 7: Total Laparoscopic Hysterectomy with Uterine Artery Ligation at Origin (No Voiceover) 119
Rakesh Sinha, Gayatri Rao, Shweta Raje

SECTION 7: PELVIC FLOOR REPAIR

Video 1: Laparoscopic Uterovaginal Prolapse Repair 123
Nutan Jain, Vandana Jain
Video 2: UV Prolapse Repair without Use of Mesh 125
Nutan Jain, Vandana Jain
Video 3: Lateral Suspension 127
Nutan Jain, Vandana Jain
Video 4: Sacrocolpopexy 129
Nutan Jain, Vandana Jain
Video 5: Post-hysterectomy Vault Prolapse Repair 131
Nutan Jain, Vandana Jain
Video 6: Vault Prolapse Repair without Use of Mesh 133
Nutan Jain
Video 7: Burch Colposuspension for Stress Urinary Incontinence 135
Nutan Jain
Video 8: The 26-minute Sacral Colpopexy: Do We Need Robotic Technology? 137
John R Miklos, Robert D Moore
Video 9: Obturator Neuralgia: Complete Resolution after Laparoscopic TVT Removal 138
John R Miklos, Robert D Moore, Orawee Chinthakanan
Video 10: Chronic Pelvic Pain and SUI Resolution after Laparoscopic TVT Removal and Burch/Paravaginal Repair 139
John R Miklos, Robert D Moore, Orawee Chinthakanan

SECTION 8: ECTOPIC PREGNANCY

Video 1: Salpingostomy 143
Nutan Jain, Vandana Jain
Video 2: Salpingectomy 145
Nutan Jain, Vandana Jain
Video 3: Interstitial Ectopic Pregnancy 147
Nutan Jain
Video 4: Hysteroscopic Management of Cervical Ectopic Pregnancy 149
Nutan Jain
Video 5: Pregnancy in a Rudimentary Horn 150
Nutan Jain
Video 6: Cesarean Section Scar Pregnancy 152
Nutan Jain, Vandana Jain
Video 7: Salpingectomy for Cornual Ectopic Pregnancy 154
Nutan Jain, Vandana Jain

SECTION 9: SPECIAL PROCEDURES

Video 1: Laparoscopic Creation of Neovagina 159
Nutan Jain, Vandana Jain
Video 2: Microsurgical Tubotubal Anastomosis 161
Nutan Jain, Vandana Jain
Video 3: Strassman's Metroplasty 163
Nutan Jain, Vandana Jain
Video 4: Laparoscopic Cervical Cerclage 165
Nutan Jain, Vandana Jain
Video 5: Laparoscopic Cerclage with Deschamps Needle (No Voiceover) 167
Hans Brölmann

SECTION 10: ROBOTIC SURGERY

Video 1: Robotic Surgery of Myomectomy 171
RK Mishra
Video 2: Robotic Total Laparoscopic Hysterectomy: Management of DUB 172
RK Mishra
Video 3: Ovarian Cystectomy: For 12 cm Right Sided Ovarian Cyst 173
RK Mishra
Video 4: Robotic Appendicectomy: Management of Acute Appendicitis 174
RK Mishra
Video 5: Robotic-assisted Tubal Reanastomosis 175
Fatih Sendag

SECTION 11: SINGLE-PORT SURGERY

Video 1: Single-port Laparoscopic Hysterectomy in Patient with Severe Endometriosis 179
Fatih Sendag
Video 2: Single-port Laparoscopic Endometriosis Surgery 180
Fatih sendag
Video 3: Single-incision Laparoscopic Myomectomy (No Voiceover) 181
Rakesh Sinha, Shweta Raje, Gayatri Rao
Video 4: Single-incision Laparoscopic Hysterectomy (No Voiceover) 183
Rakesh Sinha, Gayatri Rao, Shweta Raje

SECTION 12: ONCOLOGY

Video 1: Laparoscopic Radical Hysterectomy 187
Shailesh Puntambekar
Video 2: Laparoscopic Anterior Exenteration 189
Shailesh Puntambekar

COSMETIC GYNECOLOGY

This section is not accompanied by summary

Video 1: Endoscopic Transaxillary Breast Augmentation for the Gynecologist
Marco A Pelosi II
Video 2: Liposuction for the OBGYN: Intraoperative Comparison of Liposuction Techniques
Marco A Pelosi II
Video 3: Office Lipoabdominoplasty under Tumescent Anesthesia for the Gynecologist
Marco A Pelosi II
Video 4: Laser Assisted Liposuction of the Mons Pubis and Labia Majora
Marco A Pelosi II
Video 5: Minimally Invasive Buttocks Cosmetic Enhancement for the Gynecologist
Marco A Pelosi II
Video 6: Cosmetic Genital Surgery
Marco A Pelosi II
Video 7: The Value of Liposculpturing and Fat Transfer in Cosmetic Genital Surgery
Marco A Pelosi II

SECTION 3

ENDOMETRIOSIS

Video 1: Radical Excision of Grade II Endometriosis
Nutan Jain, Vandana Jain, Sumiti Bansal

Video 2: Laparoscopic Management of Advance Endometriosis with RV Nodule and Presacral Neurectomy
Nutan Jain, Vandana Jain, Monika Ranwa

Video 3: Laparoscopic Management of Extensive Endometriosis
Nutan Jain

Video 4: Case Reports (Part 1) of Spontaneous Pregnancies Following DIE Excision
Alysson Zanatta

Video 5: Case Reports (Part 2) of Spontaneous Pregnancies Following DIE Excision
Alysson Zanatta

Video 6: Laparoscopic Management of Endometriotic Cyst
Nutan Jain, Vandana Jain, Monika Ranwa, Ajay Agarwal

JAYPEE BROTHERS

Video 1

Radical Excision of Grade II Endometriosis

Nutan Jain, Vandana Jain, Sumiti Bansal

Age: 25 years **Parity:** P 0 + 0 **ML:** 3 years

Present Complaints: Primary infertility.
Sonography: Normal, **Hormonal profile**-normal, **Husband semen analysis**-normal.
PV Examination: Normal.
Preoperative Diagnosis: Unexplained primary infertility.
Port Placement: Patient laid in modified lithotomy position under GA. Four ports laparoscopy done. All ports are 5 mm except camera port which is 10 mm.

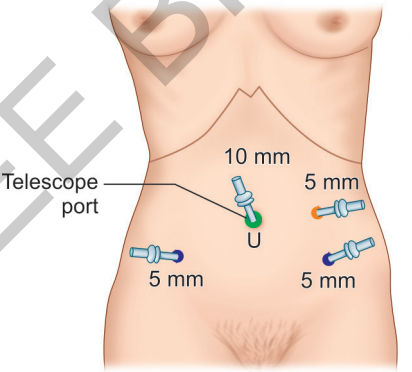

- 1st port—5 mm paraumbilical port on a vertical line drawn up from a point 2.5 cm medial to left ASIS (at Jain point). This is the first blind port, through this, the 5 mm 0° telescope is inserted.
- 2nd port—10 mm umbilical port inserted directly under visualization of 5 mm telescope.
- 3rd port—2.5 cm medial and 1 cm above the left ASIS.
- 4th port—2.5 cm medial and 1 cm above the right ASIS.

Surgical Procedure: On inserting the telescope endometriotic implants noted in pouch of Douglas and lateral pelvic wall. Allan master's window noted on right side pelvic wall. Along with these implants lot of puckering and scarring also noted in POD, uterosacrals and along the ureters. All the peritoneal implants fulgurated with bipolar forceps. Radical excision of

JAYPEE BROTHERS

all endometriotic implants done using harmonic ACE. The nodular and thickened uterosacral ligaments resected by harmonic ACE. Allan master's window opened up. Lateral dissection done parallel to ureters. Both sides peritoneum over ureter opened by bipolar forceps and ureter lateralized. Course of ureter kept under track during the fulguration and excision of implants.

Energy Source: Harmonic ACE for excising peritoneal endometriotic implants, and bipolar for fulguration.

Follow-up: Patient is given active infertility management in the form of ovulation induction in coming cycles.

JAYPEE BROTHERS

Video 2

Laparoscopic Management of Advance Endometriosis with RV Nodule and Presacral Neurectomy

Nutan Jain, Vandana Jain, Monika Ranwa

Age: 30 years **ML:** 8 years **Parity:** P1(LSCS) + 0

Present Complaints: Severe dysmenorrhea with secondary infertility. She also complained of dyspareunia.

Sonography: Her sonography showing retroverted enlarged globular uterus with signs of adenomyosis and adherent right ovary, which was tender on scanning. Her **CA-125** was increased 214 IU/mL.

PV examination: Uterus retroverted and fixed, puckering and scarring in vaginal fornices, severe tenderness on examination.

Presumptive Diagnosis: Grade IV endometriosis.

Port Placement: Patient laid in modified lithotomy position under GA. Four ports laparoscopy done, all ports are 5 mm except camera port which is 10 mm.

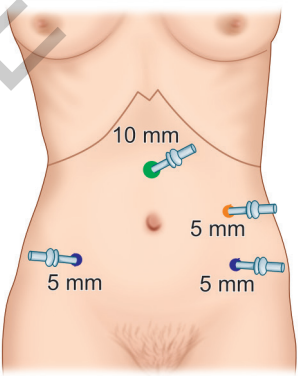

- 1st port—5 mm port at left paraumbilical position on a vertical line drawn up from a point 2.5 cm medial to left ASIS (at Jain point). This is the first blind port, through this the 5 mm 0° telescope is inserted.
- 2nd port—10 mm supraumbilical port inserted under direct visualization of 5 mm telescope.
- 3rd port—2.5 cm medial and 1 cm above the left ASIS.
- 4th port—2.5 cm medial and 1 cm above the right ASIS.

JAYPEE BROTHERS

Surgical Procedure: On inserting the telescope, uterus is densely retroverted, fixed in pouch of Douglas. Mesentery of colon is fixed to left sided anterior abdominal wall by taking three to four prolene, 1-0 stitches to enhance the pelvic vision. This is routinely done to clear the bowel from the pelvis and enhance the vision of pouch of Douglas and adnexa. Right tube was looking dilated and edematous, which was stuck on the posterior surface of uterus while right ovary stuck anteriorly. Left tube and ovary comparatively free. Initially spill seen only from left tube on hydrotubation. Gentle adhesiolysis started using sharp and blunt hook scissors. During dissection a small right ovarian endometrioma drained of chocolate material and cyst wall completely fulgurated. Right tube and ovary were totally released from the back surface of uterus. All the endometriotic implants beneath the left ovary were fulgrated using a bipolar forceps. Uterosacral ligaments felt to be thickened, nodular and adherent to rectosigmoid with lot of puckering and scarring in rectovaginal space. Blunt and sharp dissection of rectovaginal space was carried out. Right side ureteral dissection done up to uterosacral ligament so that ureter could be mobilized laterally. Now with the help of harmonic ACE the rectovaginal nodule was excised safely. An unusual located right round ligament adenomyoma noticed which was enucleated and removed. Other endometriotic implants near round ligament were also fulgurated. At the end both tubes and ovaries were seen free from the uterus, bilateral spill seen. Normal tubo-ovarian relationship restored. To combat longstanding dysmenorrhea. Presacral neurectomy done by opening up the peritoneum over the sacral promontory.

PSN: The fibrofatty loose areolar tissue in the presacral space was cleared and presacral nerve is exposed. It is a leash of nerve fibers coming down from the aortic bifurcation. It is lifted up from the sacral promontory and a long segment of nerve is transected. Hemostasis achieved. We have to be careful about the middle sacral vessels which can cause excessive bleeding in this space. Thorough suction irrigation and lavage done.

Energy Source: Bipolar energy source for fulguration of superficial endometriotic implants. Harmonic ACE for excising rectovaginal nodule.

Follow-up: Patient was given active infertility management in the form of ovulation induction in coming cycles.

JAYPEE BROTHERS

Video 3

Laparoscopic Management of Extensive Endometriosis

Nutan Jain

Age: 30 years **ML:** 7 years **Parity**: P 0 + 0

Present Complaints: Primary infertility with congestive dysmenorrhea, dyspareunia and dyschezia since 3 years.

Previous USG: Retroverted enlarged globular uterus and bilateral adherent ovaries. There was a large endometriotic cyst with typical ground glass appearance about 7 × 7 cm in left ovary and a small endometriotic cyst in right ovary.

PV examination: Uterus retroverted and fixed, Puckering and scarring in vaginal fornices, severe tenderness on examination.

Presumptive Diagnosis: Advanced endometriosis, deep infiltrating endometriosis.

Port Placement: Patient laid in modified lithotomy position under GA. Four ports laparoscopy done, all ports are 5 mm except camera port which is 10 mm.

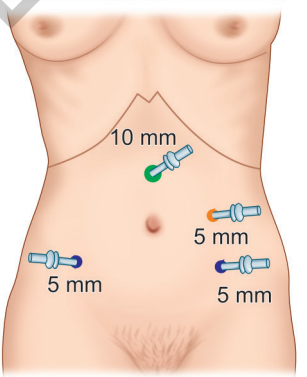

- 1st port—5 mm port at left paraumbilical position on a vertical line drawn up from a point 2.5 cm medial to left ASIS (at Jain point). This is the first blind port, through this the 5 mm 0° telescope is inserted.
- 2nd port—10 mm supraumbilical port inserted under visualization of 5 mm telescope.
- 3rd port—2.5 cm medial and 1 cm above the left ASIS.
- 4th port—2.5 cm medial and 1 cm above the right ASIS.

JAYPEE BROTHERS

Surgical Procedure: On inserting the telescope, adenomyotic uterus seen fixed in pouch of Douglas. Pouch of Douglas totally obliterated. Multiple peritoneal jellies noted which were removed. Bilateral tubes and cystic ovaries were densely adherent to each other, to ovarian fossa, to rectosigmoid, to uterosacral ligament and to pelvic sidewall. Left side big endometriotic cyst noted. Left tube was dilated, stuck to ovary very densely. Very gentle adhesiolysis proceeded. Left big cyst drained of copious amount of chocolate material which was sucked out. To facilitate enucleation a fresh cut was given on the ovarian cyst so that ovarian cortex and cyst wall were differentiated easily. Now the ovarian cortex was held by atraumatic simple grasper and cyst wall picked up by toothed grasper. With gradual traction and counter traction the whole cyst lining enucleated in toto without disturbing the ovarian follicles. Right endometriotic cyst also drained and enucleated. Bilateral salpingo-ovariolysis done. Bilateral tubes and ovaries totally freed. Left ovary temporary suspended to the left anterior abdominal wall using a prolene no. 1 suture material. Rectovaginal space fully cleared. Complete lateral clearing done. On right side, ureteral dissection done up to uterosacral ligament then deep infiltrating endometriotic nodule excised. At end free spill noted through both tubes. Bilateral normal tubo-ovarian relationship restored. Thorough suction irrigation and lavage done. Complete hemostasis achieved.

Energy Source: Bipolar energy source for fulguration of superficial endometriotic implants and for small bleeders.

Follow-up: Patient was given active infertility management in the form of ovulation induction in coming cycles.

JAYPEE BROTHERS

Video 4

Case Reports (Part 1) of Spontaneous Pregnancies Following DIE Excision

Alysson Zanatta

Case 1: BBA **Age:** 36 years **Parity:** P0 + 0

Present Complaints: Primary infertility for 2 years, dysmenorrhea and chronic pelvic pain since 1 year.

Sonography: Deep endometriosis: lesions in the posterior pelvis, including a 2 cm nodule in the rectosigmoid.

Presumptive Diagnosis: Deep infiltrating endometriosis.

Port Placement: Four ports laparoscopy under general and regional anesthesia in modified lithotomy position, all the ports are 5 mm except camera port which is 10 mm.

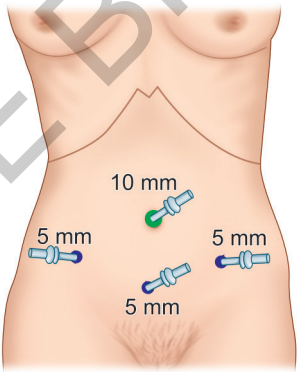

- 1st port—10 mm port inside the umbilicus.
- 2nd port—5 mm suprapubic port in the midline.
- 3rd port—5-mm 2 cm medial to left ASIS.
- 4th port—5-mm 2 cm medial to right ASIS.

Surgical Procedure: Deep endometriosis was identified in the posterior pelvis, leading to a complete cul-de-sac obliteration. The lesion was contiguous to a 2 cm nodule in the rectosigmoid. It is inferior limit situated about 13 cm proximal to the anal border. Besides superficial endometriosis in the left ovary, both adnexa looked normal, and tubes were patent to saline with methylene-blue.

JAYPEE BROTHERS

Both ureters were identified at the level of the pelvic brim, and bilateral ureterolysis was done down to the ureteral tunnels. The uterus and ovaries were suspended with prolene sutures, for better exposure of the posterior pelvis. These sutures were removed after 7 days, to reduce postoperative adhesions. Extensive resection of all endometriotic lesions was done, including partial colpectomy and discoid resection of the rectosigmoid with a circular stapler passed per anus. Postoperative period was marked by transient urinary dysfunction treated with physical therapy.

Energy Source: Bipolar energy delivered by a RoBi Kelly forceps (Karl Storz, Germany), monopolar energy delivered by a hook electrode (Karl Storz, Germany).

Follow-up: Patient got pregnant spontaneously 4 months after surgery. Delivery is expected in two months.

Patient no. 2: LRC **Age:** 30 years **Parity**: P 0 + 0

Present Complaints: Primary infertility for 10 years, dysmenorrhea and chronic pelvic pain for 8 years.

Surgical Antecedents: Two laparotomies for deep endometriosis.

Previous Sonography: Deep infiltrating endometriosis: endometriomas in both ovaries, lesions in the posterior pelvis, including up to 3 nodules in the rectosigmoid.

Presumptive Diagnosis: Deep endometriosis.

Port Placement: Four ports laparoscopy under general and regional anesthesia in modified lithotomy position.

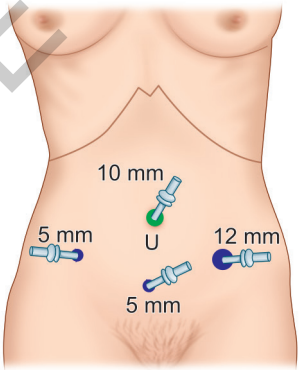

- 1st port—10 mm port inside the umbilicus for the camera.
- 2nd port—5 mm suprapubic port in the midline.
- 3rd port—12-mm 2 cm medial to left ASIS.
- 4th port—5-mm 2 cm medial to right ASIS.

Surgical Procedure: Deep endometriosis was identified in the posterior pelvis, leading to a complete cul-de-sac obliteration. Rectosigmoid was irregular and blocking the pelvis, containing nodules distributed in a segment

JAYPEE BROTHERS

of about 12 cm. Left adnexa was completely distorted, and right tube was congested because of inflammatory reaction around it.

Both ureters were identified at the level of the pelvic brim, and bilateral ureterolysis was done down to the ureteral tunnels. The uterus was suspended with prolene suture, for better exposure of the posterior pelvis. Right cystectomy was done by meticulous draining of endometriomas, without excising pseudocapsule, because of anticipated possibility of premature ovarian failure. Sutures for temporary hysteropexy and oophoropexy were removed after 7 days, to reduce postoperative adhesions. Left adnexectomy was necessary because of advanced disease. Extensive resection of all endometriotic lesions was done, including right salpingolysis, partial colpectomy and segmental resection of the rectosigmoid.

Postoperative period was marked by transient urinary dysfunction and treated with physiotherapy.

Energy Source: Bipolar energy delivered by a RoBi Kelly forceps (Karl Storz, Germany), monopolar energy delivered by a hook electrode (Karl Storz, Germany), and harmonic energy delivered by a ultracision scalpel (Ethicon, United States).

Follow-up: Patient got pregnant spontaneously 3 months after surgery. Delivery is expected in three months.

JAYPEE BROTHERS

Video 5

Case Reports (Part 2) of Spontaneous Pregnancies Following DIE Excision

Alysson Zanatta

Patient no: 1 - SBPL **Age:** 32 years **Parity:** P 0 + 0

Present Complaints: Primary infertility for 18 months; dysmenorrhea, dyspareunia and cyclic pelvic pain on voiding since 2 years.

Previous Sonography: Deep endometriosis: small endometriomas in both ovaries, lesions in the posterior pelvis, 4 cm nodule in the bladder.

Presumptive Diagnosis: Deep infiltrating endometriosis (DIE).

Port Placement: Four ports laparoscopy under general and regional anesthesia in modified lithotomy position.

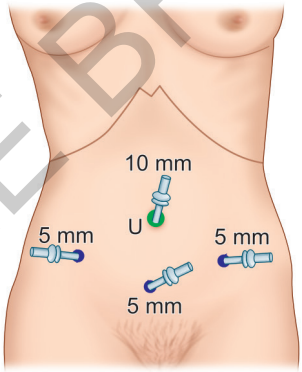

- 1st port—10 mm port inside the umbilicus.
- 2nd port—5 mm suprapubic port in the midline.
- 3rd port—5-mm 2 cm medial to left ASIS.
- 4th port—5-mm 2 cm medial to right ASIS.

Surgical Procedure: Deep endometriosis was identified in the bladder (with a complete anterior cul-de-sac obliteration), and posterior pelvis. Disease was also identified in the appendix and terminal ileum (superficial, non-stenosing lesions). Both adnexae were normal.

Cystoscopy for ureteral catheterization was done in the beginning of the procedure. At laparoscopy, both ureters were identified at the level of the pelvic brim, and bilateral ureterolysis was done down to the ureteral tunnels. Endometriomas were drained. The uterus and ovaries were suspended

JAYPEE BROTHERS

with prolene sutures, for better exposure of the posterior pelvis. Sutures for temporary hysteropexy and oophoropexy were removed after 7 days, to reduce postoperative adhesions. Extensive resection of all endometriotic lesions was done, including partial cystectomy and bladder wall repaired in two layers. Appendectomy was also carried out. Superficial lesions in terminal ileum were not excised.

A Foley's catheter was kept for 10 days, and postoperative period was uneventful.

Energy Source: Bipolar energy delivered by a RoBi Kelly forceps (Karl Storz, Germany), monopolar energy delivered by a hook electrode (Karl Storz, Germany).

Follow-up: Patient got pregnant spontaneously 2 months after surgery. Delivery occurred at 36 weeks, complicated by placenta previa and obstetric hemorrhage. Both patient and newborn were sent home after 7 days.

Patient no: 2 - CMV **Age:** 30 years **Parity**: P 0 + 0

Present Complaints: Primary infertility for 2 years; dysmenorrhea, tenesmus and cyclic rectal bleeding since 1 year.

Previous USG: Deep endometriosis: lesions in the posterior pelvis, left round ligament, and 4 cm nodule in the rectosigmoid.

Presumptive Diagnosis: Deep infiltrating endometriosis (DIE).

Port Placement: Four ports laparoscopy under general and regional anesthesia in modified lithotomy position.

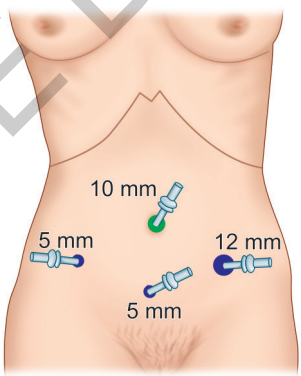

- 1st port—10 mm port inside the umbilicus.
- 2nd port—5 mm suprapubic port in the midline.
- 3rd port—12-mm 2 cm medial to left ASIS.
- 4th port—5-mm 2 cm medial to right ASIS.

Surgical Procedure: Deep endometriosis was identified in the left round ligament, rectosigmoid, tip of the appendix, and posterior pelvis (infiltrating the left inferior hypogastric plexus), leading to a partial left cul-de-sac obliteration. Both adnexae were normal.

JAYPEE BROTHERS

Both ureters were identified at the level of the pelvic brim, and bilateral ureterolysis was done down to the ureteral tunnels. The uterus and ovaries were suspended with prolene sutures, for better exposure of the posterior pelvis. These sutures were removed after 7 days, to reduce postoperative adhesions. Careful neurolysis was done to preserve left inferior hypogastric nerve and plexus. Extensive resection of all endometriotic lesions was done, segmental resection of the rectosigmoid and appendectomy done.

Energy Source: Bipolar energy delivered by a RoBi Kelly forceps (Karl Storz, Germany), monopolar energy delivered by a hook electrode (Karl Storz, Germany), harmonic energy delivered by a ultracision scalpel (Ethicon, United States).

Follow-up: Patient got pregnant spontaneously 2 months after surgery, and delivery occurred at 39 weeks, uneventful pregnancy.

JAYPEE BROTHERS

Video 6

Laparoscopic Management of Endometriotic Cyst

Nutan Jain, Vandana Jain, Monika Ranwa, Ajay Agarwal

Age: 28 years **ML:** 3 years **Parity:** P 0 + 0

Present Complaints: Primary infertility with chronic pelvic pain with congestive dysmenorrhea and dyspareunia since three years.

Sonography: Uterus retroverted and adenomyotic bilateral adherent ovaries with right endometriotic cyst 49 × 32 mm.

Preoperative Diagnosis: Stage IV Endometriosis with ovarian endometrioma.

Port Placement: Patient laid in modified lithotomy position under GA. Four ports laparoscopy done, all ports are 5 mm port except camera port which is 10 mm.

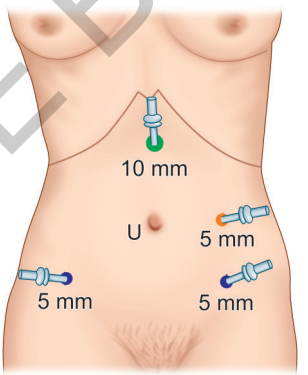

- 1st port—5 mm port at left paraumbilical position on a vertical line drawn up from a point 2.5 cm medial to left ASIS (at Jain point). This is the first blind port, through this the 5 mm 0° telescope is inserted through this.
- 2nd port—10 mm supraumbilical port under direct visualization of 5 mm telescope.
- 3rd port—2.5 cm medial and 1 cm above the left anterosuperior iliac spine.
- 4th port—2.5 cm medial and 1 cm above the right anterosuperior iliac spine.

Surgical Procedure: Uterus retroverted and fixed in pouch of Douglas which is totally obliterated. Right large endometriotic cyst present. Left tube and

JAYPEE BROTHERS

ovary densely adherent in pouch of Douglas. Left ovarian and rectosigmoid adhesions lysed with a blunt and sharp dissection. At this stage, strong Rumi uterine manipulator is used to antevert the uterus along with rectal probe and vaginal sponge to delineate the pouch of Douglas. Right ovary and tube adherent to ovarian fossa. Right ovary dissected from ovarian fossa. Chocolate material drained during adhesiolysis of ovary. Correct plane of cleavage identified between wall of cyst and ovarian tissue. With traction and counter traction, using two 5 mm atraumatic graspers, the inner cyst lining is stripped off from the normal ovarian tissue. Again left ovarian cyst adhesiolysis done from lateral pelvic wall and rectosigmoid. Complete downward rectal mobilization achieved. Normal anatomy of uterus, tubes, ovary and pouch of Douglas restored. Bilateral tubes freely patent.

Energy Source: Harmonic ACE for adhesiolysis and bipolar forceps for any bleeders.

Postoperative Management: Patient was allowed orally after 6 hours and was standing up, walking around, using the washroom and starting active breathing and leg exercises.

Follow-up: Patient is given active infertility management in the form of ovulation induction in coming cycles.

JAYPEE BROTHERS

for detailed information on obstetrics and gynecology books, visit our website www.jaypeebrothers.com, for detailed information

Comprehensive Video Atlas of

Laparoscopic Surgery in Infertility and Gynecology

Salient Features

- This *Video Atlas* is a jewel amongst the existing literature on gynae laparoscopy.
- Most unique, easy-to-learn teaching module in the form of short summary and 75 videos with narration of 8 to 10 minutes duration.
- Videos are thoughtfully selected to represent all possible applications of laparoscopy ranging from Robotics to Single-port and Standard Straight Stick Laparoscopy.
- Special sections to include rare applications like Microsurgery, Urogynecology, Tissue retrieval have found place in this Video Atlas.
- Cosmetic gynecology, the fast emerging field has been thoughtfully included. All routine surgeries like TLH, Myomectomy, Adnexal masses and Endometriosis and Infertility have been covered in an extensive manner.
- Just follow the individual described techniques step by step and you will succeed beautifully in your endoscopy career.
- A must for all those practicing gynae laparoscopy.
- All the surgeries included in the Video Atlas are routinely carried out.



Nutan Jain MS (Obst & Gynae) is Director, Vardhman Trauma & Laparoscopy Centre, Muzaffarnagar (UP), India. She is among the best laparoscopic surgeons the world has known, practicing in Northern India, has been passionate about teaching and propagating laparoscopic surgery through her mini atlas and textbooks on various aspects of laparoscopic surgery like suturing, pelvic floor repair, etc. All her books have been best sellers with translations in Spanish and Chinese. She represents her country with pride in various international conferences as teaching faculty. She has held position in the Board of ISGE and nominated for board of trustees for AAGL. She runs trainings and fellowship programmes at her centre.

Available at all medical bookstores
or buy online at www.jaypeebrothers.com

JAYPEE BROTHERS
Medical Publishers (P) Ltd.
www.jaypeebrothers.com

Join us on facebook.com/JaypeeMedicalPublishers

Shelving Recommendation
OBSTETRICS & GYNECOLOGY

ISBN 978-93-85891-88-5