our website **www.jaypeebrothers.com,** for detailed information on anatomy books, visit our website **www.jaypeebrothers.com**

First Illustrative Practice Manual of Surface & Radiological Anatomy

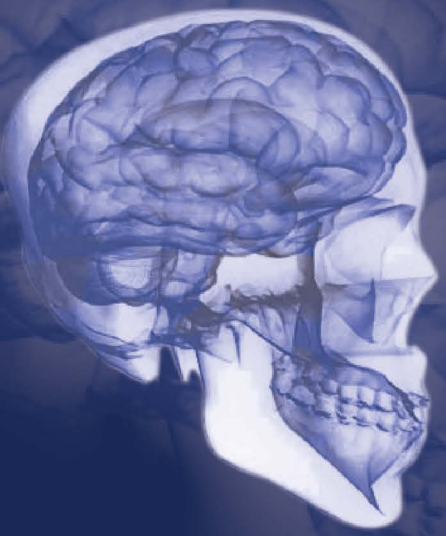

Illustrative Practice Manual of Surface and Radiological ANATOMY


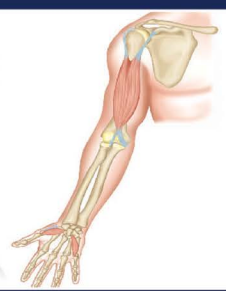
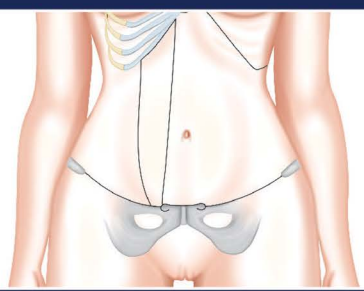




HIGHLIGHTS

- Simple and easy-to-mark illustrations
- Covers the clinically important areas of the curriculum/syllabus
- Concise introduction of important surface landmarks, markings, and projection of deeper structures
- Important points for examination purposes are highlighted
- Student-friendly approach to learning
- Relevant Radiographs, CTs, and MRIs are incorporated for the students to easily sail through the examinations and gain useful and up-to-date knowledge
- Aim of this book is to develop practical skills for undergraduates and postgraduates
- Consists of seven sections covering all the important aspects of the relevant Surface Anatomy and Radiology for the undergraduate and postgraduate students of Anatomy, as well as Dental, Nursing, Occupational and Physiotherapy students.

Anita Tuli
Shashi Raheja
Sneh Agarwal

JAYPEE

Contents

1. Upper Limb 1–28

Landmarks of Upper Limb 2
The Back 6
Relationship of Vertebral Spines with other Landmarks 6
Surface Marking 10
Nerves of the Upper Limb 14
Palpable Pulses of Upper Limb 22
Palpable Nerves of Upper Limb 22
Retinacula 22

2. Lower Limb 29–56

Bony Landmarks in the Inguinal Region 30
Bony Landmarks in the Lower Limb 30
Vessels and Nerve in Front of the Thigh 38
Femoral Artery 38
Femoral Vein 38
Femoral Nerve 38
Femoral Ring 38
Great Saphenous Vein 38
Nerves at the Back of the Lower Limb 42
Front of the Leg and Dorsum of the Foot 46
Back of the Leg and Sole 46
Palpable Pulses of the Lower Limb 50
Sites of Readily Palpable Nerves 50
Planes 54

3. Head & Neck and Brain 57–96

Surface Landmarks 58
Skull 62
Bony Landmarks of Neck 66
Pulsations Felt 66
Arteries in the Head & Neck and Face 70
In Neck 82
In Face 82
Maxillary Artery 82
Veins of Head and Neck 82
Nerves of Head and Neck 86
Parotid Salivary Gland 90
Submandibular Gland 94

4. Thorax 97–120
Surface Landmarks 98
Front of Thorax 98
Importance of Sternal Angle 98
Imaginary Lines of Thorax 98
Pleura 102
Cervical Pleura 102
Costomediastinal Pleura: Different on Both Sides 102
Costodiaphragmatic Pleura 102
Lungs 102
Heart 110
Atrioventricular Groove 110
Orifices of the Heart 110
Trachea 118
Esophagus 118

5. Abdomen and Pelvis 121–156
Important Surface Landmarks 122
Umbilicus 126
Planes and Lines of the Anterior Abdominal Wall 126
Vertical Lines 126
Horizontal Planes 126
Quadrants of Abdomen 130
Arteries of the Abdomen 130
Veins of the Abdomen 134
Inguinal Region 134
The Viscera 138
Stomach 138
Duodenum 138
The Liver 146
Pancreas 146
Spleen 150
Gallbladder 150
Bile Duct 150
Kidneys 150
Ureter 154

6. Skull and Bones 157–196
Development of Skull 158
Mandible 162
Sternum 162
Vertebrae 168
Sacrum 176
Vertebral Curvatures 176
Ossification 180

7. Radiology, CT and MRI 197–243

BONY LANDMARKS IN THE INGUINAL REGION (FIG. 1)

1. **Pubic symphysis:** Joint in the midline between the right and left pubic bones.
2. **Pubic crest:** Felt lateral to pubic symphysis.
3. **Pubic tubercle:** Prominence at lateral end of pubic crest, 2.5 cm from pubic symphysis.
4. **Iliac crest:** Felt along its entire length, in the lower waist. Anterior superior iliac spine is felt at its anterior end and posterior superior iliac spine is indicated by a dimple, 4 cm lateral to the second spinous tubercle of the sacrum.
5. **Anterior superior iliac spine:** Prominence at lateral end of groin.
6. **Tubercle of the iliac crest:** Prominence felt on the outer border of the iliac crest 5 cm posterior to the anterior superior iliac spine at L5 V vertebra.
7. **Highest point of the iliac crest:** Lies at level of L3–L4 spines.
8. **Inguinal ligament (Fig. 2):** Between anterior superior iliace spine and pubic tubercle.
9. **Posterior superior iliac spine (Figs. 2 and 3):** Dimple at S2 vertebra level to the back 5 cm from midline.

BONY LANDMARKS IN THE LOWER LIMB (FIG. 2)

10. **Greater trochanter:** Felt as a prominence hand's breadth below the tubercle of the iliac crest.

    Nelaton's line: In a normal subject in anatomical position, draw a line joining anterior superior iliac spine and the ischial tuberosity. This line passes across the upper border of the greater trochanter and the center of the acetabulam. It is of clinical importance (Fig. 1 in radiology).
11. **Natal cleft:** Cleft between the buttocks.

Task: Identify the indicated bony landmarks

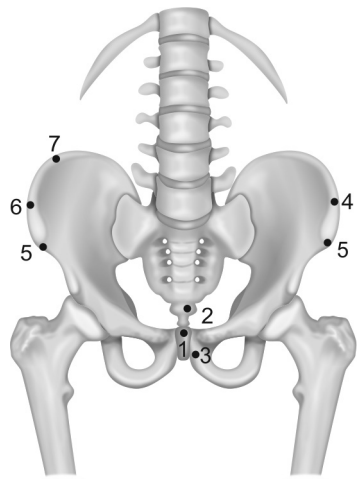

Fig. 1: Anterior view of pelvis and lower limb.

Task:
1. Identify the indicated landmarks
2. Label inguinal ligament

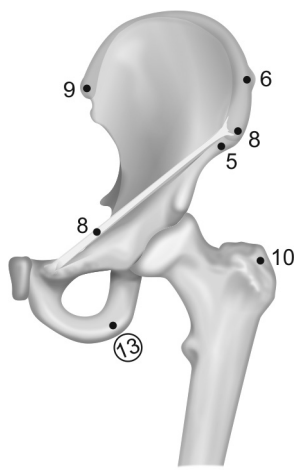

Fig. 2: Anterior view of left hip bone and femur.

12. **Gluteal fold:** Lower border of the buttocks **(Fig. 3)**.
13. **Ischial tuberosity:** Palpated in the lower part of buttocks.
    5 cm from median plane and 5 cm above gluteal fold **(Fig. 2)**.
14. **Head of the femur (Figs. 4A and B):** Felt 2.5 cm below midpoint between anterior superior iliac spine and the pubic symphysis. Pulsation of femoral artery can be felt here.
15. **Patella:** Felt and seen in front of the knee joint in standing position.
16. **Condyles of the femur:** Prominent ridges at the sides of the patella in flexed knee.
17. **Adductor tubercle:** Abduct and laterally rotate the thigh. Felt as a projection at the uppermost part of the medial condyle of femur.
18. **Tuberosity of the tibia:** 5 cm below the patella in the flexed knee at the upper end of anterior border of tibia.
19. **Condyles of the tibia:** Felt on each side of the ligamentum patellae in flexed knee.
20. **Knee joint:** Line between femoral and tibial condyles.
21. **Head of the fibula:** Felt 2 cm below the level of the knee joint on posterolateral aspect of knee.
22. **Medial malleolus:** Visible prominence on medial side of the ankle.
23. **Lateral malleolus:** Visible prominence on the lateral side of the ankle 1.25 cm lower than medial malleolus.
24. **Peroneal tubercle:** 2.5 cm below the tip of the lateral malleolus.
25. **Sustentaculum tali:** 2.5 cm below the tip of the medial malleolus.
26. **Tuberosity of the navicular:** Felt 2.5 cm below and in front of the medial malleolus.
27. **Tubercle of the base of the 5th metatarsal:** Felt halfway along the lateral border of the foot **(Figs. 4A and B)**.

Task: Identify the indicated landmarks

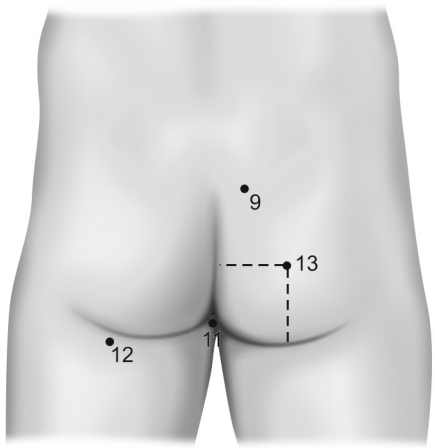

Fig. 3: Posterior view of the gluteal region.

Task: Identify the indicated landmarks

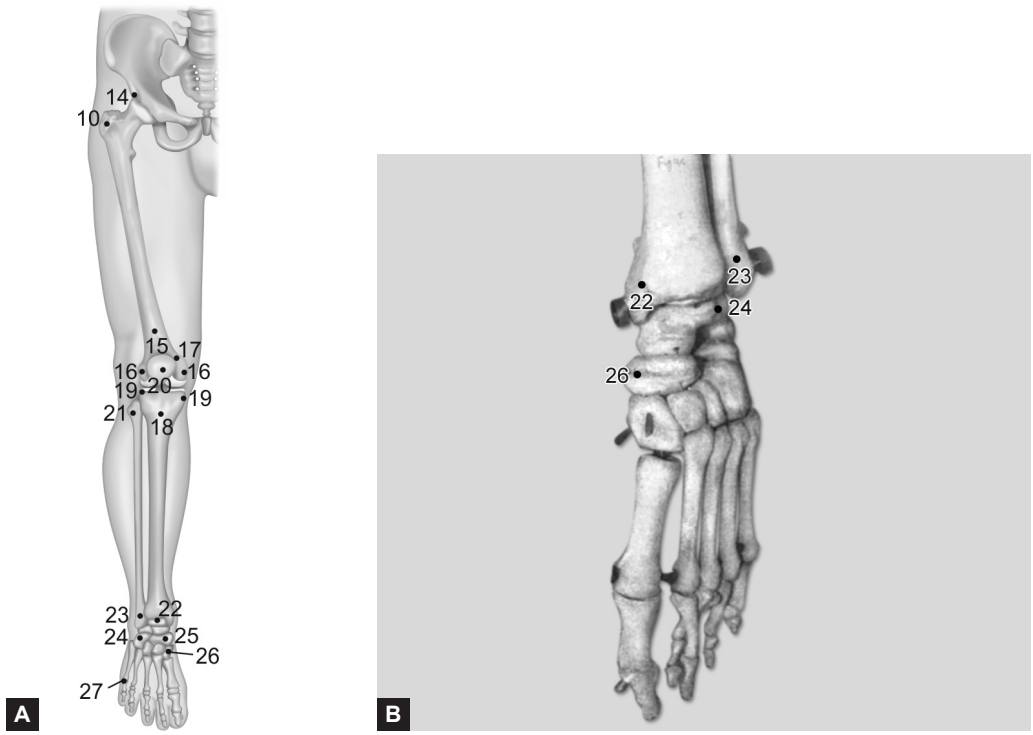

Figs. 4A and B: (A) Anterior view of lower limb with foot; (B) Anterior view of bones of left foot and ankle.

VESSELS AND NERVE IN FRONT OF THE THIGH (FIG. 5)

Femoral Artery

Mark the following points:

a. **Midinguinal point (Fig. 5):** A midpoint between anterior superior iliac spine and upper end of the pubic symphysis. Femoral pulse is felt 1.25 cm below it and deep inguinal ring lies 1.25 cm above it.

b. **Adductor tubercle:** Upper 2/3rd of line joining a and b represents femoral artery, upper 1/3 in femoral triangle and middle 1/3 in adductor canal.

Femoral Vein (Fig. 5)

The femoral vein is posterolateral to the artery in the adductor canal. It crosses behind the artery and lies on the medial side of femoral artery in the femoral triangle.

Femoral Nerve (Fig. 5)

c. Take a point 1.2 cm lateral to the midinguinal point.

d. 2.5 cm below point c, join c and d.

Femoral Ring (Fig. 5)

Lies 1 cm medial to the midinguinal point, deep to the inguinal ligament.

Great Saphenous Vein (Fig. 6)

Mark the following points:

a. Medial end of dorsal venous arch.

b. 2.5 cm in front of medial malleolus.

c. Hand breadth behind, medial border of patella at knee joint.

d. Saphenous opening 4 cm below and lateral to pubic tubercle.

Join a, b, c, d.

Task:
Mark the femoral ring, femoral nerve femoral artery, femoral vein

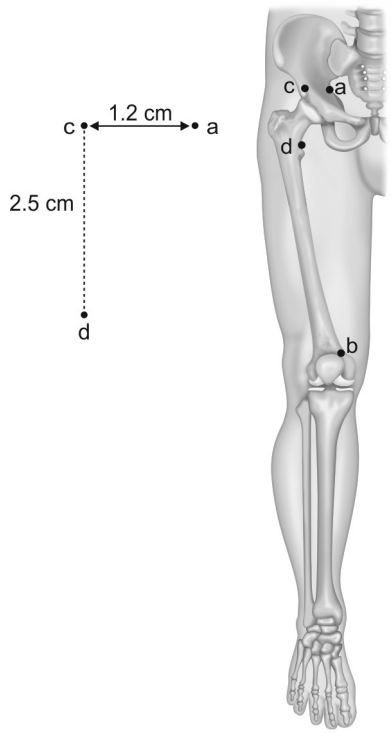

Fig. 5: Anterior view of thigh, leg and dorsum of foot.

Task:
Draw great saphenous vein

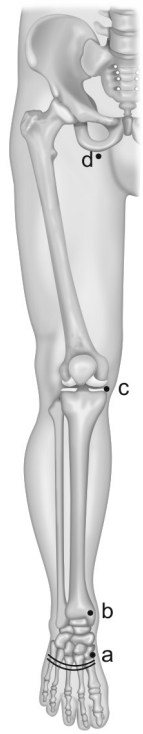

Fig. 6: Anterior view of lower limb.

NERVES AT THE BACK OF THE LOWER LIMB

Sciatic nerve (Fig. 7)

Identify: Posterior superior iliac spine, ischial tuberosity and tip of greater trochanter.

a. 2.5 cm lateral to midpoint of a line joining the posterior superior iliac spine to the ischial tuberosity.
b. Medial to the midpoint of a line joining the tip of the greater trochanter and the ischial tuberosity.
c. Midpoint of the junction of the middle and lower third of the back of the thigh.

Join a, b, c by two parallel lines 2 cm apart.

Common peroneal nerve (Fig. 7): *Mark two points*

c. Midpoint of the line on the back of the thigh at the junction of its upper two-thirds with its lower one-third.
d. The neck of the fibula.

Join c and d by a line which runs along the medial border of the biceps femoris tendon.

Tibial nerve in popliteal fossa (Fig. 7): *Mark two points*

c. Midpoint of the line drawn on the back of the thigh at the junction of its upper two-thirds and lower one-third.
e. Midpoint of a transverse line drawn on the back of the leg at the level of the tibial tuberosity.

Join points c and e.

Deep peroneal nerve (Fig. 7): *Mark three points*

d. On the lateral surface of the neck of the fibula.
f. 5 cms below the medial side of head of the fibula.
g. Midpoint between the two malleoli.

Join d, f, and g points.

Popliteal artery (Fig. 8): *Mark three points*

a. 2.5 cm medial to the midpoint of a transverse line at the junction of proximal two-third and distal one-third of back of thigh.
b. At the middle of the back of the knee (between two femoral condyles).
c. Midpoint of the transverse line on the back of the leg at the level of the tibial tuberosity.

Join a, b, c by two parallel lines.

Posterior tibial artery and posterior tibial nerve (Fig. 8): *Take two points*

c. Midpoint of the transverse line drawn on the back of the leg at the level of the tibial tuberosity.
d. A point midway between the medial border of the tendocalcaneus and the posterior border of the medial malleolus.

Join points c and d.

Tibial nerve crosses behind the artery from medial to lateral side.

Task: *Mark the following nerves*
1. Sciatic
2. Tibial
3. Common peroneal
4. Deep peroneal nerves

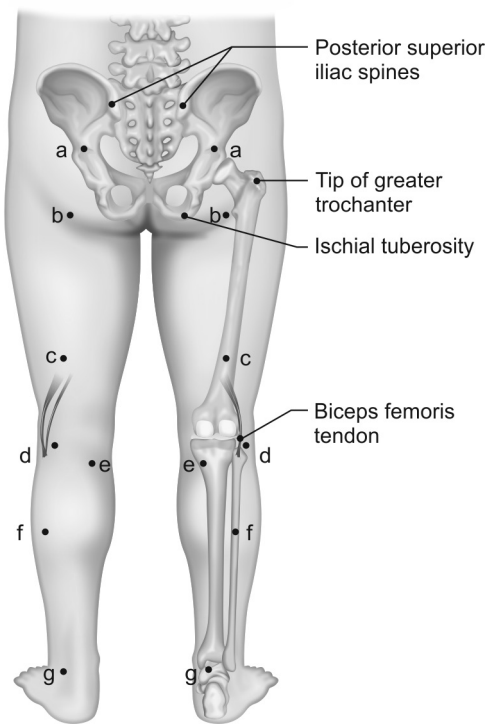

Fig. 7: Posterior view of back and lower limb.

Task: *Mark the following nerves*
1. Popliteal artery
2. Posterior tibial artery
3. Tibial nerve

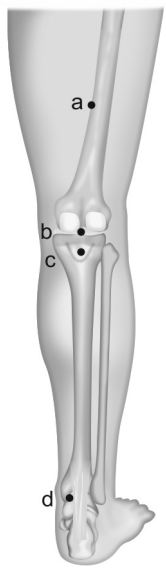

Fig. 8: Back of leg.

FRONT OF THE LEG AND DORSUM OF THE FOOT

Anterior tibial artery (Fig. 9): *Mark two points*

a. 2.5 cms below the medial side of the head of the fibula.
b. Midpoint between the two malleoli.

Join points a and b.

Dorsalis pedis artery (Fig. 9): *Mark two points*

b. Midpoint between the two malleoli in front of the ankle.
c. Proximal end of the first intermetatarsal space.

Join b and c points.

BACK OF THE LEG AND SOLE

Medial plantar artery and medial plantar nerve (Fig. 10): *Mark two points*

d. Midpoint of line joining medial border of the tendocalcaneus and the posterior border of the medial malleolus.
e. The cleft between first and second toes as far as the navicular bone.

Join d and e points.

Lateral plantar artery (Fig. 10): *Mark two points*

d. Midpoint of line joining medial border of the tendocalcaneus and the posterior border of the medial malleolus.
f. 2.5 cm medial to the tuberosity of the fifth metatarsal.

Join d and f points.

From point f, a line drawn with a slight forward convexity to the proximal end of the first metatarsal space.

Task: *Mark*
1. Anterior tibial artery
2. Dorsalis pedis artery

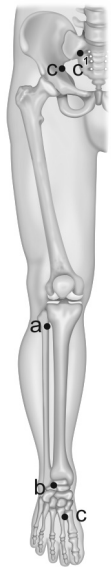

Fig. 9: Front of leg and dorsum of foot.

Task: *Mark*
1. Medial plantar artery and nerve (d, e)
2. Lateral plantar artery and nerve (d, f)

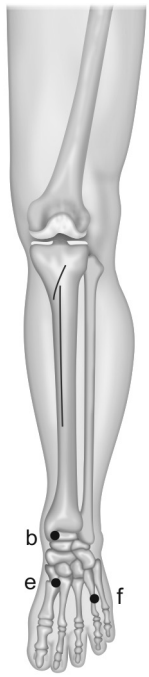

Fig. 10: Back of leg and sole.

PALPABLE PULSES OF THE LOWER LIMB (FIG. 11)

1. Femoral artery can be felt 1.25 cm below the midinguinal points.
2. Popliteal artery can be felt deep in the middle of the popliteal fossa, in flexed knee.
3. Dorsalis or pedis artery is felt midway between the malleoli to the proximal end of the first intermetatarsal space.
4. Posterior tibial artery is felt just behind the medial malleolus midway between it and the Tendo calcaneus.

SITES OF READILY PALPABLE NERVES

Common peroneal nerve: The common peroneal nerve can be felt just below the head of the fibula on lateral side of the neck of the fibula. Palpated through the skin at the back of the lateral femoral condyle medial to tendon of Biceps femoris.

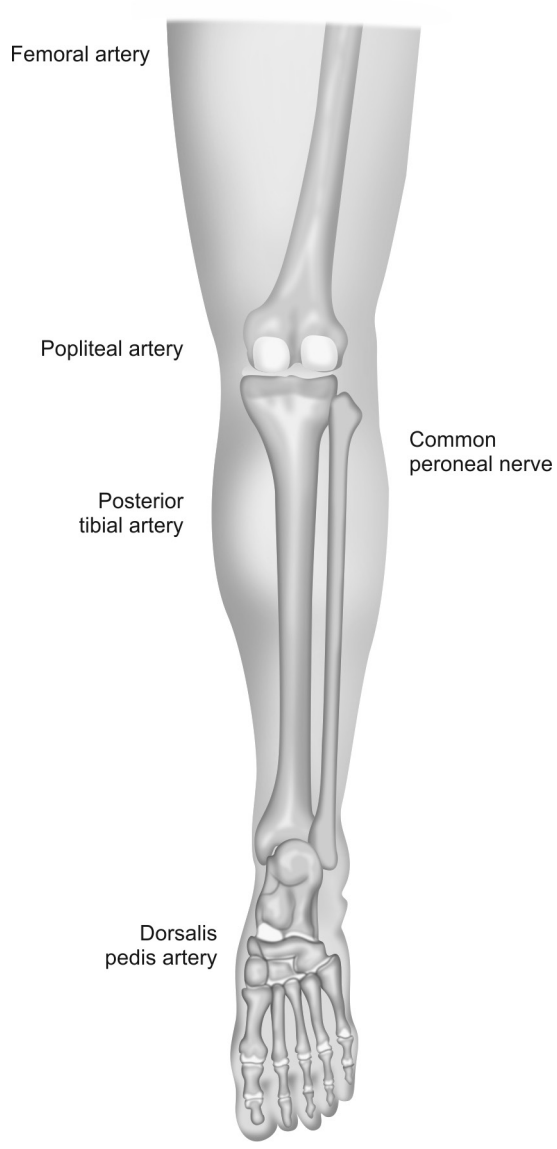

Fig. 11: Arterial pulsations of lower limb.

for detailed information on anatomy books, visit our website **www.jaypeebrothers.com,** for detailed information on anatomy bo

Illustrative Practice Manual of Surface and Radiological ANATOMY

This manual is an educational aid designed to facilitate medical students in understanding anatomy. Our objective is to induce a student to think, to recall and cultivate skills towards knowledge of anatomy. The emphasis is on achieving a better grasp to the subject of Surface and Radiological Anatomy. The challenges of studying these subjects have been simplified by illustrations.

The manual contains:

- The surface anatomy diagrams that show important anatomical landmarks related to surface structures and clinical points. The illustrations have been intentionally left unfinished so that the students can practice and complete them after acquiring sufficient knowledge
- Plain radiographs, MRI and CT scans pertinent from examination point of view have been incorporated
- Questions and discussions based on clinical applications of Anatomy will reinforce anatomical knowledge and cover the syllabus, which will help the students sail through the examinations.

Anita Tuli is Director, Professor and Head, Department of Anatomy, Lady Hardinge Medical College, New Delhi, India. She joined this institution after completing her graduation and postgraduation from University College of Medical Sciences, New Delhi. Dr Tuli is a revered teacher with keen interest in research. She has a number of scientific publications in national and international journals to her credit. Dr Tuli has been in the field of anatomy for the last 38 years and has taught the undergraduate and postgraduate medical students as well as occupational therapy/physiotherapy and nursing students. She is an erudite teacher with vast teaching experience. Interaction with students makes her immensely popular and always in demand.



Shashi Raheja is Director, Professor, Department of Anatomy, Lady Hardinge Medical College, New Delhi, India. She is a graduate and postgraduate from the same renowned institution and has distinguished herself as a very enthusiastic teacher, well loved and respected by her students. Dr Raheja is a fellow of International Medical Science Academy, New Delhi, and has a number of publications in national and international journals. She takes keen interest in the teaching program and is excellent with her cadaveric dissections. Dr Raheja has been in the field of anatomy for the last 34 years and is involved in teaching of undergraduate and postgraduate medical students, occupational therapy/physiotherapy and nursing students.



Sneh Agarwal, Professor, Department of Anatomy, Lady Hardinge Medical College, New Delhi, India, has over two decades of teaching experience in the subject. She has a vast research experience and has published over 50 research papers in indexed International Journals of Basic and Clinical Sciences. Dr Agarwal is on the review panels of the prestigious national and international publishing houses. She is considered as a medical teacher par excellence by her students.



Available at all medical bookstores
or buy online at www.jaypeebrothers.com

JAYPEE BROTHERS
Medical Publishers (P) Ltd.
www.jaypeebrothers.com

Join us on facebook.com/JaypeeMedicalPublishers

Shelving Recommendation
ANATOMY

ISBN 978-93-85999-15-4