rothers.com, for detailed information on anatomy books, visit our website www.jaypeebrothers.com, for detailed information on anatomy books

JAYPEE

Exam Preparatory Manual for Undergraduates

ANATOMY

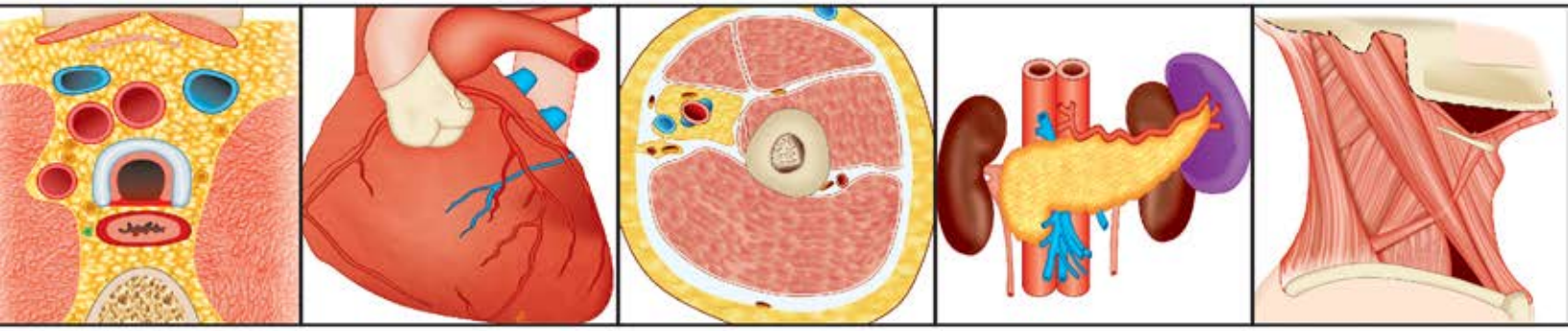

Harishanker JS
Ajai Sasi
Avinash N

Highlights

Sections: 1–6 Theory

Section 1: Upper Limb
Section 2: Lower Limb
Section 3: Thorax
Section 4: Abdomen and Pelvis
Section 5: Head and Neck
Section 6: Neuroanatomy

Red Alert (Selected Topics)

Quick Glance (Important Diagrams)

Contents

Section 1: Upper Limb

1. Introduction **1**
- Homologous parts shared by upper limb and lower limb *03*
- Parts of upper limb *03*

2. Pectoral Region **4**
- Superficial fascia of the pectoral region *04*
- Breast *04*
- Clavipectoral fascia *07*
- Pectoralis major muscle *07*
- Serratus anterior muscle *08*

3. Axilla **10**
- Axilla *10*

4. Back of the Body **12**
- Skin and fascia of the back *12*
- Muscles connecting upper limb with the vertebral column *12*

5. Scapular Region **14**
- Deltoid muscle *14*
- Muscles around the scapula *14*
- Rotator cuff/musculocutaneous cuff *15*
- Subacromial bursa *15*
- Intermuscular spaces *16*

6. Arm **18**
- Fascial compartments of arm *18*
- Anterior compartment of arm *18*
- Biceps brachii *18*
- Coracobrachialis and brachialis *18*
- Insertion of coracobrachialis—anatomical peculiarities *19*
- Cubital fossa *19*
- Posterior compartment of the arm *20*
- Triceps brachii muscle *20*

7. Antebrachium/Forearm **22**
- Fascial compartments of forearm *22*
- Contents of front of forearm *22*

- Muscles of anterior compartment *22*
- Contents of back of forearm *24*
- Muscles of posterior compartment of arm *24*

8. Wrist and Hand **27**
- Skin and superficial fascia of the palmar aspect of the hand *27*
- Flexor retinaculum *27*
- Palmar aponeurosis *28*
- Fibrous flexor sheath of fingers *28*
- Intrinsic muscles of hand *29*
- Spaces of hand *30*
- Mid palmar space of hand *31*
- Thenar space of hand *31*
- Pulp spaces of fingers *31*
- Dorsum of hand *31*
- Extensor retinaculum *32*
- Dorsal digital expansion *32*
- Anatomical snuff box *32*

9. Joints of Upper Limb **34**
- Shoulder joint complex—concept *34*
- Shoulder joint/glenohumeral joint *34*
- Abduction at shoulder joint *36*
- Elbow joint *36*
- Carrying angle *37*
- Superior and inferior radioulnar joints *38*
- Wrist joint/radiocarpal joint *38*
- First carpometacarpal joint *39*

10. Blood Supply and Lymphatic Drainage of Upper Limb **41**
- Arterial supply of upper limb—outline *41*
- Axillary artery *41*
- Anastomosis around scapula *42*
- Brachial artery *43*
- Anastomosis around elbow joint *44*
- Radial artery *44*
- Ulnar artery *44*
- Superficial palmar arch *45*
- Deep palmar arch *45*
- Venous drainage of upper limb—outline *46*
- Main superficial veins of upper limb *46*
- Lymphatic drainage of upper limb *47*

11. Nerves of Upper Limb **49**
- Nerve supply of upper limb *49*
- Brachial plexus, Erb's and Klumpke's paralysis *49*
- Axillary nerve *51*
- Musculocutaneous nerve *52*

- Radial nerve *52*
- Ulnar nerve *54*
- Median nerve *56*
- Cutaneous supply of upper limb *59*
- Dermatomes of upper limb *60*

Section 2: Lower Limb

12. Introduction **65**
- Related terms in lower limb *65*

13. Front of Thigh **66**
- Superficial fascia of front of thigh *66*
- Deep fascia of thigh/fascia lata and its modifications *66*
- Femoral triangle *67*
- Femoral sheath *68*
- Femoral canal *68*
- Muscles of front of thigh *68*
- Adductor/hunters/subsartorial canal *70*

14. Medial Side of Thigh **72**
- Medial side of thigh with its boundaries and contents *72*
- Muscles of adductor compartment of thigh *72*
- Adductor magnus muscle *72*
- Pectineus muscle *73*

15. Gluteal Region **75**
- Gluteal region—outline *75*
- Muscles of gluteal region *75*
- Gluteus maximus muscle *76*
- Structures undercover gluteus maximus *76*
- Gluteal ligaments *79*

16. Back of Thigh **80**
- Back of thigh boundaries and contents *80*
- Hamstring muscles *80*
- Rest of muscles of posterior compartment of thigh *81*
- Cross section at the level of mid-thigh *82*
- Popliteal fossa *83*

17. Leg and Dorsum of Foot **84**
- Superficial, deep fascia of leg and fascial compartments *84*
- Extensor retinaculum *84*
- Muscles of dorsum of foot *85*
- Lateral compartment of leg *86*
- Peroneal retinaculum *86*
- Guy ropes *87*
- Anserine bursa *87*

- Posterior compartment of leg *87*
- Flexor retinaculum *87*
- Muscles of posterior compartment of leg *88*

18. Sole of Foot **91**
- Sole of foot—outline *91*
- Muscles of sole of foot *91*
- Arches of foot *92*

19. Joints of Lower Limb **95**
- Hip joint *95*
- Knee joint *98*
- Deltoid ligament *104*
- Inversion and eversion of the foot *104*

20. Blood Supply and Lymphatic Drainage of Lower Limb **106**
- Femoral artery *107*
- Profunda femoris artery *108*
- Obturator artery *108*
- Medial circumflex femoral artery *109*
- Popliteal artery *109*
- Anterior tibial artery *110*
- Posterior tibial artery *110*
- Medial plantar artery, lateral plantar artery and plantar arch *110*
- Venous drainage of lower limb—outline *111*
- Great saphenous vein *113*
- Short saphenous vein *113*
- Femoral vein *114*
- Perforator veins *114*
- Lymphatic drainage of lower limb *114*

21. Nerve Supply of Lower Limb **116**
- Nerve supply of lower limb—outline *116*
- Femoral nerve *116*
- Obturator nerve *117*
- Sciatic nerve *117*
- Common peroneal nerve *119*
- Tibial nerve *119*
- Cutaneous innervation of lower limb *120*
- Dermatomes of lower limb *122*

Section 3: Thorax

22. Wall of Thorax and Thoracic Cavity **127**
- Thoracic cage *127*
- Thoracic inlet *127*
- Thoracic outlet *128*
- Scalene triangle *128*

- Diaphragm *128*
- Intercostal space *130*
- Internal thoracic artery *132*
- Azygos vein *133*
- Hemiazygos vein *134*
- Accessory hemiazygos vein *134*
- Thoracic sympathetic trunk *134*

23. Pleurae **137**
- Pleural cavities and pleura *137*
- Pulmonary ligament *138*
- Pleural recess *138*

24. Lungs **140**
- Lobes and fissures *140*
- Hilum *140*
- Mediastinal surface of lungs *141*
- Development of lungs *142*
- Root of lung *143*
- Bronchopulmonary segments *143*

25. Mediastinum **146**
- Boundaries of mediastinum *146*
- Superior mediastinum *146*
- Inferior mediastinum *147*

26. Pericardium and Heart **149**
- Pericardium *146*
- Sinuses of pericardium *150*
- External features of heart *150*
- Development of heart tube *152*
- Right atrium *152*
- Interatrial septum *153*
- Left atrium *154*
- Ventricles *154*
- Valves of the heart *155*
- Interventricular septum *156*
- Blood supply of heart *156*
- Veins of the heart *158*
- Cardiac plexuses *159*
- Lymphatic drainage of heart *160*
- Conduction system of heart *160*
- Fetal circulation *160*

27. Superior Vena Cava and Aorta **162**
- Superior vena cava *162*
- Aorta *163*
- Aortic sinuses *163*

28. Trachea, Esophagus and Thoracic Duct **166**
- Esophagus *166*
- Thoracic duct *168*
- Trachea *169*

Section 4: Abdomen and Pelvis

29. Anterior Abdominal Wall **175**
- Abdominal cavity *175*
- Abdominal planes and quadrants *175*
- Anterior abdominal wall *176*
- Rectus sheath *180*
- Fascia transversalis *181*
- Inguinal canal *181*
- Hesselbach's triangle *183*
- Inguinal hernia *183*

30. Male Genital Organs **185**
- Testis *185*
- Vas deferens *187*

31. Abdominal Cavity and Peritoneum **190**
- Greater omentum *190*
- Lesser omentum *190*
- Mesentery *191*
- Transverse mesocolon *191*
- Sigmoid mesocolon *192*
- Peritoneal cavity—greater sac and lesser sac *192*
- Epiploic foramen *193*
- Morrison's pouch *194*
- Rectouterine pouch *194*

32. Stomach **196**
- External features of stomach *196*
- Traube's space *197*
- Stomach bed *197*
- Interior of stomach *198*
- Development of stomach *199*

33. Small and Large Intestines **201**
- Duodenum *201*
- Duodenal cap *204*
- Ligament of Treitz *204*
- Jejunum and ileum *205*
- Cecum *206*
- Vermiform appendix *207*
- Colon *208*
- Meckel's diverticulum *210*

34. Spleen, Pancreas and Liver **211**
- Spleen *211*
- Vascular segments of spleen *212*
- Pancreas *213*
- Ducts of pancreas *214*
- Development of pancreas and pancreatic duct *215*
- Liver *216*
- Hepatic segments of Couinaud *217*
- Development of liver and gallbladder *219*

35. Biliary Apparatus **220**
- Biliary apparatus *220*
- Gallbladder *220*
- Cystic duct *221*
- Common bile duct *222*
- Blood supply, lymphatic drainage and nerve supply *222*
- Calot's triangle *222*

36. Kidney, Ureter and Suprarenal Gland **224**
- Kidney *224*
- Morrison's parallelogram *226*
- Vascular segments of kidney *226*
- Development of kidney *227*
- Suprarenal glands *227*
- Ureter *228*

37. Posterior Abdominal Wall **231**
- Thoracolumbar fascia *231*
- Psoas major *231*
- Psoas sheath *232*
- Cisterna chyli *232*

38. Urinary Bladder and Urethra **234**
- Urinary bladder *234*
- Trigone of bladder *236*
- Development of urinary bladder *237*
- Male urethra *237*
- Female urethra *238*

39. Male and Female Reproductive Organs **240**
- Prostate *240*
- Age changes in the prostate *243*
- Development of prostate *243*
- Uterus *243*
- Development of uterus *246*
- Uterine tubes *246*

40. Perineum and True Pelvis **248**
- Perineum *248*
- Urogenital and anal triangle *248*

- Superficial perineal pouch *248*
- Deep perineal pouch *249*
- Urogenital diaphragm *249*
- Perineal membrane *250*
- Perineal body *250*
- Pudendal canal *251*
- Pelvic diaphragm *251*
- Ischiorectal fossa *252*
- Celiac ganglion *252*
- Celiac plexus *253*
- Sacral plexus *253*

41. Rectum and Anal Canal **255**
- Rectum *255*
- Anal canal *257*
- Development of rectum and anal canal *260*

42. Large Blood Vessels of the Gut **261**
- Portal vein *261*
- Portocaval anastomoses *262*
- Internal iliac artery *263*
- Celiac trunk *264*
- Superior mesenteric artery *264*
- Inferior mesenteric artery *265*

Section 5: Head and Neck

43. Scalp, Temple and Face **269**
- Surface landmarks *269*
- Layers of scalp *269*
- Blood supply of scalp and superficial temporal region *270*
- Nerve supply of scalp and superficial temporal region *271*
- Muscles of face *272*
- Nerve supply of face *274*
- Venous drainage of face *275*
- Lymphatic drainage of face *275*
- Lacrimal apparatus *276*

44. Side of Neck **279**
- Surface landmarks *279*
- Deep cervical fascia *279*
- Carotid sheath *282*
- Posterior triangle of neck *282*
- Sternocleidomastoid *284*

45. Structures in Anterior Median Region of Neck **286**
- Structures in anterior median region of neck *286*
- Anterior triangle of neck *286*

46. Deep Structures of Neck **290**
- Thyroid gland *290*
- Parathyroid glands *293*
- Thymus *294*
- Lymph nodes of head and neck *294*
- Scalene muscles *296*
- Cervical pleura *297*
- Styloid apparatus *297*

47. Back of Neck **299**
- Muscles of back *299*
- Suboccipital triangle *300*

48. Parotid Region **302**
- Parotid gland *302*

49. Submandibular Region **305**
- Suprahyoid muscles *305*
- Submandibular salivary gland *306*
- Sublingual gland *308*

50. Temporal and Infratemporal Region **310**
- Temporal fossa, infratemporal fossa, pterygopalatine fossa *310*
- Muscles of mastication *311*
- Relations of medial and lateral pterygoid *312*
- Temporomandibular joint *312*

51. Nose and Paranasal Sinuses **316**
- Nose and nasal septum *316*
- Lateral wall of nose *317*
- Maxillary sinus *319*

52. Contents of Orbit and Eye **321**
- Orbital fascia and bulbar fascia *321*
- Extraocular muscles *321*
- Actions of extraocular muscles *323*

53. Ear **325**
- Tympanic membrane *325*
- Middle ear *326*
- Ear ossicles and muscles *327*
- Mastoid antrum *328*
- Internal ear *328*
- Auditory tube/Eustachian tube *331*

54. Oral Cavity and Tongue **333**
- Hard palate *333*
- Soft palate *334*
- Muscles of soft palate *334*
- Passavant's ridge *335*
- Tongue *335*
- Muscles of tongue *338*

55. Pharynx **340**
- Pharynx *340*
- Palatine tonsil *341*
- Constrictor muscles of pharynx *343*
- Killian's dehiscence *344*

56. Larynx **345**
- Larynx *345*
- Cartilages of larynx *346*
- Muscles of larynx *347*
- Cavity of larynx *348*

57. Vertebral Canal and Contents **350**
- Vertebral canal and its contents *350*
- Vertebral venous plexus *350*

58. Cranial Cavity **352**
- Cerebral dura mater *352*
- Intracranial dural venous sinuses *353*
- Cavernous sinus *354*
- Superior sagittal sinus *355*
- Sigmoid sinus *355*
- Hypophysis cerebri *355*

59. Blood Vessels of Head and Neck **357**
- Common carotid artery *357*
- External carotid artery *358*
- Facial artery *359*
- Occipital artery *360*
- Maxillary artery *360*
- Internal carotid artery *362*
- Ophthalmic artery *363*
- Subclavian artery *364*
- Thyrocervical trunk *365*
- Vertebral artery *366*
- Subclavian vein *367*
- External jugular vein *368*
- Internal jugular vein *368*
- Brachiocephalic vein *369*
- Ophthalmic veins *369*

60. Nerves of Head and Neck **371**
- Ansa cervicalis/ansa hypoglossi *371*
- Cervical part of sympathetic trunk *371*
- Cervical plexus *372*
- Phrenic nerve *373*
- Greater occipital nerve *374*
- Submandibular ganglion *374*
- Mandibular nerve *375*

- Maxillary nerve *378*
- Otic ganglion *378*
- Pterygopalatine ganglion *378*
- Ciliary ganglion *379*
- Nasociliary nerve *380*
- Trigeminal ganglion *380*

Section 6: Neuroanatomy

61. Cerebrospinal Fluid **385**
- Cerebrospinal fluid *385*

62. Spinal Cord **387**
- Laminar organization in spinal cord *387*
- Tracts of spinal cord *387*

63. Brainstem **390**
- Transverse section of medulla at level of decussation of pyramid *390*
- Transverse section of medulla at the level of sensory decussation *390*
- Transverse section of medulla at the level of olives *391*
- Transverse section of pons at the level of facial colliculus *392*
- Transverse section through upper part of pons *392*
- Transverse section of midbrain at the level of inferior colliculus *393*
- Transverse section of midbrain at the level of superior colliculus *393*

64. Cerebellum and Fourth Ventricle **395**
- Cerebellum *395*
- Cerebellar peduncles *396*
- Interpeduncular fossa *396*
- Floor of fourth ventricle *397*

65. Cerebrum **399**
- Lobes and external surface of cerebral hemispheres *399*
- Sulci and gyri of brain *402*
- Medial geniculate body *403*
- Lateral geniculate body *403*
- Hypothalamus *404*
- Basal ganglia *406*
- Corpus callosum *407*
- Internal capsule *408*

66. Ventricles of Brain **411**
- Third ventricle *411*
- Lateral ventricle *411*

67. Blood Supply of Brain and Spinal Cord **413**
- Circle of Willis *413*
- Blood supply of spinal cord *413*
- Blood supply of brain *414*

68. Cranial Nerves **417**
- Introduction *417*
- Olfactory nerve *418*
- Optic nerve *419*
- Oculomotor nerve, trochlear and abducent nerve *420*
- Trigeminal nerve *424*
- Facial nerve *429*
- Vestibulocochlear nerve *432*
- Glossopharyngeal nerve *434*
- Vagus nerve *436*
- Accessory nerve *439*
- Hypoglossal nerve *441*

Appendix 1: Red Alert **443**

Appendix 2: Quick Glance of Important Diagrams **446**

Index *475*

Pectoral Region

CHAPTER 2

- Pectoral region lies on the front of the chest.
- It consists of structures which connects the upper limb to the anterolateral chest wall.

1. Briefly mention about the superficial fascia of the pectoral region.

Superficial Fascia

- It lies under the skin of the pectoral region and is continuous with surrounding superficial fascia. Its contents are:
  - Moderate amount of fat
  - Cutaneous nerves derived from the cervical plexus and intercostal nerves
  - Cutaneous arterial branches from internal thoracic and posterior intercostal arteries
  - Platysma muscle
  - Breast/mammary gland.

2. Write a short note on platysma muscle.

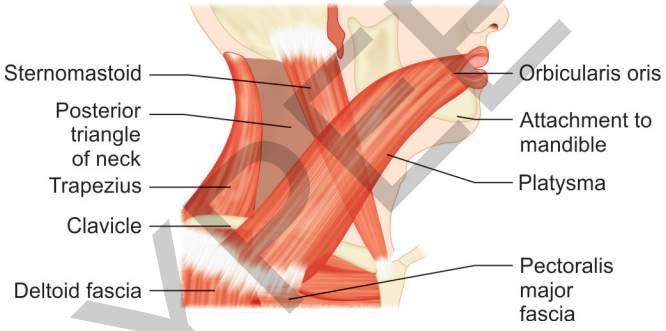

Fig. 2.1: Origin of platysma from fascia covering deltoid and pectoralis major muscles in the pectoral region (Note the platysma crossing the clavicle to pass through neck and reach the mouth by crossing the mandible)

- Platysma muscle:
  - It is a thin broad sheet of subcutaneous muscle
  - **Origin**: From the deep pectoral fascia
  - **Insertion**: Into the base of mandible and skin
  - It runs upwards and medially covering the neck
  - **Nerve supply**: Fascial nerve
  - It protects the underlying external jugular vein from external pressure.

3. Explain in detail about breast under the headings—situation and structure, blood supply, nerve supply and lymphatic drainage.

- The breast is a modified sweat gland.
- It is present in both sexes but rudimentary in males where as well-developed in females after puberty.
- It is an important accessory organ of the female reproductive system and provides nutrition to the newborn in the form of milk.

Situation, Relations and Extent

- It is **situated** in the superficial fascia of the pectoral region except the tail which pierces deep fascia of axilla through the 'foramen of Langer' and is called 'tail of Spence'
- **Breast extends:**
  Vertically: From 2nd to 6th rib
  Horizontally: Lateral border of sternum to midaxillary line.

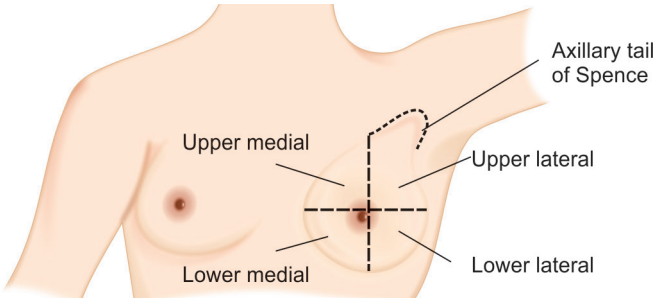

Fig. 2.2: Quadrants of breast and tail of Spence

- **Superficial relations**: Skin and superficial fascia
- **Deep relations**:
  - Retromammary space: Loose areolar tissue separating breast from deep pectoral fascia, hence breast is freely movable over pectoralis major
  - Pectoral fascia
  - 3 muscles over which base of the gland rests
    1. Pectoralis major
    2. Serratus anterior
    3. External oblique (a part)

JAYPEE BROTHERS

- Structures deeper to them
  - Clavipectoral fascia
  - Pectoralis major.

Structure of Breast

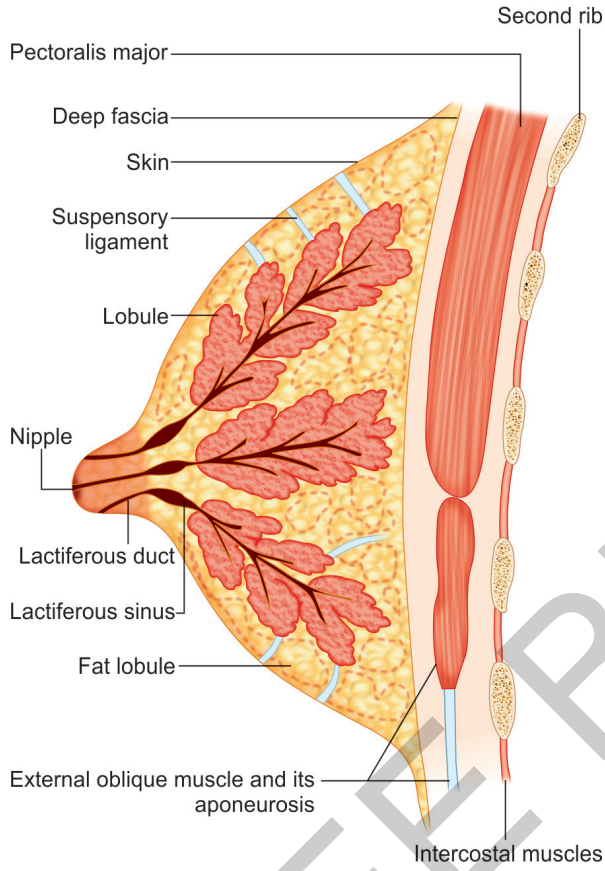

Fig. 2.3: Schematic vertical section through the breast

Breast consists of:
- Skin
- Areola
- Parenchyma
- Stroma

Skin
- It covers the gland and presents nipple and areola.
- Nipple is the conical projection situated usually at the center of breast corresponding to 4th intercostal space.
- It is pierced by 15–20 lactiferous ducts.
- It is rich in sensory nerve endings and very sensitive to touch.

Areola
- It is the circular area of pigmented skin surrounding the base of nipple.
- It is rich in sebaceous glands especially in the outer margin, which produces oily secretion preventing nipple and areola from drying and crusting.
- In pregnancy, areola becomes darker and enlarged.
- Montgomery's tubercles are the enlarged sebaceous glands around the nipple in pregnancy.

Parenchyma
- It is the glandular part of mammary gland which secretes milk.
- It consists of 15–20 lobes arranged in radial fashion around the nipple and opens into it through lactiferous ducts.
- Each lobe consists of lobules which are filled with clusters of acini secreting milk.
- Lactiferous sinuses are dilated part of lactiferous duct that helps to secrete milk.

Stroma
- It is the supporting framework of mammary gland.
- It is made up of fibrofatty tissue.
- The fibrofatty tissue is modified to form suspensory ligaments of cooper and suspends breast tissue to the skin and pectoral fascia.

Blood Supply

Breast is highly vascular. It is supplied by:

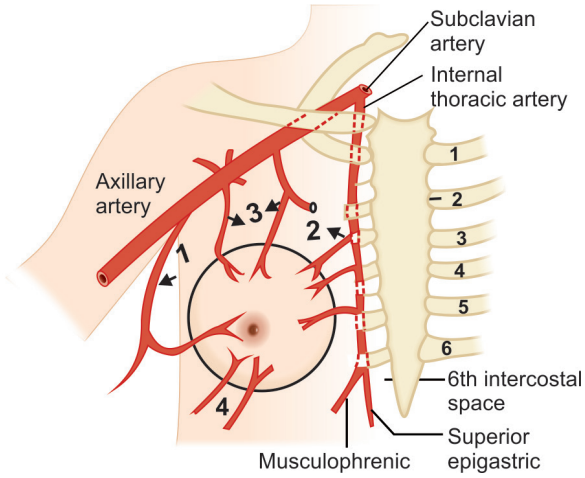

Fig. 2.4: Sources of arterial supply to the breast: (1) Branches of lateral thoracic artery; (2) Branches of internal thoracic artery; (3) Branches of acromiothoracic and superior thoracic arteries; (4) Branches of 2nd, 3rd and 4th posterior intercostal arteries

JAYPEE BROTHERS

Arterial Supply

- Internal thoracic artery through its perforating branches
- Axillary artery through:
  - Lateral thoracic
  - Superior thoracic
  - Acromiothoracic arteries
- Posterior intercostal arteries through lateral branches.

Venous Drainage

- Axillary vein
- Internal thoracic vein
- Posterior intercostal vein.

Nerve Supply

Cutaneous supply by 4th, 5th, 6th intercostal nerves.

Lymphatic Drainage

- Lymphatic drainage of breast is of great importance as they are the common channels through which metastasis of the breast cancer cells occurs to opposite breast and other organs.
- The **lymph nodes** draining the breast are:

1. ***Axillary lymph node:***
   - They drains about 75% of the lymph from the breast.
   - Among them, lymphatics end mainly in the anterior/pectoral group.
   - Lymph from the anterior and posterior groups passes to central and lateral groups and through them to apical group.
   - Eventually lymph reaches in the supraclavicular lymph nodes.
2. ***Internal mammary nodes*** arranged along the internal thoracic vessels.
   - They drains about 20% of the lymph from the breast.
   - They drains from both inner and outer half of breast.
3. ***Supraclavicular nodes.***
4. ***Cephalic/deltopectoral lymph nodes.***
5. ***Posterior intercostals nodes.***
6. ***Subdiaphragmatic lymph nodes.***
7. ***Subperitoneal lymph plexus.***

- **Lymphatic vessels** draining the breast are:
  - Superficial lymphatics drain the skin over the breast except the nipple and areola to the surrounding lymph nodes (axillary, internal mammary, posterior intercostal nodes) radially.
  - It is important to note that superficial lymphatics of the breast of one side communicate with those of opposite side. So unilateral breast malignancies becomes bilateral through metastasis.
  - Deep lymphatics drain the parenchyma of the breast along with nipple and areola.
  - Subareolar plexus of sappy is a plexus of lymphatics present deep to the areola. They drain into anterior axillary lymph nodes.
  - Lymphatics from the deeper part of the breast drain directly into the apical group of axillary lymph nodes or to the internal mammary lymph nodes.
  - Few lymph vessels from the inner part of the breast communicate with the subdiaphragmatic and subperitoneal lymphatic plexus.

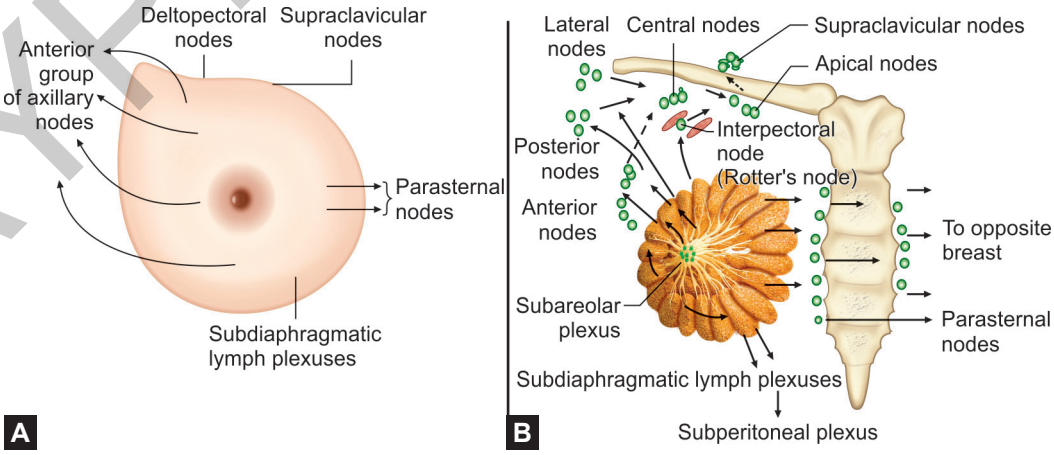

Figs 2.5A and B: A. Lymphatic drainage of the skin overlying the breast excluding areola and nipple; B. Lymphatic drainage of breast parenchyma (glandular tissue and lactiferous ducts) including areola and nipple

JAYPEE BROTHERS

Clinical Anatomy

- Knowledge of lymphatic drainage of breast is very importance as lymphadenopathy is an early and important sign for staging, treatment and prognosis of ***breast cancer***.
- Through lymphatics cancer cell can communicate with the opposite breast and other organs in the body.
- **Self-examination** of the breast stands as simplest, yet important, way to find out malignancy in early stage itself. On examination note:
  - Symmetry of breast and nipple
  - Change in the color of skin
  - Retraction of nipple
  - Discharge from nipple
  - Any palpable lump
- Cancer cells from the breast can shed off to the peritoneal cavity and moves to the ovary causing ovarian tumor known as **Krukenberg's** tumor.
- **Tubercle of Montgomery** stands as an important medico-legal evidence of pregnancy.
- **Suspensory ligament of Cooper** degenerates on aging and breast becomes pendulous as age advances.
- **Gynecomastia** is the development of breast in males due to hormonal imbalance and other reasons.

4. Write briefly about clavipectoral fascia. What are the structures passing through it?

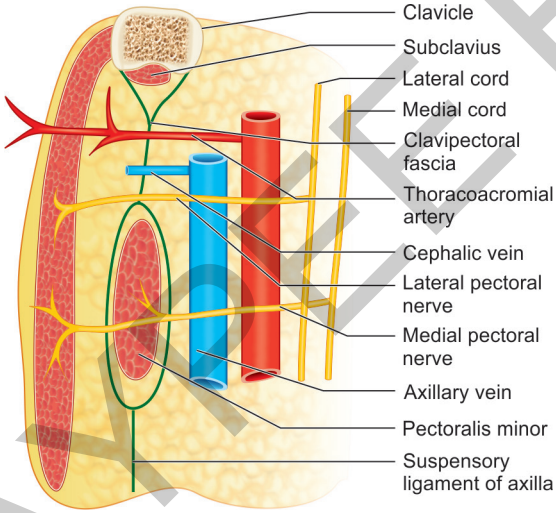

Fig. 2.6: Simplified diagram depicting clavipectoral fascia

- It is a fibrous sheet situated deep to clavicular part of pectoralis major muscle.

Extend

- **Vertically**: From the clavicle above to the axillary fascia below.
- **Medially**: Attached to the first rib and costoclavicular ligament and blend with the external intercostal membrane of the upper two intercostal spaces.
- **Laterally:** Attached to the coracoids process and blends with coracoclavicular ligament.
- Clavipectoral fascia is split into two laminae in the upper part to enclose the subclavius muscle.
- The anterior lamina is attached to the clavicle while the posterior lamina is continuous with the investing layer of deep cervical fascia.
- It is split into two laminae in the lower part to enclose pectoralis minor muscle.
- After enclosing the muscle, it extends downwards as the suspensory ligament of axilla which helps to pull up the dome of axillary fascia.

Structures Piercing the Clavipectoral Fascia

- Lateral pectoral nerve
- Cephalic vein
- Thoracoacromial vessels
- Lymphatics from the breast and pectoral region to the apical group of axillary lymph nodes.

5. Enumerate pectoral muscles.

They are:

- Pectoralis major
- Pectoralis minor

Known as key muscle of axilla as it divides axillary artery into:

- Subclavius
- Serratus anterior (not strictly a muscle of pectoral region).

6. Write a short note on pectoralis major muscle.

Pectoralis Major

Origin

- **Small clavicular head**: Medial half of anterior aspect of clavicle
- **Large sternocostal head**:
  - Lateral half of the anterior surface of sternum up to 6th rib
  - Medial end of 2nd to 6th costal cartilages
  - Aponeurosis of external oblique muscle of abdomen

Insertion

- Inserted into lateral lip of intertubercular sulcus by a **U** shaped bilaminar tendon
- Anterior lamina of tendon is formed by clavicular fibers
- Posterior lamina formed by sternocostal fibers
- Two laminas are continuous inferiorly
- Lower sternocostal and abdominal fibers are twisted in a way such that lowest fibers are inserted highest

Nerve Supply

- Lateral pectoral nerve
- Medial pectoral nerve

Actions

- **Clavicular head**: Flexes arm
- **Sternocostal head**: Adducts and medially rotates the arm.

JAYPEE BROTHERS

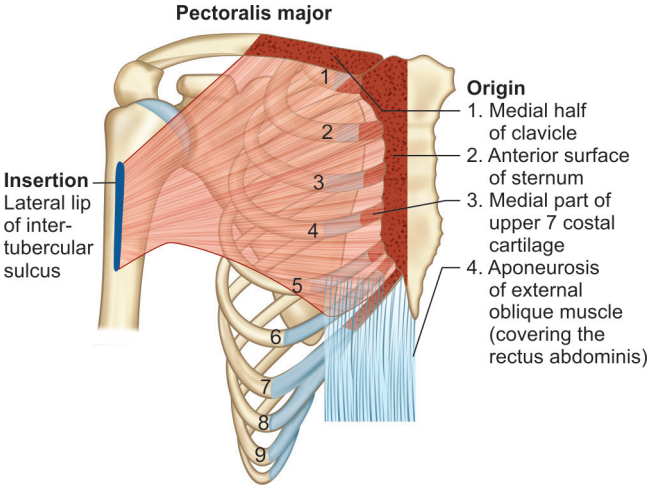

Fig. 2.7: Attachments of the pectoralis major

7. Write about the origin, insertion, nerve supply and actions of the remaining pectoral muscles.

Muscles	Origin	Insertion	Nerve	Action
Pectoralis minor	• 3rd, 4th and 5th rib near the costochondral junction • Intervening fascia covering external intercostal muscles	• Medial border and upper surface of coracoid process	• Medial and lateral pectoral nerve	• Draws scapula forward with serratus anterior • Depress the point of shoulder • Accessory muscle of respiration
Subclavius	• First rib at costochondral junction	• Subclavian groove in middle 1/3rd of clavicle	• Nerve to subclavius	• Steadies clavicle during movement of shoulder

8. Write a note on serratus anterior muscle.

Serratus Anterior

Origin
- 8 digitations from upper 8 ribs
- Fascia covering intervening intercostal muscles

Insertion: Costal surface of scapula along its medial border

Nerve Supply: Nerve to serratus anterior (from root of C5, C6 and C7)

Actions

Contd…

Contd…

- Pulls scapula forwards around the chest wall (along with pectoralis major)
- Keep medial border of scapula in firm contact with chest wall
- Rotates scapula laterally and upwards during overhead abduction of arm

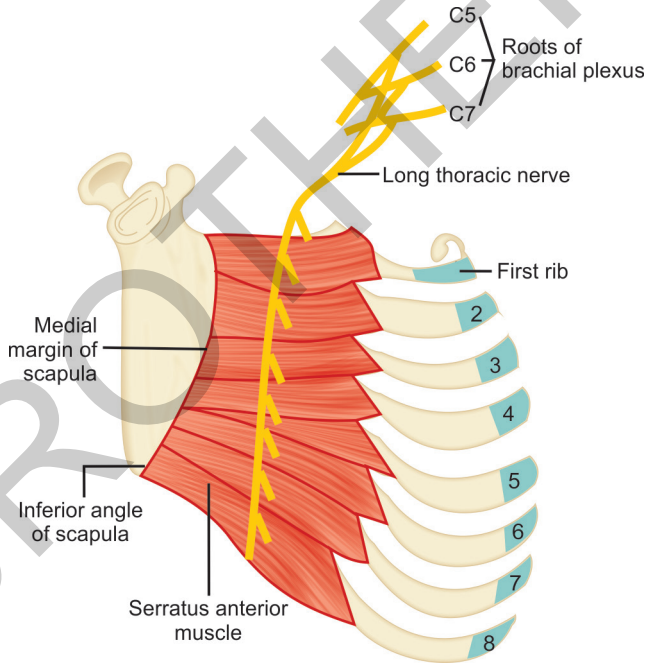

Fig. 2.8: Serratus anterior muscle in the medial wall of axilla and long thoracic nerve

Mnemonic

Serratus anterior: Innervation

SALT: **S**erratus **A**nterior = **L**ong **T**horacic

Clinical Anatomy

- *Injury to long thoracic nerve (**nerve of bell**) can occur in:*
  - Stab wounds
  - During removal of breast tumor
  - Sudden pressure on shoulder from above
  - Carrying heavy load on shoulder
- *It results in paralysis of serratus anterior and results in winging of scapula*
  - **NOTE:** Bell's palsy is associated with facial nerve and palsy or paralysis of muscles supplied by it.

JAYPEE BROTHERS

MULTIPLE CHOICE QUESTIONS

1. On climbing a tree, which of these two muscles at together?
   a. Teres major and teres minor
   b. Latissimus dorsi and teres major
   c. Pectoralis major and latissimus dorsi
   d. Teres major and pectoralis major

2. Ligaments of cooper are modifications of:
   a. Axillary fascia
   b. Pectoral fascia
   c. Fatty tissue of breast
   d. Fibrous stroma of breast

3. Which among these does not pierce clavipectoral fascia?
   a. Lateral pectoral nerve
   b. Cephalic vein
   c. Thoracoacromial vessels
   d. Subclavian artery

4. Which among these are not an early warning sign of breast cancer?
   a. Change in the color of skin
   b. Gliding mass under the skin of breast
   c. Retraction of nipple
   d. Discharge from nipple

5. Which among these is not a pure pectoral muscle?
   a. Pectoralis major
   b. Pectoralis minor
   c. Serratus anterior
   d. Subclavius

ANSWERS

1. c. **2. d** **3. d** **4. b** **5. c**

JAYPEE BROTHERS

for detailed information on anatomy books, visit our website www.jaypeebrothers.com, for detailed information on anatomy books, visit our webs

Exam Preparatory Manual for Undergraduates
ANATOMY

Salient Features

- Exam-oriented approach to anatomy
- Well-organized and generously illustrated chapters
- Concise description in a simple and lucid manner
- Simplified flowcharts and redrawn diagrams
- Most probable theory questions are given in Appendix 1 for university exam preparation
- Simplified diagrams are given in Appendix 2 for last-minute quick glancing
- MCQs are given at the end of each chapter for quick revision
- Authentic references from standard textbooks.

Harishanker JS, Ajai Sasi, Avinash N are MBBS students (2011–12 batch) from Malabar Medical College Hospital & Research Centre, Calicut (now Kozhikode), Kerala, India. The trio is well known among the faculties and students of Malabar Medical College as well as Kerala University of Health Sciences, Thrissur, Kerala. They have been constantly involved in bringing up student-friendly concise books for anatomy. *Asterion: The Practical Handbook for Anatomy* was their initial effort towards this and now *Exam Preparatory Manual for Undergraduates—Anatomy* is the result of the same.



Harishanker JS



Ajai Sasi



Avinash N

Available at all medical bookstores or buy online at www.jaypeebrothers.com

JAYPEE BROTHERS
Medical Publishers (P) Ltd.
www.jaypeebrothers.com
Join us on facebook.com/JaypeeMedicalPublishers

Shelving Recommendation
ANATOMY

ISBN 978-93-85999-17-8
9 789385 999178