information on surgery books, visit our website **www.jaypeebrothers.com,** for detailed information on surgery books, visit our website **www.jaypeebrothers.com**

Textbook & Atlas of

LAPAROSCOPIC HYSTERECTOMY

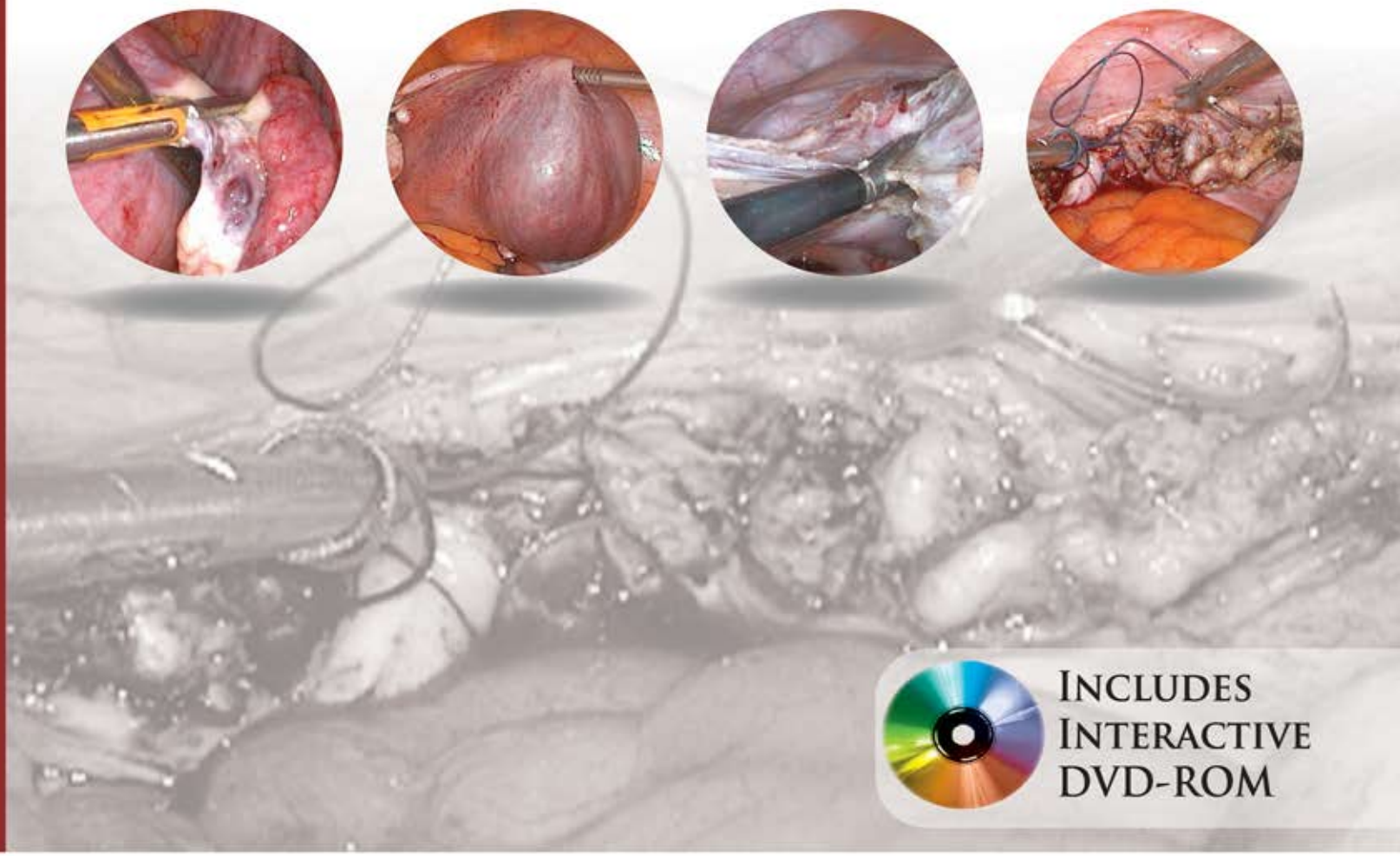

INCLUDES INTERACTIVE DVD-ROM

B Ramesh
Pooja Sharma Dimri

Foreword
Stephen T Jeffery

JAYPEE

Contents

SECTION 1: BASICS

1. Hysterectomy—Then and Now **3**
Pooja Sharma Dimri, Neha Jiniswale
- *Vaginal Hysterectomy 4*
- *Abdominal Hysterectomy 4*
- *Radical Hysterectomy 4*

2. Laparoscopic Pelvic Anatomy—An Overview **6**
Sandip Datta Roy
- *The Umbilicus, Peritoneal Folds and Posterior Peritoneum 6*
- *Structures at the Pelvic Brim 8*
- *Pelvic Sidewall 9*
- *Broad Ligament, Round and Ovarian Ligaments 9*
- *Pelvic Cellular Tissues, Fascia and Ligaments 11*
- *Vesicouterine/Vesicocervical Ligaments 11*
- *Pubocervical and Rectovaginal Fascia 11*
- *Avascular Spaces of Pelvis 12*
- *Retropubic Space (Space of Retzius) 12*
- *Paravesical Space 13*
- *Pararectal Space 13*
- *Vesicovaginal Space 14*
- *Rectovaginal Space 14*
- *Presacral Space 14*
- *Para-aortic Area 14*
- *Pelvic Lymph Nodes 14*
- *Vascular Relationships 14*
- *Venous Drainage 17*
- *Nervous Elements 17*
- *Afferent Innervation 18*
- *The Ureter 18*
- *Urinary Bladder 18*
- *Sigmoid and Rectum 20*

3. Indications of Hysterectomy **22**
Pooja Sharma Dimri, Neha Jiniswale
- *Benign Diseases 22*
- *Preinvasive Diseases 24*
- *Malignant Conditions 24*
- *Laparoscopic Hysterectomy in Special Conditions 24*
- *Hysterectomy Trends 25*
- *Contraindications 25*
- *Anatomic/Disease Related 25*

4. Preoperative Preparation **27**
B Ramesh, Pooja Gupta
- *Initial Visit 27*
- *History 27*

- *Examination and Assessment 27*
- *Patient Information 28*
- *Informed Consent 28*
- *Preoperative Assessment 28*
- *Preoperative Investigations 28*
- *Ward Management 29*
- *Operating Theater Management 30*

5. Anesthetic Implications in Total Laparoscopic Hysterectomies 31

Rajendra Manjrekar

- *History 31*
- *Physiology of Insufflation 32*
- *Physiological Trespass Created by the Pneumoperitoneum 32*
- *Raised Intra-abdominal Pressure (IAP) 32*
- *Neurohumoral Response Associated with Raised IAP 33*
- *Gaseous Interchange 33*
- *Other Physiological Effects 34*
- *Respiratory Complications of Pneumoperitoneum 34*
- *Gas Embolism 35*
- *Risk of Aspiration of Gastric Contents 36*
- *Cardiac Arrhythmias during Laparoscopy 36*
- *Effect of Pneumoperitoneum on Regional Hemodynamics 36*
- *Anesthesia for Laparoscopic Hysterectomy 36*
- *Anesthetic Technique 37*
- *Positioning of the Patient During the Surgery 37*
- *Extubation of the Patient 38*
- *Postoperative Nausea and Vomiting 38*
- *Monitoring of the Patient 38*
- *Use of Laryngeal Mask Airway 39*
- *Regional Anesthesia 39*
- *Alternatives to CO_2 Pneumoperitoneum 39*
- *Inert Gases 39*
- *Gasless Laparoscopy 39*

6. Instrumentation in Total Laparoscopic Hysterectomy 42

B Ramesh, Pooja Sharma Dimri, Chandana A

- *Endoscopy Operating Room 42*
- *Equipment 43*
- *Telescope 45*
- *Instruments for Entry 45*
- *Hand Instruments 46*
- *Additional Instruments/Equipment 47*
- *Energy Sources 48*
- *Morcellators 49*
- *Sterilization 49*

7. Energy Sources in Total Laparoscopic Hysterectomy 51

Priya Bhave

- *Conventional Electrosurgical Devices 51*
- *Conventional Electrosurgery in TLH 54*
- *Advanced Bipolar Vessel Sealers 55*
- *Ultrasonic Energy 56*
- *Practical Tips for Electrosurgery 57*

SECTION 2: ROUTES AND TYPES OF HYSTERECTOMY

8. Total Abdominal Hysterectomy **63**
Reeti Mehra, Navneet Magon
- *History 63*
- *Indications 63*
- *Advantages/Disadvantages over Vaginal Hysterectomy or Laparoscopic Hysterectomy 64*
- *Preoperative Preparation 64*
- *Operative Steps 64*
- *Postoperative Management 66*
- *Complications 66*
- *Special Circumstances 67*

9. Vaginal Hysterectomy—The Signature of a Gynecologist **68**
Navneet Magon, Alokananda Ray
- *The Scope of Vaginal Hysterectomy 69*
- *Reasons Commonly Reported for Avoiding Vaginal Hysterectomy and Clinical Evidence 69*
- *Trial of Vaginal Hysterectomy 71*
- *Method of Vaginal Hysterectomy 71*

10. Laparoscopic Hysterectomy—The Game Changer **75**
Navneet Magon, Nilanchali Singh
- *History 75*
- *Types 75*
- *Indications 76*
- *Contraindications 77*
- *Advantages/Disadvantages over Abdominal Hysterectomy 77*
- *Advantages/Disadvantages over Vaginal Hysterectomy 77*
- *Comparison of Total Laparoscopic Hysterectomy with Subtotal Hysterectomy 78*
- *Operative Steps of Total Laparoscopic Hysterectomy 78*

11. Choosing the Route of Hysterectomy **83**
Navneet Magon
- *Hysterectomy: Evolution from the Annals of History 83*
- *The Passage: Vaginal Passageway 85*
- *The Passenger: Uterine Size 85*
- *Place of the Passenger: Pelvic Cavity 85*
- *Choosing a Route for Hysterectomy: Quality of Care 86*
- *Vaginal Surgery: Signature of a Gynecologist 86*

SECTION 3: THE PROCEDURE

12. Ports and Positioning **91**
Pooja Sharma Dimri, Dipti Gunge-Jadhav
- *Basics of Port Positioning 91*
- *Port Placement 92*
- *Uterine Manipulation During Total Laparoscopic Hysterectomy 92*

13. The Upper Pedicle **97**
Pooja Sharma Dimri
- *Surgical Anatomy 97*
- *Instrumentation 98*

- *Procedure 98*
- *Removal of Ovaries in Hysterectomy 101*
- *Removal of Fallopian Tubes in Hysterectomy 102*

14. Bladder Dissection in Total Laparoscopic Hysterectomy 104
Pooja Sharma Dimri, B Ramesh, Rachana Ghanti
- *Surgical Anatomy 104*
- *General Considerations 105*
- *Bladder Dissection Techniques 105*
- *Other Approaches to Facilitate Bladder Dissection in Difficult Cases 107*

15. Uterine Artery and Total Laparoscopic Hysterectomy 109
Uddhavraj Dudhedia, Mallika Shetye
- *Considerations 109*
- *Our experience and Conclusion 116*
- *Special Considerations 117*
- *Illustrative Difficult Case Scenarios 117*
- *Discussion: Controversies and Dilemma 120*

16. Cardinal Uterosacral Ligament Complex, Opening of the Vaginal Vault and Specimen Retrieval 122
B Ramesh, Reshu Saraogi, Pooja Sharma Dimri
- *Cardinal Uterosacral Ligament Complex 122*
- *Dissection of the Cardinal Uterosacral Ligament Complex in Laparoscopic Hysterectomy 122*
- *Opening of the Vaginal Vault 123*
- *Specimen Retrieval 123*
- *Laparoscopic Supracervical Hysterectomy 125*
- *Electromechanical Morcellation in Hysterectomy—Current Status 127*

17. Suturing of Vault in Total Laparoscopic Hysterectomy 130
Pooja Sharma Dimri
- *Questions and Controversies 130*

SECTION 4: SPECIAL CONSIDERATIONS

18. Laparoscopic Uterine Artery Occlusion in Hysterectomy—Practical Tips and Tricks 141
Hafeez Rahman, Sandesh Kade
- *Different Approaches to Occlude the Uterine Arteries 141*

19. Total Laparoscopic Hysterectomy in a Large Uterus and Multiple Surgeries—Difficulties and Modifications 148
Vimee Bindra
- *Entry and Port Placement 148*
- *Manipulation 150*
- *Adhesions and Adhesiolysis 151*
- *Securing the Uterine Artery 154*
- *Specimen Retrieval: A Challenge in a Big Uterus 155*
- *Blood Loss 158*

20. Total Laparoscopic Hysterectomy in Severe Endometriosis 161
Paul PG, Dhivya Narasimhan, Varsha Rengaraj, Saurabh Patil
- *Preoperative Evaluation 161*
- *Preoperative Preparation 161*
- *Instruments and Equipment 161*
- *Procedure 162*

- *Abdominal Entry and Port Positions 162*
- *Anatomical Correction 162*
- *Upper Pedicles 163*
- *Bladder Mobilization and Division of Uterine Vessels 163*
- *Division of Cervicovaginal Attachments 163*
- *Excision of Rectovaginal Nodules and Adnexal Removal/Repair 163*
- *Vault Closure 163*
- *Checking the Rectum and Cystoscopy 164*
- *Postoperative Management 164*
- *Difficulties 164*

21. Laparoscopic Radical Hysterectomy 166
Shailesh P Puntambekar, Sanjay Kumar, Seema S Puntambekar, Vikrant Sharma, Aishwarya S Puntambekar, Atul R Dokrimare

- *Indications 167*
- *Investigations 167*
- *Complications 171*

22. Concomitant Stress Urinary Incontinence Surgery with Laparoscopic Hysterectomy 173
Prakash Trivedi, Animesh Gandhi

- *Magnitude of the Problem 173*
- *Concomitant Stress Urinary Incontinence Repair with Total Laparoscopic Hysterectomy 174*
- *Laparoscopic Burch Colposuspension 174*
- *Tension Free Vaginal Tape 176*
- *TSUIT 178*
- *TROT/TOT/Monarc 179*
- *Miniarc/Minislings 181*
- *Complications in Concomitant Total Laparoscopic Hysterectomy and Stress Urinary Incontinence Repair Surgeries—Our Experience 182*

23. Laparoendoscopic Single-site Hysterectomy 183
B Ramesh

- *Patient Selection 183*
- *Patient Counseling 184*
- *Preoperative Preparation 184*
- *Access 184*
- *Port and Instrument Selection 184*
- *Types of Hysterectomy 184*
- *LESS-LAVH 185*
- *LESS-TLH 185*
- *Special Situations 189*
- *Comparison with 4 Port Conventional TLH/LAVH 192*
- *Complications 192*
- *Learning Curve 192*

24. Robot-assisted Laparoscopic Hysterectomy 195
Sabhyata Gupta

- *da Vinci Robotic System 195*
- *da Vinci Surgical System Components 196*
- *Robotic Hysterectomy—Special Considerations 203*

25. Day Care Total Laparoscopic Hysterectomy 206
Rajesh Modi

- *Preoperative Preparation 206*
- *The Anesthesia Protocol 207*
- *Technique 207*
- *Postoperative Recovery 211*

SECTION 5: COMPLICATIONS OF TLH

26. General Complications of Laparoscopic Surgeries **215**
Aditi Agarwal, Pooja Sharma Dimri
- *Classification of Complications (Organ Specific) 215*
- *Anesthesia-related Complications 216*
- *Patient Positioning 216*
- *Entry Complications: Access-related 217*
- *Gas Embolism 219*
- *Bowel Injury 220*
- *Injury to the Urinary Tract 221*
- *Electrosurgical Injuries 222*
- *Postoperative Shoulder Pain 223*
- *Port Site Infections 223*
- *Port Site Hernia 223*
- *Port Site Metastasis 223*
- *Venous Thrombosis 223*
- *Prevention of Complications: Key Points 223*

27. Bladder Injuries in Total Laparoscopic Hysterectomy **226**
Jnaneshwari TL, B Ramesh
- *Anatomy of the Urinary Bladder 226*
- *Etiology 227*
- *Mechanism of Bladder Injury in Hysterectomy 227*
- *Prevention Techniques 228*
- *Recognition of Bladder Injury 228*
- *Screening for Bladder Injury 229*
- *Management 230*
- *Post-operative Considerations 231*
- *Role of Routine Cystoscopy in Total Laparoscopic Hysterectomy (TLH) 231*

28. Ureteric Injuries in Total Laparoscopic Hysterectomy **232**
Dipti Gunge-Jadhav, Yogesh Jadhav
- *Risk Factors for Ureteric Injury 232*
- *Sites of Ureteral Injury 233*
- *Diagnosis 234*
- *Management 234*
- *Prevention and Early Recognition of Ureteral Injury 239*

29. Bowel-related Complications of Operative Gynecological Laparoscopy **243**
MS Chandramouli
- *Mechanism 243*
- *Case Selection 244*
- *Operative Technique 245*
- *Recognition of Bowel Injury (Early and Late) 245*
- *Prevention of Bowel Injury 246*
- *Management of Bowel Injury 247*
- *Dealing with Aftermath of Bowel Injury 247*

30. Vault Complications Following Total Laparoscopic Hysterectomy **250**
B Ramesh, TM Chaithra
- *Risk Factors 250*
- *Vault Hemorrhage 251*
- *Vault Hematoma 252*
- *Vault Dehiscence/Evisceration 252*

- *Vault Infections/Vault Abscess 253*
- *Vault Discharge 254*
- *Vault Granuloma 254*
- *Late Complications 254*
- *Sexual Dysfunction 254*

31. Post Hysterectomy Vault Prolapse and Management 256
B Ramesh, Chandana A
- *Anatomy 256*
- *Assessment of Post-hysterectomy Prolapse 257*
- *Prevention and Management of Post Hysterectomy Vault Prolapse 257*

32. Conversion of Total Laparoscopic Hysterectomy 264
B Ramesh, Pooja Sharma Dimri
- *Factors for Conversion in Laparoscopic Hysterectomy 264*

SECTION 6: FOOD FOR THOUGHT

33. Vaginal Hysterectomy in the Era of TLH—The View from the Vaginal End 269
Vyomesh Shah
- *Choice of Route of Hysterectomy: What Does Evidence Say? 270*
- *The Incidence of Different Types of Hysterectomy 270*
- *Indications of Vaginal Hysterectomy 271*
- *New Aqua Dissection Modified Technique for Nondescent Vaginal Hysterectomy: A Study of 11,007 Cases (From 1997–2007) 271*

34. Are All Hysterectomies Indicated? 285
Manju Puri, Richa Aggarwal
- *Uterine Leiomyomas 286*
- *Abnormal Uterine Bleeding 288*
- *Endometriosis 289*
- *Adenomyosis 289*
- *Uterovaginal Prolapse 289*
- *Chronic Pelvic Pain 290*
- *Benign Adnexal Mass 290*
- *Preinvasive Neoplastic Diseases 290*

35. Alternatives to Hysterectomy in Dysfunctional Uterine Bleeding 293
Jyoti Taneja
- *Diagnosis 294*
- *Medical Management 294*

SECTION 7: OUR EXPERIENCE

36. Total Laparoscopic Hysterectomy—Practical Tips 305
B Ramesh, Pooja Sharma Dimri, Chandana A
- *General Considerations 305*
- *Surgical Procedure 306*
- *TLH—Our Experience (2004–2014) 309*

Index 315

CHAPTER 3

Indications of Hysterectomy

Pooja Sharma Dimri, Neha Jiniswale

'A man always has two reasons for doing anything: A good reason and the real reason.'

—JP Morgan

INTRODUCTION

Hysterectomy is the most commonly performed major gynecological surgical procedure worldwide.[1] Approximately 70% are performed via abdominal approach and the rest 30% performed vaginally.[2] However, after the description of surgical technique of total laparoscopic hysterectomy in 1989, this minimally invasive approach has become an alternative method to traditional techniques of hysterectomy.

Traditionally laparoscopic approach has been commonly used to facilitate vaginal hysterectomy. However, in the hands of advanced laparoscopic surgeon, the entire uterus can be removed laparoscopically. The underlying pathology, uterine mobility, vaginal accessibility and the surgeon's skills determines the extent to which laparoscopy is used.

A Cochrane collaboration systematic review, encompassing 27 studies (3643 patients) compared results of total laparoscopic hysterectomy, vaginal hysterectomy, and abdominal hysterectomy and concluded that vaginal access should be preferred in relation to abdominal access, based on best results. Authors also concluded that when vaginal hysterectomy was not possible, a laparoscopic hysterectomy could avoid the need of abdominal hysterectomy.[3] Indications of laparoscopic hysterectomy are same as those for hysterectomy by any other route. In 2005, American Congress of Obstetricians and Gynecologists (ACOG) committee opinion listed treatment of endometriosis, management of leiomyoma, adhesiolysis, ligation of infundibulopelvic ligaments and evaluation of abdominal cavity to facilitate removal of difficult ovaries as indications for use of laparoscopy in hysterectomy.[4]

The common indications are discussed below:

BENIGN DISEASES

Leiomyoma

Leiomyomas are a common gynecologic pathology and leading indication for hysterectomy. They can present as menorrhagia, pelvic pain and pressure symptoms or may be totally asymptomatic. For such symptomatic and asymptomatic but palpable and enlarging myomas, total laparoscopic hysterectomy (TLH) provides a permanent solution.

The specimen can be retrieved vaginally or by power morcellation. TLH can replace total abdominal hysterectomy (TAH) even for large uteri if surgeon has

JAYPEE BROTHERS

necessary skills.[5] However, suspicious fibroids such as growing after menopause, or not responding to GnRH agonist therapy, rapidly growing over short time frame, exceeding 10 cm in diameter should be treated with prudence because of rare possibility of leiomyosarcoma.

As per new food and drug administration (FDA) analysis, if laparoscopic power morcellation is performed in these women, there is risk that the procedure will spread cancerous tissue in pelvis and abdomen, significantly worsening patients' likelihood of long-term survival. Most hospitals therefore have curtailed use of morcellation to select number of cases, and while using a special bag that keeps the tissue fragments contained in it. However, the recent American Association of Gynecologic Laparoscopists (AAGL) statement to FDA is that we should improve but not abandon power morcellation, and that power morcellation with appropriate informed consent should remain available to appropriately screened, low risk women.[6]

Adenomyosis

Those women with substantial pain despite small fibroid burden may be more likely to have concomitant adenomyosis. It is a frequent cause of dysmenorrhea, often refractory to medical management, therefore a common indication of hysterectomy.

Abnormal Uterine Bleeding

For cases resistant to medical management, hysterectomy is the ultimate treatment option. However, there are now many different techniques to reduce bleeding by destroying uterine endometrium (ablation or resection). Failure of endometrial ablation is also a potential indication for hysterectomy. It is imperative that in case of abnormal uterine bleeding endometrial sampling is advisable to rule out endometrial malignancy before taking up for hysterectomy especially in postmenopausal women. In many cases without prior endometrial sampling, the final histopathology shows endometrial malignancy and patient may have to undergo repeat staging surgery.

Endometriosis

Another common indication for laparoscopic hysterectomy is pelvic pain due to endometriosis. The index of suspicion for cul-de-sac or bowel endometriosis should be high when patient presents with dyspareunia, pain radiating to back or leg, pain with bowel movements, tenesmus or rectal bleeding with menses.

When child bearing is not a concern, endometriosis is best treated by excision of endometriosis and hysterectomy (to remove possible deep intrauterine endometriosis) in severe cases.

According to Reich, at least one ovary can be preserved.[7] Endometriosis can remain symptomatic after removal of both ovaries as estrogen is also made by skin, adipose tissue and endometriosis itself. So even with extensive endometriosis, diseased area should be removed and not normal ovaries. It is important to note that supracervical hysterectomy is an incomplete treatment as endometriosis is present commonly in posterior cervix.

Chronic Pelvic Pain

Chronic pelvic pain (CPP) affects the quality of life of patient. The benefit of hysterectomy as a treatment module is not proven. It should be performed only when other causes are ruled out and medical modalities of treatment have failed. Moreover hysterectomy may be beneficial when pain originates from dysmenorrhea. A significant portion of patients with chronic pelvic pain have endometriosis, pelvic inflammatory disease (PID), tubal or ovarian pathology. It is in these cases that TLH and bilateral salpingo-oophorectomy (BSO) can help alleviate the pain. But it is important to note that chronic pelvic point (CPP) is multifactorial with a strong psychological component. Thorough evaluation and counseling of the patient is imperative before embarking on surgery.

Pelvic Organ Prolapse

The results of laparoscopy for repair of pelvic organ prolapse are encouraging. By combining the precision of endoscopic vision and positive pressure of pneumoperitoneum, access has been gained to anatomical spaces that were difficult to explore before. Also repair procedure can be adjusted under strict visual control.

Surgical correction of pelvic organ prolapse involves hysterectomy, repair of anterior and posterior wall defects and resuspension of vaginal apex. Planning of type and route of surgery should include individual's risk of surgery, risk of recurrence and previous treatment if any. Maher et al.[8] have reported a randomized controlled trial on upper vaginal prolapse comparing lap sacropexy and vaginal sacrospinous fixation. According to them abdominal sacral colpopexy was better than vaginal sacrospinous colpopexy in terms of a lower rate of recurrent vault prolapse (RR 0.23, 95% CI 0.07–0.77) and less dyspareunia (RR 0.39, 95% CI 0.18–0.86). Laparoscopic route can be employed in correction of posterior vaginal wall prolapse when coexisting apical defect requires surgery. The technique is modification of sacropexy with extension of posterior mesh to rectovaginal septum.

JAYPEE BROTHERS

PREINVASIVE DISEASES

Laparoscopic hysterectomy can be done for endometrial hyperplasia with atypia and adenocarcinoma in situ of cervix. Cervical intraepithelial neoplasia is itself not an indication of hysterectomy, but laparoscopic route can be chosen if indicated:

- Recurrent high grade cervical intraepithelial neoplasia (CIN)
- CIN3 at endocervical limit of conization
- Microinvasion
- Poor compliance to follow-up.

MALIGNANT CONDITIONS

Cervical Cancer

As far as laparoscopic surgery in management of cancer cervix is concerned, two situations have to be distinguished:

1. In early stage cases (stage 1a and $1b_1$) laparoscopic surgery allows confirmation of staging, at the same time assisting radical surgery.
2. In advanced cases ($1b_2$ and beyond), role of laparoscopy is only for staging before choosing therapy. Laparoscopic lymphadenectomy is helpful in assessing spread of disease before radiotherapy. Pelvic lymph nodes are already in the field of radiotherapy, but para-aortic lymph node sampling can be done to assess the need for extended field radiotherapy.

It is important to note that in cases of malignancy, direct manipulation of tumor should be avoided. If the tumor is so bulky that the above cannot be ensured, conversion to laparotomy should be undertaken promptly without undue hesitation. It should be remembered that just for the sake of accomplishing surgery by laparoscopy, the oncologic principles should not be compromised.

Endometrial Cancer

Laparoscopic hysterectomy can be carried out in women with endometrial cancer. In most cases the uterus is relatively small and surgeon can remove uterus laparoscopically and examine it from inside. The depth of penetration is then observed. If there is myometrial invasion of more than half, thorough pelvic lymphadenectomy will be required. Various studies have shown that with laparoscopic surgeries, incidence of postoperative complications like pyrexia, paralytic ileus, wound infection is reduced.

Laparoscopic Radical Hysterectomy

There are two types of laparoscopic radical hysterectomy, the first type being the total laparoscopic radical hysterectomy in which the entire process of radical hysterectomy is carried out laparoscopically, however, closure of the vaginal vault could also be done through the vaginal route. Laparoscopic assisted radical vaginal hysterectomy (LARVH) is the second type and it involves mobilization of the ureters ureteric dissection, lymphadenectomy and development of the paravesical and pararectal spaces laparoscopically, while the rest of the procedure is completed vaginally as classically described by Schauta.[9]

Radical surgeries in general are associated with an overall increase in morbidity and mortality, the reason for which can be attributed to the extensive nature of tissue dissection and disruption of radical procedures. This is further increased in open surgery where tissue handling and access is more. Laparoscopic procedures in general are associated with less tissue disruption, less pain, less infection and adhesion formation because of the reduced incision, little or no tissue handling and use of energy sources like diathermy. The overall survival rates are same whether the route is abdominal or laparoscopic in hands of an experienced surgeon.

LAPAROSCOPIC HYSTERECTOMY IN SPECIAL CONDITIONS

Nulliparous Women

Laparoscopic hysterectomy is a better option compared to vaginal hysterectomy in nulliparous women as uterine descent is not there, making vaginal hysterectomy (VH) difficult. In young girls suffering from mental retardation, if hysterectomy is desired for control of menstrual hygiene, then postoperative management is much easier with laparoscopy because of advantages in form of minimal wound attention, reduced morbidity and speedy recovery.

Previous Abdominal/Pelvic Surgery

Laparoscopy can be challenging in these cases as adhesions to anterior abdominal wall can be encountered with blind entry. Some techniques have been advocated to decrease the risk such as using Veress needle at Palmer's point for entry and use of optical trocars.

Women with Obesity

In very obese patients, during laparoscopic surgery, maintenance of pneumoperitoneum and Trendelenburg position is often compromised by high ventilation pressures. However, vaginal hysterectomy may also be difficult in terms of access to deeper and distally placed pedicles.

JAYPEE BROTHERS

Overall vaginal route is better for experienced vaginal surgeon.

HYSTERECTOMY TRENDS

Worldwide, fibroids are the most frequent indications of TLH. A study was published in Korean journal on 1041 female who underwent TLH with or without BSO from May 2003 to December 2008.[10] Various indications reported were leiomyoma, adenomyosis, endometrial hyperplasia and malignancy. In our hospital we conducted a retrospective analysis of 858 laparoscopic hysterectomies performed between 2004 and 2014. Surgical procedure was performed by same surgeon and with standard operating technique. Most common indication was fibroid (54.4%), others being DUB (17.8%), adenomyosis (8.8%), endometriosis (3.2%), postmenopausal bleeding (3.4%), laparoscopic radical hysterectomy with pelvic lymph node dissection (0.9%), endometrial hyperplasia (2.2%)(Fig. 3.1).

Rates of hysterectomy appear to be decreasing with a peak in 2002, with 680,000 procedures to 430,000 in 2010 in US. It could be possibly due to advent of less invasive therapy for management of conditions previously treated with hysterectomy. However, amongst all routes of hysterectomy, the rate of total laparoscopic hysterectomy has increased. In 1990, it accounted for 0.3% of all hysterectomies to 9.9% in 1997 and 11.8% in 2003.[11]

CONTRAINDICATIONS

The contraindications to TLH are now relative with the advancement in equipment, optics, instrumentation and expertise. The most important absolute indications are medical comorbidities which preclude safety of anesthesia and surgery. The various contraindications of laparoscopic hysterectomy can be classified into the following groups:

Medical conditions: Gynecologic laparoscopy has a unique requirement of pneumoperitoneum and Trendelenburg position. Severe cardiac and pulmonary disease may contraindicate laparoscopic access. The anesthesia in laparoscopic gynecology is described in Chapter 5.

Surgeon expertise: Surgeon's inexperience is one of the relative contraindications. Laparoscopy has a long learning curve. Proper knowledge of laparoscopic anatomy, entry techniques, instrumentation and operative procedure is essential. Lack of training, skill and experience is relative contraindication.

Technical: Laparoscopy is equipment dependent method of surgery. Equipment for entry and creation of pneumoperitoneum, vision and the procedure should be available and in optimum condition. The unavailability of the same may preclude laparoscopy.

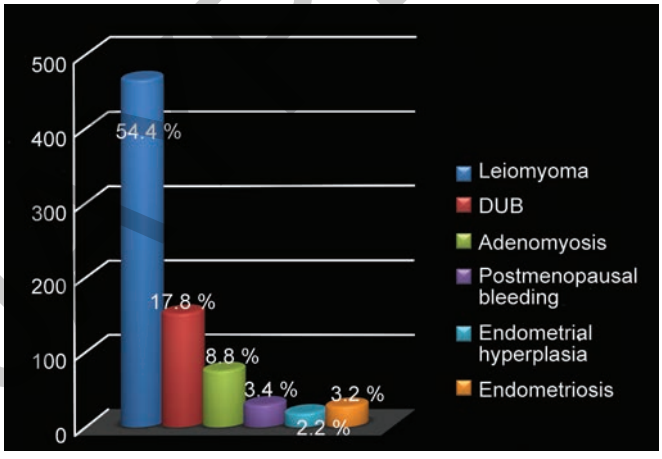

Fig. 3.1: Indications of total laparoscopic hysterectomy (TLH) at our center from 2004 to 2014

ANATOMIC/DISEASE RELATED

Severe adhesions due to multiple previous abdominal surgery, large uterus, obstructive fibroids and endometriosis may cause difficulty in access and performance of surgery. This may be feasible for an expert surgeon but may be considered as a contraindication for an inexperienced surgeon. Cases of malignancy should be evaluated for feasibility of laparoscopy. In cases of extreme obesity, longer trocars and instruments should be used. It is important to note that the surgical principles and the optimum result of the surgery along with patient safety should not be compromised at any cost.

Long Road Ahead!

In spite of laparoscopic hysterectomy having been there for a long time, it is practised in relatively few centers in India and world. The reasons of this suboptimal acceptance is lack of proper and adequate training at the level of medical school, nonavailability of adequate number of specialized training centers, lack of equipment and high cost of establishing the laparoscopic setup. There is a need for standardized curriculum and training program to be established along with dedicated training centers for skill development. Also, need for standardization of procedures with special emphasis on prevention of complications cannot be overemphasized. Reduction in costs of equipment would allow more and more surgeons and hospitals to embark in this endeavor. Gynecologists should make efforts to include TLH in their armamentarium by acquiring and embracing new skill, technology and expertise. Given adequate training in laparoscopic surgery and with proper technique,

JAYPEE BROTHERS

laparoscopy may be considered instead of laparotomy in most patients needing hysterectomy.

REFERENCES

1. Kondo W, Monica Z, Anibal W, Carneiro L. Surgical technique of total laparoscopic hysterectomy. Brazilian journal of video endoscopic surgery; march 2003.
2. Clayton RD. Hysterectomy. Best practice and Research. Clin Obstet Gynecol. 2006;20:73-87.
3. Johnson N, Barlow D, Lethaby A, Tavender E, Garry R. Surgical approach to hysterectomy for benign gynec disease. Cochrane database syst rev. 2006;2:CD003677.
4. ACOG Committee Opinion #311: Appropriate use of laparoscopically assisted vaginal hysterectomy. Obstet Gynecol. 2005;105:929.
5. Walid MS, Heaton RL. TLH for uteri over one kilogram: journal of society of laparoscopic surgeons. 2010;14(2):178-82.
6. Brown J. AAGL Advancing minimally invasive surgery worldwide: Statement to the FDA on Power morcellation. JMIG. 2014;21(6):970-1.
7. Reich H, Secktin T, Reich JM. Laparoscopic hysterectomy for advanced endometriosis and rectosigmoid disease. In: J Donnez (Ed)(3rd Edn) Atlas of Laparoscopy & Hysteroscopy. London, Informa UK. 2007;93-110.
8. Maher C, Baessler K, Glazener CMA, Adams EJ, Hagen S. Surgical management of pelvic organ prolapse in women: A short version Cochrane review, published online: 18 DEC 2007.
9. Barakat RR, Markman M, Randal M. 6th Ed. Principles and Practice of gynecologic oncology. Philadelphia USA Lippincott Williams & Wilkins. 2014.
10. Moon JM, Hong J, Jean YT. Clinical outcomes of 1041 TLH: 6 years experience. Korean joural of obstetric and gynaecology. 2011;54:618-22.
11. Wu JM, Wetcher ME, Geller EJ, et al. Hysterectomy rates in US, 2003. Obstet Gynecol journal. 2007;110:1091-5.

JAYPEE BROTHERS

for detailed information on surgery books, visit our website **www.jaypeebrothers.com,** for detailed information on surgery books, visit our website **www.jaypeebr**

Textbook & Atlas of LAPAROSCOPIC HYSTERECTOMY

The book *Textbook and Atlas of Laparoscopic Hysterectomy* is a unique book dedicated to the procedure of laparoscopic hysterectomy. It describes all aspects of the procedure in totality. All chapters are written in exhaustive detail with utmost attention to latest technological advances. The flow of the book is very appealing to the reader navigating from simple-to-complex. The book is organized into 7 sections and 36 chapters for comprehensive reading. Experts in gynecologic endoscopy; some of them internationally renowned, have contributed various chapters to the book and shared their rich experience. The text is enriched with scientific evidence, latest advances as well as experience of the authors. It is ably supported by illustrations, operative pictures, tables and boxes to make reading simplified and with enhanced clarity. It also comes with a DVD with audio narration of videos on total laparoscopic hysterectomy (TLH). Sections on basics, routes and types of hysterectomy, procedure, complicated surgery and complications along with a section on our experience with tips and tricks make it a must-read book on laparoscopic hysterectomy for postgraduates and beginners and a reference text for those who are already performing laparoscopic hysterectomies.



B Ramesh MD DGO FCPS FICOG is a renowned Gynecologic Endoscopic Surgeon and Director at Altius Hospital, Bengaluru, Karnataka, India. He is the pioneer in single incision laparoscopic surgery (SILS) technique in Gynecologic Laparoscopy in India and has demonstrated it in many workshops all over the country. His special interests, apart from gynecologic laparoscopy, are urogynecology and infertility. He has performed several thousand laparoscopic surgeries all over India and has trained more than 1,000 gynecologists in operative laparoscopy from India and abroad. He has received many awards for his contribution to the field of medicine. He believes in holistic medical and surgical approach to the patient. His passion and dedication to his work has been a source of inspiration to many aspiring gynecologic laparoscopic surgeons.



Pooja Sharma Dimri MD DNB FMIS is an alumnus of Lady Hardinge Medical College, Delhi, India. She did fellowship in minimally invasive surgery in gynecology from Altius Hospital, Bengaluru, Karnataka, India and now works as Consultant Gynecologic Endoscopic Surgeon in Mumbai, Maharashtra, India. Apart from being an efficient surgeon, she is actively involved in academics and research. She has been faculty in many national conferences. She has also done a lot of work in the field of different techniques of morcellation of fibroids.

Available at all medical bookstores
or buy online at www.jaypeebrothers.com

JAYPEE BROTHERS
Medical Publishers (P) Ltd.
www.jaypeebrothers.com

Join us on facebook.com/JaypeeMedicalPublishers

Shelving Recommendation
SURGERY

ISBN 978-93-85999-28-4