our website www.jaypeebrothers.com,for detailed information on orthopedic books, visit our website www.jaypeebrothers.com



Differential Diagnosis in Spine Surgery

Editors
John D Koerner
Alexander R Vaccaro
Daniel H Kim

Foreword
Kern Singh

JAYPEE

Contents

1. Lower Back Pain in Children and Adolescents **1**
Tamir Bloom, Sanjeev Sabharwal, Saad B Chaudhary
- Chief Complaint/History *1*
- Differential Diagnosis *3*
- Workup *7*

2. Lower Back Pain in Adults **19**
Tim Colangelo, John D Koerner, Alexander R Vaccaro
- Differential Diagnosis *19*
- Anatomy *19*
- Physical Exam *22*
- Imaging Studies *27*
- Further Workup *30*

3. Arm Pain, Weakness and Numbness **33**
Angela Chang, Caleb Behrend, Alexander R Vaccaro
- Chief Complaint/History *33*
- Differential Diagnosis *34*
- Anatomy/Physical Exam *34*
- Neurologic Examinations *44*

4. Cervical versus Shoulder/Periscapular Pain **52**
Christie Stawicki, Tristan Fried, Loren Mead, Sarah Nyirjesy, John D Koerner, Alexander R Vaccaro
- Chief Complaint/History *52*
- Differential Diagnosis *53*
- Workup *54*
- Further Workup *59*

5. Groin Pain **61**
Brett Walker, Mike Donahue
- History *61*
- Differential Diagnosis *62*
- Physical Examination *70*
- Imaging Studies *76*
- Further Diagnostic Studies *77*

6. Leg Pain/Weakness/Numbness **80**
Andrew G Park, Karim Shafi, Tristan Fried, Alexander R Vaccaro
- History *80*
- Physical *81*
- Differential Diagnoses *81*
- Vascular *81*
- Infection *82*
- Inflammatory *83*
- Neoplastic *83*
- Neurologic *83*
- Degenerative *87*
- Deficiency *87*
- Autoimmune *87*
- Anatomic *88*
- Trauma *89*
- Toxins *90*
- Endocrine *91*

7. Bowel/Bladder Incontinence, Retention, and Saddle Anesthesia **94**
Heidi M Hullinger, Rex AW Marco
- Chief Complaint/History *94*
- Differential Diagnoses *95*
- Evaluation *98*
- Imaging *100*
- Further Workup *104*

8. Neck Pain in Adults **107**
Brian P Calio, Anuj Shah, Troy Mounts
- History *107*
- Differential Diagnosis *108*
- Physical Exam *116*

9. Headaches **121**
Stephanie Wrobel Goldberg, Alexander J Schupper, Stephen Silberstein
- Chief Complaint/History *121*
- Differential Diagnosis *121*
- Anatomy and Pathophysiology *125*
- Physical Exam and Workup *127*
- Treatment *128*

10. Gait Abnormalities 131
Colin Vroome, Christopher M Maulucci, George M Ghobrial, James S Harrop
- Differential Diagnoses *131*
- Workup *134*
- Imaging Studies *140*
- Further Workup *141*

11. Sacroiliac Joint Pain 144
Martin Griffis, Jessica Stark, Daniel H Kim
- Differential Diagnosis *145*
- Anatomy *145*
- Physical Exam *147*
- Imaging Studies: MRI and CT Images *148*
- Further Workup *149*
- Treatment *149*
- Discussion *149*

12. Differential Diagnosis: Hemiparesis 152
Ahmed J Awad, Matthew Goldfarb, George M Ghobrial, Christopher M Maulucci, James S Harrop
- Chief Complaint/History *152*
- Differential Diagnosis *153*
- Workup *153*
- Imaging Studies *154*
- Further Workup *155*

13. Progressive Diffuse Paresis in Adults 158
Kevin Henrichsen, Sarah Nyirjesy, Saint-Aaron Morris
- Intracranial Disorders *158*
- Peripheral Nerve Disorders *170*
- Neuromuscular Junction Disorders *172*
- Muscular Disorders *174*

14. MRI Cord Changes 181
Vahe M Zohrabian, Adam E Flanders
- Inflammatory Causes *181*
- Neoplastic Causes *186*
- Vascular Causes *190*
- Metabolic Causes *194*
- Traumatic Causes *196*

Index *201*

CHAPTER 3

Arm Pain, Weakness and Numbness

Angela Chang, Caleb Behrend, Alexander R Vaccaro

INTRODUCTION

Musculoskeletal injuries and overuse of joints are the most common causes of upper limb pain and weakness. Pain, sensory disturbances and weakness are associated with neural compression and may be readily apparent upon physical examination with repetitive motion. It is important to identify the source of patient symptoms as well as associated symptoms as damage to upper and lower motor tracts may be the diagnoses. Narrowing of anatomical locations may contribute to discomfort and vascular constriction, and signs of cyanosis or insufficient vascular supply to peripheral tissues may be readily apparent upon visual inspection. Nerve conduction tests and electromyography (EMG), imaging studies and lab workup may be appropriate to confirm diagnosis.

CHIEF COMPLAINT/HISTORY

Patient may notice or complain of generalized neck and arm pain or weakness with a tingling sensation in the forearm and fingers upon evaluation. When taking the history, have the patient elaborate upon their symptoms. Ask the patient about the onset of symptoms, quality of the pain (continuous, intermittent, or throbbing), specific location, severity, frequency, radiation, associated symptoms, if there have been previous similar experiences and what actions alleviate or exacerbate symptoms. The past medical history should include any prior trauma, infections (may provide indications of acute or chronic infections), neurological symptoms, surgical procedures and relevant family history. It may be important for the clinician to ask about previous diagnosis of diabetes, immune suppression or cancer. The clinician should observe patient's gait and note any limitations, including discomfort or compensatory mechanisms, of range of movement at neck, shoulder, upper limb joints and spine. Symptoms such as sensory deficit, fevers, chills or unexplained weight loss should be noted. Bulbar symptoms such as

JAYPEE BROTHERS

Box 3.1: Upper limb pain and weakness history: pertinent red flags.

- Trauma
- Unexplained significant motor and/or sensory loss (indications of neurological lesions)
- Lesions, tenderness or swelling (indications of tumor or infections)
- History of cancer
- Persistent or progressive pain that is unresponsive to NSAIDs
- Pain at rest, including night pain

(NSAIDs: Nonsteroidal anti-inflammatory drugs).

difficulty in swallowing food and liquids, facial weakness, or excess salivation may be indicative of progressive weakness or degeneration of motor neurons extending above the spinal cord.

Motor and sensory abnormalities need to be carefully assessed by the clinician. If the patient has spinal cord injury, it must be recognized and treated early to reduce the possibility of permanent loss of function. Physical examination of the spine and upper limb should include palpations for bony abnormalities, noting any tenderness, areas of redness, blisters or other irregularities. Such findings are red flag indicators (Box 3.1).

If patient describes a pattern of pain consistent with cardiac origin including uncomfortable tightness of chest and radiation from chest to the arm (neck and jaw), shortness of breath and lightheadedness, seek immediate emergency care.

DIFFERENTIAL DIAGNOSIS

An extensive range of pathologies can result in upper limb pain and/or weakness (Table 3.1). Though causes of upper limb pain or weakness are primarily attributed to the overuse of muscles and joints, loss of neuronal integrity (compression and/or degeneration) can produce similar symptoms along with sensory deficits. Progressive muscle weakness or muscular strength throughout the day may be indicative of an autoimmune disease. Progressive and chronic muscular weakness may be reflective of central nervous system (CNS) pathology. Management of symptoms should begin with non-invasive therapies such as injections of local anesthetic and prescription of nonsteroidal anti-inflammatory drugs (NSAIDs) to provide relief and muscle strengthening with physical or occupational therapy, prior to consideration of surgical intervention.

ANATOMY/PHYSICAL EXAM

Prior to physical exam, evaluation of patient history should include the patient's ability to carry out daily routines and activities. Recall key elements

JAYPEE BROTHERS

Table 3.1: Differential diagnosis of common spinal causes of upper limb pain/weakness.[7, 16-20, 24, 25]

	Presenting characteristics of upper limb pain	*Associated symptoms*
Muscular strain	• Sudden onset of pain • Soreness • Limited range of motion	• Bruising or discoloration • Swelling • Muscle spasms • Stiffness • Weakness
Compressive neuropathy	• Signs of thoracic outlet syndrome of neurogenic origin • Signs of carpal tunnel syndrome	• Sensory deficit
Tendonitis	• Pain or tenderness at joint	• Swelling • Stiffness
Rotator cuff tear	• Pain at rest and during motion • Weakness	• Crepitus
SLAP tear	• Crepitus, popping or clicking with motion • Pain • Weakness	• Sense of instability at shoulder joint • Ache
Cervical radiculopathy	• Sharp pain that extends to periphery	• Pins and needles sensation • Weakness
Cervical myelopathy	• Upper limb pain • Tingling • Muscle weakness	• Irregular movements • Lightheadedness • Problem with fine motor movements
Angina or myocardial infarction	• Pain and squeezing sensation of chest • Pain radiation to left shoulder	• Jaw pain (pain extension to the neck) • Sweating • Nausea • Belching (more prevalent in females) • No symptoms
Thoracic outlet syndrome	• Pain in neck, shoulder or hand • Tingling or numbness down the arm	• Cramping upon repetitive activity (sign of claudication) • Muscle wasting
Malignancy (compression of spinal or peripheral nerves)	• Radiating pain • Numbness or tingling	• Muscle weakness
Spinal infection	• Fever • Chills • Pain	• Tenderness • Stiffness • Erythema

Contd…

JAYPEE BROTHERS

Contd…

	Presenting characteristics of upper limb pain	*Associated symptoms*
Fracture	• Abnormal contour • Pain • Swelling or bruising	• Loss of function
Fibromyalgia	• Generalize muscular or joint pain • Depression • Fatigue • Anxiety	• Concentration and memory problems • Headaches • Irritable bowel syndrome • Morning stiffness • Sleeping problems • Numbness and tingling of upper limb
Cerebrovascular event	• Sudden unilateral numbness or weakness of face and arm • Confusion	• Blurred vision • Loss of balance
Radial head dislocation (Pediatric)	• Pain • Hanging arm • Disuse of arm	• No swelling or deformity
Erb-Duchenne palsy	• Discomfort of shoulder • Stiff and crooked appearance of arm	• Circulatory problems and associated cramps
Amyotrophic lateral sclerosis	• Progressive muscle weakness, cramping, fasciculations and spasticity	• Abnormal fatigue • Slurred speech • Respiratory failure
Compartment syndrome	• Intense pain, worse with motion • Paresthesia	• Numbness or paralysis • Difficulty moving • Muscle bulging
Syringomyelia	• Loss of hot/cold sensitivity • Numbness and tingling • Muscle weakness • Pain	• Paralysis • Bowl and bladder dysfunction
Multiple sclerosis	• Numbness or weakness of limb • Loss of vision • Loss of coordination of muscles	• Dysarthria and dysphagia • Muscle spasm • Bowel and bladder dysfunction
Myasthenia gravis	• Progressive weakness throughout the day • Eyelid drooping (ptosis) • Double vision (diplopia) • Paralysis of eye movements	• Bulbar weakness resulting in dysarthria • Tiredness
Lambert-Eaton myasthenic syndrome	• Weakness improves throughout the day • Disruption of autonomic nervous system	• Diplopia • Ptosis • Lack of sweating (anhidrosis) • Orthostatic hypotension • Constipation

Contd…

JAYPEE BROTHERS

Contd…

	Presenting characteristics of upper limb pain	*Associated symptoms*
Congenital myopathies (i.e. Duchenne muscular dystrophy and Becker's muscular dystrophy)	• Progressive muscular atrophy during adolescent development • Skeletal abnormalities	• Respiratory inadequacy
Degenerative arthritis of upper limb joints	• Discomfort • Pain of neck and/or back • Stiffness of neck and/or back	• Depression associated with disability • Nodules in joints are associated with rheumatoid arthritis (generally distal interphalangeal joints and cervical spine are unaffected)
Polymyalgia rheumatica fever	• Pain • Tenderness • Stiffness • Fever and headache	• Depression • Lethargy • Night sweats • Loss of appetite • Weight loss

(SLAP: Superior labral anterior to posterior).

Other diagnosis of peripheral neuropathy include nutritional deficiency, viral infection, Lyme disease, lead poisonings and other neurotoxins. This may be determined with a thorough history and laboratory workup.

of history especially potential mechanisms of injury, pathologic or traumatic. Remain cognizant of patient's experiences of limitations consistent with physical findings. Visual inspection of alignment and assessment of range of motion should be systematic, starting at the spine and working towards the periphery to ensure a comprehensive physical exam. If the patient has painful joints, let the patient move them gently to see how they manage or compensate for compromised range of motion. X-rays of recent traumatic injury to joints should be obtained prior to attempting range of motion tests. Long hair pulled up or aside and restrictive clothing should be removed prior to active and passive physical examination.

Begin by observing the general appearance, gait, and posture. Take notice of patient's ease in movement when walking, sitting and rising, and if applicable, ability to remove additional garments such as a jacket. Also observe for protective positioning of the upper limb. The use of an assistive device should be noted. Note any observable facial asymmetry, spasticity, dysarthria, or fasciculation as these are indications of motor neuron disease.

JAYPEE BROTHERS

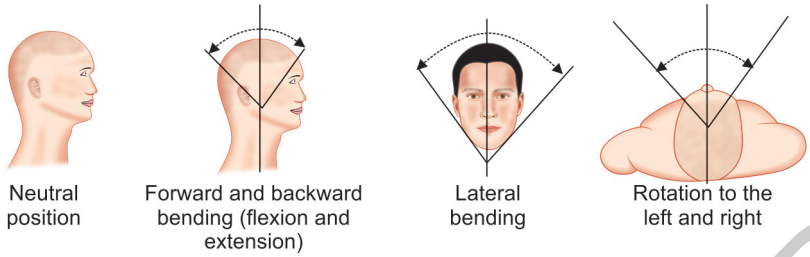

Fig. 3.1: Range of motion testing of the neck.

Note any bruising, ecchymosis, skin abrasions or other signs of trauma. Note any abnormalities of bony structures or soft tissue structures at joints upon palpation. During postural analysis, examine the patients resting head position and inclination of gaze. The patient should be able to look straight ahead with leveled shoulders. An elevated shoulder in relation to another may be indicative of scoliosis, muscle imbalance or glenohumeral instability.

Upon assessing the patient's cervical spine range of motion, the patient should be able to flex the neck (ask the patient to bring head to the chest and back to center) and extend the neck (ask the patient to lean head back and look at the ceiling) with ease (Fig. 3.1). The patient should be able to laterally flex the head (ask patient to bring head to one side of the shoulder and then the other) with ease and should be able to rotate head to the left and right (ask patient to look to the right and left) symmetrically with ease. Abnormal findings including limited range of motion, pain-limiting range of motion, asymmetry in range of movement for rotation or lateral bending, and fixed deformity in the sagittal or coronal plane may be indicative of nerve impingement.[2] The Spurling's test may be implemented to evaluate the patient for cervical root compression. Ask patient to extend the head and turn the head toward the affected side and apply downward pressure (Fig. 3.2). Pain arising from the neck in a dermatome may suggest cervical radiculopathy or cervical spondylitis.[1,3,14,15] Before assessing the integrity of the shoulder, check for tenderness to palpation of neck muscles or palpable neck masses. The presence of scars from prior surgery or injury should also be noted.

When performing physical examination of the shoulder, patient should be able to shrug the shoulders symmetrically. Tenderness or swelling upon palpitation of the sternoclavicular joint, clavicle, acromioclavicular (AC) joint, bicipital groove, periscapular area and around the subacromial bursa are suggestive of primary shoulder pathology. Check range of motion for forward flexion, abduction, internal and external rotation for passive and active range of motion. Move the arm while stabilizing the scapula with the other to help isolate glenohumeral joint during passive examination.

JAYPEE BROTHERS



Fig. 3.2: Spurling's test is performed by extending the head and turning towards the affected side and applying downward pressure.

Improvement of symptoms with stabilization of the scapula is suggestive of scapular dyskinesis as is periscapular tenderness. If there is tenderness over the AC joint this is suggestive of arthritis or injury. Normal range of motion for abduction is up to 150° and adduction up to 30°. Forward shoulder flexion ranges from 0° to 180° and extension from 45° to 60°. Rotation of the shoulder should also be tested with the elbow flexed to 90° and should range from 0° to 90° in external rotation and 70°–90° in internal rotation (Fig. 3.3). Knowing expected range of motions can help assess for joint limitations during provocative maneuvers.

To assess whether the etiology of the patient's shoulder pain is of musculoskeletal origin, perform the cross body adduction test. Patients are asked to raise the affected arm to 90° and adduct the arm (cross the arm to reach the other clavicle). Motion with pain may be reflective of arthritis at the AC joint. Motion without pain rules out AC joint dysfunction and may indicate a rotator cuff impingement if the patient is experiencing shoulder pain.[9] Specific range of motion examinations may direct to a diagnosis of underlying pathology. The Neer's test can be implemented to detect rotator cuff tendon impingement under the coracoacromial notch.[11] While stabilizing the scapula with one hand, use the other to passively abduct the patient's pronated arm. Pain during forward flexion is a positive test. Typically patients with this abnormal finding will experience pain between 60° and 120° (Fig. 3.4). The Hawkins maneuver is useful in identifying a subacromial impingement or

JAYPEE BROTHERS

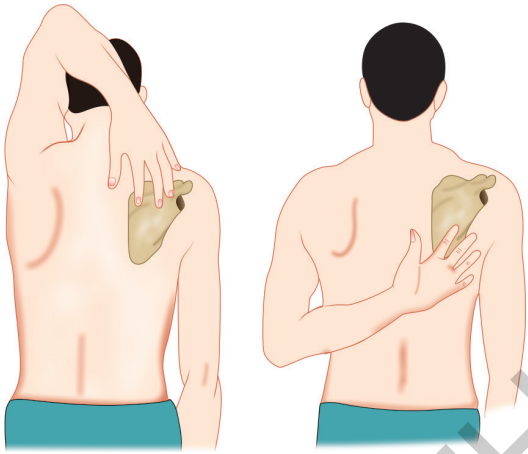

Fig. 3.3: Evaluation of range of motion of the shoulder in external rotation and internal rotation.

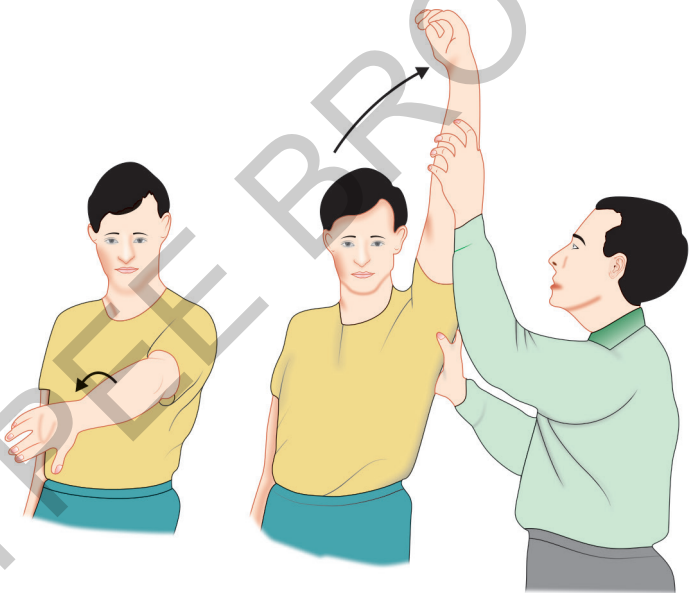

Fig. 3.4: Neer's test for impingement is performed by stabilizing the scapula and forward flexion of the patient's pronated arm.

tendonitis of the rotator cuff; this tests for the integrity of the infraspinatus (and teres minor muscle). A positive Hawkins sign is pain upon internally rotating the shoulder in question at 90° (in front of the chest); the arm should be stabilized while pushing down on the forearm. To improve the sensitivity of the Hawkins test, perform the infraspinatus test and painful arc test.[11] Position the patient's elbow so that it is at the side and at 90° with the humerus medially rotated

JAYPEE BROTHERS

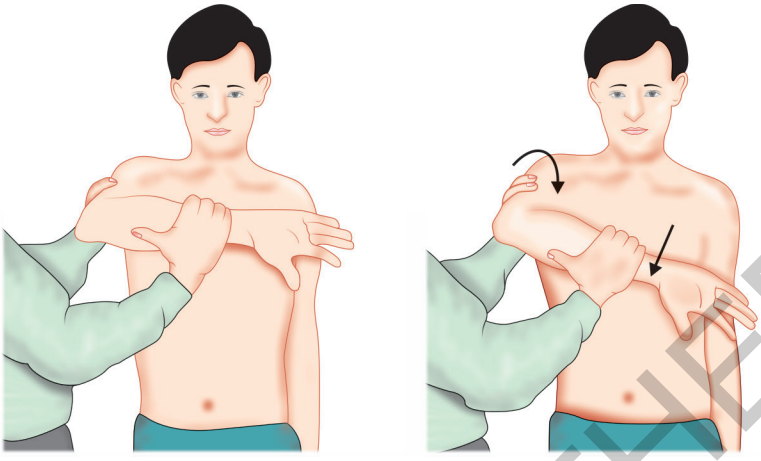

Fig. 3.5: Hawkins test is performed by internally rotating the arm with the shoulder at 90 degrees.

to 45°; apply rotational force medially (Fig. 3.5). Pain or inability to counter applied force is indicative of infraspinatus strain. Ask the patient to abduct the arm and bring it back to neutral, a positive painful arc test is pain between 60° and 120° of elevation during abduction. A drop arm test can be performed to diagnose a rotator cuff tear or supraspinatus strain.[23] Passively abduct the patient's arm in relation to the shoulder to 90°, and ask the patient to slowly lower the arm upon release. Failure to lower the arm in a controlled manner is a positive drop arm test. Note that control of arm motion above 90° abduction is by the deltoid muscle. Similarly the Jobe's test can be used to determine if the integrity of the supraspinatus is compromised. The patient is asked to abduct the arm and hold out his hand with the thumbs pointing down (as if emptying the contents of a can).[13] Provide downward pressure to test the strength of the patient's supraspinatus muscles (should provide substantial oppositional force) (Fig. 3.6). It is necessary to assess if there is injury to the labrum of the shoulder. Instruct patient to flex the arm to 90° with full extension of the elbow. Ask patient to internally rotate the arm so that the thumb points down and have patient resist downward force by the examiner. Ask patient to externally rotate the arm so that the thumb is up and provide downward force. Patient should be able to provide force upward. If the patient experiences pain, there may be associated clicking, and with downward pressure against the internally rotated arm and alleviation of pain when downward force is applied to an externally rotated arm, this may indicate damage of the labrum.

Swelling, warmth, erythema, pain with range of motion or an effusion can indicate infection. Focal posterior swelling over the olecranon with tenderness, warmth or erythema is consistent with bursitis in the absence of injury. Check for rashes or discoloration. Identify an excessive (cubitus valgus) or decreased

JAYPEE BROTHERS

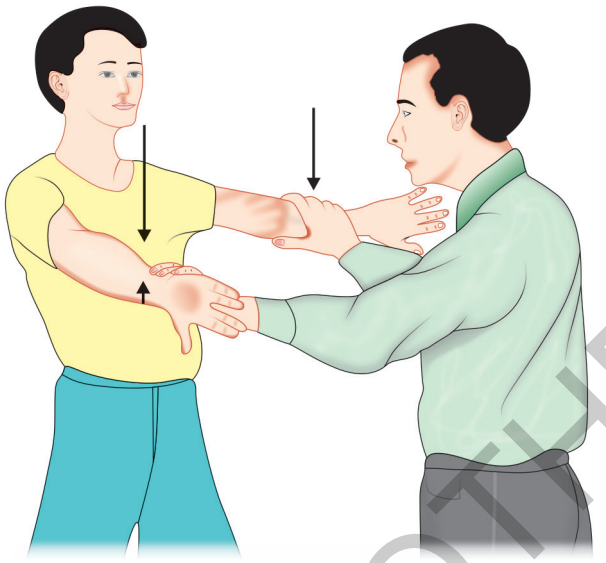

Fig. 3.6: Jobe's test is performed by applying downward force to the patient's abducted arm with the thumbs pointed down.

(cubitus varus) carrying angle of the elbow; females will have a larger expected carrying angle (Fig. 3.7). Assess the range of movement and integrity at the elbow joint with active and passive flexion and extension, and supination and pronation with flexed forearm. At the elbow, the patient should be able to extend the forearm to 0° and flex to 150°, and rotate the forearm with flexed elbow to 70° in pronation and 85° in supination. The patient should be able to perform movements with ease and without pain even with introduction of oppositional force. Patient may have weakness when tested with an opposing force if a neurologic injury is present or secondary to pain in the setting of trauma. Take note of crepitus or misalignment during range of motion.

Evaluate the muscles of the hand and wrist; the patient may present with abnormal contours of the hand with obvious signs of muscle wasting and/or deformities such as nodules. Identify pain or weakness by having the patient to sustain a tight and firm grasp on the examiner's two fingers. Ask patient to open and close the hand; patients should be able to do that 20 times in 10 seconds. Patients who are slow to open and close the hands at a rate lower than 20 times in 10 seconds, suggest stiffness or neurologic impairment from rheumatoid arthritis or cervical myelopathy respectively. In this test, patients may accelerate in the rate at which they open and close their hands, which is a hallmark sign of Lambert-Eaton myasthenic syndrome (patients with Lambert-Eaton will have progressive ease in motion when performing repetitive activities). Range of motion for ulnar and radial deviation is from 0° to 20° in the radial direction and 0°–30° in the ulnar direction. Extension

JAYPEE BROTHERS

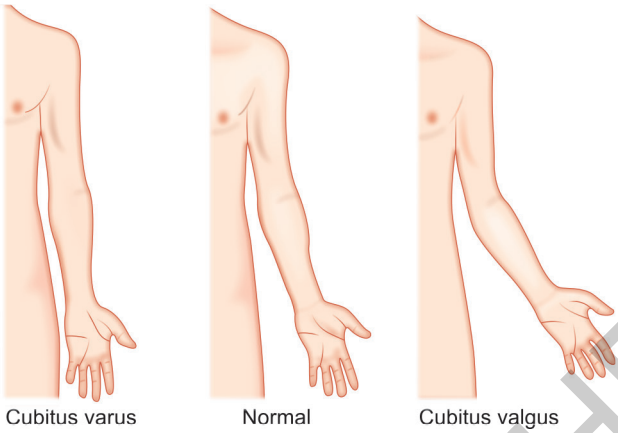

Fig. 3.7: Carrying angles of the elbow.

and flexion of the hand at the wrist both range from 0° to 60° in their respective directions. Evaluate range of motion of the hand at wrist, thumb and digits; weakness and inability to flex or extend without pain is indicative of pathology. Patient should be able to extend and flex the wrist and digits and oppose the thumb. Successful execution of full range of motion at the thumb at the metacarpophalangeal joint should continue up to 60° (flexion) and at the interphalangeal joints to 80°. Flexion of the digits at the metacarpophalangeal joints should continue up to 90° and extension up to 30°. Abduction of the digits at the metacarpophalangeal joints should continue up to 25°.[30]

If patient experiences upper limb pain at rest and throughout physical exam, a diagnosis of thoracic outlet syndrome may be considered. There are controversies in regards to diagnosis (and management) of thoracic syndrome as compression may be of vascular, neurogenic, or a combination of both in origin.[27] Patient can present with a range of symptoms in regards to severity and progression of the compression. A diagnosis of thoracic outlet syndrome is determined when there is compressive pressure on the nerves and blood vessels that travel in the space between the clavicle and first rib.[28] Start the patient with an elevated arm stress test. Ask patient to raise both arms over the head (at 90° abduction) and to open and close fists for a few minutes. In thoracic outlet syndrome, there is compression of the brachial plexus and/or blood vessels as they leave through the thoracic outlet between the clavicle and the first rib to innervate and supply the arm respectively (Fig. 3.8). Patients may complain of a vague pain that is over the neck, shoulder, arm and lateral hand region. There may be swelling or redness of the arm; patients may also feel cold to the touch distally. Overhead actions recreate or exacerbate symptoms consistent with thoracic outlet syndrome findings (i.e. generalized aching sensation in the neck and/or arm with pain, numbness or tingling in the forearm that may extend to lateral digits). Visual

JAYPEE BROTHERS

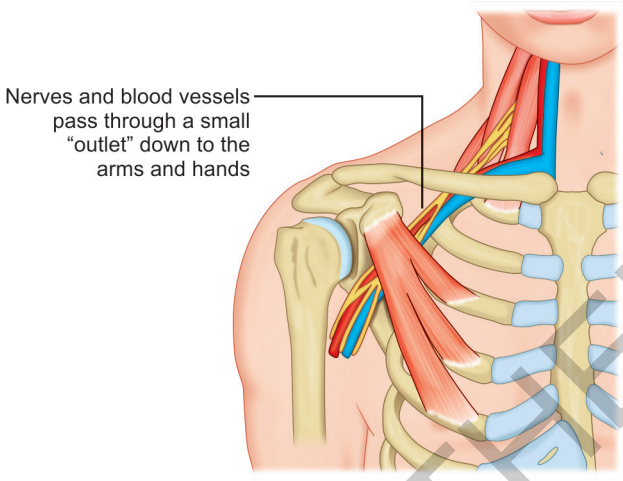

Fig. 3.8: Brachial plexus and blood vessels traveling under the clavicle to the arm.

inspection for cyanosis, edema, irregularities in the supraclavicular fossa, and muscular atrophy of the hand is common. Further diagnostic measures with X-rays, computed tomography (CT) scan, magnetic resonance imaging (MRI) and ultrasound may be necessary. Non-invasive ultrasound imaging should be used first to determine if there is occlusion to the subclavian artery or potential bony and/or soft tissue abnormalities. Additional X-ray, CT or MRI with arteriography/venography may be taken to further examine the integrity of the subclavian artery, and identify the location of vascular compression and related pathology. Injection of local anesthetic to the anterior scalene muscle may be considered as a diagnostic measure; relief of pain may indicate thoracic outlet syndrome.

When evaluating a patient who presents with generalized and widespread musculoskeletal pain, who can perform active and passive motions with relative ease, ask the patient to elaborate more about the presentation and origin of the pain and associated symptoms. Patients may describe widespread musculoskeletal pain along with feeling a sense of fatigue, delay in cognitive activities, sleep dysfunction, stiffness, anxiety and depression. Through eliminating other potential systemic neuromuscular and musculoskeletal diseases by physical examination and laboratory testing, and obtaining a throughout history, the examiner may the examiner may diagnose the patient with fibromyalgia.[21]

NEUROLOGIC EXAMINATIONS

When patients present with upper limb pain, it is important to maintain awareness of pyramidal tract and myotome and dermatome distribution of

JAYPEE BROTHERS

for detailed information on orthopedic books, visit our website www.jaypeebrothers.com, for detailed information on orthopedic

Differential Diagnosis in Spine Surgery

Salient Features

- Covers the spectrum of conditions which patients with spinal and nonspinal pathology may present to the clinician
- Provides typical case presentations as well as the initial workup for each condition
- Focuses not only on the most common causes for neck and back pain, but also discusses less common conditions
- Presents 'red flags' for each patient scenario that could be indicative of serious conditions, as well as referred pain to the spine.



John D Koerner MD graduated from Wake Forest University, Winston-Salem, North Carolina, USA. He received his medical degree and completed his residency in Orthopedic Surgery at New Jersey Medical School, Rutgers University, Newark, New Jersey, USA. Dr Koerner completed a Spine Fellowship at Thomas Jefferson University/Rothman Institute, Philadelphia, Pennsylvania, USA. He serves as a Deputy Editor for Clinical Spine Surgery and is currently in practice at Hackensack University Medical Center in New Jersey, USA.



Alexander R Vaccaro MD PhD MBA is President of the Rothman Institute, Chairman and Professor of the Department of Orthopedic Surgery, and Professor of Neurosurgery at the Sidney Kimmel Medical College, Thomas Jefferson University in Philadelphia, Pennsylvania, USA. Dr Vaccaro is also the Co-Director of the Regional Spinal Cord Injury Center of the Delaware Valley, USA, and is also Co-Chief of Spine Surgery and the Spine Fellowship program.



Daniel H Kim MD FAANS FACS is Professor in the Department of Neurosurgery at The University of Texas Medical School, Houston, Texas, USA, where he also serves as the Director of Spinal Neurosurgery and Reconstructive Peripheral Nerve Surgery. Dr Kim is an expert in minimally invasive spinal surgery, both endoscopic and robotic, and peripheral nerve surgery.

Available at all medical bookstores
or buy online at www.jaypeebrothers.com

JAYPEE BROTHERS
Medical Publishers (P) Ltd.
www.jaypeebrothers.com

Join us on facebook.com/JaypeeMedicalPublishers

Shelving Recommendation
SPINE SURGERY

ISBN 978-93-85999-47-5