ks, visit our website **www.jaypeebrothers.com,** for detailed information on obstetrics & gynecology books, visit our website **www.jaypeebrothers.com**

SMART OBGYN 2016

Desire for Excellence

OBSTETRICS GYNECOLOGY

SMART Obstetrics & Gynecology Handbook


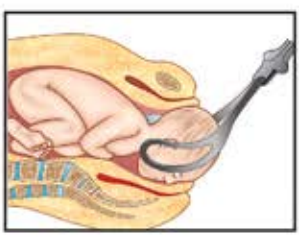
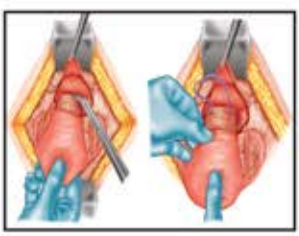


Nandita Palshetkar
Rishma Dhillon Pai
Pratik Tambe
Deepali Kale
Rohan Palshetkar

JAYPEE

Contents

1. **Intrauterine Insemination: Patient Selection and Workup** 1
   Rishma Dhillon Pai
   ***Rationale** 1*
   ***Indications of Intrauterine Insemination** 1*
   ***Prerequisites for Intrauterine Insemination** 3*

2. **Ovulation Induction** 7
   Nandita Palshetkar
   ***Rationale for Inducing Ovulation while Carrying Out Intrauterine Insemination** 7*
   ***Procedure of Ovarian Stimulation and Induction** 7*

3. **The Luteal Phase** 24
   Hrishikesh Pai
   ***Luteal Phase Support** 24*
   ***Role of Antibiotics** 26*

4. **Nuchal Translucency** 28
   Shailesh Kore, Neha Saxena
   ***Increased Nuchal Translucency—Pathophysiology** 28*
   ***Measurement of Nuchal Translucency** 29*
   ***Repeatability in the Measurement of Nuchal Translucency** 31*
   ***Nuchal Translucency and Chromosomal Defects** 32*
   ***Accuracy of Nuchal Translucency as a Screening Marker** 33*

5. **Applications of Three-dimensional Ultrasound in Obstetrics** 38
   Narendra Malhotra, Jaideep Malhotra, Neharika Malhotra Bora
   ***Three-Dimensional Voluson Technique** 40*
   ***Digital Three-Dimensional Sonography** 40*
   ***Three-Dimensional Ultrasound in Obstetrics** 40*
   ***Limitations of Three-Dimensional Ultrasound** 46*

6. **Intrauterine Growth Restriction: Diagnosis and Management** 47
   Anupama Rao, Zenab Tambawala
   ***Screening for Intrauterine Growth Restriction** 48*
   ***Confirmation of Diagnosis and Further Surveillance** 50*
   ***Management of IUGR** 52*

7. Assessing Fetal Wellbeing in Third Trimester **56**
Ameet Patki, Deepali Kale

Fetal Movement Counting 57
Nonstress Test 57
Acoustic Stimulation Tests 59
Contraction Stress Test 59
Biophysical Profile 60
Uterine Artery Doppler 62
Umbilical Artery Doppler 62
Other Fetal Artery Doppler Parameters 62

8. Imaging Modalities for Adherent Placenta **65**
Vinita Salvi

Diagnosis 65
Ultrasonography 66
Magnetic Resonance Imaging 67

9. Intrapartum Monitoring of Fetus: What's New? **69**
Vandana Bansal

Intermittent versus Electronic Fetal Monitoring 70
Electronic Fetal Monitoring: Definitions 72
Classification of Fetal Heart Rate Tracings 82
Methods of Intrauterine Resuscitation used for Category II or Category III Tracings Conservative Measure (NICE 2014) 84
Adjuncts to the use of Continuous Electronic Fetal Monitoring including Fetal Blood Sample 85
Interpretation of FHR Traces/Cardiotocographs (NICE Guidelines) 86
Principles of Intrapartum CTG Trace Interpretation 90
Electronic Fetal Monitoring and Record-keeping 90

10. Vaginal Hysterectomy in Case of Previous Lower Segment Cesarean Section **92**
Shirish S Sheth

Access to the Vesicouterine Peritoneum: Anterior Pouch 92
Surgical Technique in Women with History of Two or More C-Sections in Past 97

11. Management of Third and Fourth-degree Perineal Tears **101**
Bipin Pandit

Prediction and Prevention of Obstetric Anal Sphincter Injury 102
Surgical Techniques 105
Overlapping 105
End-to-end (Approximation) 105

Postoperative Management 107
Prognosis 108
Future Deliveries 109
Risk Management 109

12. Human Papillomavirus Vaccination **111**
Neerja Bhatla, Deepali Kale

Types of Vaccine and Vaccination Schedule 112
The Future Perspective 114

13. Treatment of Cervical Intraepithelial Neoplasia **116**
Nikhil Purandare, Deepali Kale

Treatments of Cervical Intraepithelial Neoplasia 117
Excision and Ablative Techniques 117
Glandular Disease 121
Follow-up after Treatment 121

14. Electrosurgery and Energy Use at Endoscopy **123**
CV Hegde

15. The Art of Laparoscopic Suturing **127**
Rajendra Sankpal

Needle Holder 128
Assisting Needle Grasper 128
Choice of Needles 128
Choice of Laparoscope 128
Choice of Suture Material 129
Camera Port 129
Ancillary Ports 129
Taking a Bite with Needle 132
Placing a Knot 132

16. 3D Laparoscopy **136**
Rakesh Sinha, Gayatri Rao, Shweta Raje

Brief History of 3D Vision 137
Physics of 3D 138
Stereoscopic View 139
Learning Curve 142
Costs 143
Benefits of 3D Laparoscopy 145

17. Laparoscopic Hysterectomy: Easy and Safe **147**
Prakash Trivedi, Sandeep Patil, Animesh Gandhi, Soumil Trivedi

Indications of Laparoscopic Hysterectomy 148

Bipolar and Laparoscopic Suturing Technique 148
Ligasure and Harmonic Scalpel 148
Enseal and Harmonic Scalpel 150
Thunderbeat and Harmonic Scalpel 150
Tackling the Uterine Artery at the Origin 152
Morcellation Controversy and the Solution 154
The Lateral Window for Difficult Bladder Dissection 155
Single-Port or Single-Incision Multiple-Port Technique 155
Robotic Surgery for Removal of Uterus 157
Complications in TLH 157

18. Office Hysteroscopy **159**
Pratik Tambe, Pooja Bandekar

Operative Procedure 160
Technological Improvements 160
Reliability and Feasibility 160
Operative Office Hysteroscopy 161
Comparison with Daycare Hysteroscopy 162
Operative Office Hysteroscopy without Anesthesia 163
Pain Relief during Outpatient Hysteroscopy 163
Cochrane Meta-analysis 164
Postmenopausal Bleeding 164
Pre-IVF Office Hysteroscopy 165
Recurrent Implantation Failure 165

19. Hysteroscopy in Asherman's Syndrome **167**
Neeta Warty, Rajkishor Sawant

Incidence 168
Etiopathology 168
Classification 169
Relevant Anatomy 170
Role of Hysteroscopy 170
Optimizing Results and Preventing Recurrence 173
Our Experience 175
Postprocedure 176
Irrigation Modalities 176
Complications 177
Sequelae 178
Hysteroscopy under Guidance 181
Other Techniques 182

20. The Incompetent Cervix 186
Ameya Purandare

Etiology 187
Pathogenesis 188
Diagnosis 188
Methods of Treatment 191
Technical Details 192
Evidence-based Medicine—RCOG Trial 199
Possible Developments 201

21. Operative Vaginal Delivery 203
Nozer K Sheriar, Ameya Purandare

Prevalence of Use 203
Classification 204
Indications and Contraindications 204
Prerequisites 204
Choice of Instrument: Forceps vs Vacuum 207
Forceps 208
Vacuum/Ventouse 220
Post-Delivery Care 226
Training in Operative Vaginal Delivery 226
Future of Operative Vaginal Delivery 227

22. Obstetric Hysterectomy 230
Ganpat Sawant, Aaradhana Wagh

Incidence 230
Indications 230
Surgical Consideration 231
Surgical Technique 231

23. Internal Iliac Artery Ligation in Obstetrics 233
Adi E Dastur, Ameya Purandare

Surgical Anatomy 233
Anatomic Relations of Internal iliac Artery 233
Collateral Circulation 233
Hemodynamic Consequence of Internal Iliac Ligation 234
Indications of Internal Iliac Ligation 235
Success Rate of Internal Iliac Artery Ligation 235
Technique 235
Efficacy 236
Complications 237
Recent Advances 237

24. Laparoscopic Myomectomy **239**
S Krishnakumar, Pratik Tambe
Indications 239
Operative Procedure 240
Laparoscopic vs Hysteroscopic Approach 242
Practice Guidelines 245
Recommendations 245

25. Surgical Management of Endometriosis **248**
Nagendra Sardeshpande
Indications for Surgery 248
Why Surgery? 249
Why Endoscopic Surgery? 249
Preoperative Evaluation 249
Steps of Surgery for Endometriosis 250
Surgery for Deep Infiltrating Endometriosis 253
Decision Making in Endometriosis Associated with Infertility 254
Surgical Management of Endometriomas 254
Role of Adhesion Barriers 259
Surgical Management of Other Common Forms of Endometriosis 259
Other Sites of Endometriosis 262
Pain Relief for Symptomatic Endometriosis 263
Perioperative Management 263
Hysterectomy for Endometriosis 263

Index ***267***

4

Nuchal Translucency

Shailesh Kore, Neha Saxena

INTRODUCTION

Trisomy 21 is one of the most commonly observed chromosomal abnormalities. In 1866, Langdon Down described the phenotypic features of individuals with this syndrome, which was subsequently named after him.[1] He reported that the skin of an individual with trisomy 21 appears to be too large for their body.[1] More than a century later, Szabo and Gellen (1990) described the association between Down's syndrome and neck edema in the first trimester.[2] Nicolaides et al. (1992) referred to this as "Nuchal Translucency."

Nuchal translucency (NT) is the appearance of a collection of fluid under the skin behind the fetal neck in the first-trimester of pregnancy on ultrasound. The term translucency is used, irrespective of whether it is septated or not and whether it is confined to the neck or envelopes the whole fetus.

Many studies have shown established association between increased nuchal translucency measurement and fetal aneuploidies, fetal anomalies, rare genetic syndromes and spontaneous abortions.[3] In past, little was known of the overall long-term outcome of euploid children with increased NT.[4] However, according to the recent reports, it is shown that pregnancy outcomes are much more adverse with an NT that exceeds a set threshold of 3.5 mm, which represents 99th percentile or more for any gestational age window for first trimester screening.[5]

INCREASED NUCHAL TRANSLUCENCY— PATHOPHYSIOLOGY

Lymphatic system of fetus starts developing between 10–14 weeks of gestation. Thus, it was thought that, progressive increase in the width of the translucent area during this period may be indicative of congenital lymphedema.[6]

However, the heterogeneity of conditions associated with increased nuchal translucency indicates that there may more than one mechanism for abnormal collection of fluid below the skin of the fetus.[7]

JAYPEE BROTHERS

The possible mechanisms are:

- Cardiac failure due to associated anomalies of the heart and great vessels.
- Altered composition of the extracellular matrix.
- Abnormal/delayed development of lymphatic system.
- Failure of lymphatic drainage due to impaired fetal movements associated with various neuromuscular disorders.
- Fetal anemia or hypoproteinemia.
- Congenital infections, acting through cardiac failure or anemia.
- Venous congestion in the heart or neck in conditions like diaphragmatic hernia or skeletal dysplasia.

MEASUREMENT OF NUCHAL TRANSLUCENCY

The 'Fetal Medicine Foundation' (London) has laid down following guidelines for correct measurement of 'Nuchal Translucency:[8]

- The gestational period must be 11–13 weeks and six days. At and after 14 weeks of gestation with fetus is often in a vertical position, which makes it difficult to obtain the appropriate image.
- The fetal crown-rump length should be between 45 and 84 mm.
- The magnification of the image should be such that the fetal head and thorax occupy the whole screen.
- A mid-sagittal view of the face should be obtained. This is defined by the presence of the echogenic tip of the nose and rectangular shape of the palate anteriorly, the translucent diencephalon in the center and the nuchal membrane posteriorly. Minor deviations from the exact midline plane would cause non-visualization of the tip of the nose and visibility of the zygomatic process of the maxilla (Fig. 4.1).
- The fetus should be in a neutral position, with the head in line with the spine. Failure to visualize sonolucent amniotic fluid between chin of the fetus and thorax indicates that fetus is in hyperflexed position. When the fetal neck is hyperextended the measurement can be falsely increased and when the neck is hyperflexed, the measurement can be falsely decreased.
- Care must be taken to distinguish between fetal skin and amnion. In case of doubt, sonographer should wait for fetal movement clearly away from the amnion.
- The widest part of translucency must always be measured.
- Measurements should be taken with the inner border of the horizontal line of the calipers placed on the line that defines the nuchal translucency thickness—the crossbar of the caliper should be such that it is hardly visible as it merges with the white line of the border, not in the nuchal fluid (Fig. 4.2).
- In magnifying the image (pre- or post-freeze zoom) it is important to turn the gain down. This avoids the mistake of placing the caliper on the fuzzy edge of the line which causes an underestimate of the nuchal measurement.

JAYPEE BROTHERS

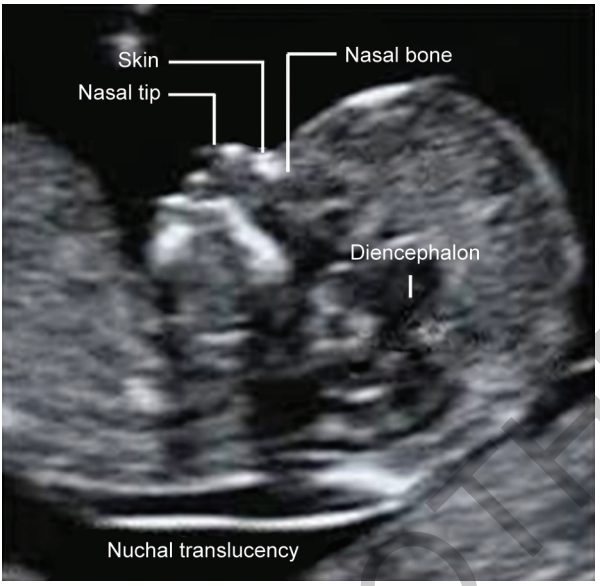

Fig. 4.1: Nuchal translucency measurement by ultrasound

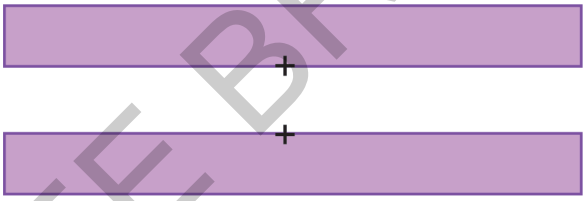

Fig. 4.2: Correct placement of calipers for measurement of nuchal translucency

- During the scan more than one measurement must be taken and the maximum one that meets all the above criteria should be recorded in the database.

The use of a semiautomated technique for the measurement of NT improves the accuracy of measurements. This measurement obtained is similar to that obtained manually and it is, therefore, applicable to the software of the Fetal Medicine Foundation.

Nuchal cord has clinical implications on the measurement of NT in the first trimesters of pregnancy.[9,10] In cases of loop of cord, the average of the two measurements of NT above and below the cord is taken to avoid a falsely increased NT.

According to the Fetal Medicine Foundation' (London) it was also found that:

- In 95% cases, NT can be measured successfully by transabdominal ultrasonography, while remaining 5% cases may require vaginal route.

JAYPEE BROTHERS

The extremely obese women or patients with acutely retroverted uterus may require vaginal ultrasonography.

- To obtain optimum measurement, ultrasound machine should be of good quality, should have a video-loop function and the caliper should be able to provide measurements to one decimal point. The Doppler machine may be useful in certain cases.
- The sonographer performing scan should be capable of obtaining correct fetal sagittal view required for measurement of crown-rump length. After few hours of supervised training, such sonographer can acquire skill of measuring 'Nuchal Translucency'. The sonographer should take adequate time (approximately 10 minutes) to get proper image by adhering to standard guidelines.
- The ability to measure nuchal translucency and obtain reproducible results improves with training; good results are generally achieved after 80–100 supervised or audited scans.[11]
- The distribution of nuchal translucency measurements, quality of images in terms of adherence to standard guidelines like magnification, section, caliper placement, skin line and visualization of the amnion separate from the nuchal membrane are taken into account in the audit of the results.[12] (Herman A 1998)
- The ability to achieve reliable measurement of nuchal translucency is dependant on motivation of the sonographer. A study by Roberts LJ[13] (1995) comparing the results obtained from the hospitals where nuchal translucency was used in clinical practice for intervention to those from hospitals where they merely recorded the values but did not act on the results, reported that, in the interventional group, successful measurement of nuchal translucency was achieved in 100% of cases and measurement was more than 2.5 mm in only 2.3% of cases; while the respective percentages in the other group were 85% and 12%.
- It is necessary that all operators follow same standard criteria to achieve uniformity of results.
- The maximum thickness of subcutaneous translucency between the skin and the soft tissue overlying the cervical spine should be measured by placing the calipers on the lines as shown the Figure 4.1.

REPEATABILITY IN THE MEASUREMENT OF NUCHAL TRANSLUCENCY

A potential criticism of screening by ultrasound is that scanning not only requires highly skilled operators but it is also prone to operator variability. But various studies have confirmed the good repeatability in the NT measurement. The prospective study by Pandya et al.[14] has showed that the intraobserver variability was less than 0.54 mm and interobserver variability was less than 0.62 mm in 95% of the cases. The same study also demonstrated that the caliper placement repeatability was similar to the intraobserver and interobserver repeatability, suggesting that a large part of the variation in

JAYPEE BROTHERS

the measurement can be accounted for caliper placement rather than the generation of the image. Digital image processing and automation of caliper placement can reduce the variation of measurements.[15]

Ultrasound examination of the fetus is a subjective process that is highly dependent on operator skills and the quality of the ultrasonography equipment. These limitations militate against the deployment of ultrasound as a screening tool in the manner in which maternal serum biochemistry has been used.[16]

NUCHAL TRANSLUCENCY AND CHROMOSOMAL DEFECTS

Increased nuchal translucency (Fig. 4.3) can be associated with a number of anomalies, including:

- Aneuploidy—trisomies (including Down's syndrome) and Turner's syndrome
- Nonaneuploidy structural defects and syndromes—congenital diaphragmatic hernia, congenital heart disease, omphalocele, skeletal dysplasia, fetal infections, etc.[17–19]

There have been various researches to establish the association between increased NT and adverse pregnancy outcome in karyotypically normal fetuses.[20]

Sairam et al. reported the presence of an increased NT as an independent risk for fetal cardiac and extracardiac defects in patients with a normal karyotype.[21] Studies by Hyett et al. have also shown an increased prevalence of congenital heart diseases with raised NT thickness.[22]

In most of the women with increased NT, as gestation progresses, the region of nuchal translucency might either regress or evolve into nuchal edema or cystic hygroma.



Fig. 4.3: Increased nuchal translucency (NT)

JAYPEE BROTHERS

In chromosomally normal fetuses where NT regresses, a large proportion will have a normal outcome (but spontaneous regression does not however, mean a normal karyotype).

Other possibilities of erroneous reporting of increased NT can be incorrect measurement technique, chorioamniotic separation, fetal neck skin thickening due to first-trimester hydrops fetalis or presence of nuchal cord. These possibilities should be ruled out before deciding about further course of action. In few cases, repeat examination at higher center may be warranted.

ACCURACY OF NUCHAL TRANSLUCENCY AS A SCREENING MARKER

The detection rate of about 75–80% can be obtained by screening of fetuses by NT alone with maternal age for trisomy 21 and other major aneuploidies with a false positive rate of 5%. The detection rate can be improved to 90% by a combination of NT with maternal serum free β-hCG and pregnancy-associated plasma protein A (PAPP-A). However, the detection rate can further be increased up to 95% and the false positive rate can be reduced to 3% by taking into consideration the nasal bone, ductus venosus flow and tricuspid flow.

The measurement of nuchal transparency is a potentially useful 1st trimester screening tool, as 65–85% of trisomy fetuses and other, nontrisomy abnormal fetuses show increased NT. Abnormal findings warrant further evaluation on a targeted basis.

At 12 weeks of gestational age, an "average" nuchal thickness of 2.18 mm has been observed; however, up to 13% of chromosomally normal fetuses present with a nuchal translucency of greater than 2.5 mm. Thus, for even greater accuracy of predicting risks, the outcome of the nuchal scan may be combined with the results of simultaneous maternal blood tests. In pregnancies affected by Down's syndrome there is a tendency for the levels of hCG to be increased and PAPP-A to be decreased. There has been a reduction in false positive rates with the use of nuchal scanning over the previous use of just biochemical blood profiling alone.[23]

Since early 1990s, many studies demonstrated the association of increased nuchal translucency at 11–14 weeks and chromosomal defects, the sensitivities of various studies ranging from 20 to 80%. This variation in the results was probably because of difference in maternal age distribution of the population studied, 'cut off' value of abnormal translucency measurement, which ranged from 2 to 10 mm. Also difference in criteria or protocol in measurement of the nuchal translucency led to this variation. Subsequent larger study by Pandya PP[24] (1995) & Szabo & Gellen (1995) for screening of downs syndrome had sensitivities ranging from 75–80%, with acceptable false positive rate. Nicolaides et al.[25] in 1994 reported a series of 1273 pregnancies in which a nuchal translucency >= 2.5 mm was seen in 84% of fetuses with trisomy 21 and 4.5% of normal fetuses. Also, Comas C in their

JAYPEE BROTHERS

study reported the prenatal detection rates of trisomy 21 greater than 95% and a 5% false-positive rate with an early second trimester nuchal translucency measurement (Table 4.1).[26]

It must be remembered that mean measurement of nuchal translucency is around 1.5–2.0 mm. If 'cut off' value for screen positive is far above the mean, though the test will become more specific, but it will have very low sensitivity. Thus, it is essential to keep cut off value at level where test will give good sensitivity with acceptable (<5%) false positive rate. As NT increases with gestation, instead of using standard cut off, it is necessary to use gestation related multiple of the median (MoM) value/cut offs to decide whether patient is screen positive or not. Actual risk assessment by using software taking into consideration maternal age and other demographic/risk factors along with NT measurement with or without maternal serum dual markers values (MoM) is more appropriate method of screening and useful in counseling the couple.

Appropriate training, high motivation and adherence to a standard technique/criteria are required for successful screening program with good sensitivity with acceptable false positive rate. According to Monni et al.[27,28] detection rate of trisomy 21 in their study improved from 30 to 80% by following the standard guidelines. The accuracy and repeatability greatly depends on level of competence of the staff which can be achieved by proper and adequate training, certified by external agency. It should be subjected to quality control with high standard precision equipment and clinical protocol.[12]

One Stop Center for Assessment of Risk (OSCAR)

Fetal Medicine Foundation (FMF) recommends universal screening, that is, all women between 11 and 13^{+6} weeks should be offered combined first trimester screening (Age+ NT+ maternal serum PAPP-A and β-hCG). With technological advances, it is now possible to give report of screening and risk assessment in one visit. Actual risk assessment is done by using software using age, other risk factors along with NT and maternal serum markers (MoMs). Rather than saying patient as screen positive or negative, actual final risk is told to the patient/couple. The couple is then asked to take decision after nondirectional counseling about further testing. In many cases, women with increased risk are subjected to invasive testing with chorion villus sampling for definitive diagnosis. However, this procedure carries a small

TABLE 4.1: Results of studies of screening for trisomies using nuchal translucency measurement

Author	*Gestation (weeks)*	*N*	*Sensitivity*	*False-positive ratio*
Pandya et al[24]	10–14	1763	75%	3.6%
Nicolaides et al[25]	11–14	1273	84%	4.4%
Comas[26]	11–16	11, 281	95%	5%

JAYPEE BROTHERS

risk of miscarriage. Thus, it is necessary to have screening done with good detection with low false positive rate. False positive rate can be reduced greatly by adding other markers like nasal bone, ductus venosus flow and tricuspid flow. Also non-invasive prenatal test (NIPT) which uses cell-free fetal DNA in maternal blood can be used in high risk/screen positive cases to select only those who will actually require invasive testing.

SUMMARY AND CONCLUSION

- Nuchal translucency is a promising first trimester screening tool for the detection of chromosomal anomalies and congenital malformations.
- Optimum time for successful measurement of nuchal translucency was 11 and 13^{+6} weeks.
- Prevalence of chromosomal defect is dependent on both nuchal translucency thickness and maternal age.
- All pregnant women between 11 and 13^{+6} weeks should be offered combined first trimester screening (Age+ NT+ Maternal serum PAPP-A and β-hCG).
- The risk of an adverse fetal outcome remains and increases with increasing NT even in a fetus with a normal karyotype.
- For reproducible and accurate measurements of NT, strict adherence to quality guidelines of the technique, training and supervision of the sonologist is of utmost importance.

REFERENCES

1. Langdon Down J. Observations on an ethnic classification of idiots. Clin Lectures and Reports, London Hospital. 1866;3:259-62.
2. Szabo J, Gellen J. Nuchal fluid accumulation in trisomy-21 detected by vaginal sonography in first trimester. Lancet. 1990;336:1133.
3. Pandya PP, Kondylios A, Hilbert L, Snijders RJM, Nicolaides KH. Chromosomal defects and outcome in1015 fetuses with increased nuchal translucency. Ultrasound Obstet Gynecol. 1995;5:15-9.
4. Pandya PP, Snijders RJM, Johnson SP, Brizot de Lourdes M, Nicolaides KH. Screening for fetal trisomies by maternal age and fetal nuchal translucency thickness at 10-14 weeks of gestation. Br J Obstet Gynaecol. 1995d;102:957-62.
5. Souka AP, von Kaisenberg CS, Hyett JA, Sonek JD, Nicolaides KH. Increased nuchal translucency with normal karyotype. American Journal of Obstetrics and Gynecology. 2005;192(4):1005-21.
6. Souka AP, Krampl E, Geerts L and Nicolaides KH. Congenital lymphedema presenting with increased nuchal translucency at 13 weeks of gestation. Prenat Diagn. 2002;22:91-2.
7. Nicolaides KH, Sebire NJ, Snijders RJM. Pathophysiology of increased nuchal translucency. In the 11-14 weeks scan: The diagnosis of fetal abnormalities. Carnforth, UK: Patherson publishing; 1999. pp. 95-113.

JAYPEE BROTHERS

8. Nicolaides KH, Sebire NJ, Snijders RJM. Nuchal translucency and chromosomal defects. In the 11-14 weeks scan: The diagnosis of fetal abnormalities. Carnforth,UK: Patherson publishing. 1999; pp.1-63.
9. Lee P, Won H, Chung J, Shin H, Kim A. The variables affecting nuchal skin fold thickness in mid trimester. Prenatal diagnosis. 2003;23(1):60-4.
10. Scheier M, Egle D, Himmel I, Ramoni A, Viertl S, Huter O, et al. Impact of nuchal cord on measurement of fetal nuchal translucency thickness. Ultrasound in Obstetrics & Gynecology. 2007;30(2):197-200.
11. Braithwaite JM, Kadir RA, Pepera TA, Morris RW, Thomson PJ, Economides DL. Nuchal translucency measurement: training of potential examiners. Ultrsound Obstet Gynecol. 1996;8:192-5.
12. Herman A, Mayman R, Dreazen E, Caspi E, Bukovsky I, Weinraub Z. Nuchal translucency audit: a novel image-scoring method. Ultrsound Obstet Gynecol. 1998;12:398-403.
13. Roberts LJ, Bewley S, Mackinson AM, Rodeck Ch. First trimester fetal nuchal translucency: problem with screening the general population. Br J Obstet Gynecol. 1995;102:381-5.
14. Pandya PP, Altman D, Brizot ML, Pettersen H, Nicolaides KH. Repeatability of measurement of fetal nuchal translucency thickness. Ultrsound Obstet Gynecol. 1995;5:334-7
15. Bernardino F, Cardoso R, Montenegro N, Bernardes J, deSa JM. Semiautomated ultrasonographic measurement of fetal nuchal translucency using a computer software tool. Ultrasound Med Biol. 1998; 24:51-4.
16. Scholl J, Iyer C, Heard A, Coletta J, Panda B, Russell M. Thicker nuchal translucency is associated with greater risk of abnormal fetal and neonatal outcomes among fetuses with first trimester cystic hygroma. American Journal of Obstetrics and Gynecology. 2011;204(1, Supplement):S168.
17. Spencer K. Accuracy of Down syndrome risks produced in a first-trimester screening programme incorporating fetal nuchal translucency thickness and maternal serum biochemistry. Prenatal Diagnosis. 2002;22(3):244-6.
18. Ghi T, Huggon I, Zosmer N, Nicolaides K. Incidence of major structural cardiac defects associated with increased nuchal translucency but normal karyotype. Ultrasound in Obstetrics & Gynecology. 2001;18(6):610-4.
19. Goetzl L. Adverse Pregnancy Outcomes After Abnormal First-Trimester Screening for Aneuploidy.Clinics in Laboratory Medicine. 2010;30(3):613-28.
20. Michailidis G, Economides D. Nuchal translucency measurement and pregnancy outcome in karyotypically normal fetuses. Ultrasound in Obstetrics & Gynecology. 2002;17(2):102-5.
21. Sairam S, Carvalho JS. Early fetal echocardiography and anomaly scan in fetuses with increased nuchal translucency. Early Human Development. 2012;88(5):269-72.
22. Hyett J, Moscoso G, Papapanagiotou G, Perdu M, Nicolaides K. Abnormalities of the heart and great arteries in chromosomally normal fetuses with increased nuchal translucency thickness at 11–13 weeks of gestation. Ultrasound in Obstetrics & Gynecology. 1996;7(4):245–50.

JAYPEE BROTHERS

23. Muller F, Benattar C, Audibert F, Roussel N, Dreux S, Cuckle H. "First-trimester screening for Down syndrome in France combining fetal nuchal translucency measurement and biochemical markers". Prenat Diagn. 2003;23(10):833-6.
24. Pandya PP, Goldberg H, Walton B, et al.The implementation of first trimester scanning at 10-13 weeks' gestation and the measurement of fetal nuchal translucency thickness in two maternity units. Ultrsound Obstet Gynecol. 1995;5:20-5.
25. Pandya PP. Ultrasound screening for fetal abnormalities in the first trimester. Prenatal Diagnosis. 1997;17:13:1269-8.
26. Comas C, Torrents M, Muñoz A, Antolín E, Figueras F, Echevarría M. Measurement of nuchal translucency as a single strategy in trisomy 21 screening: should we use any other marker? Obstet Gynecol. 2002;100(4):648-54.
27. Monni G, Zoppi MA, Ibba RM, Floris M, Manca F, Axiana C. Nuchal translucency and nasal bone for trisomy 21 screening: single center experience. Croat Med J. 2005;46(5):786-91.
28. del Carmen Saucedo M, DeVigan Vodovar. Measurement of nuchal translucency and the prenatal diagnosis of down syndrome. Obstet & Gynecol. 2009;114(4):829-38.

JAYPEE BROTHERS

for detailed information on obstetrics & gynecology books, visit our website **www.jaypeebrothers.com,** for detailed information on obstetrics & gyn

SMART Obstetrics & Gynecology Handbook

Salient Features

- Provides the latest evidence-based knowledge needed by general gynecologists, high-risk obstetrics practitioners, endoscopic surgeons and assisted reproductive technology (ART) consultants in obstetrics and gynecology
- Experts from the region and abroad have contributed chapters, which were peer-reviewed by five senior editors who have authored or edited best selling books
- A perfect blend of clinical experience and scientific theories to support the experiences
- Useful as a ready reckoner or a reference text to look up when confronted with the issues we have attempted to address and as a guide for gynecologists and obstetricians practicing infertility, ultrasound, gynecology and obstetric scans
- Includes the current state of evidence and practice guidelines for the busy practitioners.



Nandita Palshetkar MD FCPS FICOG is a Professor of Gynecology, DY Patil Medical College, Navi Mumbai, Maharashtra, India. She is the Head of IVF Unit at Lilavati and Bhatia Hospitals, Mumbai; DY Patil Medical College, Navi Mumbai; Fortis Hospitals in New Delhi, Gurgaon, and Chandigarh. She has been a Senior Vice President, FOGSI (2011). She is currently President, Mumbai Obstetric and Gynecological Society (MOGS). She has been practicing IVF since the last 25 years.



Rishma Dhillon Pai MD DNB FCPS DGO FICOG is a Consultant Gynecologist at the Jaslok and Lilavati Hospitals, Mumbai, Maharashtra, India. She is the Director of the Everywoman Clinics with clinics in Bandra and Kemps Corner, Mumbai. She is the President Elect of Federation of Obstetric and Gynaecological Societies of India (FOGSI) for the year 2017. She is the Vice President, Indian Society for Assisted Reproduction; General Secretary, Indian Association of Gynaecological Endoscopists (IAGE) and Board Member, World Endometriosis Society. She has been practicing IVF since the last 25 years.



Pratik Tambe MD FICOG is an ART Consultant and Gynec-Endoscopic Surgeon who possesses an International Diploma in Advanced Laparoscopic Surgery from Clermont-Ferrand, France. He has been trained in Assisted Reproduction, Brussels, Belgium and in Clinical Embryology, and ICSI at London and Singapore.

He is the Executive Council Member of the MOGS, IAGE and AMC. He is a Mentor for the MOGS Youth Council, and National Coordinator, FOGSI Endocrinology Committee. Besides being faculty for FOGSI training courses in Infertility, IUI and Endoscopic Surgery, he is a peer-reviewer, Journal of Obstetrics and Gynecology of India. He has contributed to several publications for FOGSI and MOGS and has over 150 invited talks at national and international conferences.

He has won several prizes for his scientific paper presentations including the MOGS Dr NA Purandare Prize and the MOGS Dr SD Upasani Prize twice. He has also won the MOGS Best Youth Council Member Award and the MOGS Dr Duru Shah Best Committee Member Award.



Deepali Kale MBBS DGO FCPS DNB FMAS is an Assistant Professor of Obstetrics and Gynecology at Nowrosjee Wadia Maternity Hospital and Seth GS Medical College, Mumbai, Maharashtra, India. She has been trained in Obstetrics and Gynecology at King Edwards Medical Hospital, Mumbai. She has completed FOGSI-ICOG Certification Course in high-risk pregnancy and perinatology under the guidance of Dr Suchitra N Pandit, Kokilaben Dhirubhai Ambani Hospital, Mumbai. She has been trained in obstetric ultrasound and teaches at Ultrasonography Training courses conducted at Nowrosjee Wadia Maternity Hospital. She has been trained and certified in Basic Life Support (BLS) by American Heart Association (AHA). Her areas of interest are high-risk obstetrics and fetal medicine.



Rohan Palshetkar MBBS MS OBGY is Lecturer, Padmashree Dr DY Patil Hospital and Research Center, Nerul, Navi Mumbai, Maharashtra, India. He has Fellowship in Endoscopy.

Available at all medical bookstores
or buy online at www.jaypeebrothers.com

JAYPEE BROTHERS
Medical Publishers (P) Ltd.
www.jaypeebrothers.com

Join us on facebook.com/JaypeeMedicalPublishers

Shelving Recommendation
OBSTETRICS & GYNECOLOGY

ISBN 978-93-85999-72-7