ebrothers.com, for detailed information on orthopedic books, visit our website www.jaypeebrothers.com, for detailed information on orthopedic books

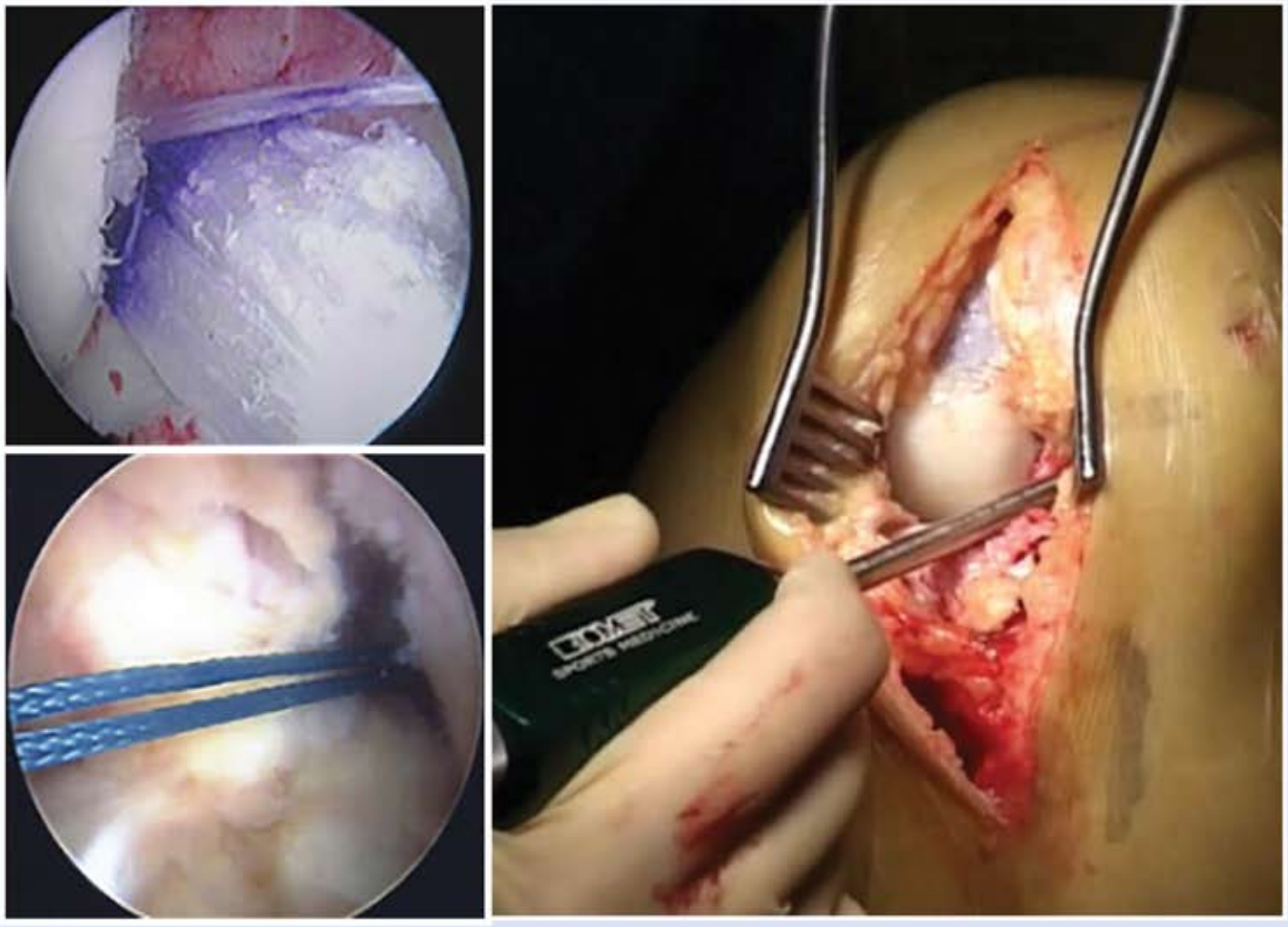

Mastering Orthopedic Techniques

KNEE RECONSTRUCTION

Editors
Rajesh Malhotra
Sunil Apsingi
Krishna Kiran Eachempati
Deepak Gautam

Forewords
David J Deehan
Philippe Neyret
Rene Verdonk

JAYPEE

Contents

1. **Diagnostic Arthroscopy of the Knee** 1
   Vijay Kumar, Vivek Shankar
2. **MRI in Sports Injuries of the Knee** 13
   Sravan Kumar Marupaka, Nori Madhavi, Ravi Mittal
3. **Anterior Cruciate Ligament Injuries: Who Needs Reconstruction?** 39
   Marc Jacob Strauss, Lars Engebretsen
4. **Anatomic Single-bundle Anterior Cruciate Ligament Reconstruction with Hamstrings Using Variable Length Looped Button Device** 47
   Amite Pankaj, Deepak Chahar
5. **Transtibial Anterior Cruciate Ligament Reconstruction** 65
   R Allum, Andrew Price, Sunil Apsingi
6. **Anatomic Anterior Cruciate Ligament Reconstruction: The Double-bundle Technique** 77
   Kellie K Middleton, Akere A Atte, Bart Muller, Freddie H Fu
7. **Anterior Cruciate Ligament Reconstruction in the Skeletally Immature Patient** 93
   J Lee Pace, Mininder S Kocher
8. **Combined Medial Unicompartmental Knee Arthroplasty and Anterior Cruciate Ligament Reconstruction** 103
   BE Campbell, H Pandit, DW Murray, CAF Dodd
9. **Arthroscopic Single-bundle Posterior Cruciate Ligament Reconstruction with Hamstring Graft** 113
   Sunil Apsingi, Krishna Kiran Eachempati, Rajesh Malhotra
10. **Posterior Cruciate Ligament Reconstruction: The Single-bundle Tibial Inlay Technique** 123
    Lutul D Farrow, John A Bergfeld, Waqas Hussain, Michael Griesser
11. **Posterolateral Corner Reconstruction** 139
    Andrew G Geeslin, Robert F LaPrade
12. **Posterolateral Corner Reconstruction: The Modified Larson Technique** 149
    Sunil Apsingi, Krishna Kiran Eachempati, Rajesh Malhotra
13. **Posteromedial Corner Reconstruction** 157
    Andrew G Geeslin, Robert F LaPrade
14. **Reconstruction of Medial Collateral Ligament and Associated Medial Knee Stabilizers** 167
    Amite Pankaj, Raju Easwaran
15. **Surgical Management of Multiple Ligament Knee Injury** 177
    Gregory C Fanelli
16. **Decision Making in Meniscus Tear** 195
    Vaibhav Jain, Deepak Gautam, Ravi Mittal

17. Outside-in Meniscal Repair **201**
Vaibhav Jain, Deepak Gautam, Ravi Mittal

18. Inside-out Meniscal Repair **205**
Vaibhav Jain, Deepak Gautam, Ravi Mittal

19. Meniscal Repair Using the All-inside Technique **209**
Don Johnson, William M Weiss

20. Arthroscopic Meniscectomy **225**
Vijay Kumar D, Sunil Apsingi

21. Arthroscopic Synovectomy **233**
Deepak Gautam, Vaibhav Jain, Ravi Mittal

22. Patellofemoral Joint: Anatomy and Biomechanics **243**
Naman Wahal, Mayur Nayak, Rajesh Malhotra

23. Medial Patellofemoral Ligament Reconstruction **253**
Amit P Chandratreya

24. Trochleoplasty in Patellar Dislocation **275**
Simon Donell

25. Patellofemoral Arthritis **291**
Mayur Nayak, Naman Wahal, Rajesh Malhotra

26. Osteochondral Defect: An Overview of Management and Guide to Decision Making **305**
Deepak Gautam, Vaibhav Jain, Ravi Mittal

27. Osteochondral Autograft Transfer **317**
Sunil Apsingi, Krishna Kiran Eachempati, Rajesh Malhotra

28. Autologous Chondrocyte Implantation **323**
Seok-Jung Kim

29. Tibial Spine Fractures **331**
Marie-Lyne Nault, Mininder S Kocher

30. Arthroscopy Assisted Tibial Plateau Fracture Fixation **341**
Bhavuk Garg, Vivek Shankar, Samarth Mittal

31. Arthroscopic Decompression of Baker's Cyst **351**
Amite Pankaj, Deepak Chahar

32. Osteotomies around Knee and Computer-assisted Surgery **359**
Frederic Picard, Kamal Deep, Dominique Saragaglia

33. High Tibial Osteotomy in Ligament Deficient Knees **371**
Krishna Kiran Eachempati, Sunil Apsingi, AV Gurava Reddy, Rajesh Malhotra

34. Post-traumatic Stiff Knee **385**
J Maheshwari, Vikram A Mhaskar

35. Rehabilitation Protocol for Soft Tissue Reconstruction of Knee **395**
Kanchan Mittal, Deepak Gautam

36. Outcome Measures of Knee **407**
Sahil Batra, Rajesh Malhotra

Index *441*

4

Anatomic Single-bundle Anterior Cruciate Ligament Reconstruction with Hamstrings Using Variable Length Looped Button Device

Amite Pankaj, Deepak Chahar

Overview

Anterior cruciate ligament (ACL) deficiency makes the knee more prone to recurrent trauma leading to meniscal and chondral injury, and early degenerative disease in addition to causing functional limitations. Anterior cruciate ligament reconstruction (ACLR) has become standard orthopedic practice worldwide and the ultimate goal of ACL reconstruction is the restoration of normal knee kinematics in patients with functionally unstable ACL-deficient knees. The reconstructed ligament should provide both sagittal (anteroposterior) and rotational stability. There are various options regarding surgical technique, graft choice and fixation devices during ACLR.

The techniques of ACLR surgery have evolved a great deal over the last three decades with transition from two incision technique (femoral and tibial tunnels drilled separately) to single incision transtibial technique (femoral tunnel drilled through tibial tunnel) in early 1990s to anatomic double bundle and single bundle reconstruction in early 2000s to computer assisted ACL reconstruction in 2010s. The estimated failure rate of ACLR is between 10% and 25%.[1] The majority of failures are caused by technical problems, and an estimated 80% of these technical failures are caused by malpositioning of the femoral tunnel and/or the tibial tunnel.

Although there is lack of consensus amongst surgeons and literature regarding most appropriate techniques and landmarks to guide the surgeon to perform an ACLR with an optimum functional long term outcome, there has been a trend towards recreation of anatomy as far as possible. Transtibial tunnel drilling has been shown to produce a high nonanatomic femoral tunnel that is located outside the native femoral ACL insertion site.[2-4] Recognition that transtibial tunnel drilling results in a nonanatomic vertically oriented femoral tunnel has led to increasing interest in surgical techniques that place the femoral tunnel within the footprint of the native ACL. In this chapter, we describe our surgical technique of anatomic single bundle arthroscopic ACL reconstruction using quadrupled hamstrings.

Indications and Contraindications

The ideal candidate for ACLR is a young, active patient with minimal effusion, good range of motion, good muscle control and who is ready to undergo postoperative rehabilitation. Skeletally immature patients with an ACL tear need to be tackled very carefully and the

JAYPEE BROTHERS

decision to operate should be based on a balanced approach after educating the parents regarding the risks and benefits of operation. Medial compartmental arthritis is not a contraindication for ACLR where a high tibial osteotomy or a unicondylar knee arthroplasty can be combined with ACLR.

Sedentary, inactive and elderly patients are not good candidates for surgery and should be offered a conservative treatment. Patients with advanced degenerative/inflammatory conditions are contraindicated for surgery. Certain professions require consideration regarding the choice of graft such as those who need to kneel regularly in their profession may not be good candidates for patellar bone-tendon graft and professional players who require strong knee flexors such as gymnasts, professional footballers, sprinters and wrestlers may do better with grafts other than hamstrings.

Preoperative Work-up

HISTORY, CLINICAL EXAMINATION AND IMAGING

Patients who have suffered an ACL injury usually give a typical history of a noncontact injury leading on to acute pain and swelling in the knee. They often describe a 'pop' at the time of injury. Any subsequent injury should also be made note of as these patients usually present months or years after the initial injury and repeated trauma may cause meniscal and cartilage injuries that may not have been present initially. Clinical diagnosis is confirmed by Lachman's and Pivot shift tests and any other associated injury is also carefully evaluated.

A preoperative anteroposterior and lateral radiograph of the affected knee, and weight bearing radiographs of both sides on long films are important to rule out any bony injury, joint space narrowing and malalignment. It is also important to assess and document the meniscal, chondral and other ligamentous structures prior to embarking upon the surgery as the patient needs to be adequately counseled regarding the magnitude of surgery, post-operative rehabilitation protocol, and the likely outcome. It is for this reason that magnetic resonance imaging is often asked for during preoperative planning of the patient. It has been shown in clinical studies that the results of meniscal repair are superior when a concomitant ACLR is also performed, since the drilling of bony tunnels allows a number of growth factors to be released into the joint cavity thus enhancing the healing potential of the meniscal tissue. Chondral defects are also commonly encountered in ACL deficient knees and appropriate equipment must be ready to deal with these, should it be necessary.

TIMING OF SURGERY

Anterior cruciate ligament reconstruction (ACLR) should usually be performed after the knee has recovered from the insult of initial trauma and this means that the knee should have gained almost full range of movement which is more or less painless, and the swelling should have reduced substantially. Although three weeks is the usual period that the patients take to achieve these goals, there are no strict guidelines as to when earliest ACLR can be performed. The reason for delaying the surgery is to avoid the increased incidence of arthrofibrosis when ACLR is performed acutely. However, if one is dealing with a high performance professional athlete, early surgery is recommended to shorten the time needed to return to sports.

Surgical Procedure

POSITIONING

After spinal, epidural or general anesthesia, and administering the antibiotic, the patient is positioned on a standard operating table and an examination under anesthesia (EUA) is performed. EUA should include Lachman's test, anterior and posterior drawer tests, varus and valgus stress tests, and a pivot shift test. Dial test should also be performed to check the

JAYPEE BROTHERS

integrity of posterolateral corner. All these should be compared with the normal side as well. If ACL deficiency is confirmed, graft harvest can be performed before diagnostic arthroscopy. However, if the EUA is still equivocal, proceed with the diagnostic arthroscopy first.

After this, a tourniquet is placed around the thigh and a leg holder may be placed around it if a "leg hanging free" position is desired. We prefer not to use the leg holder and position the leg on the table in such a manner that an unrestricted flexion can be achieved intraoperatively without much assistance. We apply a padded side post at the level of the tourniquet and place a foot rest distally at a position such as to keep the knee at 90°–100° of knee flexion **(Figs 4.1A and B)**.

The side post acts as a lateral fulcrum to give valgus stress intra-operatively to inspect the medial compartment and maintains the position of the knee in flexion without any need for manual assistance during the rest of the procedure.

GRAFT HARVEST

A standard anterolateral arthroscopy portal is marked at 1–1.5 cm above the joint line adjacent to patellar tendon and a 3–4 cm longitudinal incision is marked over the pes anserinus starting one fingerbreadth medial to tibial tubercle and two to three fingerbreadths below the joint line **(Fig. 4.2)**.



Figures 4.1A and B: Positioning. (A) Thigh support maintains the desired knee position; (B) A foot-rest is placed in such a fashion that both 90° flexed position and hyperflexed (120°) position can be obtained without the need of an assistant supporting the limb. At 90° the heel rests against the foot-rest while in hyperflexed position the toes rest against it

JAYPEE BROTHERS

Anteromedial portal and accessory anteromedial portal may be marked with a pen although it is best to place these portals under direct vision with a 18G spinal needle. Diagnostic arthroscopy is performed and any associated intra-articular pathology is dealt with. It is often helpful to try to palpate the pes anserinus tendons before making the incision for the graft harvest which may, however, be difficult in obese patients. Some surgeons prefer to make an oblique incision for graft harvest and report marginally less chances of injury to Infrapatellar branch of saphenous nerve. Longitudinal incision, on the other hand, is more extensile and forgiving. This part of the surgery is done with the surgeon standing and the patient positioning as descried above. Other positioning of the patient with the table broken and patient's leg hanging requires the surgeon to be seated and patient's foot is supported in surgeon's lap. After incising the skin and subcutaneous fat the sartorial fascia is visualized and the gracilis and semitendinosus tendons are palpated by rolling the tendons under a finger. Next the sartorial fascia is incised at the lower border of the semitendinosus and the two tendons are identified separately with digital palpation **(Fig. 4.3)**.

Semitendinosus is naturally separated from the gracilis tendon approximately 5–8 cm from the tibial insertion. A curved clamp is placed around the semitendinosus tendon and it is pulled into the wound thus bringing the fascial attachments to gastrocnemius into the wound which can then be easily divided by Metzenbaum scissors **(Figs 4.4A and B)**.



Figure 4.2: Skin markings. High anterolateral portal, far medial portal and an accessory medial portal are marked. A longitudinal incision for graft harvest is marked two to three finger-breadths below the joint line



Figure 4.3: The first shiny layer visible after incising the skin and subcutaneous fat is the sartorial fascia. The sartorial fascia is incised at the lower border of pes anserinus

JAYPEE BROTHERS

Finger dissection is done at this stage to confirm that no fascial bands are remaining before passing the tendon stripper. This step is essential to prevent accidental premature amputation of the tendon graft. A looped suture can be passed around the tendon to secure it and to prevent it from getting retracted proximally after distal detachment **(Fig. 4.5)**.

The tendon is detached distally and the length can be gained by 1–2 cm by taking a strip of periosteum along with the semitendinosus tendon. The distal end of the tendon can be secured with a whipstitch with Ethibond No. 5 suture or fiber wire suture at this stage itself. A closed tendon stripper is then advanced over the tendon in line with the tendon and with a sustained gentle traction on the sutures the stripper is pushed onto the tendon with slight rotatory movement till the tendon gives way **(Fig. 4.6)**.

The tendon should never be pulled vigorously as it may lead to premature amputation of the graft. Commonly, the length of the semitendinosus graft is 28–32 cm which can now be transferred to back table for preparation **(Fig. 4.7)**.

We prefer to harvest only semitendinosus for majority of our isolated single bundle ACL reconstructions but the decision to harvest one or both tendons depends upon the fixation option chosen and the length and quality of the semitendinosus graft. If one chooses a suspensory type of fixation device, shorter graft length can be sufficient. We prefer to place at least 20 mm of graft in the femoral tunnel.

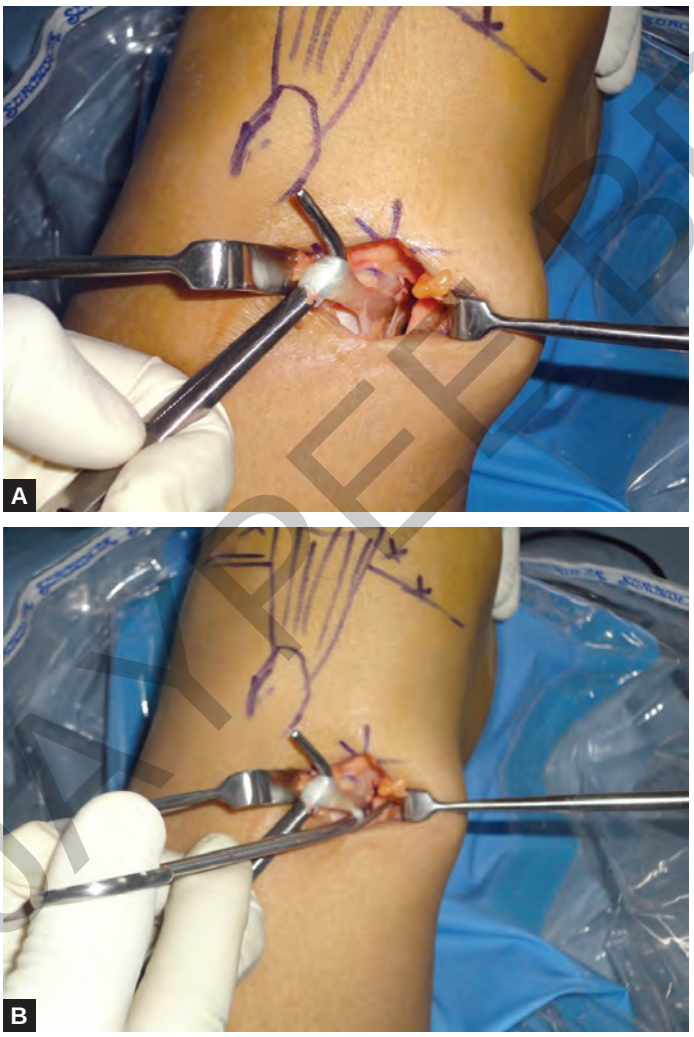

Figures 4.4A and B: Semitendinosus tendon has fascial attachments to the medial head of gastrocnemius muscle which are divided with scissors before a tendon stripper is passed along

JAYPEE BROTHERS



Figure 4.5: A looped suture is passed around the tendon to prevent inadvertent proximal retraction of the tendon after distal division

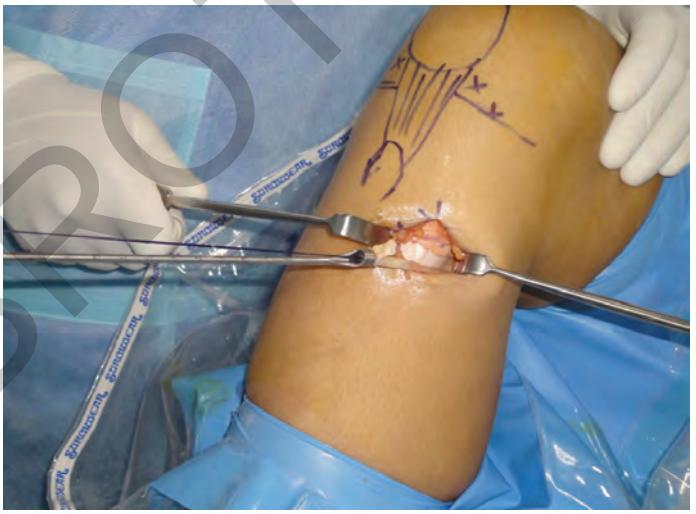

Figure 4.6: The distal attachment of the tendon is divided by taking 1–2 cm of periosteum and a closed tendon stripper is passed along the tendon



Figure 4.7: The harvested semitendinosus graft. 28–32 cm is the usual length that is obtained in an average adult patient

JAYPEE BROTHERS

SEMITENDINOSUS GRAFT PREPARATION

The graft is cleared of any muscle tissue with a blunt instrument; either a metal scale or the flat of handle of scalpel can be used for this purpose. The graft is divided into two equal halves and each strand graft is prepared by whipstitching the each end with No. 5 Ethibond suture/fiber wire. It is advisable to use sutures of different colors or size to differentiate one strand from the other in order to tie each strand separately over a post in the event of poor intereference fixation on tibial side. The two strands thus prepared are then looped around a suture to get a quadrupled graft and the final length and diameter of the graft is measured and noted **(Fig. 4.8)**.

The diameter of the looped end determines the size of femoral tunnel and the end with the sutures dictates the size of the tibial tunnel and the diameter is carefully noted down.

PORTAL PLACEMENT

Anterolateral viewing portal is made in standard fashion close to the patellar tendon about 1 cm above the joint with the knee in mid flexion. Placement of medial portal is very crucial in transportal technique of femoral drilling and it should be made with the help of a spinal needle. The portal should be placed as far medial and low as possible without injuring the articular cartilage on the medial femoral condyle or the medial meniscus. If the portal is placed too close to patellar tendon the direction of femoral tunnel drilling would be erroneous and it would technically be difficult to reach the anatomic center of ACL footprint. In certain situations an additional high anteromedial portal may be utilized as a viewing portal; however, we have found that to be unnecessary in most of our ACLR procedures where we rely on anatomic landmarks to place the femoral tunnel. Nonetheless, in the situations where the anatomic landmarks are not clearly defined, we prefer to use the width measurement technique where we need an accessory portal to pass the measuring device.

TRANSTIBIAL OR TRANSPORTAL

There are two fundamental approaches to place femoral tunnel during ACLR, through the tibial tunnel or through the anteromedial or accessory medial portal independent of tibial tunnel. A lot of work has been done and published in the recent literature that shows that transportal technique may be a better technique to place the femoral tunnel in the center of the anatomic ACL insertion on the femur without compromising the tibial tunnel placement. Although it is not impossible to place the femoral tunnel at the native site through transtibial route, it often compromises the tibial tunnel either in position (usually positioned too posteriorly), length (very oblique and hence short tunnel is usually needed

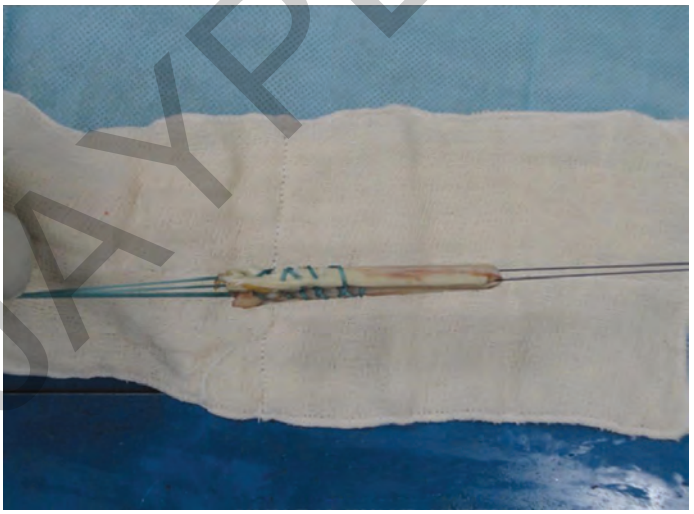

Figure 4.8: Quadrupled semitendinosus graft with whipstitched ends with Ethibond No. 5

JAYPEE BROTHERS

to reach the anatomic point) or inadvertent over-reaming of the tibial tunnel (in an effort to place the femoral tunnel at the anatomic center, the direction of which may not be in line with the tibial tunnel causing unavoidable eccentric reaming of tibial tunnel) which may compromise the tibial fixation of the graft.[3,4] Although transtibial technique is more familiar to surgeons and is technically easier, recent literature is inclined towards transportal technique and we shall describe the latter technique in this chapter.

Transportal technique leads to creation of femoral tunnels that are usually shorter in length and a couple of technical modifications and tricks can be adopted to avoid very short tunnels. In general, we prefer to have intraosseous length of lateral femoral condyle at least 35 mm to enable us to use a looped fixation device such as Endobutton CL (Smith and Nephew) or ACL Tightrope (Arthrex) on the femoral side.

NOTCH PREPARATION AND FEMORAL TUNNEL PLACEMENT

The femoral footprint is debrided carefully with arthroscopic shaver or radiofrequency probe taking care not to damage the native footprint bony anatomy. It is crucial to clear the lateral intercondylar notch to the back and identify the proximal most part of the femoral articular cartilage. The ACL tibial stump is also debrided at this stage and it is important to leave some portion of the tibial stump intact as it is believed to provide proprioception to the neo-ligament. In majority of the cases two distinct bony ridges can be identified on the lateral femoral condyle, lateral intercondylar ridge (also known as Resident's ridge) and lateral bifurcate ridge[5] **(Fig. 4.9)**.

Lateral intercondylar ridge represents the distal and anterior limit of the ACL femoral attachment and the femoral tunnel needs to be proximal and posterior to it. The bifurcate ridge represents the interval between the two bundles of the ACL, anteromedial bundle and posterolateral bundle. The arthroscopic orientation of the intercondylar notch in 90° of knee flexion can be described either as shallow or deep (distal or proximal anatomically) and high or low (anterior or posterior anatomically). There is lot of ambiguity while describing the arthroscopic orientation and it is common mistake to label distal or arthroscopic shallow part of the femoral anatomy as anterior and proximal or arthroscopic deeper part as posterior. Consensus is emerging amongst the authors to use anatomic orientation to avoid ambiguity and confusion and we shall be using the anatomic reference in this chapter **(Figs 4.10A and B)**.

After defining the anatomic landmarks the viewing portal can be changed from anterolateral portal to anteromedial portal and findings are reconfirmed. Anteromedial portal provides an orthogonal view of the lateral femoral notch and anatomic landmarks are better visualized **(Figs 4.11A and B)**.

It is recommended that surgeons use additional high anteromedial portal for viewing to drill the femoral tunnel during the initial few cases of anatomic ACLR.

Freddie Fu et al.[6] are credited with popularizing the anatomic basis of ACLR, double bundle or single bundle, and we believe in performing ACLR based on anatomic landmarks. We prefer to place the center of the femoral tunnel at the bifurcate

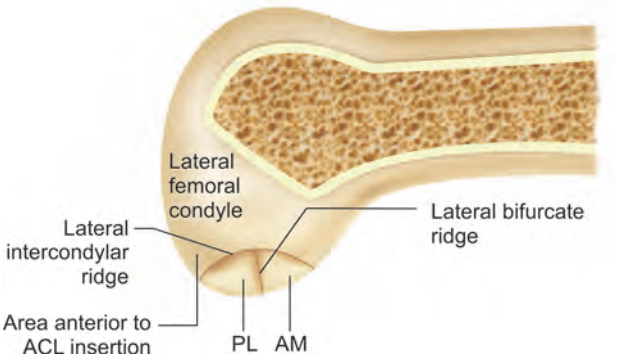

Figure 4.9: Bony ridges on lateral wall of the intercondylar notch. Lateral intercondylar or "resident's ridge" is the first bony ridge on the lateral wall. It denotes the distal and anterior limit of the ACL footprint. The smaller ridge is known as the lateral bifurcate ridge which separates the anteromedial bundle and the posterolateral bundle of ACL

JAYPEE BROTHERS

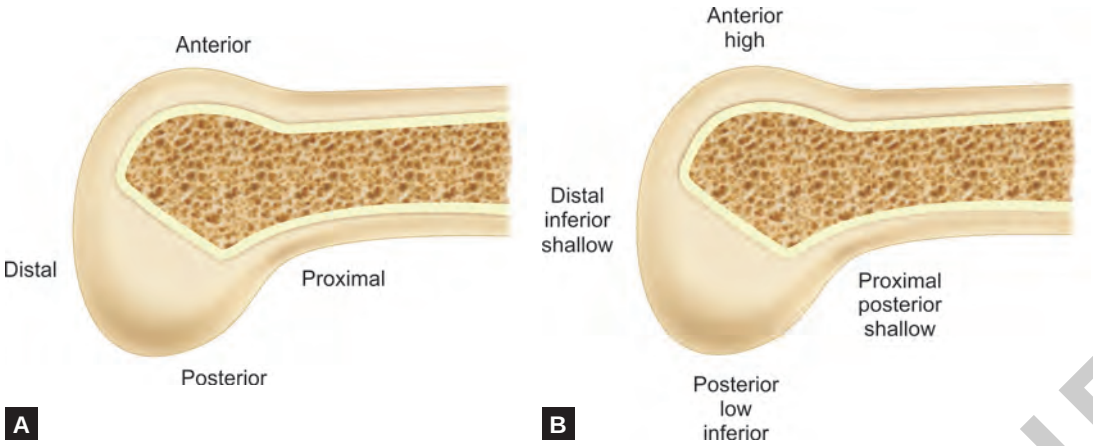

Figures 4.10A and B: (A) Anatomic orientation; (B) Various expression used in literature to describe arthroscopic orientation while making the femoral entry point

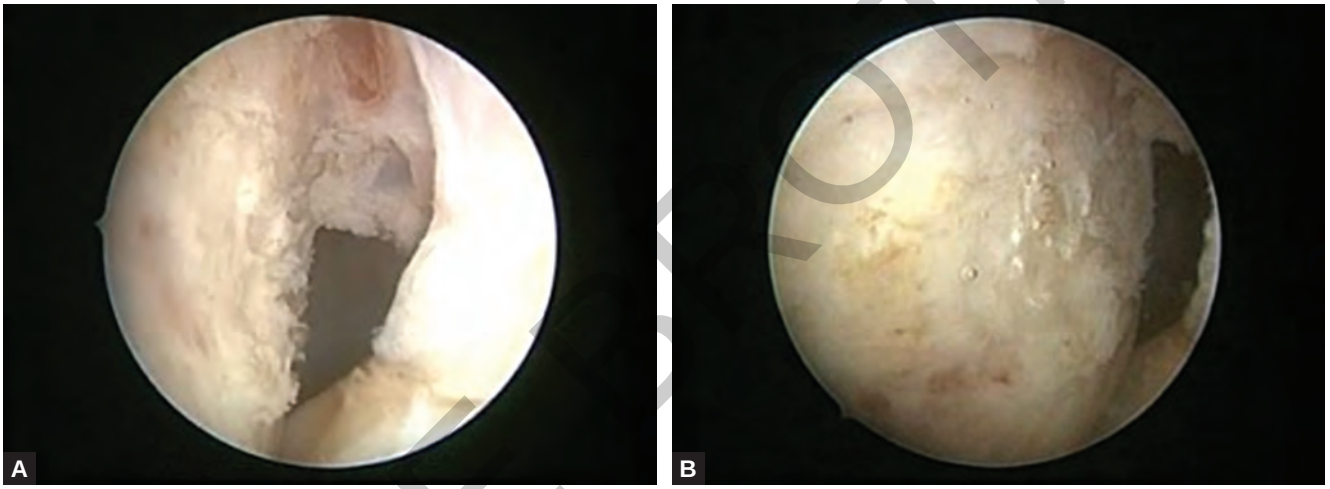

Figures 4.11A and B: (A) View of lateral wall of intercondylar notch from anterolareal portal; (B) Same from anteromedial portal. The anatomy of the lateral wall is much better visualized via anteromedial portal

ridge 5–6 mm anterior to the posterior articular margin. We do not believe in referring to the O'clock face method as the method is very subjective and has a wide inter—as well as intra-observer variability and furthermore, the position changes with the change in the knee flexion angle. The center of the femoral tunnel is marked with a microfracture pick and again confirmed via anteromedial portal **(Fig. 4.12)**.

MEASUREMENT TECHNIQUE

It is reported that anatomic landmarks may be reliably identified in only 60–80% of the cases with the difficulty being more in chronic cases. In such situations, we rely on the measurement of the lateral condylar width with the help of specially designed rulers that can be placed collinearly with the lateral femoral wall through anterolateral portal **(Fig. 4.13)**.

It has been shown by Bird J H et al.[7] in anatomic as well clinical studies that the midpoint of a line drawn from a point at the proximal margin of the lateral femoral articular cartilage parallel to the tibia with the knee in 90° of flexion corresponds to the bifurcate ridge with a margin of error of 1mm and that this technique can be used with advantage in cases where the anatomic ridges are poorly defined **(Figs 4.14A to C)**.

JAYPEE BROTHERS



Figure 4.12: The centrum of the femoral tunnel is marked with a microfracture awl at bifurcate ridge 5–6 mm above the lowermost visible articular cartilage



Figure 4.13: Measuring devices used to measure the width of lateral wall and ACL footprint. The "hockey" shaped device is used to measure the femoral width while the "T-shaped" devices are used to measure the tibial footprint

JAYPEE BROTHERS

While utilizing the above technique it is essential to use three portals, viewing through high anteromedial portal, measuring tool through anterolateral portal and microfracture pick through the low medial portal. Viewing from the anteromedial portal with the instruments in a low medial portal may cause some difficulty in visualization and manipulation of instruments due to crowding in the notch area **(Fig. 4.15)**.

After marking the midpoint of the femoral tunnel the drilling is done with the technique as described below.

FEMORAL DRILLING

The femoral tunnel is prepared before the tibial tunnel. Transportal drilling of the femoral tunnel requires the knee to be placed in more than 90° of knee flexion for a number of reasons:

- There are chances of posterior "blow out" of femoral tunnel if drilling is done at 90°.
- The tunnels may be very short if drilled at 90°.
- The guide may come out of the lateral aspect of the thigh below the lateral intermuscular septum and may endanger neurovascular structures.

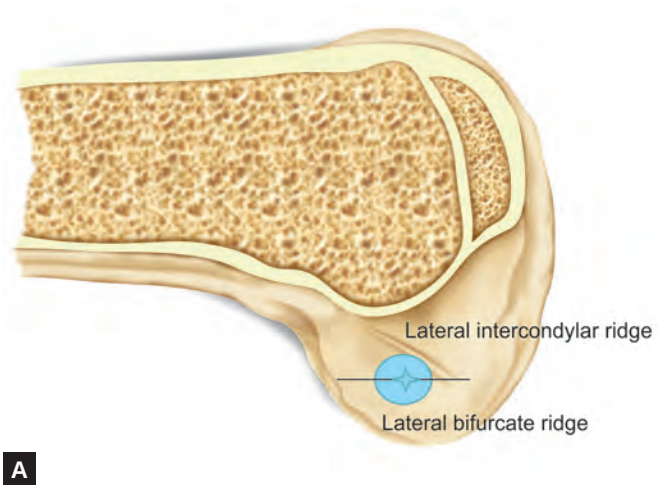

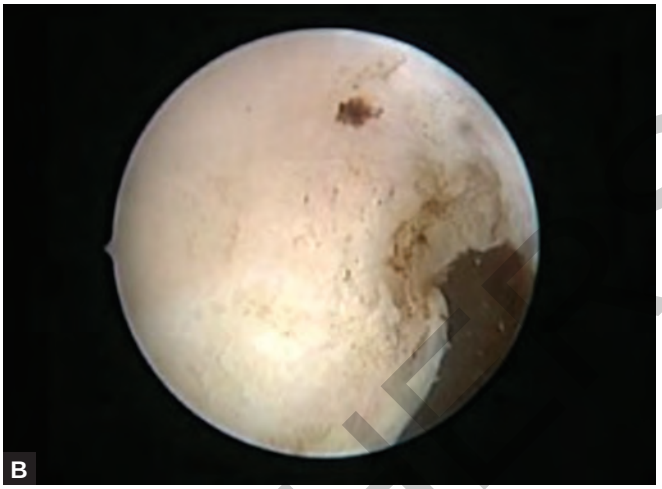

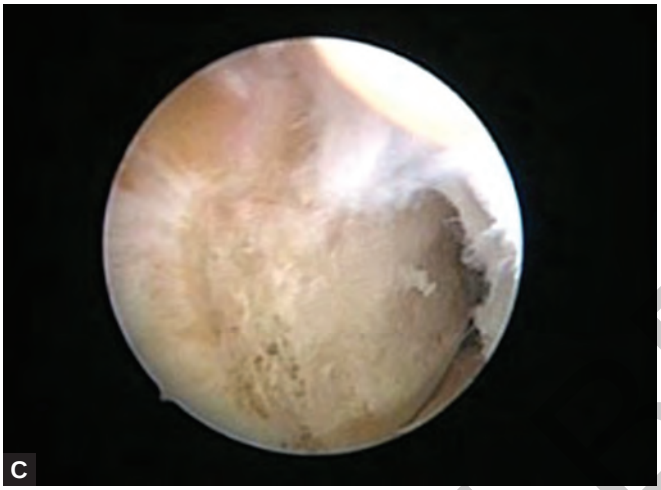

Figures 4.14A to C: (A) Midpoint of lateral intercondylar width corresponds to the bifurcate ridge with an error of 1 mm; (B and C) The bony ridges may not be clearly visible in chronic cases and measuring technique can be used in such cases



Figure 4.15: An accessory high medial portal is used to visualize while far medial portal is used to perform drilling

JAYPEE BROTHERS

Drilling the femoral tunnel with the knee in hyperflexion has its own problems of poor visualization (infrapatellar fat pad coming in front and obstructing vision and poor inflow of fluid because the capacity of joint decreases with hyperflexion), difficulty in passing the instruments through anteromedial portal as the skin becomes tight and the portal becomes narrow in hyperflexion, and, the chances of iatrogenic damage to the articular cartilage of medial femoral condyle. Infrapatellar fat pad should be adequately resected if it is obstructing the view and pressure pump may be used to increase the fluid inflow during this stage of the procedure. It is recommended to introduce the instruments through the anteromedial portal with the knee being in 90° and negotiating them under direct vision clear of the medial femoral condyle. Once the instruments are in the notch area, the knee can be brought into hyperflexion.[8]

Based upon the choice of button fixation and manufacturer's guidelines, appropriately sized guide pin is introduced into the joint and placed at the previously marked point on the side wall of the lateral femoral condyle. We introduce the guide pin and a cannulated reamer as a composite so as to have a better control over the guide pin and to lever the tibia down which helps give a better direction and a longer tunnel. The lateral femoral condyle is drilled throughout its width and the guide pin is pushed out of the lateral aspect of the distal thigh **(Fig. 4.16)**.

The intraosseous length is measured either with the drill guide (ACL Tightrope drill guide) or it can be measured after drilling over the guide pin with 4.5 mm cannulated drill and using a depth gauge. Illustrated in **Figure 4.19**, the intraosseous length is 35 mm and it is noted down. It is desirable to keep at least 20 mm of graft in the femoral tunnel to allow secure biointegration. The appropriately sized femoral acorn reamer is introduced carefully over the guide pin with hand to avoid damage to articular cartilage and once in contact with the side wall of the notch it is advanced to a depth of 20 mm. The depth markings may be assessed outside the skin if the arthroscopic visualization is not clear. We prefer to use fluid pump during this stage of the procedure to help in better visualization. A looped suture is passed next via guide pin to be used later as a suture shuttle to pass the graft **(Figs 4.17A and B)**.

TIBIAL TUNNEL

The tibial tunnel is placed in the center of the tibial footprint, the so called "mid-bundle' position. Footprint can be measured using specially designed ruler guides, although this technique requires the tibial stump to be debrided extensively. We debride the ACL stump only minimally as it has been suggested that ACL remnant may have a role in restoring proprioceptor fibers to the reconstructed ligament. Other landmark that can reliably

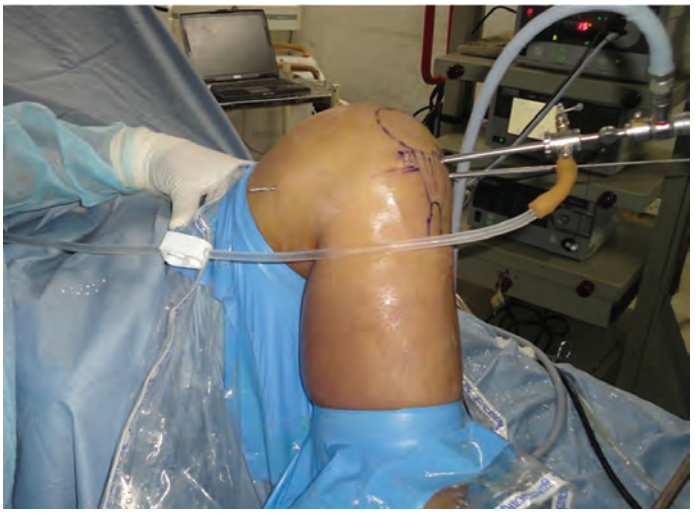

Figure 4.16: Femoral guide pin is drilled through and is brought outside the skin on lateral aspect of thigh. Note the hyperflexed position of the knee with arthroscope in high medial portal. The pin should exit anterior to the mid-coronal plane of the thigh to avoid inadvertent damage to the common peroneal nerve

JAYPEE BROTHERS

for detailed information on orthopedic books, visit our website **www.jaypeebrothers.com,** for detailed information on orthopedic books, visit our w



Mastering Orthopedic Techniques

KNEE RECONSTRUCTION

Decision making in knee soft tissue injuries is a demanding subject to grasp. The rapid advances in technology and the skills required to master them are a daunting prospect even for an experienced surgeon. This book presents you with the multiple surgical techniques described for the knee soft tissue injuries in a systematic approach with numerous illustrations of the actual procedure being performed. The aim is to acquaint the readers with the various sequential steps of the surgical techniques so as to influence the learning curve in a positive direction. The book will prove to be an invaluable asset to residents and orthopedic surgeons with special interest in knee reconstruction and complements the earlier edition on *Total Knee Arthroplasty* published under the *Mastering Orthopedic Techniques* series.



Rajesh Malhotra, an irresistible soul, is through and through the AIIMSONIAN. He joined the All India Institute of Medical Sciences (AIIMS) (1979), New Delhi and successfully completed graduation in the year 1984. He has been working there, in different capacities ever since. He completed Master of Surgery (MS) in Orthopedics (1988). Presently, he occupies the prestigious position of Professor of Orthopedics since September 2005. He has also been Visiting Consultant, Ahmadi Hospital, Kuwait (May 2002 to Aug 2002). Consequently, he was awarded the Fellow of Royal College of Physicians and Surgeons (FRCS) in 2012, Fellow of American College of Surgeons (FACS) in 2013, and Fellowship of the International College of Surgeons (FICS)—Indian Section in 2015. He is a talented prolific writer, and the author of 510 publications; 327 articles, 67 editorials, 40 abstracts, 2 publications in yearbook and 74 posters, a rich-source material and extensively cited in standard text. He has distinguished himself as an Editor, and has 11 books (another 2 are in Press) to his credit. He has delivered over 500 invited lectures including several Public lectures. *Knee Reconstruction* is his latest addition to the series *Mastering Orthopedic Techniques*.



Sunil Apsingi is Joint Director (Orthopedics) and Head, Arthroscopy and Sports Injuries, MaxCure Hospital, Hyderabad, Telangana, India. He did his basic Orthopedic training from Postgraduate Institute of Medical Education and Research (PGIMER), Chandigarh. He has worked in the Biomechanics Department, Imperial College, London, UK. He specializes in knee ligament reconstruction surgery including multi-ligament surgeries and shoulder arthroscopic surgery. He has presented his work extensively in national and international meetings and published in various indexed journals. He has also co-authored chapters in three books.



Krishna Kiran Eachempati, Alumnus of AIIMS (2001), is the Director and Chief, Department of Orthopedics, MaxCure Hospital, Hyderabad, Telangana, India. He completed his fellowship program in Computer Navigated Knee and Hip Replacements from Germany. He specializes in computer-assisted/navigated knee replacements, complex primary and revision arthroplasties of hip and knees, sports injuries pertaining to knee arthroscopy. He has to his credit more than 40 publications, has co-authored a few chapters in more than four textbooks.



Deepak Gautam completed his Masters in Orthopedic Surgery from All India Institute of Medical Sciences (AIIMS), New Delhi, India. He worked as a Research Associate, Department of Orthopedics, AIIMS, New Delhi. He was a Travelling Fellow of Asia Pacific Orthopaedic Association (APOA) in Hip and Knee Arthroplasty (2015). He did his fellowship in Hip and Knee Reconstruction from Oldenburg, Germany. Currently, he is working as a Wellcome Trust Fellow, Department of Orthopedics, AIIMS, New Delhi.

Available at all medical bookstores
or buy online at www.jaypeebrothers.com

JAYPEE BROTHERS
Medical Publishers (P) Ltd.
www.jaypeebrothers.com

Join us on facebook.com/JaypeeMedicalPublishers

Shelving Recommendation
ORTHOPEDICS

ISBN 978-93-85999-73-4