our website www.jaypeebrothers.com, for detailed information on cardiology books, visit our website www.jaypeebrothers.com

NIC Companion Book of Interventional Cardiology



Narendra Nath Khanna
Rishi Sethi
J Shiv Kumar

JAYPEE

Contents

1. Good Clinical Practices in Cath Lab **1**
Rishi Sethi, Akshyaya Pradhan, J Shiv Kumar
The Team Approach 1; Communication: Encourage the Culture to Speak-up 2

2. Ten Commandments of Radial Interventions **10**
Tejas Patel, Sanjay Shah, Samir Pancholy
Commandment 1: Patient Selection, Preparation and Cath Lab Set-up Criteria 10; Commandment 2: Gaining Radial Artery Access 10; Commandment 3: Management of RA SPASM 11; Commandment 4: Aiming at Reduction of Radial Artery Occlusion 14; Commandment 5: Working Through Complexities of Radial and Brachial Vasculature 14; Commandment 6: Working Through Challenges of Subclavian Innominate and Aortic Arch Regions 18; Commandment 7: Catheter Selection Criteria 18; Commandment 8: Post-Procedure Management 22; Commandment 9: Management of Complications 23; Commandment 10: Dealing with Special Situations 25

3. Fractional Flow Reserve: How to Interpret in Different Situations? **30**
PS Sandhu, Upendra Kaul
Principles of Coronary Pressure and Flow 30; Measurement of Fractional Flow Reserve 31; Induction of Maximal Hyperemia 32; Specific Features and Limitations of Fractional Flow Reserve 33; Methodology for Assessment of Fractional Flow Reserve 34; Economic Considerations and Physiologically-guided Revascularization 40

4. Uses of Optical Coherence Tomography in Special Situations **42**
G Sengottuvelu, R Ravindran
Preprocedural Lesion Assessment 42

5. Antegrade Approach to Chronic Total Occlusion **53**
Arun Kalyanasundaram
The Basics: Prepare for Success 53; Vascular Access and Guide Support 53; Procedural Anticoagulation 53; Antegrade Wire 54; Antegrade Dissection/ Re-entry 55; Dedicated Re-entry Systems 55; Tips and Tricks 56; Final Thoughts 61

6. Retrograde Approach to Chronic Total Occlusion **62**
Suryaprakash Rao
Types of Retrograde Techniques 62; What do You Need for Retrograde Chronic Total Occlusion Percutaneous Coronary Intervention 63; Additional Tools 66

7. Technique and Role of Rotablation in Interventional Cardiology **67**
AB Mehta, Anmol Sonawane
Principle of Rotablation 67; Mechanism of Action 69; Indications 72; Contraindications 72; Procedure 72; Procedural Information 74; Lesion-specific Indications 75; Complications 78; Rotablator System Failure 79; Burr Entrapment 79; Prevention of Entrapment 81

8. Bifurcation Coronary Lesions: Definition, Classification and Approaches to Bifurcation Management **83**
Goran Stankovic, Zlatko Mehmedbegovic, Milorad Zivkovic, Vladimir Kanjuh
Anatomical and Hemodynamic Specifications of Bifurcation Segments 84; Approach to Bifurcation Treatment 85; A Second Stent in the Side Branch Following Provisional Approach 88; Two Stents as an "Intention to Treat" 89; Inverted Culotte Technique 90; Mini-Crush Technique 92; V and the Simultaneous Kissing Stent Techniques 93; Dedicated Bifurcation Stents 93

9. Tips and Tricks of Vein Graft Intervention **97**
Shirish MS Hiremath, Omkar S Thopte
Natural History of Saphenous Vein Graft Disease 97; Indications 98; Covered Stents 100

10. Step by Step and Challenging Situations in Patent Ductus Arteriosus Closure **107**
Kshitij Seth, Bharat Dalvi
History of Transcatheter Closure of Patent Ductus Arteriosus 107; Current Indications 107; Contraindications 108; Patient Selection 108; Role of Echocardiography 109; Angiographic Delineation of Patent Ductus Arteriosus 110; Limitations of Angiographic Classification 110; Step by Step Procedure 113; Special Subsets 113; Concluding Remarks 117

11. Step-by-Step Ventricular Septal Defect-device Closure **118**
Manoj Kumar Rohit, Pavan Rasalkar
Patient Selection 118; Devices Selection 120; Technique of Device Closure of VSD 121; Complications 125

12. Endovascular Repair of Aortic Aneurysm **130**
Narendra Nath Khanna, Suparna Rao
Background 130; Why Should Interventional Cardiologists do Endovascular Aneurysm Repair? 131; Aortic Aneurysms 131; Endovascular Aortic Aneurysm Repair 133

13. Use of Positron Emission Tomography in Cardiology **145**
PK Pradhan, AP Gowri Sankar, A Arya

14. Cardiogenic Shock **153**
Lawrence Rajan
Revascularization 154; Mechanical Support 156

15. Carotid Angioplasty and Stenting: State-of-the-Art **163**
Narendra Nath Khanna, Michel Henry, Rini Pramesti
Indications 163

16. Tips and Tricks of Central Vein Recanalization **178**
BC Srinivas, CM Nagesh, Babu Reddy
Endovascular Intervention 178; Technical Key Points for Intervention 179; Case Scenarios 179

17. Pressure Wire... Beyond Fractional Flow Reserve **185**
Sayan Sen, Justin Er Davies
Physiological Basis of Instant Wave-free Ratio 185; How to Measure Instant Wave-free Ratio 185; Instant Wave-free Ratio Compared to Fractional Flow Reserve 186; Implementation of Instant Wave-free Ratio into Clinical Practice 188; Instant Wave-free Ratio in Tandem Lesions and Virtual Stenting 190

18. Retrieval of Foreign Bodies during Cardiac Catheterization **193**
Vijay Trehan, Sanjeev Kathuria
Background 194; Retrieval Devices 194; Methods 196

19. Aortic and Pulmonary Balloon Valvotomy: A Step-by-Step Guide **202**
Manisha Chakrabarti, Supriya Choudhary
Timing of Intervention for Aortic Stenosis 202; Technique 203; Procedure 203; Post-catheterization Care 205; Complications and Results 205; Balloon Pulmonary Valvuloplasty 205

20. Step-by-Step Approach to Transcatheter Aortic Valve Implantation **209**
Sanjay Mehrotra
Indications for Percutaneous Treatment 209; Planning and Patient Assessment 209; Complications Transcatheter Aortic Valve Implantation/Transcatheter Aortic Valve Replacement 213; Final Thought 213

Index ***215***

4 CHAPTER

Uses of Optical Coherence Tomography in Special Situations

G Sengottuvelu, R Ravindran

INTRODUCTION

Optical coherence tomography (OCT) guidance for coronary interventions is increasingly being used and several randomized trials are underway to show its benefits over angiography.[1,2] There are several special situations where OCT has been documented to be extremely useful to the operator during decision making during percutaneous coronary interventions (PCI). Of the three imaging modalities used to study the coronary artery dimensions, *viz.*, quantitative coronary angiography (QCA), intravascular ultrasound (IVUS) and OCT, the dimensions derived from OCT has the nearest correlation with cadaveric and phantom models[3] **(Figs 4.1A to D)**. The advent of co-registration[4] along with rapid acquisition, easy interpretation, instantaneous 3D reconstruction and the user friendly interface makes it an attractive tool for assisting PCI at all stages (preprocedural lesion assessment, procedural guidance, post-PCI optimization and late follow-up assessment). With this background we would be discussing selective situations where we found OCT to be most useful.

PREPROCEDURAL LESION ASSESSMENT

Intraluminal Filling Defects

Angiographic intraluminal filling defects are sometimes challenging to identify and differential diagnosis could be thrombus or dissection flaps. OCT is the most sensitive *in vivo* test to differentiate between organized thrombus and dissection flaps, and it is important to understand that both often coexist. Insights from OCT have shown that linear filling defects seen by angiography which are often labeled as spontaneous coronary artery dissections are in fact truly organized thrombus (this mimics spontaneous dissection flaps). OCT, though useful to plan appropriate management in these patients, it may be difficult to differentiate organized thrombus and healing spontaneous flaps. Presence of intimo-medial discontinuity favors a dissection and may have coexisting organized thrombus. Ideal way to differentiate is to examine a moving image rather than a still frame and closely follow the flap like structure in the adjacent frames **(Figs 4.1A to D)**. If the filling defect is clearly within the vessel and intima and the media are intact, it favors the diagnosis of recanalized thrombus. OCT also can differentiate red versus white thrombus and ruptured plaque can be well-visualized. Presence of multiple plaque rupture or empty cavities in nonculprit artery in acute coronary syndrome (ACS) situations has been shown by OCT. Similarly, thin cap fibroatheroma can be easily identified by OCT.

Spontaneous Coronary Artery Dissection

Optical coherence tomography (OCT) is useful tool to confirm the diagnosis of spontaneous coronary artery dissection (SCAD). In our case example, angiographic filling defect in the left main in a young lady with anterior wall myocardial infarction was confirmed to have SCAD with intramural hematoma by OCT.

JAYPEE BROTHERS

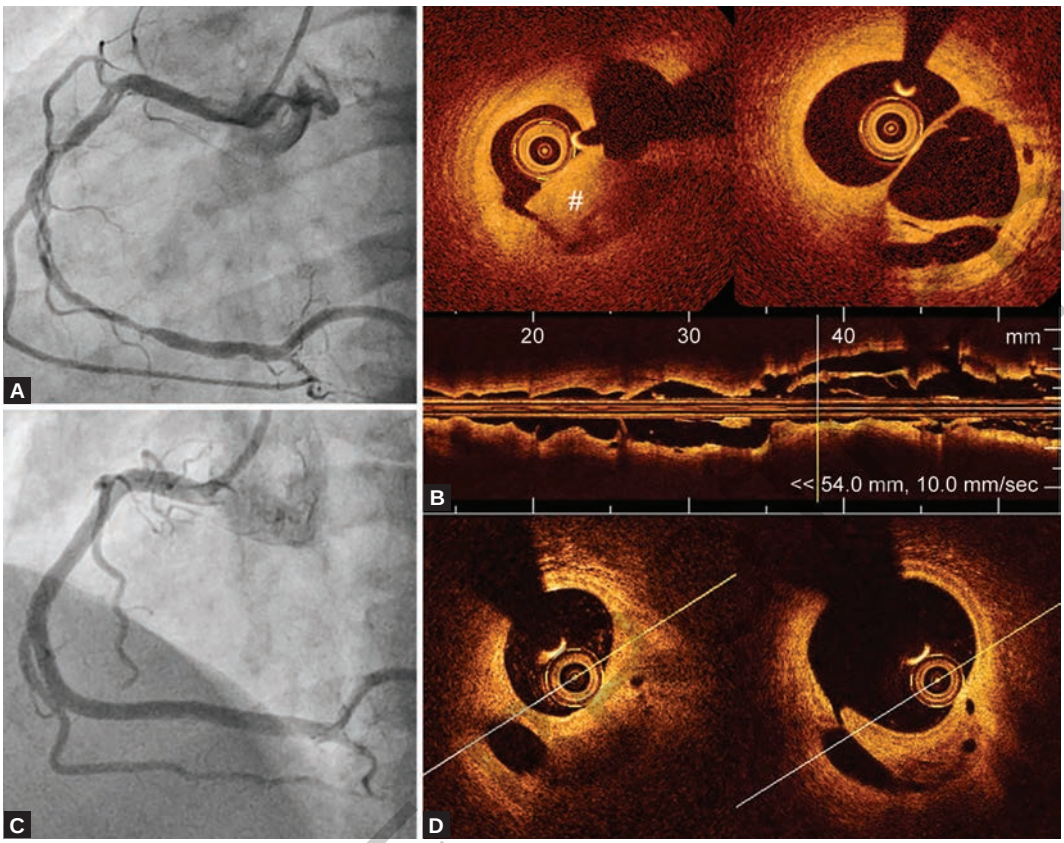

Figs 4.1A to D: Intraluminal filling defects—this patient with recent inferior wall myocardial infarction (IWMI) had both organized recanalized thrombus (A and B) and dissection flaps (C and D) that was treated with multiple overlapping scaffolds

OCT clearly showed the large entry point of the dissection in the ostioproximal left anterior descending (LAD) with intramural hematoma extending to both the left main proximally and distally up to mid-LAD. Although OCT would be the best available modality to define this entity, one has to be cautious as forceful contrast injection during OCT can extend the dissection flaps. This patient underwent percutaneous coronary intervention (PCI) with sealing of the proximal entry point using a bioabsorbable vascular scaffold and did well on follow-up **(Figs 4.2A and B)**.

Another example was a young man with multiple linear opacities in right coronary artery angiogram from ostium to distal bifurcation that persisted even after a trial of anticoagulation. OCT showed both dissection flaps and organized thrombus and was treated with multiple overlapping bioabsorbable scaffolds and is doing well on follow-up **(Figs 4.1A to D)**.

Angiographic Haziness

Diagnostic angiogram can be difficult to interpret and quantify lesions in some situations particularly with intermediate lesions, lesions in bends, haziness within the lesion, etc. A perfect illustration of this fact can be understood from the case shown in the figure. A middle aged lady with a hazy borderline mid-RCA lesion had a significant fractional flow reserve (FFR) value. Subsequently OCT showed multiple recanalized channels of varying diameters within the lumen (lotus root appearance) suggestive of organized recanalized thrombus thus explaining the significant ischemia

JAYPEE

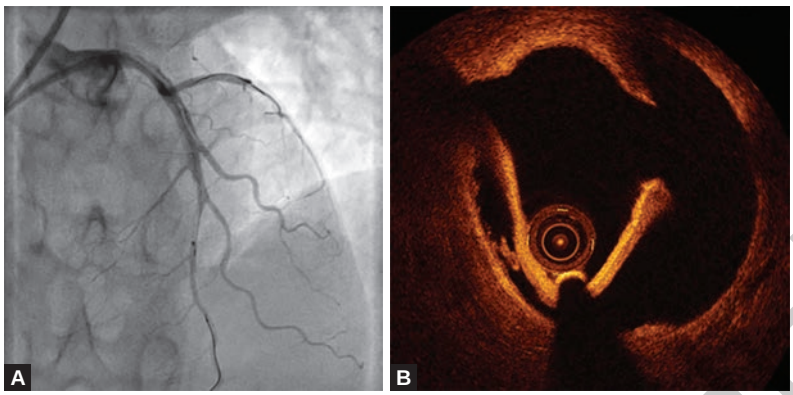

Figs 4.2A and B: Intraluminal filling defects—this patient with anterior wall myocardial infarction (AWMI) and an intraluminal filling defect was found to have a dissection flap with intramural hematoma

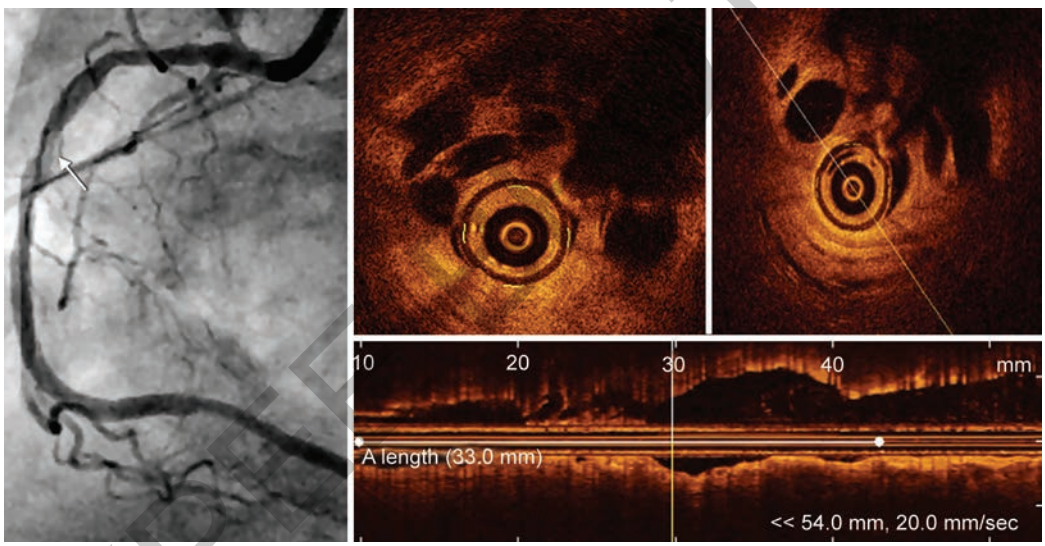

Fig. 4.3: Across the angiographic haziness in the mid-RCA (arrow) there was significant FFR (0.53) and OCT showed organized recanalized thrombus. Contrast through this multiple channels masked a critical ischemic lesion on the angiogram

on FFR **(Fig. 4.3)**. A similar OCT picture with lotus root appearance showing recanalized thrombus was reported by us in a case of myeloproliferative disorder presenting with ACS **(Figs 4.4A and B)**.

Bifurcation Lesions

Optical coherence tomography (OCT) particularly, with 3D reconstruction is emerging as a useful tool during bifurcation PCI. A single main branch pull back also allows assessment of the side branch ostium by multiple methods. Carinal catch is the most easy and reproducible method **(Figs 4.5A and B)**. Main branch opposite to the carina is the most common site of plaque distribution on intravascular imaging studies **(Figs 4.6A and B)**. Soft plaque of the proximal main branch on the side of the side branch predicts significant plaque shift post-PCI. Dedicated pre- and post-side

JAYPEE BROTHERS

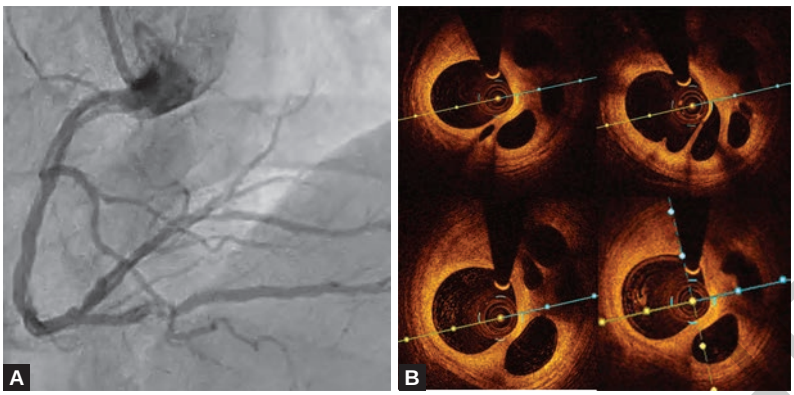

Figs 4.4A and B: Right coronary artery (RCA) angiogram from a patient with myeloproliferative disorder showed multiple linear shadows that were confirmed to be organized recanalized thrombus rather than a dissection flap on the OCT

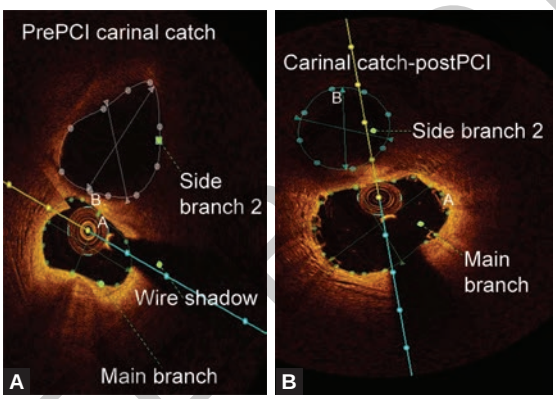

Figs 4.5A and B: Carinal catch of a bifurcation lesion pre- and post-PCI showing similar area and eccentricity of the side branch ostium ensuring no plaque or carinal shift

branch pull backs are needed to appreciate plaque and cardinal shift accurately. Eccentricity and area of the side branch ostium obtained from carinal catch of pre- and post-main branch pullback also helps to differentiate carinal versus plaque shift.

Three dimensional OCT can be done quickly and has a unique role to identify the position of the side branch wire during re-crossing. During bifurcation PCI, identification of favorable position of the side branch wire after main branch stenting from main branch OCT is an important use of 3D OCT **(Figs 4.7A and B)**. The side branch wire entering the distal most strut is considered favorable in all bifurcation techniques except in double kissing (DK) crush where in, the wire through a proximal most strut is considered favorable. In addition wire criss-crossing preventing advancement of hardware's during bifurcation PCI can also be identified.

During Percutaneous Coronary Interventions

Vessel dimensions as identified by OCT are the most accurate among the available modalities. The average of the midwall (inner-media to media) diameter at the landing zones (proximal and distal reference vessel diameter) for stent sizing is one of the safe ways and gives the largest

JAYPEE BROTHERS

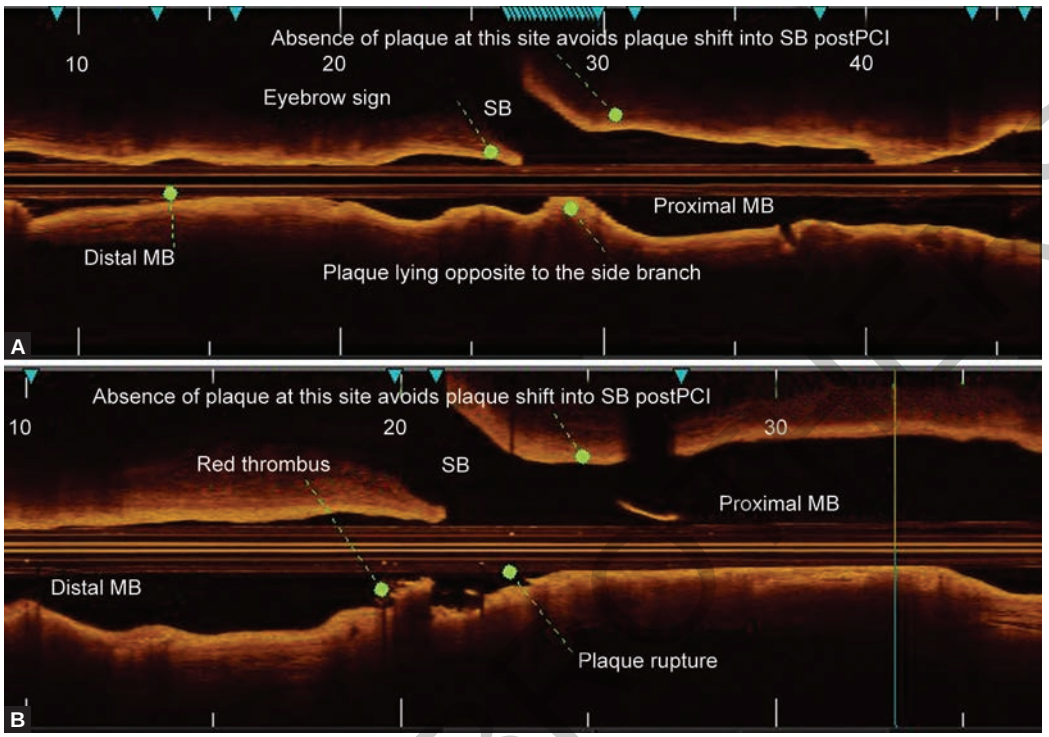

Figs 4.6A and B: Initial longitudinal view of a bifurcation lesion showing eyebrow sign, a marker of postPCI carinal shift. Longitudinal and cross-section of a LAD-D1 bifurcation showing ruptured plaque with thrombus opposite to the carinal. Lack of plaque on the ipsilateral side of the side branch is favorable (no plaque shift happens)

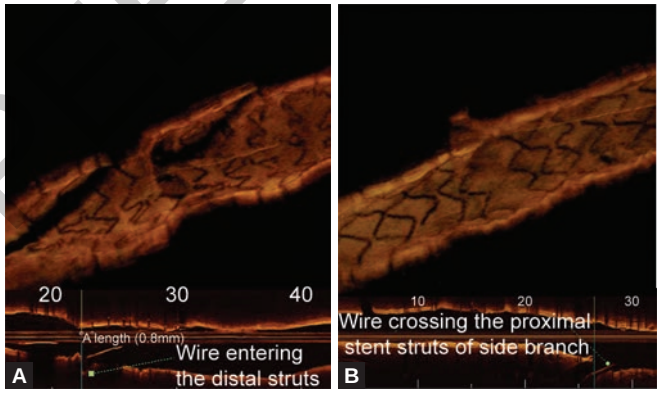

Figs 4.7A and B: 3D OCT showing side branch wire through a distal strut (favorable) and a proximal strut (unfavorable)

post-PCI minimum stent area. Landing zones are determined in an area where the media is clearly visible for atleast half of the vessel circumference. Marking the landing zones automatically gives the stent length and with angiographic co-registration positioning can even more accurate **(Fig. 4.8)**.

JAYPEE BROTHERS

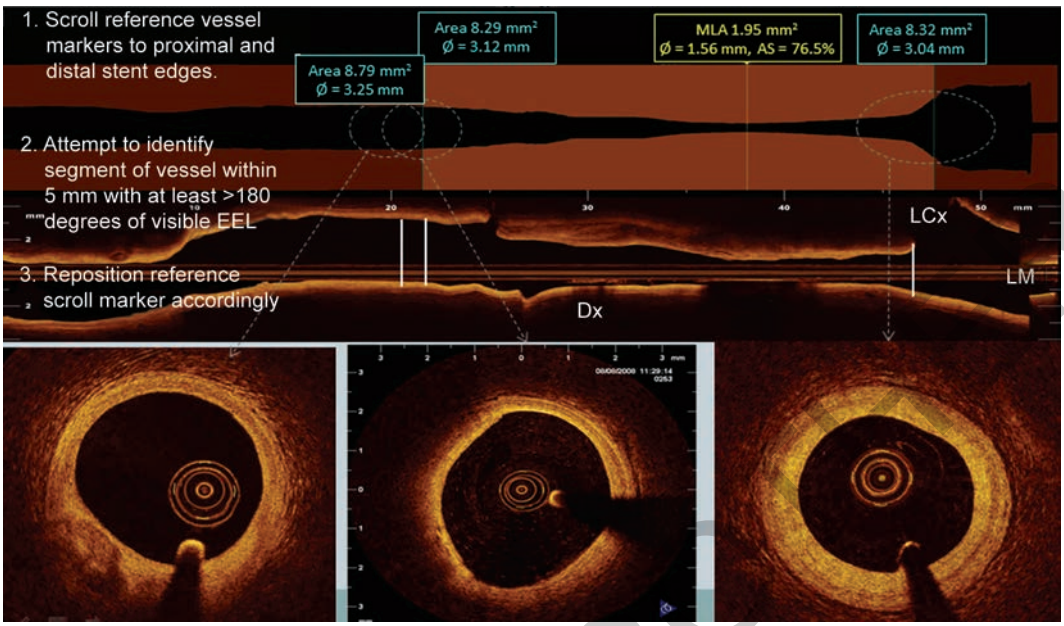

Fig. 4.8: Illustration to show selection of stent size and landing zones. The bottom middle frame is not an optimal landing zone as the media is not seen for > 180 degrees

Postpercutaneous Coronary Interventions Assessment

Suboptimal Angiographic Result

This is the most common indication for OCT in real world practice. A variety of causes for suboptimal angiographic result can be identified with OCT. Edge dissections, malappositions, under expansions and geographical miss are more frequently identified by OCT than by angiogram. Plaque or thrombus prolapsing through the stent struts can pose suboptimal angiographic results and can be identified. Major plaque prolapse compromising the lumen area by >10% may require intervention.

Assessment of Bioresorbable Vascular Scaffold

Optical coherence tomography (OCT) with its high resolution capabilities has been shown to be most useful for assessment of bioresorbable scaffolds. It may be useful tool during the initial learning phase of scaffold implantations as it helps in assessment of accurate vessel dimensions, understand plaque morphology and to ensure adequate postdilatation. Lesion preparation is very important for bioresorbable vascular scaffold (BVS) implantation and hence understanding plaque morphology helps us to plan optimal bed preparation strategy. Lessons from OCT imaging have reinforced the importance of proper lesion predilatation and adequate postdilatation with noncompliant balloon without exceeding the recommended BVS limits. When BVS is used in complex subsets such as bifurcations, post-implantation assessment by OCT can improve outcomes **(Figs 4.9A to F)**.[5] OCT has shown more malappositions in calcified lesions and overlapping BVS sites which need high pressure postdilatation **(Figs 4.10A to F)**. OCT can identify scaffold deformations and fractures which are not seen by angiography. It is also important to note that OCT imaging is not mandatory for every BVS implantation.

In Stent Restenosis

High resolution OCT images can differentiate between the different forms of in stent restenosis

JAYPEE BROTHERS

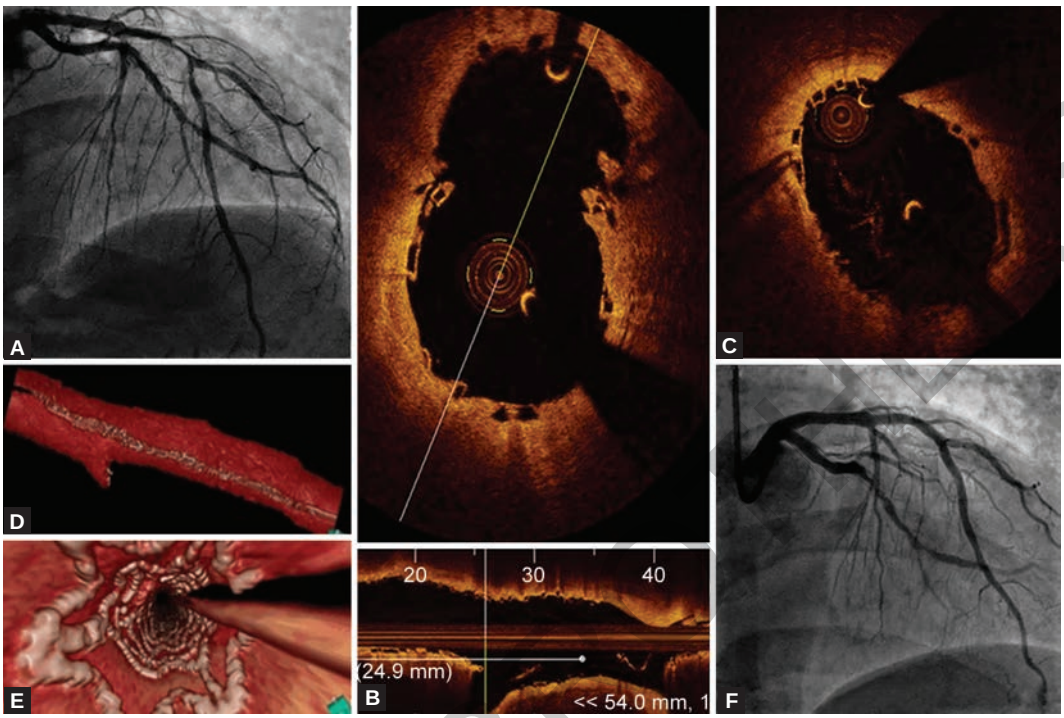

Figs 4.9A to F: (A) Optical coherence tomography (OCT) guided bifurcation with two scaffold strategy; (B and C) OCT from LAD and (D) diagonal; (E and F) 3D OCT fly through at bifurcation showing excellent results

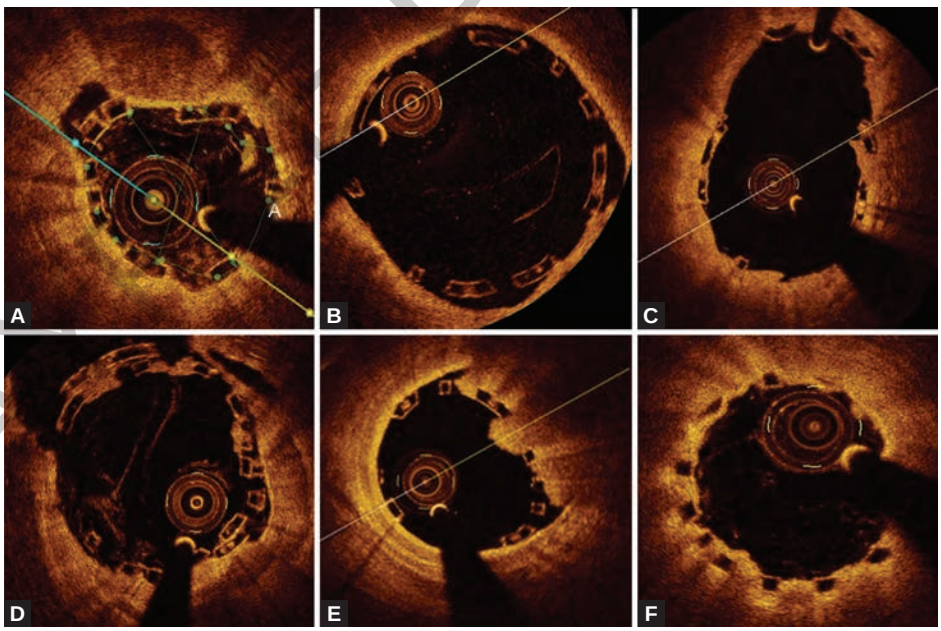

Figs 4.10A to F: Post-BVS assessment—Malapposition due to underlying calcium (A), malapposition due to under sizing (B). OCT after bifurcation PCI with two BVS using T and protrusion technique (C). BVS overlap with malapposition (D). Thrombus prolapses through BVS (E and F)

(ISR) and can guide management. Bright homogeneous areas represent neointimal hyperplasia that may require predilatation with cutting balloon **(Figs 4.11A and B)**. Dark areas within the bright neointima may represent neoatherosclerosis or cell poor fibrin rich neointima and usually yields well to compliant balloon dilatations and would require another DES **(Fig. 4.11C)**.

Stent Thrombosis

Optical coherence tomography (OCT) can give valuable information during assessment of subacute or late stent thrombosis. Possible cause of stent thrombosis can be identified from the high resolution OCT images *viz., edge dissections, stent fracture, persistent uncovered strut, neoatherosclerotic plaque rupture, significant distal lesions, etc.*

Optical coherence tomography (OCT) evaluation of a subacute stent thrombosis three weeks post-PCI with drug eluting for ostial left anterior descending (LAD) lesion showed well-apposed stent struts without any edge dissection. An untreated angiographically borderline mid-LAD lesion showed a minimal luminal area of 1.1 sq. mm which was treated with another stent and there were no subsequent events **(Fig. 4.12)**.

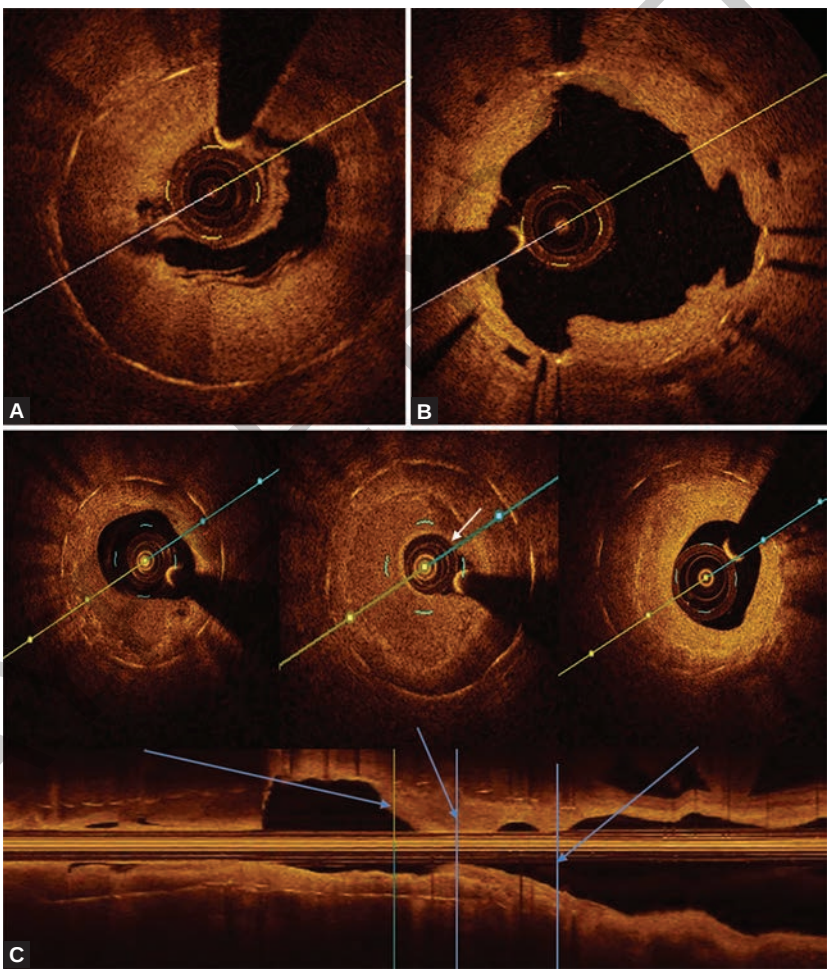

Figs 4.11A to C: Homogeneous neointima that required cutting balloon (A-baseline and B-after cutting balloon). Heterogeneous in stent restenosis (ISR) that yielded to compliant balloon dilatation (C)

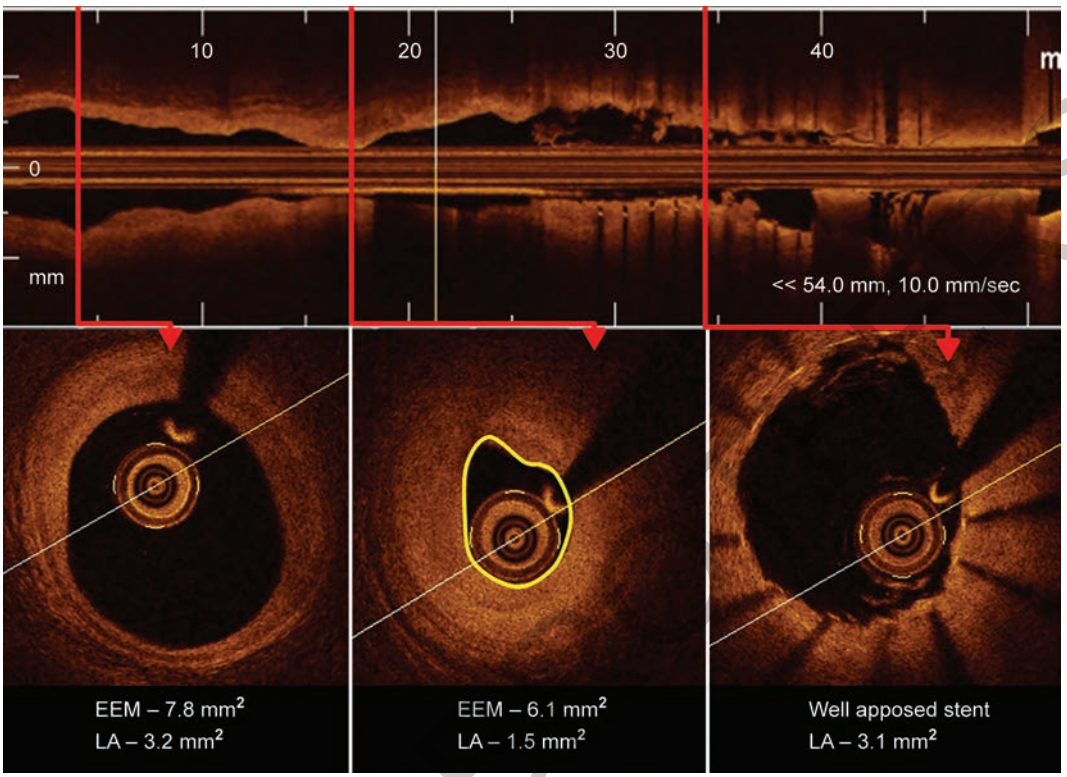

Fig. 4.12: Stent thrombosis OCT after thrombus aspiration. Significant distal lesion was identified as the cause

Another case of very late stent thrombosis, 6 years after PCI with Cypher stent was evaluated with OCT and was found to be due to stent fracture.

Need for Long-term Dual Antiplatelet Therapy

Persistent uncovered stent struts leading to very late stent thrombosis especially after first generation drug-eluting stents (DES) has been documented and may need long-term dual antiplatelet therapy (DAPT) use. OCT can help in assessment of strut coverage there by helping to decide duration of DAPT in some situations (first generation DES). Very late stent thrombosis with DES is a real threat and DAPT trial has shown some benefits for continuing dual antiplatelets beyond 1 year, put together and empirically also many patients remain on prolonged DAPT post PCI in contemporary practice. A patient 7 years after PCI had persistent uncovered struts along with some positive remodeling and was advised for continuation of DAPT **(Fig. 4.13)**.

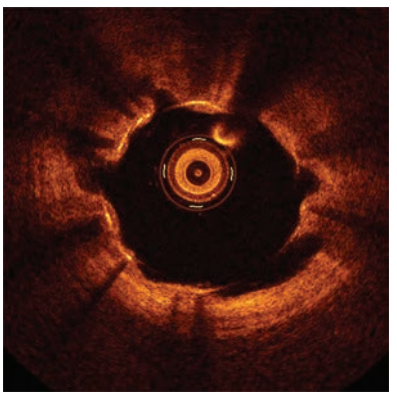

Fig. 4.13: Late follow-up OCT 7 years after first generation DES showing uncovered stent struts and erosions which are marker for late stent thrombosis

JAYPEE BROTHERS

MISCELLANEOUS

3D reconstruction and intravascular fly through can be useful in some situations. Other research indications for follow-up OCT include early endothelialization studies, plaque regression studies and BVS resorption studies. OCT imaging of the right coronary artery (RCA) ostium showed plaque prolapse caused by probable guide catheter induced injury. This was treated with an additional stent covering the ostium. In a different situation, we used OCT into LAD to identify whether coronary guidewire into the left circumflex (LCx) passed through the ostial stent struts of the LAD prior to planning PCI to LCx.

CONCLUSION

Although there are no guideline endorsed class I recommendations for OCT imaging, it gives incredible richness of data and can guide clinical decision-making, at least in individual patients and in specific clinical scenarios and the insights that we gain from its high resolution is tremendous. Our experience has shown that OCT would be particularly useful in angiographically ambiguous lesions, suboptimal PCI results, stent thrombosis or restenosis, and in complex interventions such as bifurcations. Application of OCT has further increased in our context as it is the imaging of choice after BVS implantation at least in the early phases of BVS use in more complex cases such as bifurcations, long overlapping scaffolds and calcified lesions where suboptimal scaffold expansion maybe frequent.

REFERENCES

1. Prati F, Di Vito L, Biondi-Zoccai G. Angiography alone versus angiography plus optical coherence tomography to guide decision-making during percutaneous coronary intervention: the Centro per la Lotta contro l'Infarto-Optimisation of Percutaneous Coronary Intervention (CLI-OPCI) study. EuroIntervention. 2012;8(7):823-9.
2. Prati F, Romagnoli E. Clinical Impact of OCT Findings During PCI: The CLI-OPCI II Study. JACC Cardiovasc Imaging. 2015;8(11):1297-305.
3. Kubo T, Akasaka T, Shite J, et al. OCT compared with IVUS in a coronary lesion assessment: the OPUS-CLASS study. JACC Cardiovasc Imaging. 2013;6(10):1095-104.
4. Lasse Hebsgaard, Troels Munck Nielsen, Shengxian Tu, et al. Co-registration of optical coherence tomography and X-ray angiography in percutaneous coronary intervention. The Does Optical Coherence Tomography Optimize Revascularization (DOCTOR) fusion study. Int J Cardiol. 2015;182:272–8.
5. Ashok Seth, Sengottuvelu G, Ravi Sekar. Salvage of Side Branch by Provisional "TAP Technique" Using Absorb™ Bioresorbable Vascular Scaffolds for Bifurcation Lesion: First Case reports with Technical Consideration, Catheterization and Cardiovascular Intervension 2014.

FURTHER READING (OUR PUBLICATIONS ON OCT)

1. Sengottuvelu G, Rajendran R, Majumdar D. Capping spontaneous coronary artery dissection with overlapping bioabsorbable scaffolds. Heart Lung Circ. 2015;24(2):e39-40.
2. Sengottuvelu G. Erosion/malapposition of a sirolimus eluting stent-Optical coherence tomography image-A case report. Indian Heart Journal. 2012;64(6):610-3.
3. Sengottuvelu G, Ligthart JM, Rajendran R, 3D optical coherence tomographic image of bifurcation lesion treated with two Absorb scaffolds. Indian Heart J. 2015;67(1):62.
4. Sengottuvelu G, Rajendran R Multimodality imaging in the evaluation of recurrent very late stent thrombosis. Asia Intervention 2015;1:124 DOI: 10.4244/AsiaInterv_V1I2A23.
5. Sengottuvelu G, Rajendran R. Plaque rupture in a non-culprit artery detected by optical coherence tomography and treated with plaque capping. Indian Heart J. 2014;66(6):733-4.
6. Sengottuvelu G, Rajendran R, Dattagupta A. Optical coherence tomographic image of dynamic left main coronary artery compression caused by intramural haematoma due to spontaneous coronary artery dissection - degloved artery managed with bioresorbable vascular scaffold. Euro Intervention. 2015;11(6):659.
7. Sengottuvelu G, Rajendran R. OCT during left main bifurcation PCI. Indian Heart J. 2014;66(5):557-8.
8. Sengottuvelu G, Rajendran R.Full polymer jacketing for long-segment spontaneous coronary artery dissection using bioresorbable vascular scaffolds. JACC Cardiovasc Interv. 2014;7(7):820-1.
9. Sengottuvelu G, Rajendran R. Reply: organized thrombus mimicking spontaneous coronary artery dissection. JACC Cardiovasc Interv. 2014; 7(12):1458-9.

JAYPEE BROTHERS

10. Sengottuvelu G, Rajendran R, Majumdar D. Optical coherence tomogram of spontaneous coronary artery dissection managed with drug eluting stent. Indian Heart J. 2014;66(2):247-8.
11. Sengottuvelu G, Rajendran R, Ravi S. Optical coherence tomographic image of an angiographically borderline lesion with a significant fractional flow reserve. J Am Coll Cardiol. 2014;63(18):1926.
12. Sengottuvelu G, Robert Van-Geuns, Rajendran R. Optical coherence tomographic visualization of ten years old radial to right coronary artery anastomotic site during PCI to occluded radial graft. Heart, Lung and Circulation. 2016.
13. Sengottuvelu G, Rajendran R. Optical coherence tomographic findings of myeloproliferative disorder presenting as acute myocardial infarction. Eur Heart J. 2016. [Epub ahead of print].

JAYPEE BROTHERS

or detailed information on cardiology books, visit our website www.jaypeebrothers.com, for detailed information on cardiology

NIC Companion Book of Interventional Cardiology



Narendra Nath Khanna MD DM FRCP (London, Glasgow, Edinburgh) FACC FSCAI FESC FAPSIC FCCP FIMSA FEISI MNAMS FCSI FICP FICC is a leading Senior Consultant (Interventional Cardiology and Vascular Interventions) and is working as an Advisor, Apollo Group of Hospitals, and Coordinator (Vascular Services), Indraprastha Apollo Hospitals, New Delhi, India. He has had extensive training in Coronary and Vascular Intervention at USA and France.

He is a Fellow of Royal College of Physicians (London, Glasgow, Edinburgh), American College of Cardiology, Society for Cardiovascular Angiography and Interventions (USA), European Society of Cardiology, American College of Chest Physicians, Asian Pacific Society of Interventional Cardiology, Cardiological Society of India (CSI) and Indian College of Cardiology. He is also the Chairman of National Interventional Council and Asia Pacific Vascular Society, Organizing Secretary and Course Chairman of Asia Pacific Vascular Intervention Courses since 2009, Founding Member and Treasurer of Endovascular Interventional Society of India and Course Director of TCT India.

He has authored 32 book chapters and has about 140 publications in various national and international journals to his credit. He has been invited as a Faculty to deliver more than 400 guest lectures in international and national scientific meetings and to perform Live Case demonstrations. He is recognized as one of the leaders in Coronary and Vascular Interventions in India and is proficient in a lot of new devices and technologies. He has pioneered newer techniques for percutaneous mechanical pulmonary thrombectomy and techniques for endovascular treatment of aortic aneurysms, ischemia and gangrene of the limbs, endovenous laser therapy and below-knee interventions and pudendal artery stenting for male erectile dysfunction. For his contributions, he has been conferred many awards like Glory of India Award, Rajiv Gandhi Award, Mother Teresa Award, and Distinguished Services Award by World Congress on Clinical and Preventive Cardiology.



Rishi Sethi MD DM FACC FESC FSCAI MAMS FAPSIC FCSI is an eminent Interventional Cardiologist and Professor, Department of Cardiology, King George's Medical University, Lucknow, Uttar Pradesh, India. He received his training in Interventional Cardiology from the National University Heart Center, Singapore. Apart from his role as an interventional cardiologist, his prominent areas of interest are clinical research and advocacy. He is a recipient of Cardiological Society of India Travel Award and AV Gandhi Award for Excellence in Cardiology. He is presently Member of Scientific Advisory Committee of Asian Pacific Society of Interventional Cardiology and the Convener of the CSI-STEMI Subspecialty Council.



J Shiv Kumar MBBS MD (Internal Medicine) DM (Cardiology) is Senior Consultant and Head of Cardiology, Apollo Hospitals, Secunderabad, Telangana, India and Faculty (Cardiology), Preventive and Promotive Health Care, Deemed University recognized by Harvard University, USA. He has authored a book *Preventive Cardiology for PPHC Students* recognized by Medical Council of India. He is a member of National Education for Rural Health Doctors recognized by Government of India. He has been Speaker and Chairperson at International Colombo Summit, Colombo, Sri Lanka (2003), HDL Symposium, Dubai, UAE (2003), Phuket, Bangkok (2004), Cairo, Egypt (2005).

Available at all medical bookstores
or buy online at www.jaypeebrothers.com

JAYPEE BROTHERS
Medical Publishers (P) Ltd.
www.jaypeebrothers.com

Join us on facebook.com/JaypeeMedicalPublishers

Shelving Recommendation
CARDIOLOGY

ISBN 978-93-85999-98-7