eebrothers.com, for detailed information on dental books, visit our website www.jaypeebrothers.com, for detailed information on dental books

Essential Quick Review

With Free Companion FAQs on Operative Dentistry & Endodontics

Operative Dentistry & Endodontics



HIGHLIGHTS

- Supplementary FAQ book containing Definitions, Classifications and Viva-voce
- Diagrams with supporting answers
- Recent question bank of all India universities
- Covers entire undergraduate DCI syllabus

Priya Verma Gupta
Vivek Hegde

JAYPEE

Contents

Section 1 Operative Dentistry

1. Introduction to Operative Dentistry 3-5
2. Isolation 6-10
3. Dental Caries, Risk Assessment and Management 11-24
4. Fundamentals of Tooth Preparation 25-33
5. Dental Cements 34-46
6. Dental Amalgam Restoration 47-59
7. Composite Resins 60-67
8. Composite Resin Restoration 68-71
9. Direct Gold Restoration 72-76
10. Dental Hypersensitivity 77-78
11. Cast Metal Restorations 79-83
12. Minimal Interventional Dentistry 84-88
13. Infection Control 89-92

Section 2 Endodontics

14. Clinical Diagnostic Aids in Endodontics 95-101
15. Diagnosis and Treatment Planning 102-105
16. Instruments 106-115
17. Materials in Endodontics 116-123
18. Principles and Rationale of Endodontic Treatment 124-124
19. Biomechanical Preparation 125-130
20. Obturation of Root Canal 131-136
21. Endodontic Emergencies 137-148
22. Endodontic Surgery Replantation and Transplantation 149-154
23. Post-endodontic Restorations 155-157
24. Endodontic Failures 158-162
25. Tooth Discolouration and Its Management 163-165
26. Treatment of Traumatised Teeth 166-171

Section 3 Recently Asked Questions

27. Recently Asked Questions 175-203

Chapter 4

Fundamentals of Tooth Preparation

LONG ESSAYS

Question 1

Define cavity preparation. Write the various concepts of cavity design for amalgam restorations?

Answer

- Cavity: It refers to a defect in the tooth enamel or in both enamel and dentine due to carious process
- Cavity preparation: It is the mechanical alteration of a defective, injured or diseased tooth to best receive a restorative material, which will re-establish the normal form, function and aesthetics of the tooth.

Outline Form

This forms the occlusal portion just like pit and fissure lesions but the difference being the external outline is extended proximally towards proximal surface that is defective.

Establishing the Occlusal Slip

A punch cut is made in the pit close to the involved proximal surface using a high speed bur.

- A number 245 bur is used
- The long axis of bur is kept parallel to the long axis of tooth
- Initial depth should be 1.5–2.0 mm (**Fig. 4.1**).

Central fissures are included while the outline is extended to maintain uniformity in depth of pulpal floor.

- Isthmus width should be narrow as null as possible. It should not be wider than one-fourths of the intercuspal distance
- Slight occlusal convergence to facial, lingual and proximal walls are given that provides retention for amalgam restoration
- On distal pit area a dovetail is given which prevents mesial displacement of the restoration.

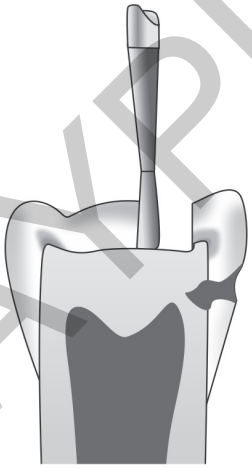

Fig. 4.1: Extend the bur keeping it parallel to the long axis of tooth

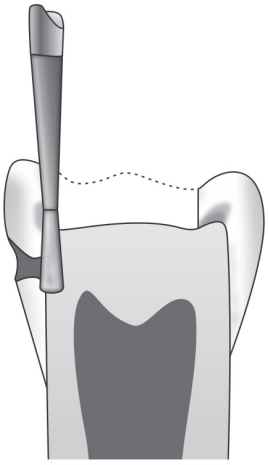

Fig. 4.2: Extend the preparation ending short by 0.8 mm of cutting through marginal ridge

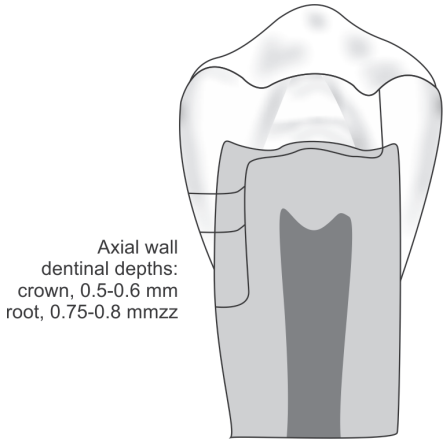

Fig. 4.3: Proximal cutting should be sufficiently deep into dentin

JAYPEE BROTHERS

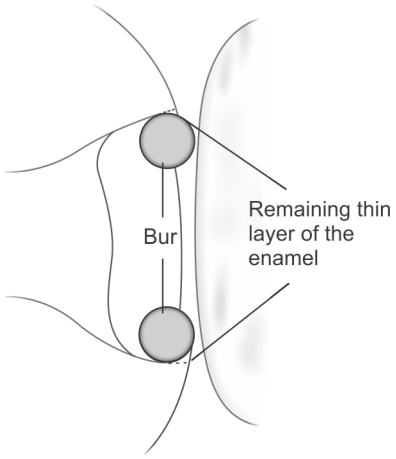

Fig. 4.4: A small slice of enamel is kept at contact area so as to prevent accident damage to adjacent tooth

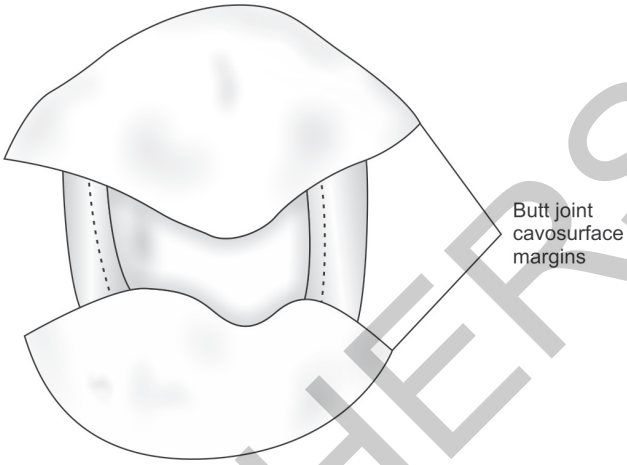

Fig. 4.5: The cavosurface margins should be 90° with occlusal convergence

Extending Occlusal Step Proximally

- Outline form is determined by the faciolingual position of the contact and the extent of carious lesion
- Preparation is extended towards the proximal surface while establishing the pulpal depth
- It should be 0.8 mm short of cutting through mesial marginal ridge **(Fig. 4.2)**
- The retentive locks are prepared into the axiolingual and axiofacial line angles **(Fig. 4.3)** proximal cutting into dentine should be 0.5–0.6 mm.

Preparation of Proximal Box

- To clear the contact area faciolingual preparation is widen
- Proximal cut is diverged gingivally
- This is done to gain good retention and to conserve the marginal ridge
- Small amount of enamel is left at the contact area to prevent damage to the adjacent tooth **(Fig. 4.4)**
- Use matrix bond to avoid contact
- Using a chisel or enamel hatchet fracture the enamel in the region of the contact
- Proximal margins should have a cavosurface angle of 90° and proximal box should converge occlusally **(Fig. 4.5)**
- It should be done to keep the tooth strong and the occlusal forces on the amalgam should be lesser
- Clearance of facial and lingual margins of proximal box should be 0.2–0.5 mm.

Primary Resistance Form

- There should be flat pulpal and gingival floor
- It should have cavosurface angle of 90°
- It should include the weakened tooth structure
- It should pressure tooth structure by maintaining minimal width of the preparation
- All the internal unit and point angles are rounded
- Cusp capping is done to pressure the cuspal strength.

Primary Retention Form

- It prevents the restoration from being displaced
- Retention form is increased by:
  - Two to five percent occlusal convergence of the buccal and lingual walls
  - By giving an occlusal dovetail.

Final Tooth Preparation

- Remove all the debris and correct all cavosurface angles and margins
- Removal of old restorative materials, remaining caries and deep pit and fissures that are involved in the preparation
- Removal of soft caries with spoon excavator or slow speed round bur.

Secondary Retention and Resistance Form

- Retention grooves are placed
- Locking the proximal box
- Placement of slots and pot holes in the gingival floor.

Pulp Protection

- Use of pulp protecting material
- Finishing of enamel walls and margins
- All unsupported enamel is removed
- Beveling of enamel portion of the gingival wall with gingival margin trimmer (GMT)

JAYPEE BROTHERS

- Cavosurface angle should be 90°
- Finally clean the preparation with wally and air spray
- Dry it with moist air.

Question 2

Define fissure sealant, pit, fissure and occlusal sealants and classify pit and fissure sealant?

Answer

Fissure Sealant

A fissure sealant is a material that is placed in the pits and fissures of teeth in order to prevent or arrest the development of dental caries.

Fissure sealants are defined whereby pits and fissures that occur principally on the occlusal surfaces of the molar and premolar, teeth are occluded by application of fluid materials, which are then polymerized.

Pit

It is defined as a small pinpoint depression located at the junction of developmental grooves or at terminals of those grooves. The central pit describes a landmark in the central fossae of the molars where developmental grooves join (Ash, 1993).

Fissure

It is defined as deep clefts between adjoining cusps. They provide area for retention of caries producing agents. These defects occur on occlusal surfaces of the molars and premolars, with tortuous configuration that are difficult to assess from the surfaces. These areas are impossible to keep clean and highly susceptible to advancement of the carious lesion, (Orbans, 1990).

Occlusal Sealants

Occlusal sealants are defined as the application and mechanical bonding of a resin material to an acid etched enamel surface thereby sealing existing pits and fissures from the oral environment.

Classifications

Pits and fissures are broadly classified into four varieties:

- A shallow groove
- Complete penetration of the enamel
- The fissure may end blindly
- The end of fissure may open into an irregular chamber.

Nagano (1960) described four principal types of fissures, based on the alphabetical description of shape.

- V type
- U type
- I type
- IK type.

The shallow, wide V and U shaped fissures tend to be self-cleansing and somewhat caries resistant. Deep, narrow I shaped fissures are quite constricted and resemble a battle neck. They have a narrow slit-like opening with a larger base as it extends toward the dentino-enamel junction. These caries susceptible, I shaped fissures may also have a number of branches. Similarly, IK shaped fissures are also very susceptible to caries. Usually, non-invasive technique is recommended for U and V shaped fissures and invasive technique for I and IK type fissures.

Pit and fissure sealants can be classified in different ways.

- According to the chemistry of materials it may be of three types with different resin systems:
  - Alkyl cyanoacrylates
  - Polyurethane
  - BIS-GMA.
- According to the method of polymerization
  - Ultraviolet-activated sealants
  - Self-cured or chemically cured sealants
  - Light-activated sealants.
- According to the filler particles incorporated in the sealants
  - Filled
  - Unfilled.
- According to the coloring pigments incorporated into the sealants.
  - Clear
  - Tinted/endowed sealants.

Mitchell and Gordon (1990) stated that the sealants can be differentiated in the following ways:

- Polymerization methods
  - Self-activation (mixing two components)
  - Light activation
    - First-generation: Ultraviolet light
    - Second-generation: Self-cure
    - Third-generation: Visible light.
  - Fourth generation: Fluoride releasing.
- Resin systems
  - BIS–GMA
  - Urethane acrylate.
- Filled and unfilled

JAYPEE BROTHERS

- Clear or tinted: Clear sealants have been shown to have better flow characteristics than tinted or opaque, but this can be an advantages or disadvantage depending on the position of the tooth to be sealed. Although the retention rates of the two types are similar, colored sealants are more easily appreciated by the patients and monitored by the dentist at subsequent recalls.

RJ Simonsen (1981) listed the advantages of coloring the sealants.

- Ease in detection which makes recall examinations much easier and faster
- Ease in application, for example, one can more easily detects the materials, where the material is placed and that if it is present in the amount desired
- Provision of a visible primary preventive service that increases patient and parents acceptance.

RIPA (1993) classified fissure sealant into four generations:

1. Ultraviolet activated
2. Auto polymerizing
3. Visible light cured
4. Fluoride containing sealants.

Question 3

Write a short note on classification of the tooth preparation?

Answer

Classification of Tooth Preparation

GV Black (1947) classified tooth preparation based on anatomic areas involved and the associated type of treatment. He classified tooth preparation into five original classes. Later class VI was added to the original classification by Simon.

Class I

All pit and fissure restorations are included in this class. Class I restorations can be divided into three groups:

1. Restoration on occlusal surface of premolars and molars
2. Restoration on occlusal two-thirds of the facial and lingual surfaces of molars
3. Restoration on lingual surface of maxillary incisors **(Figs. 4.6 - 4.8)**.

*Class I cavity preparation has eight (8) line angles and four (4) point angles.

Class II

All restorations on proximal surface of posterior teeth:

1. MO: Mesio-occlusal preparation
2. DO: Disto-occlusal preparation
3. MOD: Mesio-occlusal distal preparation **(Figs. 4.9 - 4.11)**.



Fig. 4.6: Typical class I cavity preparation on maxillary premolar

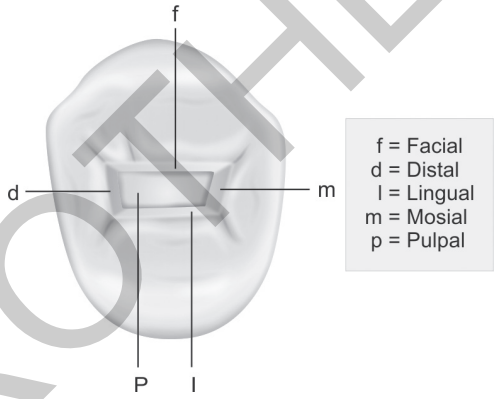

Fig. 4.7: Schematic representation of class I cavity preparation walls

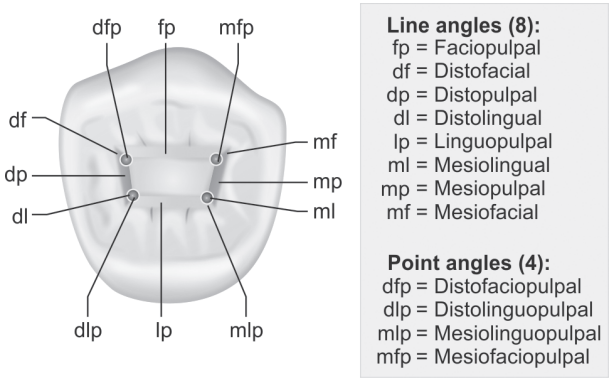

Fig. 4.8: Schematic representation of class I cavity preparation line angles and point angles

*Class II cavity preparation has eleven (11) line angles and six (6) point angles.

Class III

Restoration on the proximal surfaces of anterior teeth and do not involve the incisal edge **(Figs. 4.12 - 4.14)**.

*Class III cavity preparation has six (6) line angles and three (3) point angles.

JAYPEE BROTHERS



Fig. 4.9: Typical class II mesio-occlusal cavity preparation on maxillary premolar

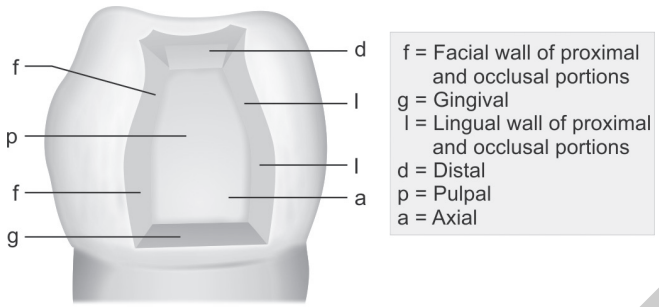

Fig. 4.10: Schematic representation of class II cavity preparation walls

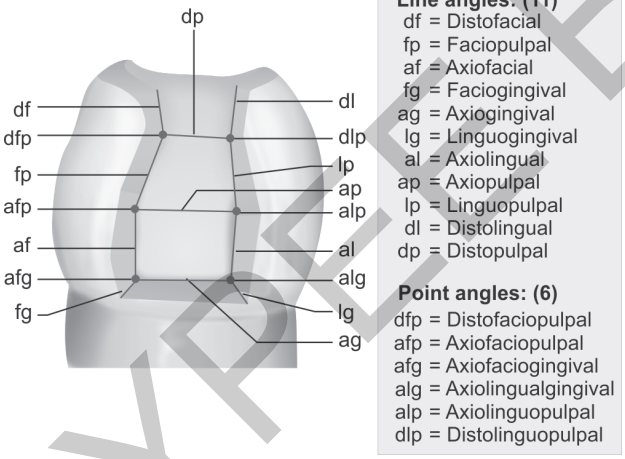

Fig. 4.11: Schematic representation of class II cavity preparation line angles and point angles

Class IV

Restoration on the proximal surfaces of anterior teeth that do involve the incisal edge **(Figs. 4.15 - 4.17)**.

*Class IV cavity preparation has eleven (11) line angles and six (6) point angles.



Fig. 4.12: Class III cavity preparation on maxillary central incisor

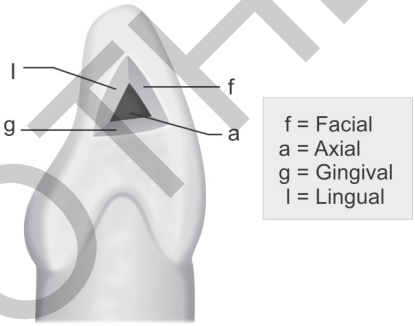

Fig. 4.13: Schematic representation of class III cavity preparation walls

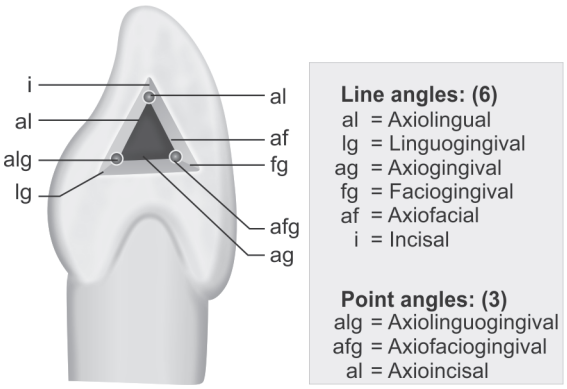

Fig. 4.14: Schematic representation of class III cavity preparation line angles and point angles

Class V

Restoration on the gingival third of the facial third of the facial or lingual surface of all teeth (except pit and fissure lesion) **(Figs. 4.18 - 4.20)**.

*Class V cavity preparation has eight (8) line angles and four (4) point angles.

JAYPEE BROTHERS



Fig. 4.15: Class IV cavity preparation for inlay on maxillary canine

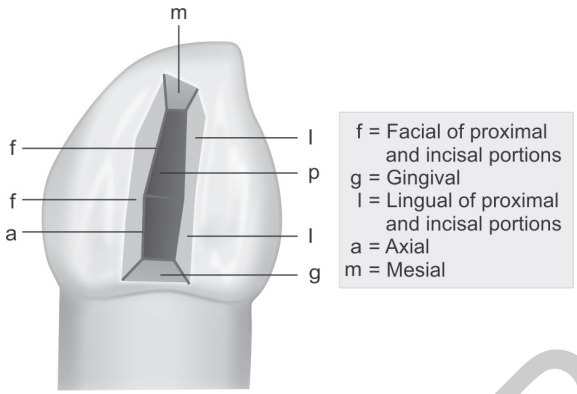

Fig. 4.16: Schematic representation of class IV cavity preparation walls

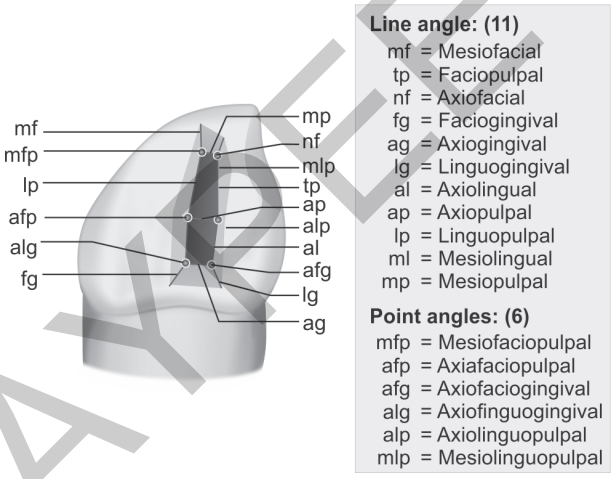

Fig. 4.17: Schematic representation of class IV cavity preparation line angles and point angles



Fig. 4.18: Class V cavity preparation

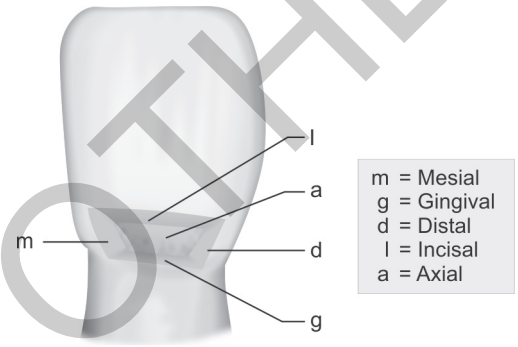

Fig. 4.19: Schematic representation of class V cavity wall

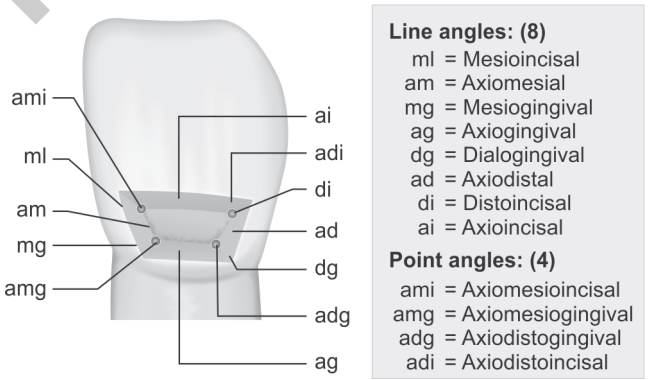

Fig. 4.20: Schematic representation of class V cavity preparation line angles and point angles

Class VI

Restoration on the incisal edge of anterior teeth or the occlusal cup height of posterior teeth.

*Class VI cavity preparation has eight (8) line angles and four (4) point angles.

JAYPEE BROTHERS

SHORT ESSAYS

Question 1

Cavity preparation for class III composites?

Answer

Conventional Class III

Steps

Outline of tooth preparation is determined by the extent of lesion.

- The bur entry is preferred from the lingual side to conserve estethesis, color match is not required, unsupported facial enamel can be saved for bonding, discoloration in future is less visible
- Labial approach is given when the labial enamel is involved
- Malignated teeth
- When there is damage only in the root surface
- When carious lesion is not deep
- It is kept at 0.75 mm.

Beveled Conventional Class III Tooth Preparation

It is indicated in:

- For replacing existing restoration that is defective at the crown portion of anterior tooth
- For larger preparation.

Steps

Caries is approached lingually with small round bur.

- Bur is moved incisogingival direction
- Tooth preparation should be same as that of existing carious lesion
- Initial depth of axial wall should be 0.7 mm deep gingivally
- 1.25 mm deep incisally
- Axial wall should follow the tooth contour
- It should be convex outwardly
- Removal of all infected dentive or restoration is done in final preparation with a spoon excavator
- Calcium hydroxide is placed to protect the pulp
- External walls should be perpendicular to enamel surface **(Fig. 4.21)**
- Prepare retentive grooves and cover along gingiva axial line angle and inciso axial line angle.

Modified (Conventional) Class III Tooth Preparation

It is indicated in: Small to moderate class III.

Steps

- Bur entry is done from palatal surface
- Extent and design depends on the extent of the carious lesion **(Fig. 4.22)**
- It does not have definite axial wall depth
- The walls diverge from axial depth show scoop shape
- Finally, the preparation is cleaned and pulp protection is provided.

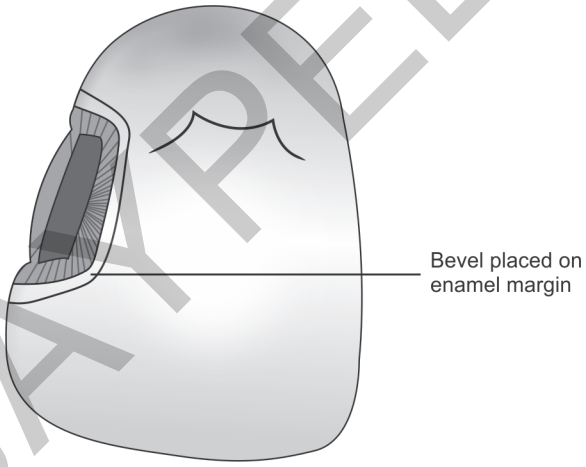

Fig. 4.21: Beveled class III tooth preparation for composites

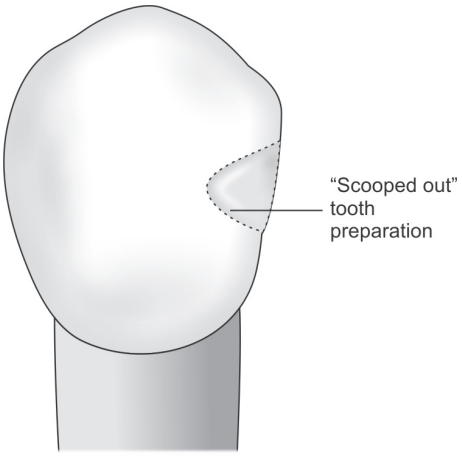

Fig. 4.22: Extent of preparation is determined by extent of caries

JAYPEE BROTHERS

SHORT NOTES

Question 1

Explain extension for prevention?

Answer

Extension for prevention is placing the margins of preparations at areas that would be cleaned by the excursions of food during chewing.

- In this the margins of the restoration are placed on line angles of the tooth
- The occlusal surface is extended through pits and fissures
- Buccal and lingual extending of proximal unit angles through embrasures and cervically below the gingival margin
- It prevents recurrence of decay in the tooth surface of adjoin restoration
- It results in self-cleaning embrasure areas.

Question 2

What is air abrasion?

Answer

- It is also known as advanced particle beam technology or microabrasion
- It is done by involving high energy sand blasting of tooth surface
- This works on the method that abrasion particles are emitted in a particular, well defined shape that is focused on the target
- Particle: Size 25–30μ
- Pressure: 60–120 pound per square inch pressure
- Most common in the AL_2O_3 dust.

Question 3

Discuss reverse class II amalgam restoration?

Answer

- In class II cavity preparation extension of proximal area is important for eliminating caries and for breaking the proximal contacts
- In cases where the teeth have broader contacts reverse S-shape curve is given
- It is done to widen the box and it removes less tooth structure **(Fig. 4.23)**
- Excessive flare should be avoided as this will make proximal walls pass the axial angle through the cusp
- This then results in weakening of tooth and more prone to fracture.

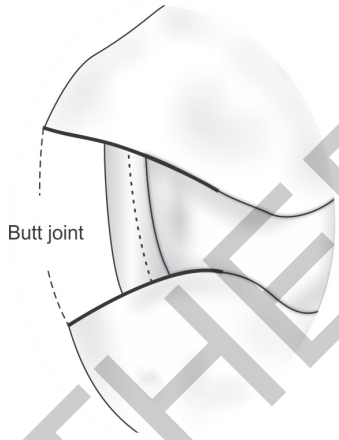

Fig. 4.23: Reverse curve is given to the proximal walls by curving them toward the contact area

Advantages

- Triangular ridge is prevented in the cusp
- Conserves the tooth structure
- Increases the resistance form.

Question 4

What is acid etching?

Answer

- It is a process of increasing the surface reactivity by demineralization the superficial calcium layer and thus cleating the enamel tags. These tags are responsible for micromechanical bonding between tooth and restorative resin
- Acid used is 37% phosphoric acid time given for etching is 15–20 seconds
- It is supplied in liquid and get form

Steps for Bonding

- Cleaning and washing of teeth is done. Dry it to descent any contaminants
- Apply acid etchant for 15–20 seconds
- Wash it with water for 10 seconds
- After wash it should give frosty white appearance
- Bonding agent is than applied.

Properties

- It cleans debris from enamel surface increases the enamel surface for bonding agent
- Products micropores which have mechanical interlocking appearance.

JAYPEE BROTHERS

Question 5

What is enameloplasty?

Answer

It is defined as removal of sharp and irregular enamel margins of the enamel surface by rounding or saucering it and converting it into a smooth groove making itself clearing area.

Indications

- In case where caries thickness is one-third of that of enamel present
- When there are shallow fissures that cross lingual and facial ridge
- It does not extend the outline form so if a fissure cannot be converted into a groove it should not be implemented.

Question 6

Define attrition, abrasion and erosion?

Answer

- Attrition: Attrition is defined as mechanical wear of opposite teeth commonly seen on the contacting occlusal, incisal and proximal surfaces
- Abrasion: Abrasion is defined as loss of tooth material by mechanical wear other than contacting surfaces. It is common due to improper brushing and use of abrasive tooth powder
- Erosion: Erosion is defined as loss of dental hard tissue as a result of a chemical process which does not involve bacteria.

Question 7

What is smear layer?

Answer

Smear layer is an iatrogenically produced layer which decreases both sensitivity and permeability of dentinal tubules.

It has two compounds:

1. Superficial smear layer: This is the layer which is loosely attached to the underlying dentin till the depth of 1–1.5 mm
2. Smear plugs: This occludes the dentinal tubules. It extends till the depth of 1 mm.

Question 8

What is cavosurface angle?

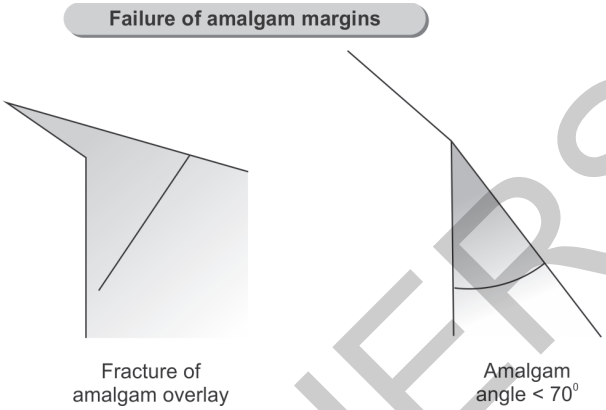

Fig. 4.24: Cavosurface margins should be 90° for amalgam fracture of restoration can occur if angle is acute or obtuse

Answer

- It is defined as the angle of the tooth structure which is formed by the junction of a prepared wall and the external tooth surface
- It should be a butt joint
- If the cavosurface angle is acute the enamel margin may fracture under load
- If it is obtuse it will fracture under masticatory stress **(Fig. 4.24)**.

Question 9

Explain tunnel preparation?

Answer

It is the preparation made for removal of proximal caries by making an access through occlusal surface while leaving the marginal ridge intact.

Indications

- It is indicated in tooth which won't last more than 5 years
- In posterior teeth, with incipient proximal lesions patients with low caries index.

Contraindications

- When the proximal decay undermines the marginal ridge
- When there is occlusal load on marginal ridge.

Question 10

What is prophylactic odontotomy?

Answer

- It is a technique where minimum cavity preparation is one and amalgam restoration is given
- This procedure is not used now.

JAYPEE BROTHERS

for detailed information on dental books, visit our website **www.jaypeebrothers.com,** for detailed information on dental books, visit our website

Essential Quick Review
Operative Dentistry & Endodontics

Essential Quick Review (EQR) is a simple and comprehensive series that contains all the important aspects of the final year syllabus. The language used here is lucid as well as scientific which can be easily gathered and reproduced in examinations. Efforts have been made to cover all important areas in the form of question–answers, definitions and classifications format. We hope that this effort of ours will prove out to be beneficial for students

Priya Verma Gupta is an experienced pedodontist, currently working as Professor at Divya Jyoti College of Dental Sciences and Research, Modinagar, Ghaziabad, Uttar Pradesh, India. She has keen interest in academics and has many international and national publications to her credit. She has so far authored several books and has contributed actively to other medical and dental textbooks as a co-author as well as contributor. Currently, she is associated with the editorial board of Journal of Indian Medical Gazette and Jaypee's International Journal of Clinical Pediatric Dentistry.



Vivek Hegde is Vice Principal, Professor and Head, Department of Operative Dentistry and Endodontics at M A Rangoonwala Dental College, Pune, Maharashtra, India. His many achievements include being President of the Society of Oral Laser Applications, Director of the Indian Board of Endodontics, Faculty at the University of Vienna, Vienna, Austria, Editor of various Journals and past Vice President of the Indian Association of Conservative Dentistry and Endodontics (IACDE).



Available at all medical bookstores
or buy online at www.jaypeebrothers.com

JAYPEE BROTHERS
Medical Publishers (P) Ltd.
www.jaypeebrothers.com

Join us on facebook.com/JaypeeMedicalPublishers

Shelving Recommendation
DENTISTRY

ISBN 978-93-86056-22-1