our website **www.jaypeebrothers.com,** for detailed information on radiology books, visit our website **www.jaypeebrothers.com**

Textbook of
RADIOLOGY
Musculoskeletal Radiology



Editors
Hariqbal Singh
Shrikant Nagare

JAYPEE

Contents

1. Congenital Skeletal Anomalies and Dysplasia **1**

Preaxial and Postaxial Polydactyly *1*; Ectrodactyly Ectodermal Dysplasia Cleft Lip Syndrome *1*; Madelung's Deformity *1*; Congenital Hip Dislocation *2*; Osteopetrosis *2*; Sprengel Deformity *3*; Macrodystrophia Lipomatosa *3*; Multiple Epiphyseal Dysplasia *3*; Cleidocranial Dysostosis *4*; Holt-Oram Syndrome *5*; Fibrous Dysplasia *6*; Fibrodysplasia Ossificans Progressiva *7*; Mucopolysaccharidoses *7*; Perthes Disease *10*; Congenital Bifid Sternum *10*; Bone Island or Enostosis *11*

2. Trauma **12**

Patterns of Fracture *12*; Healing of Fracture *12*; Fall on Outstretched Hand *14*; Fracture *16*; Stress Fracture *18*; Segond Fracture *19*; Avulsion Fracture *20*; Fracture Scaphoid *21*

3. Metabolic and Endocrine Disorders **22**

Rickets *22*; Renal Rickets *23*; Osteoporosis and Osteomalacia *24*; Acromegaly *25*; Fluorosis *26*; Resorption of Terminal Tufts *26*; Expansile Lesions of Metaphysis *27*; Hand as an Index of Disease *29*

4. Infections **32**

Periosteal Reaction (Periostitis) *32*; Osteomyelitis *32*; Sequelae to Septic Arthritis *36*; Tuberculous Arthritis *36*; Congenital Syphilis *37*; Infectious Arthritis *37*; Sacroiliitis *38*

5. Noninfective Inflammatory Arthritis **41**

Seronegative Spondyloarthropathy *41*; Hypertrophic Osteoarthropathy *42*; Ankylosing Spondylitis *44*; Psoriatic Arthritis *44*

6. Joints **46**

Anatomy Shoulder Joint *46*; Avulsion of Greater Tuberosity *47*; Acromioclavicular Degeneration *48*; Spinoglenoid Cyst *49*; Glenoid Labrum Tear *50*; Tuberculous Arthritis Right Shoulder *50*; Rotator Cuff Tears *52*; Anatomy Hip Joint *52*; Osteoid Osteoma *54*; Avascular Necrosis *56*; Septic Arthritis *58*; Anatomy Knee Joint *58*; Cruciate Ligaments *63*; Collateral Ligaments *63*; Menisci *65*; Pigmented Villonodular Synovitis *69*; Osteomyelitis *69*; Rheumatoid Arthritis *69*; Neuropathic Arthropathy *71*

7. Bone Tumors **72**

WHO Classification of Bone Tumors *72*; Aneurysmal Bone Cyst *73*; Osteoid Osteoma *74*; Osteochondroma *75*; Diaphyseal Aclasis (Chondromatosis) *76*; Tallus Chondroblastoma *77*; Giant Cell Tumor *77*; Hemangioma *78*; Lipoma *78*; Adamantinoma *79*; Fibrolipomatous Hamartoma Median Nerve *80*; Plasma Cell Tumor *81*; Plasmacytoma *82*; Multiple Myeloma *83*; Pigmented Villonodular Synovitis *84*; Fibrous Dysplasia *86*; Polyostotic Fibrous Dysplasia *87*; Ameloblastoma *89*; Loose Bodies in Shoulder Joint *90*; Osteochondritis Dissecans *90*; Odontogenic Fibromyxoma of the Maxilla *90*; Osteosarcoma *90*; Ewing's Sarcoma *96*; Osseous Lymphoma *96*; Liposarcomas *98*; Sacrococcygeal Teratoma *99*; Skeletal Metastasis *99*

8. Soft Tissues **101**
Classification of Soft Tissue Tumors *101*; Subcutaneous Lipoma *101*; Macrodystrophia Lipomatosa *103*; Liposarcoma *105*; Fibrolipomatous Hamartomas of Median Nerve *105*; Baker's Cyst *106*; Complete Tear Tendo-Achilles *106*; Neurogenic Tumors *106*; Bilateral Nasolabial Cyst *109*; Soft-tissue Calcifications *109*

9. Breast **116**
Breast Anatomy *116*; Breast Cysts *117*; Antibioma *118*; Intramammary Lymph Node *119*; Fibroadenomas *119*; Gynecomastia *120*; Phyllodes Tumor *120*; Carcinoma Breast *120*; Carcinoma Breast with Metastases *120*; Carcinoma *In Situ* *121*

10. Miscellaneous **124**
Imaging in Sickle Cell Anemia *124*; Pycnodysostosis *125*; Solitary Dense Vertebra *125*; Rib Notching *125*; Bone Infarct *125*; Fibrous Dysplasia *126*; Kienböck's Disease *127*; Avascular Necrosis Scaphoid *127*; Hyperostosis Frontalis Interna *129*; Renal Osteodystrophy *129*; Ozone Therapy *130*; Geode *131*; Magnetic Susceptibility Artifact *132*; Cloud Computing *132*; Metallic Foreign Bodies *132*

11. Ossification Centers **134**

Index *139*

4
Infections

Periosteal Reaction (Periostitis)

Periosteum is the outer surface of bone which separates bone from surrounding soft tissues. It is firmly adherent to the underlying bone. It is normally not visible on X-rays. An underlying inflammatory or neoplastic process provokes hyperemia that activates fibroblasts to osteoblasts that produce osteoid tissue which gets mineralized and appears as layers of new bone termed as periostitis **(Fig. 4.1)**. Presence of periosteal reaction indicates the biologic underlying process. It takes 10–21 days from the intial insult for the periosteal reaction to become visible on X-rays.



Fig. 4.1 X-ray forearm shows periosteal reaction (arrow) in the process of healing of fracture

Causes of Periosteal Reaction

- Trauma
- Infection
- Inflammatory arthritis
- Neoplasm—osteoid osteoma, osteosarcoma. Ewing's sarcoma
- Congenital—physiological in infants during first 1–6 months
- Metabolic—hypertrophic pulmonary osteoarthropathy, thyroid
- Acropachy, hypervitaminosis A, fluorosis
- Venous insufficiency.

Types of Periosteal Reaction

- Continuous—it may be solid, lamellar, multilamellar or parallel spiculated
  - Solid—seen as thickening of periosteal surface and indicates benign etiology as in osteoid osteoma, eosinophilic granuloma
  - Single lamellar—thin 1–2 mm faint radiopaque line from the cortical surface as in histiocytosis, healing fractures
  - Multilamellar or onion peel-multiple concentric layers of periosteum as in Ewing's sarcoma
  - Parallel speculated-bony spicules may appear perpendicular to the cortex, i.e. hair on end appearance as seen with thalassemia. Sunburst appearance is due to bony spicules fanning out in focal divergent manner and seen with osteosarcoma.
- Discontinuous or interrupted mineralization forms an angular configuration with underlying cortex resembling both sides of an angle (Codman angles) as in osteogenic sarcoma
- Complex reaction includes combination of lamellated, divergent spiculated reaction and Codman's angle.

Osteomyelitis

Osteomyelitis refers to bony inflammation that is almost always due to infection, typically bacterial. In most instances, osteomyelitis results from hematogenous spread, although direct extension from trauma and ulcers is also relatively common.

In the initial stages of infection, bacteria multiply setting up a localized inflammatory reaction and resulting in localized cell death. With time the infection becomes demarcated by a rim of granulation tissue and new bone deposition.

Although no organisms are recovered in up to 50% of cases, when one is isolated, *Staphylococcus aureus* is by far the most common agent. Different organisms are more common in specific clinical scenarios. *Staphylococcus aureus*: 80–90% of all infections.

JAYPEE BROTHERS

- *Escherichia coli:* Intravenous drug users and genitourinary tract infection
- *Pseudomonas:* Intravenous drug users and genitourinary tract infection
- *Klebsiella:* Intravenous drug users and genitourinary tract infection
- *Salmonella:* Sickle cell disease
- *Haemophilus influenzae:* Neonates
- *Group B streptococci:* Neonates

The location of osteomyelitis within a bone varies with age, on account of changing blood supply:

- *Neonates:* Metaphysis and or epiphysis
- *Children:* Metaphysis
- *Adults:* Epiphyses and subchondral regions

In some instances, radiographic features are specific to a region or particular type of infection, for example:

- Subperiosteal abscess
- Brodie's abscess
- Pott's puffy tumor
- Sclerosing osteomyelitis of Garre.

Considering the imaging, the earliest changes are seen in adjacent soft tissues with swelling and loss of normal fat planes. An effusion may be seen in an adjacent joint. The bone itself remains normal in appearance for 10–14 days. After this time a number of changes may be noted like regional osteopenia, periosteal reaction and may appear aggressive including formation of a Codman's triangle and eventually peripheral sclerosis.

In chronic or untreated cases eventual formation of a sequestrum, involucrum or cloaca may be seen.

CT is superior to both MRI and X-rays in depicting the bony margins and identifying a sequestrum/involucrum. Appearances are otherwise similar to plain films.

MRI is most sensitive and specific and is able to identify soft-tissue/joint complications.

Although ultrasound excels as a fast and cheap examination of the soft tissues, and allows soft tissue collections to be drained it has little direct role in the assessment of osteomyelitis, as it is unable to visualize within bone.

It does however have a role to play in assessment of soft tissues and joints adjacent to infected bone, able to visualize soft tissue abscesses, cellulitis, sub periosteal collections and joint effusion.

Ultrasound also is useful in assessing the extra-osseous components of orthopedic instrumentation as it is not affected by metal artifact.

In nuclear medicine a number of techniques may be employed to detect foci of osteomyelitis. These include:

- *Bone scintigraphy (Tc-99m):* Increased osteoblastic activity results in increased levels of radiotracer uptake in the surrounding bone usually both on blood pool and delayed views. It is highly sensitive but not particularly specific.
- *In^{111}-labeled WBC and $Galium^{67}$ scintigraphy is particularly useful in:*
  - Diabetic osteomyelitis, especially combined with Tc-99m phosphonate imaging
  - Orthopedic implants
  - Vertebral osteomyelitis (Ga^{67})
  - Ulcers in bed ridden patients with potential underlying osteomyelitis (In^{111} with Tc-99m phosphonate).

Acute Osteomyelitis

Acute osteomyelitis is an inflammation of bone (cortical bone and its marrow space) caused by an infecting organism. Pyogenic osteomyelitis is the most common and Staphylococcus aureus is the most common bacteria involved. Although on the basis of the route of infection, acute osteomyelitis can be classified as hematogenous or exogenous. Hematogenous osteomyelitis is predominantly seen in children (2–16 years) and involves the highly vascular long bones, especially those of the lower limb. In adults, hematogenous spread is more common to the lumbar vertebral bodies than elsewhere. In neonatal osteomyelitis, isotopic bone scans are reportedly normal in most patients.

Before puberty, infection starts in the metaphyseal sinusoidal veins. Because bones are relatively rigid structures, focal edema accumulates under pressure and leads to local tissue necrosis, breakdown of the trabecular bone structure, and removal of bone matrix and calcium. Infection spreads along the haversian canals, through the marrow cavity, and beneath the periosteal layer of the bone. Subsequent vascular damage causes the ischemic death of osteocytes, leading to the formation of a sequestrum. Periosteal new bone formation on top of the sequestrum is known as involucrum.

Differentiating acute osteomyelitis from bone infarction in patients with sickle cell disease is a major challenge. The 2 conditions must be differentiated on the basis of clinical findings and imaging studies because both are common in patients with sickle cell disease. The 2 diseases are managed differently.

Fine-needle aspiration (FNA) or needle biopsy may be used under ultrasonographic, fluoroscopic, or CT guidance to obtain samples of pus, tissue, or both to establish a histologic diagnosis of acute osteomyelitis. The disease process involves 5 stages:

1. *Inflammation:* This stage represents initial inflammation with vascular congestion and increased intraosseous pressure; obstruction to blood flow occurs with intravascular thrombosis.
2. *Suppuration:* Pus within the bones forces its way through the haversian system and forms a subperiosteal abscess in 2–3 days.
3. *Sequestrum:* Increased pressure, vascular obstruction, and infective thrombus compromise the periosteal and endosteal blood supply, causing

JAYPEE BROTHERS

bone necrosis and sequestrum formation in approximately 7 days.
4. *Involucrum:* This is new bone formation from the stripped surface of periosteum
5. *Resolution or progression to complications:* With antibiotics and surgical treatment early in the course of disease, osteomyelitis resolves without any complications.

Clinical features vary in infants, children and adults, being related to the structural and vascular differences of bone at these ages. In children older than one year the epiphyseal plate blocks extension of the infection so the infection spreads laterally into the subperiosteal space or to the joint in which synovial reflections extend beyond the epiphysis to metaphysis, such as the shoulder and hip joints. In infants, small capillaries cross the epiphyseal growth plate, and thus, permit extension of infection to the epiphysis and the joint. In adults the epiphyseal plate is fused and no longer forms a barrier to the spread of infection from metaphysis to the adjacent joint. Thus acute pyogenic arthritis is a frequent complication of osteomyelitis in infants.

Neonatal osteomyelits presents with few clinical signs despite multiple sites of involvement, and hence, a complete skeletal survey is warranted in such cases. Premature infants requiring umbilical catheterization are at higher risk for osteomyelitis. Radionuclide bone scintigraphy is advocated in all patients with suspected neonatal osteomyelitis, following initial radiographs.

Plain radiographs are the first imaging study in the work-up of osteomyelitis. Soft tissue swelling and small single or multiple osteolytic areas affecting the metaphysis is the earliest change which is seen within 7–10 days. Elevation of the periosteum or periosteal reaction which is lamellar layered new bone formation is seen after 3–6 weeks. Typically the dead bone (sequestrum) also forms at 3–8 weeks. It appears dense. Osteopenia in the surrounding bone develops due to hyperemia. Later remodeling reverts the appearance of bone to normal in infants and children but in adults the sclerosis and cortical irregularity persist.

Ultrasonography shows deep soft tissue swelling (earliest sign). Periosteal elevation seen as a hyperechoic line with subperiosteal fluid collection. Cortical breech is seen as focal defect in the cortex. Ultrasonography detects presence of fluid in the joint especially of hip and shoulder joints in an infant.

Radionuclide scintigraphy is the most sensitive investigation for diagnosing acute osteomyelitis 99m Tc-labeled methylene diphosphonate (99m Tc-MDP), hydroxymethylene diphosphonate (99m Tc-HMDP) and gallium 67 citrate are the most commonly used radionuclide agents. They shows positive findings usually within 3 days and sometimes within 24 hours of onset of infection. Triple phase bone scanning is done; osteomyelitis shows hot areas on all phases.

MRI is an important imaging tool in the evaluation of early osteomyelitis and overlying soft tissue involvement. It is superior to scintigraphy in evaluation of axial skeletal osteomyelitis because of better anatomical delineation. In addition, MRI can distinguish soft tissue infection with periostitis from osteomyelitis.

Localized Osteomyelitis (Brodie's Abscess)

Brodie's abscess is a limited osteomyelitis caused either by organisms of low virulence of high resistance in the host. It occurs most frequently at one end of the bone, but it, may also occur in the diaphysis. It is seen as a well circumscribed osteolytic focus surrounded by a sclerotic margin. Occasionally a metaphyseal serpiginous channel with sclerotic border marks the tract of infection. This is considered characteristic of nontubercular etiology like *Staphylococcus*, *Streptococcus* or *hemophilus*. In early stage when the lesion is small, it is difficult to identify on X-rays and CT or MRI is required.

Chronic Osteomyelitis

Chronic osteomyelitis results from failure to eliminate the acute or subacute osteomyelitis, or from local spread of soft tissue infection, complication of compound fractures or following surgery. Radiographs show bone destruction and focal cortical thickening due to periosteal new bone formation, cortical defects and sequestrum with modeling deformities and soft tissue irregularities can also be seen. The sequelae include:

a. Growth plate destruction leading to limb length discrepancy
b. Extensive bone destruction with modeling deformity.
c. Avascular necrosis and sequestrum formation **(Figs 4.2 and 4.3)**
d. Chronically discharging sinus **(Figs 4.4A to D)**
e. Pathological fractures and
f. Premature osteoarthritis changes.

Sequestrum is a piece of dead bone that has become separated during the process of necrosis from normal bone. It is extra dense, more radio-opaque and more heavier than surrounding bone. It does not decalcify because of avascularity. Its surface is usually irregular due to erosive process by proteolytic enzymes in granulation tissue. Types of sequestra are:

1. Tubular or diaphyseal seen in pyogenic osteomyelitis.
2. Trapezoid seen in pyogenic osteomyelitis.
3. Ring seen at end of stumps, around Steinmann pin and wires.
4. Flake or Feathery seen in tuberculous osteomyelitis in a cavity.
5. Coarse Sandy seen in tuberculous osteomyelitis out the cavity.
6. Fine Sandy seen in viral osteomyelitis.
7. Black seen in actinomycosis.

JAYPEE BROTHERS

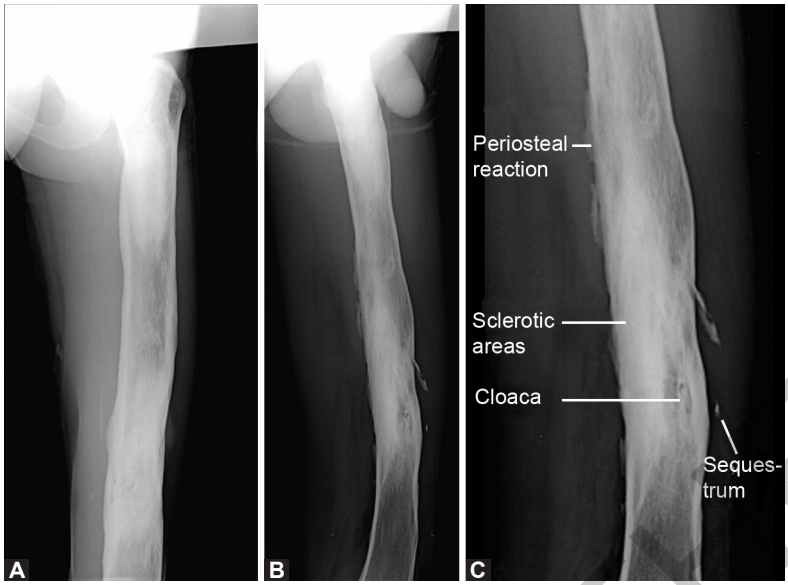

Figs 4.2A to C X-ray thigh shows chronic osteomyelitis. C is magnified view of B



Fig. 4.3 X-ray left forearm of a 3-year-old male with chronic osteomyelitis, ulna shows cortical thickening, bone destruction and sequestrum formation (arrows)

Clinically pain, local swelling, discharge from wound, sinus formation, scars and muscle contractures, shortening of bones, deformities and decreased movements and systemic signs and symptoms may be present.

Conventional X-rays show cloacae, involucrum or sequestrum. There are sclerotic and lucent areas admixed with bony thickening and deformities. In osteomyelitis of the skull, typically no sclerosis is seen.

Scintigraphy: It is more useful in determining activity. 67Ga has been recommended as the optimal agent. Following successful treatment 67Ga uptakes should decrease to a normal level.

MRI is used to distinguish regions of active infection from uninvolved marrow or fibrotic regions.

Sclerosing Osteomyelitis of Garre

A rare type of chronic osteomyelitis occurring in children and young adults, presenting with insidious onset of local pain. There is predilection for involvement of mandible and shafts of long bones.

JAYPEE BROTHERS

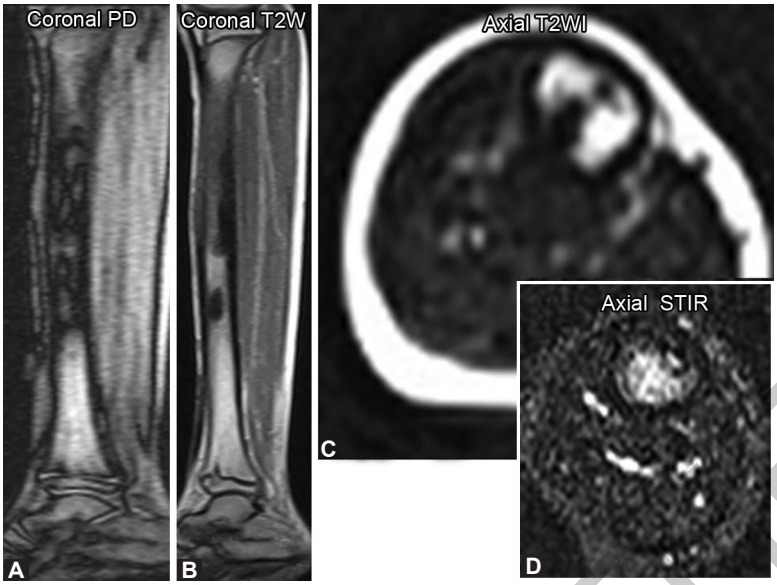

Figs 4.4A to D A 10 years old female presented with discharging sinus on right side of leg with pain and fever on MR shows altered marrow signal intensity involving the metadiaphysis of the right tibia. Patchy areas of sclerosis noted with endosteal thickening and sinus tract noted in the lower end of tibia in the anteromedial cortex. Soft tissue edema with focal collection noted in the anteromedial soft tissue of the tibia with a sinus tract in a case of osteomyelitis of right tibia

Radiological appearance is of intense sclerosis resulting in thickened bone. Areas of frank bony destruction are rare. In this the periosteal reaction and permeative bone destruction are absent.

Sequelae to Septic Arthritis

Infectious arthritis affects children and hip joint is a common site to be involved. Spread of infection may be hematogenous, local trauma, neighboring osteomyelitis or adjoining soft tissue infection. *Streptococcus* group is frequently implicated. The avascular joint cartilage gets infected through the highly vascular synovial membrane causing edema and effusion, the obliteration of cartilage leads to reduction of joint space and destroys the articular cartilage. Followed by immobilization due to pain leads to osteoporosis and destruction leading to subluxations or dislocations other sequelae are fibrous ankylosis and deformity. Initially radiographs may show joint space widening with soft tissue swelling. Later osteoporosis, loss of joint space, marginal and central erosion of articular cortex is seen **(Fig. 4.5)**.



Fig. 4.5 Sequelae in septic arthritis left hip in an 8-year-old female in the form of destruction of left femoral head which is displaced superiorly with development of pseudoarthorosis

Tuberculous Arthritis

Tubercle bacilli are deposited in the synovium through a hematogenous route or direct penetration from a metaphyseal focus of osteomyelitis. A monoarticular presentation is most common involving large joints (hip, knee, and shoulder joint) are involved. Bony destruction is not usually evident on clinical presentation which, unlike acute septic arthritis, is slow and insidious with gradual onset of pain, stiffness and synovial swelling.

Initially joint effusion associated with a synovial hypertrophy is seen and is difficult to differentiate from other conditions including septic arthritis, hemophilia, Lyme disease, pigmented villonodular synovitis, and juvenile rheumatoid arthritis. Later on there is gradual proliferation of granulation tissue at the joint periphery which manifests clinically as a joint effusion with or without thickening of synovial tissue. Radiographically, there is soft tissue swelling and diffuse osteopenia, without a focal abnormality. Granulation tissue spreads across the joint, and the

JAYPEE BROTHERS

first bony changes are marginal erosions, which are evident radiographically. Over a time, there is erosion of the articular cartilage and of the underlying bone, resulting in loss of joint space on plain radiographs. Later on secondary degenerative changes in the joint are observed. The early findings on magnetic resonance imaging are nonspecific, and include a joint effusion, marrow edema, and during the stage of arthritis—abnormalities within the articular cartilage and subchondral bone **(Figs 4.6A to D)**.

Radiographic findings characteristic of tuberculous arthritis are referred as Phemister's triad which includes juxta-articular osteoporosis, peripherally located bone erosions and gradual loss of joint space. Soft tissue swelling and osteoporosis may dominate the initial radiographic findings. Marginal erosions in weight bearing joints are characteristic findings in tuberculous arthritis of hip, knee and ankle joints. These erosions produce corner defects simulating erosions of other synovial processes such as rheumatoid arthritis. The eventual outcome of tuberculous arthritis is a fibrous ankylosis of the affected joint. Bony ankylosis is seen occasionally but is more frequently observed with septic arthritis. The main differential diagnoses of tuberculous arthritis include erosive arthropathies (rheumatoid arthritis and gout), and other monoarticular processes (pigmented villonodular synovitis and osteochondromatosis).



Figs 4.6A to D A 57 years old male presented with history of right shoulder discharging sinus since 5 months. No history of fever. MR shows loss of normal joint space with destruction of the articular surface involving the humerus and glenoid of right shoulder and moderate joint effusion with sinus tract extending anteriorly up to the skin surface. Atrophy of the rotator cuff muscles is seen, predominantly of the supraspinatus muscles. The effusion appears hyperintense on T2 and STIR (A to C) and hypointense on T1WI (D)

Congenital Syphilis

In utero syphilis infection results in transmission from maternal infection of spirochete *Treponema pallidum*. The pathogen is capable of crossing the placenta any time during gestation. The following tests can be assessed on maternal blood:

- Fluorescent treponemal antibody absorbed test (FTA-ABS)
- Rapid plasma reagin (RPR)
- Venereal disease research laboratory test (VDRL)

Antenatal sonographic features are nonspecific and mimic those of the generalized in utero infection, like fetal hepatosplenomegaly placentomegaly, ascites. In severe cases there may be evidence of fetal hydrops or bowing of fetal long bones.

Skeletal lesions early in disease are osteochondritis, osteomyelitis which is diaphyseal, periostitis which occurs early in the course of disease.

Osteochondritis occurs at metaphysis in which widens the zone of provisional calcification until there is epiphyseal separation. X-ray shows, lucent metaphyseal bands which heal after six months of age. Osteomyelitis can also be seen in skull with geographic areas of destruction. Saber tibia results from growth stimulation of the tibia with forward bowing. Dactylitis, especially of proximal phalanx of index finger can be seen. Other changes seen are saddle nose, notched and narrowed incisors-Hutchinson's teeth, periosteal reaction and new bone formation more commonly seen in proximal 2/3 of tibia shaft common late manifestation.

Differential diagnosis includes birth trauma, rickets, severe malnutrition treatment is with penicillin. Fetal demise or still birth can occur in untreated cases. Fetal developing hydrops tend to have poor prognosis.

Infectious Arthritis

Infectious arthritis is classified as pyogenic (septic) or nonpyogenic. Pyogenic septic arthritis is most frequently caused by *Staphylococcus aureus*, may be caused multiple other organisms, including staphylococci, *Streptococcus pneumoniae*, group B streptococci, *Gonococcus* species, *Escherichia coli*, *Haemophilus* species, *Klebsiella* species, *Pseudomonas* species, and *Candida* species. Infection can lead to rapid and severe joint destruction.

Nonpyogenic infective arthritis tends to be less aggressive and have a more chronic course. Causative organisms include *Mycobacterium tuberculosis*, fungi, and spirochetes.

In septic arthritis the most common route of transmission is hematogenous from a distant source

JAYPEE BROTHERS

such as pneumonia or a remote wound infection. Direct seeding from can occur through trauma, surgery, or spread from a contiguous infection such as osteomyelitis or cellulitis.

Imaging is not the primary means of diagnosing septic arthritis. Joint fluid aspiration and evaluation is the key to the diagnosis, and samples should be obtained in all suspected cases of septic arthritis. This sampling can usually be achieved with fine-needle aspiration performed either blindly or with fluoroscopic guidance, depending on the location. Surgical exploration may be necessary in unusual cases, such as those involving sacroiliac and sternoclavicular joint infections.

Fluid should be sent for Gram staining, culturing, glucose testing, and leukocyte count and differential determination. White blood cell counts are usually 50,000–60,000/μL, with more than 80% neutrophils. Synovial fluid glucose levels are decreased. Gram-stain results are positive in 75% of patients with gram-positive cocci. Gram staining is less sensitive in cases of gonococcal infection. Only 25% of cultures of gonococcal synovial fluid are positive.

Multiple imaging modalities are available for assessing septic arthritis. Plain radiography should be used as the initial study. However, if further imaging is required, MRI is the most sensitive and specific technique. Scintigraphy, computed tomography (CT), fluorodeoxyglucose (FDG)/positron emission tomography (PET), and ultrasonography are also used, to a lesser extent.

Plain radiographs are not sensitive to early findings, such as joint effusion or soft tissue changes.

MRI is expensive and time consuming. It shows marrow edema in subchondral regions with synovial thickening **(Figs 4.7A to D)**. It is usually unnecessary if clinical suspicion is high and if the joint is easily accessible for aspiration. CT is similar to MRI, but it has the disadvantage of ionizing radiation. However, it can be useful for guiding the aspiration of certain joints. Scintigraphy is extremely sensitive but extremely nonspecific.

Ultrasonographic findings can confirm a joint effusion, but it cannot be used to assess its cause. It cannot accurately depict bony or cartilaginous abnormalities. This modality also may be useful to guide joint aspiration, and it is generally less expensive than either CT or MRI.

Sacroiliitis

Sacroiliitis is inflammation of the sacroiliac joint. The true prevalence of sacroiliac joint lesions is unknown in most population groups, either with or without low backache. Similarly, the presence of sacroiliitis on MRI has not been determined in low backache cases attributable to either mechanical or inflammatory or both these broad etiological groups. Low back pain is a common referral in routine MRI practice. Clearly, it is one of the most common symptoms evaluated and treated by practitioners. It has been observed that in any 12-month period in USA, 15–20% of the population has an episode of lumbosacral pain with back symptoms occurring in 50% of working age adults yearly. Low back pain is associated with a wide range of clinical disorders. The most common group is mechanical disorders, which occurs in more than 90% of all episodes of back pain. 10% of the remaining patients with back pain have symptoms related to systemic illness, like cancer, inflammatory back disease or infection.

Characteristic radiographic features include joint space narrowing, sclerosis, and erosions of the ilium and sacrum. Sacroiliitis is the hallmark of ankylosing spondylitis. The inflammation is evident early in the

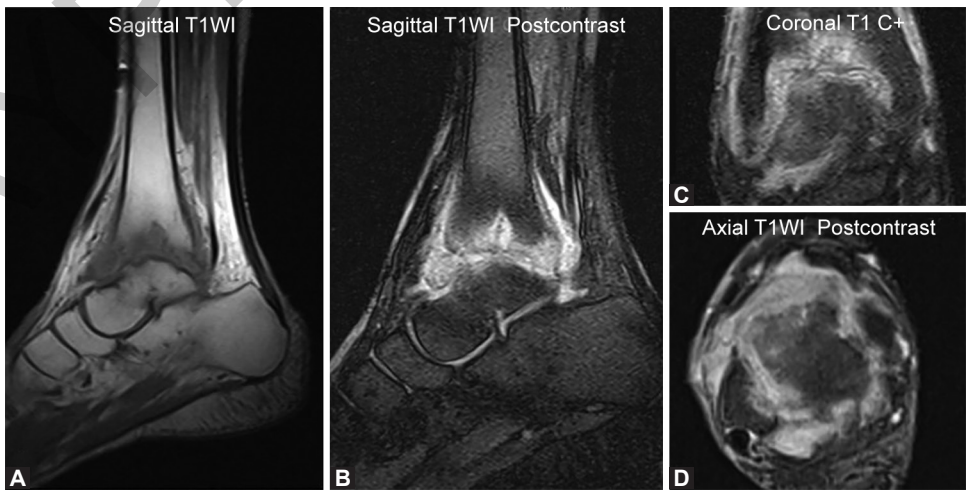

Figs 4.7A to D MR of right ankle in a 21-year-old female with history of fever and pain in ankle on T1WI sagittal image show marrow edema in subchondral regions (A). Sagittal, coronal and axial T1WI postcontrast images show synovial thickening and enhancement (B to D)

JAYPEE BROTHERS

course of the disease. In later stages, the radiographic changes are almost invariably bilateral and symmetric. The alterations occur in both the synovial and the ligamentous (superior and posterior) portions of the joint and predominate in the ilium. Periarticular osteoporosis and loss of definition, superficial erosion, and focal sclerosis of subchondral bone are present initially. Sacroiliitis is evaluated by using CT to look for presence of subchondral sclerosis, osteophytosis, or cartilage loss. Sacroiliac joint is a unique joint in the human body with differences in type and thickness of articular cartilage between different regions of the sacral and iliac articular surfaces.

MRI of normal sacroiliac joint reveals an intermediate signal of the cartilage of the synovial compartment on T1 and T2 images limited by the signal void. MRI may have a role in the early diagnosis of sacroiliitis. Advantages of MRI include direct visualization of cartilage abnormalities, detection of bone marrow edema, improved detection of erosions, and the absence of ionizing radiation **(Figs 4.8A to D)**. Detection of synovial enhancement on MRI has been found to correlate with disease activity, as measured by laboratory inflammatory markers.

The marrow on T1, T2 and T1FS images has a homogeneous intermediate signal. Fat suppressed images are extremely useful in imaging of cases with sacroiliitis. Fat suppression causes rescaling of signal intensities, categorizes cartilage as the brightest structure. This additive effect along with the darkened appearance of fat in adjacent soft tissues and sacral, iliac and lumbar marrow renders improved visualization of structures and increases the conspicuity of lesion, thereby improving their pickup rate. There are two fat suppressed sequences that are available: T1-weighted with fat suppression (T1FS) and fast short tau inversion recovery (Fast STIR) sequences. These are superior to T1 and T2 images, in demonstrating the changes of sacroiliitis.

There are few normal variants, which merits consideration during MRI evaluation of sacroiliac joint. Partial volume artifact between the synovial and ligamentous compartments can be misinterpreted as erosions. There is normally a region of high signal at the immediate subchondral marrow, on Fast STIR images, which can be mistaken for early sacroiliitis. A patchy distribution of fat within the bone marrow as the sole finding should not be considered as an indicator for sacroiliitis.

The value of MRI in the diagnosis of sacroiliitis has been well established. MRI accurately delineates the cardinal features of sacroiliitis, such as changes in joint space width and symmetry, presence of erosions, subchondral edema, sclerosis, cysts and ankylosis. Furthermore, MRI plays a useful role in patients with early disease, by its superior ability to directly image changes in articular cartilage. Comparative studies between MRI and CT in the evaluation of patients with suspected sacroiliitis have further shown that the sensitivity and specificity of MR for the detection of cortical erosions and subchondral sclerosis when compared to CT images were 100 and 94.3%, respectively.

MRI offers valuable information on the lesions affecting the various structures of the sacroiliac joint

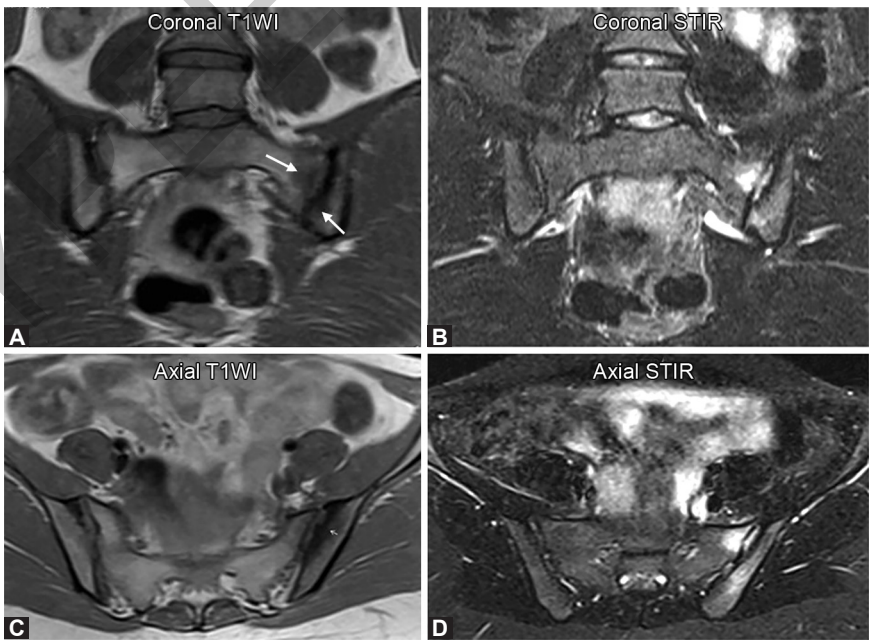

Figs 4.8A to D A 19 years female with history of low back ache since 6 months shows abnormal hypointense signal on coronal and axial T1WI (A and C) involving the articular surface of the left sacroiliac joint. Coronal and axial STIR images (B and D) show hyperintense signal involving the articular surface of the left sacroiliac joint. These imaging findings are suggestive of left sacroiliitis

JAYPEE BROTHERS

in sacroiliitis. Synovial pannus tissue appears low signal intensity on T1 and high signal on T2 **(Figs 4.8A to D)**, spared cartilage exhibits persisting low-signal foci within synovial compartment, bone erosions shows high signal regions at the bone periphery and subchondral bone sclerosis displays markedly hypointense subchondral bone and infectious sacroiliitis shows diffuse high signal intensity in the bone marrow.

Seronegative and HLA B27-associated spondyloarthropathy (SpA) is a heterogeneous group of related inflammatory joint disease that share typical clinical features and a unique association with the major histocompatibility complex class I molecule HLA-B27. It comprises of five clinically defined subcategories: ankylosing spondylitis (AS), psoriatic arthritis (PsA), reactive arthritis (ReA), inflammatory bowel disease-associated arthritis and undifferentiated spondyloarthropathy (uSpA).

The value of using a 'fat suppressed' coronal sequence of the sacroiliac joint, is that it identifies sacroiliitis reliably by the presence of subchondral edema, erosions and sclerosis even when there is no joint space narrowing. Once sacroiliitis is identified on MRI, the patient is evaluated clinically, assessed for human leukocyte antigen (HLA) status, erythrocyte sedimentation rate (ESR) and C-reaction protein (CRP) for activity and subject to a periodic follow-up, wherein intravenous gadolinium is used to characterize the disease activity.

In the final analysis, the use of a 'fat suppressed' coronal sequence during the evaluation of the lumbar spine is a simple and convenient screening strategy. It reliably identifies sacroiliitis, which is a demonstrable cause of low backache, but often neglected or missed.

Cellulitis is an acute infection of the dermis and subcutaneous tissues manifesting as pain, erythema, edema, and warmth. CT scan images are used to accurately differentiate between superficial cellulitis and cellulitis associated with a deep-seated infection. In uncomplicated cellulitis, CT demonstrates skin thickening, septation of the subcutaneous fat, and thickening of the underlying superficial fascia a radiopaque foreign body associated with cellulitis may also be detected by CT scan. If the infection spreads to deeper tissues, deep cellulitis, myositis, necrotizing fasciitis, or osteomyelitis can occur, all of which can be excluded with CT. Complications like soft-tissue abscess and thrombophlebitis may also be seen on CT mages.

Necrotizing fasciitis is a progressive, rapidly spreading infection of the deep fascia, with secondary necrosis of the subcutaneous tissues, more common in immunocompromised patients with HIV infection, diabetes mellitus, cancer, alcoholism, vascular insufficiencies, and organ transplants. On CT images one can see the presence of gas in the subcutaneous tissues caused by gas-forming anaerobic organisms, thickening of the affected fascia, fluid collections along the deep fascial sheaths, and extension of edema into the inter-muscular septa and the muscles without any enhancement of the fascia, thus distinguishing non-necrotizing fasciitis from necrotizing fasciitis.

*Soft-tissue abscess is common in immuno-*compromised patients. CT shows a well-demarcated fluid collection with peripheral pseudo-capsule showing rim enhancement thus differentiating an abscess from simple cellulitis or fasciitis.

Infectious myositis is infection of skeletal muscle, seen most commonly in quadriceps muscle. On CT, there is enlargement and decreased attenuation of the affected muscle with effacement of surrounding fat planes. Involvement of a muscle group that is disproportionate to the involvement of subcutaneous tissue helps distinguish myositis from primary cellulitis. Intramuscular fluid collections may be observed, and contrast material is administered to help differentiate necrotic from viable musculature and to demonstrate a rim-enhancing abscess if present. CT guided aspiration and drainage of the muscle abscess followed by administration of appropriate antibiotics is also possible.

JAYPEE BROTHERS

for detailed information on radiology books, visit our website **www.jaypeebrothers.com,** for detailed information on radiology boo

Textbook of

RADIOLOGY

Musculoskeletal Radiology

Salient Features

- As today's radiology occupies an important place in concluding the diagnosis, it will be a great advantage for postgraduate students to undertake the examination not only in radiology but also for other clinical subjects
- Provides the most imaging solutions on musculoskeletal system routinely required at any imaging establishment
- Structured in such a way that the student is adequately prepared to undertake the postgraduate examination
- Includes a large number of images to give a better grasp over the musculoskeletal system
- Covers the most questions asked or likely to be asked during the examination
- Useful for all residents and general practitioners as well as for medical colleges, institutional and departmental libraries.

Hariqbal Singh is Professor and Head, Department of Radiology, Shrimati Kashibai Navale Medical College and General Hospital, Pune, Maharashtra, India. He has technical expertise as radiologist in managing personnel and resources. He is an effective administrator, communicator and team leader. He has been a postgraduate teacher, examiner and guide. He has a large number of publications in countrywide and global medical journals. He has authored a number of books on radiology.



Shrikant Nagare is Consultant, Department of Radiology, Shrimati Kashibai Navale Medical College and General Hospital, Pune, Maharashtra, India. He is a keen radiologist and zealous observer.



Available at all medical bookstores
or buy online at www.jaypeebrothers.com

JAYPEE BROTHERS
Medical Publishers (P) Ltd.
www.jaypeebrothers.com

Join us on facebook.com/JaypeeMedicalPublishers

Shelving Recommendation
RADIOLOGY

ISBN -978-93-86056-73-3