rmatology books, visit our website **www.jaypeebrothers.com,** for detailed information on dermatology books

5th Edition

DIAGNOSIS AND TREATMENT OF COMMON SKIN DISEASES

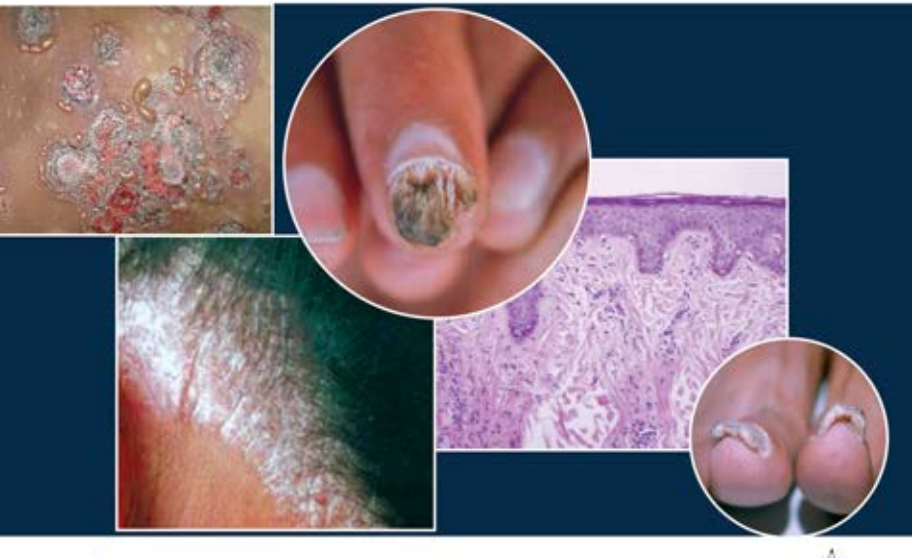

Virendra N Sehgal

JAYPEE

Contents

1. Systemic Drugs Commonly Used in Dermatologic Practice **1**

Acyclovir *2*
Albendazole *2*
Allopurinol *2*
Amphotericin–B *3*
Amylobarbitone *3*
Antacids *4*
Antihistaminics *4*
Astemizole *5*
Azathioprine *8*
Azidothymidine *8*
Beta Carotene *8*
Bleomycin *9*
Chloroquine *9*
Carbamazepine *10*
Chlordiazepoxide *10*
Cetirizine *10*
Chloramphenicol *11*
Clemastine Fumerate *11*
Cephalexin *12*
Collagen Implant *12*
Colchicine *13*
Clofazimine *13*
Cyanocobalamin *14*
Cyclophosphamide *14*
Corticosteroids *14*
Cycloserine *16*

Diamino-Diphenyl Sulphone *17*
Diazepam *17*
Doxycycline *17*
Erythromycin *18*
Ethambutol *18*
Etretinate *19*
Fluconazole *19*
Ethionamide/Prothionamide *19*
5-Fluorouracil *20*
Indomethacin *20*
Interferons *21*
Grisofulvin *21*
Gold Salts *21*
Isotretinon *22*
Isoniazid *22*
Itraconazole *23*
Ketoconazole *23*
Para-Aminosalicylic Acid and Salts *24*
Methotrexate *24*
Levamisole *25*
Metronidazole *25*
Minocycline *(Cynomycin)* *26*
Penicillins *26*
Penicillamine *28*
Paracetamol *28*
Para-Aminobenzoic Acid *29*
Pentoxifylline *29*
Oxyphenylbutazone/Phenylbutazone *29*
Nifedepine *30*
Potassium Iodide *30*
Prednisolone *31*
Propantheline *31*
Psoralens *32*
Pyrazinamide *33*
Pyridoxine *33*
Rifampicin *34*
Ranitidine *34*
Streptomycin *35*

Spectinomycin *35*
Terbinafine *36*
Tetracycline *36*
Thalidomide *36*
Thiabendazole *37*
Thiacetazone *37*
Tinidazole *38*
Trimethoprim + Sulphadiazine *38*
Trimethoprim + Sulphamethoxazole *38*
Xanthinol Micotriate *39*
Vitamin-A *39*
Zidovudine *40*
Zinc Sulphate *40*
Vitamin-E *40*
Recommended Reading *41*

2. Topical Therapy Used in Dermatological Practice 43
Wet Dressings *44*
Lotions *44*
Medicated Baths *45*
Acyclovir *46*
Aluminium Acetate Solution *47*
Ammoniated Mercury *47*
Benzoyl Peroxide *48*
Boric Acid Ointment *48*
Calcipotriol *48*
Cantharidin *48*
Ciclopirox Olamine *49*
Clotrimazole *49*
Colchicine *49*
Corticosteroids *50*
Crotamiton *50*
Cryotherapy *50*
2,4-Dinitrochlorobenzene (DNCB) *52*
Erythromycin *53*
Fluorouracil *53*
Gamma Benzene Hexachloride *53*

Gentian Violet *54*
Glutaraldehyde *54*
Hydroquinone *54*
Iodochlorohydroxyquin *55*
Liquid Nitrogen *55*
Local Anesthetics *55*
Miconazole Nitrate *56*
Monobenzone *56*
Mupirocin *56*
Nystatin (Mycostatin) *57*
Placental Extract Lotion *57*
Povidone Iodine *57*
Psoralen + Ultraviolet–A (PUVA) Therapy *57*
Quinodochlor *58*
Salicylic Acid *59*
Sisomicin *59*
Silver Nitrate Solution *59*
Silver Sulphadiazine *60*
Selenium Sulphide *60*
Sodium Fusidate *60*
Sulphur *61*
Sunscreens *61*
Paba And Paba Esters *61*
Tar Derivative Shampoos *62*
Terbinafine *63*
Tertracycline *63*
Tolnaftate *63*
Tretinoin *63*
Triamcinolone *64*
Trichloroacetic Acid *64*
Urea *65*
Vitamin A and D *65*
Vitamin E *65*

3. Drugs that may Cause Specific Side Effects 67
Drugs Causing Acneiform and Pustular Eruptions *68*
Drugs Causing Alopecia *68*
Drugs Causing Eczema (Eczematous)/Dermatitis *69*

Drugs Causing Erythema Multiforme *69*
Drugs Causing Erythema Nodosum *70*
Drugs Causing Scarlatiniform and Morbilliform (Exanthematic) Eruption *70*
Drugs Causing Exfoliative Dermatitis *70*
Drugs Causing Fixed Drug Eruptions *71*
Drugs Causing Gynaecomastia *71*
Drugs Causing Hair Color Change *71*
Drugs Causing Hirsutism *72*
Drugs Causing Hypertrichosis (Excessive Hair) *72*
Drugs Causing Leucocytoclastic Angiitis *72*
Drugs Causing Lichenoid Eruptions *73*
Drugs Causing Lupus Erythematosus-like Lesions *73*
Drugs Causing Lymphadenopathy *73*
Drugs Causing Nail Discolorations *74*
Drugs Causing Pemphigus-like Lesions *74*
Drugs Causing Photosensitivity *74*
Drugs Causing Purpuric Eruptions *75*
Drugs Causing Toxic Epidermal Necrolysis *75*
Drugs Causing Urticaria *75*
Drugs Causing Vesicobullous Lesions *76*

4. Instant Diagnostic Criteria and Treatment of Common Skin Disorders 79
Acne Vulgaris *80*
Alopecia Areata *85*
Atopic Dermatitis *88*
Bullous Pemphigoid *93*
Dermatitis Herpetiformis *95*
Chronic Benign Familial Pemphigus (Hailey-Hailey Disease) *98*
Erythrasma *99*
Folliculitis *101*
Hidradenitis Suppurativa *104*
Keloids and Hypertrophic Scars *106*
Infectious Eczematoid Dermatitis *109*
Impetigo *111*
Miliaria/Sweat Rash *114*

Leprosy *116*
Leprosy Reactions *122*
Hyperhidrosis *124*
Chickenpox *125*
Herpes Zoster *127*
Candidiasis *131*
Lichen Planus/Lichenoid Interface Dermatosis *137*
Pityriasis Rosea *143*
Lichen Sclerosus Et Atrophicus *146*
Melasma/Chloasma *148*
Molluscum Contagiosum *154*
Pediculosis Capitis *156*
Pediculosis Corporis and Pubis *157*
Pemphigus *159*
Pitted Keratolysis *164*
Pityriasis Versicolor *166*
Psoriasis *169*
Recurrent Aphthous Ulcerations *180*
Rosacea *182*
Scabies *187*
Seborrheic Dermatitis *191*
Sexually Transmitted Infections Syphilis *193*
Chancroid *197*
Gonorrhea *201*
Nongonococcal Urethritis *204*
Herpes Simplex/Herpes Progenitalis *206*
Donovanosis *209*
Lymphogranuloma Venereum *214*
Dermatophytosis/Dermatomycosis *217*
Urticaria *227*
Vitiligo *231*
Verrucae Vulgaris/Common Warts *239*
Cutaneous Tuberculosis *244*
Lichen Simplex Chronicus/Prurigo Nodularis *255*
Chilblains *259*
Twenty Nail Dystrophy/TND *262*
Sarcoidosis *264*
Associated Syndromes *266*

Seborrheic Keratosis/Verruca/Senile Wart *268*
Pseudoacanthosis Nigricans/Type 3 Acanthosis *269*
Pigmented Nevus/Mole/Melanocytic Nevus/ and Nevus Pigmentation *272*

5. Drugs Formulary of Dermatological Preparations **277**
Topical Agents *278*
Systemic Agents *290*
Shampoos *298*
Face Wash *301*

6. Biologics: Therapeutic Applications **303**

7. Emergency Dermatology: Erythroderma **311**
Erythroderma *312*
Pityriasis Rubra Pilaris *312*
Airborne Contact Dermatitis/ABCD *318*
Atopic Dermatitis *320*
Toxic Epidermal Necrolysis *322*
Psoriasis *323*
Pemphigus Foliaceus *326*

8. Emergency Dermatology: Angioedema **329**
Management *334*

Index *337*

CHAPTER 4

Instant Diagnostic Criteria and Treatment of Common Skin Disorders

JAYPEE BROTHERS

ACNE VULGARIS

Acne vulgaris (or simply acne) is a long term skin condition characterized by areas of blackheads, whiteheads, pimples, greasy skin, and possibly scarring.

Instant Diagnostic Criteria

It is an androgen-dependent anomaly of adolescence of both men and women. Open and/or closed comedon is its diagnostic hallmark. The former has widely dilated pilosebaceous orifices filled with lipid, keratin and microorganisms, popularly acclaimed 'black head' **(Figs 4.1 to 4.4)**. It may easily be squeezed with the help of comedon extractor. Its course may be punctuated by the appearance of papules, pustules, nodules, cysts, keloid and acne scars **(Figs 4.5 and 4.6)**. The lesions are usually located on seborrheic sites, comprising forehead, cheeks, nasolabial folds, nose, chin, top of the shoulders, front and back of the chest **(Figs 4.7 and 4.8)**. Invariably it is associated with seborrhea capitis. Occasionally, seborrheic dermatitis may be its accompaniment. It is, therefore, essential to demarcate its morphological features into:

- Closed comedon
- Open comedon
- Papular/pustular
- Nodular/cystic
- Keloid/scar

Topical Therapy

It is an important ingredient and includes degreasing of the seborrheic sites. This is achieved by washing of the skin with soap (Acnelak) containing Irgasan DP300 and water. The skin after this procedure is ready for use of variety of acclaimed topical preparations.

- Tretinoin 0.025–0.05% (A-ret gel, Adit, Eudyna, Retino-A) cream should be applied once a day before retiring to the bed,

JAYPEE BROTHERS



Fig. 4.1



Fig. 4.2



Fig. 4.3

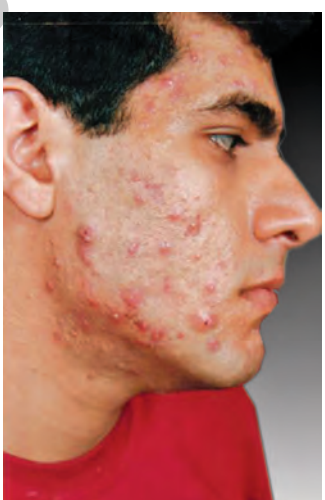

Fig. 4.4

Figs 4.1 to 4.4: Acne vulgaris: 'Black head'

JAYPEE BROTHERS



Fig. 4.5



Fig. 4.6

Figs 4.5 and 4.6: Acne vulgaris: Pustules, nodules, cysts, keloid and acne scars

JAYPEE BROTHERS



Fig. 4.7



Fig. 4.8

Figs 4.7 and 4.8: Acne vulgaris: On the shoulders, front and back of the chest

JAYPEE BROTHERS

to the area of skin where acne lesions occur. Only a sufficient quantity of medication should be applied to cover the affected areas lightly, using gauze swab/the clean fingertips.

- Apply erythromycin 4% w/w (Eromed, Eryacne) gel base.
- Erythromycin 4% w/w (Eromed, Eryacne) gel base, apply a thin film all over the affected area including shoulders and back once or 2 times a day.
- Clindamycin phosphate 1% (Aclin, Clin, Clindac) gel base, apply all over the affected area once or 2 times a day.
- Benzoyl peroxide 2.5–5% (Benzac-AC, Pernox) gel base, apply once or 2 times a day over the affected areas.
- Erythromycin 4% and benzoyl peroxide 5% (Acnebenz gel) gel base.

Table 4.1: Acne vulgaris: Treatment schedule

Generic name	*Trade name*	*Dosages*	*Duration*	*Remarks*
Erythromycin I.P. 333 mg	Eromed–333	3 tablets a day	2–3 weeks	
Roxithromycin 150 mg	Biorox, Roxmed–150	1 tablet 2 times a day	2–3 weeks	Safe
Azithromycin 250 mg	Azithral, Azibact, Aziwak	2 tablets first day, 1 tablet a day	2 weeks	Safe
Minocycline hydrochloride 50 mg	Cynomycin–50, Cynomycin–100	1 capsule 2 times a day	3–4 weeks	
Doxycycline hyclate 100 mg	Biodoxi, Doxi–1	1 tablet 2 times a day	Up to 4 weeks	
Isotretinoin*	Iso-e-ret, isotroin	Start at 0.5 mg/kg and increase gradually up to 1 mg/kg/day	4–5 months	Cystic acne, Acne rosacea and acne fulminas
Prednisolone + Isotretinoin		0.5–1 mg/kg/day + 1 mg/kg/day	2 weeks followed by usual dose.	Acne fulminans

** It should be used only after explaining the effect and/or untoward effect to the patients and prerequisite (lipid profile, pregnancy test) should be fulfilled.*

JAYPEE BROTHERS

- Adapalene 0.1% (Alangel, Adaferin) gel w/w, apply gently over the affected part before retiring to bed.

Facial acne scars may be treated with Contractubex. For details, refer to topical therapy of hypertrophic scars and keloids.

Systemic Therapy

Erythromycin and tetracycline are frequently used to control acne along with vitamin A, zinc, antioxidants (rejubinating factor) and retinoids. Their dosages schedule is shown in **Table 4.1**.

Surgical Management

- Acne ice-pick scars—dermabrasion.
- Hypertrophic scars—excision and suture.
- Keloid formation—excision with a margin of healthy skin, followed by skin grafting.

Recommended Reading

1. Benner N, Sammons D (September 2013). "Overview of the treatment of acne vulgaris". Osteopathic Family Physician 5 (5): 185–90. (doi:10.1016/j.osfp.2013.03.003.)
2. McWilliam J. Acne vulgaris: clinical features, assessment and treatment. Nurs Stand. 2009;23(34):49-56; quiz 58.
3. Sardana K, Garg VK, Sehgal VN. Efficacy of fixed low-dose isotretinoin (20 mg, alternate days) with topical clindamycin gel in moderately severe acne vulgaris J Eur Acad Dermatol Venereol. 2009;23(5):556-60. doi: 10.1111/j.1468-3083.2008.03022.x. Epub2009Jan9.
4. Sardana K1, Sehgal VN. Retinoids: fascinating up-and-coming scenario. J Dermatol. 2003;30(5):355-80.
5. Sehgal VN, Jain S. Acne and acneiform dermatoses. See comment in PubMed Commons below. J Indian Med Assoc. 1991;89(3):80-1.

ALOPECIA AREATA

Alopecia areata (AA) is an autoimmune disease in which hair is lost from some or all areas of the body, usually from the scalp due to the body's failure to recognize "self" and destroys its own tissue as if it were an invader.

JAYPEE BROTHERS

Instant Diagnostic Criteria

It is an autoimmune disease. Environmental factors contribute in good measure to start the episode. It is recognized by the presence of round and/or oval loss of hair confined primarily to the hairy part of the skin. Largely, it is asymptomatic. At times, itching at the site may be prominent. The lesions are usually skin colour, presence of melanin on the lesions make them prominent. Illustration of exclamation mark and hair pull test are their essential components for diagnosis. Reticular pattern of hair loss is an important prelude to the ultimate immergence of either alopecia totalis and/or universalis. Scalp and beard are the usual site of affliction, in addition to the other hairy part of the skin. It is easy to conceive its morphology should its diversification be recognized and demarcated. It is, therefore, imperative to comprehend its clinical variants.

- Alopecia areata classic **(Fig. 4.9)**
- Alopecia reticular **(Fig. 4.10)**
- Alopecia totalis **(Fig. 4.11)**
- Alopecia universalis **(Fig. 4.12)**

Diagnostic clinch may be possible to achieve by preparing hematoxylin-eosin stained section, where cell's character may decide it as an autoimmune disease or otherwise.

Management

Topical Therapy

In the first instance, it is incumbent to degrease the scalp by the application of shampoos. Cetrimide 20% (Cetrimide-conc, cetrilak) shampoo should be attempted to thoroughly wash the hair. This should immediately be followed by ketoconazole 2% w/w (Nizral) shampoo. The suds thus formed should be retained on the hair including alopecia areata for 5 minutes period. The scalp is rinsed and dried by the hair drier. It is now ready to receive an application of Minoxidil 2–5% (Mintop, Rootz-M5) 0.5–1 mL is adequate and should be applied 2 times a day for 4 to 6 months period.

JAYPEE BROTHERS

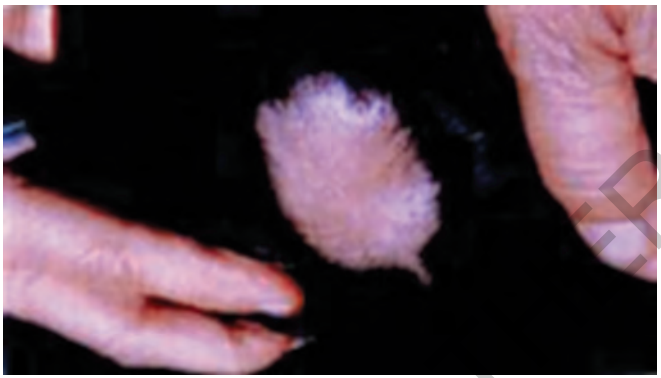

Fig. 4.9: Alopecia areata: Classic

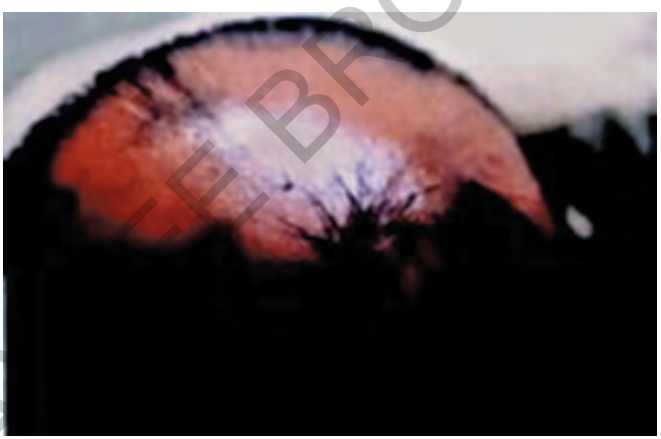

Fig. 4.10: Alopecia reticular

Systemic Therapy

Should its aetiology is established as autoimmune, prednisolone (Wysolone) in the dosages of 20–30 mg may be given for a requisite period. Levamisole (Dicaris, Vermisole) 50 mg for children and 150 mg for adults may be given as a pulse therapy for 2 consecutive days every week.

JAYPEE BROTHERS



Fig. 4.11: Alopecia totalis



Fig. 4.12: Alopecia universalis

JAYPEE BROTHERS

Recommended Reading

1. Hordinsky MK. Overview of alopecia areata.J Investig Dermatol Symp Proc. 2013;16(1):S13-5. doi: 10.1038/jidsymp.2013.4.
2. Rokhsar CK, Shupack JL, Vafai JJ, Washenik K. Efficacy of topical sensitizers in the treatment of alopecia areata. J Am Acad Dermatol. 1998;39(5 Pt 1):751-61. [Medline].
3. Sehgal VN, Jain S. Alopecia areata: clinical perspective and an insight into pathogenesis. J Dermatol. 2003;30(4):271-89.
4. Sutherland L, Laschinger M, Syed ZU, Gaspari A. Treatment of alopecia areata with topical sensitizers. Dermatitis. 2015;26(1): 26-31. doi: 10.1097/DER.0000000000000094. PMID: 25581667

ATOPIC DERMATITIS

Atopic dermatitis (AD)/atopic eczema an eczema is a type of dermatitis, an inflammatory, relapsing, non-contagious and itchy skin disorder. It is often chronic in nature. In children under one year of age much of the body may be affected. As they

get older the back of the knees, the *popliteal fossa* and front of the elbows, the *antecubital* fossa are the most common area for the rash. In adults the hands and feet are most affected.

Instant Diagnostic Criteria

It is a pruritic, eczematous dermatosis, the symptoms of which chronically fluctuate with remissions and relapses. Most individuals with atopic dermatitis have atopic diathesis. The characteristics of the later envisage personal/family history of asthma, allergic rhinitis and/or conjunctivitis, and atopic dermatitis and/or predisposition to overproduction of immunoglobulin E (IgE) antibodies. Pruritus is its cardinal symptom whereas its morphology is fairly helpful and is formed by acute lesions, such as erythema, exudation, papules, vesiculopapules, scales and crusts **(Figs 4.13 to 4.16)**. Infiltrated erythema, lichenification, prurigo, scales and crusts, however, identify chronic lesions. Its sites of predilections are forehead, periorbital area, perioral area, lips, periauricular area, neck, joint areas of limbs and trunk. The lesions are usually symmetrical. Chronic or chronically relapsing course usually has co-existence of old and new lesions, which may be more than 2 months in infancy and more than 6 months in childhood, adolescence and adulthood. Definitive diagnosis of atopic dermatitis requires the presence of all three features without any consideration of severity (*vide infra*). In addition, family history of bronchial asthma, allergic rhinitis and/or conjunctivitis, atopic dermatitis, complications such as bronchial asthma, allergic rhinitis and/or conjunctivitis, follicular papules (goose-skin) and elevated serum IgE level. Occasionally, ocular complications comprising cataracts and/or retinal detachment, especially in patients with severe facial lesions, Kaposi's varicelliform eruption, molluscum contagiosum **(***see* **Fig. 4.69)** and impetigo contagiosa may also be encountered. Other cases should be evaluated on the basis of the clinical course with the tentative diagnosis of acute or chronic, nonspecific eczema. Its clinical manifestations vary according to the age, namely:

JAYPEE BROTHERS



Fig. 4.13



Fig. 4.14



Fig. 4.15



Fig. 4.16

Figs 4.13 to 4.16: Atopic dermatitis

JAYPEE BROTHERS

for detailed information on dermatology books, visit our website **www.jaypeebrothers.com,** for detailed infor

Diagnosis and Treatment of Common Skin Diseases

The text of the book is unique for it takes cognizance of succinct morphology of skin lesion, which ultimately facilitates to form instant diagnosis of common skin diseases. It is capped by tabulation of generic and brand name of the drugs options in vogue for treatment of skin diseases. Besides, it carries drug formulary of dermatological preparations for instant reference.



Virendra N Sehgal One of the foremost medical scientists in the field of Dermatology/ Venereology/Leprosy, is well known for his exquisite research contributions. He has over 553 original research publications published in leading peer-reviewed national and international journals with high-citation index and impact factor. He has established a school in the field of cutaneous tuberculosis, histoid leprosy, reaction in leprosy, leprosy in children, and classification of leprosy. He has authored several books which are used at graduate and postgraduate levels. Deservingly, he was honored with the Ambadyrs, Fulfords and Glaxo Orations, besides JALMA Trust Fund Oration Award, Indian Council of Medical Research, Dr BC Roy National Fund Award and IMA Dr RK Menda Memorial Oration Award. Professor Dr KC Kandhari Foundation Award was presented to him on 36th National Conference, Indian Association of Dermatologists, Venereologists and Leprologists (IADVL)(2008). He is also a recipient of lifetime achievement award of Indian Association of Leprologists (IAL), 2009. LHMC Alumni Association has Bestowed upon him Lifetime Achievement Award on the auspicious 100 Glorious years (1916-2016) on 20th Dec. 2015 Besides, he was honored and felicitated in recognition of his outstanding contributions towards, Developing Dermatology, Teaching and Research, in the Country on August 1-2,2015 by IADVL-AIIMS Dermatology Resident Doctors & PG Teachers Conference Jointly Organized by Department of Dermatology and Veneorology, AIIMS IADVEL Academy & IADVL Delhi State Branch at JLN Auditorium, AIIMS , New Delhi

His incessant, meritorious and academic contributions have created a place of pride for him in the International literature of the specialty. Currently, he has 553 Research Gate Publications with a Research Gate score of 44.94

He has several books to his credit ever since 1978:

1. Textbook of Sexually Transmitted Disease (Venereal Disease)
2. Textbook of Clinical Leprosy
3. Donovanosis (Granuloma Inguinale)
4. Histoid Leprosy
5. Textbook of Clinical Dermatology
6. Dermatologic Surgery Made Easy

Available at all medical bookstores or buy online at www.jaypeebrothers.com

JAYPEE BROTHERS
Medical Publishers (P) Ltd.
www.jaypeebrothers.com

Join us on facebook.com/JaypeeMedicalPublishers

Shelving Recommendation
DERMATOLOGY

ISBN 978-93-86056-77-1

9 789386 056771