website www.ejaypee.com, for detailed information on cardiology books, visit our website www.ejaypee.com, for detailed information on cardiology books, visit our website www.ejaypee.com,

Complimentary Online Videos

Interesting Cases in Echocardiography



Navin C Nanda

JAYPEE

Interesting Cases in Echocardiography

Editor

Navin C Nanda MD DSc (Hon) DSc (Med) (Honoris Causa) FACC FAHA FISCU (D) FSGC FICA FACA FICP (Hon) FIAE FICMU (Hon) FACIP FCSC (S) FIACS FICC (Hon)

Distinguished Professor of
Medicine and Cardiovascular Disease
University of Alabama at Birmingham
Birmingham, Alabama, USA

President
International Society of Cardiovascular Ultrasound

Editor-in-Chief
Echocardiography: A Journal of Cardiovascular Ultrasound
and Allied Techniques

JAYPEE BROTHERS



The Health Sciences Publisher

New Delhi | London | Panama

Contents

Section 1: Mitral Valve

Case 1 2
Case 2 3
Case 3 4
Case 4 5
Case 5 10
Case 6 13
Case 7 14
Case 8 18
Case 9 19
Case 10 20
Case 11 22
Case 12 24
Case 13 25
Case 14 26
Case 15 28
Case 16 30
Case 17 31

Section 2: Aortic Valve, Aorta

Case 18 34
Case 19 35
Case 20 36
Case 21 38
Case 22 39
Case 23 40
Case 24 41
Case 25 42
Case 26 44
Case 27 45
Case 28 46
Case 29 49
Case 30 50

JAYPEE BROTHERS

Case 31 53
Case 32 54
Case 33 58
Case 34 59
Case 35 60
Case 36 63
Case 37 65

Section 3: Tricuspid and Pulmonary Valves, Pulmonary Hypertension

Case 38 68
Case 39 69
Case 40 71
Case 41 72
Case 42 73
Case 43 76
Case 44 77
Case 45 78
Case 46 79
Case 47 80
Case 48 81
Case 49 82
Case 50 83

Section 4: Prostheses, Rings and Clips

Case 51 86
Case 52 87
Case 53 88
Case 54 89
Case 55 91
Case 56 95
Case 57 97
Case 58 99
Case 59 102
Case 60 106
Case 61 109
Case 62 111
Case 63 112
Case 64 113

JAYPEE BROTHERS

Case 65 116
Case 66 117
Case 67 118
Case 68 119
Case 69 120
Case 70 121
Case 71 124
Case 72 127
Case 73 128
Case 74 130
Case 75 132
Case 76 134
Case 77 136
Case 78 139
Case 79 140

Section 5: Endocarditis

Case 80 146
Case 81 150
Case 82 152
Case 83 154
Case 84 156
Case 85 158
Case 86 160
Case 87 164
Case 88 167
Case 89 169
Case 90 170
Case 91 173

Section 6: Coronary Artery Disease

Case 92 176
Case 93 177
Case 94 178
Case 95 179
Case 96 180
Case 97 181
Case 98 182

JAYPEE BROTHERS

Case 99 184
Case 100 186
Case 101 188
Case 102 192
Case 103 193
Case 104 195
Case 105 199
Case 106 201
Case 107 202
Case 108 204
Case 109 205
Case 110 207
Case 111 208

Section 7: Left Ventricle, Right Ventricle and Cardiomyopathy

Case 112 210
Case 113 212
Case 114 213
Case 115 214
Case 116 215
Case 117 216
Case 118 217
Case 119 218
Case 120 219
Case 121 220
Case 122 221
Case 123 222
Case 124 223
Case 125 224
Case 126 225
Case 127 228
Case 128 230
Case 129 231
Case 130 232
Case 131 233
Case 132 235
Case 133 237
Case 134 239
Case 135 240

JAYPEE BROTHERS

Case 136 241
Case 137 243
Case 138 244
Case 139 245
Case 140 247
Case 141 248
Case 142 255
Case 143 259
Case 144 262
Case 145 263
Case 146 265
Case 147 266
Case 148 269
Case 149 271
Case 150 272
Case 151 273
Case 152 274
Case 153 275

Section 8: Pericardial Disorders

Case 154 278
Case 155 279
Case 156 280
Case 157 281
Case 158 282
Case 159 285
Case 160 286
Case 161 287
Case 162 290
Case 163 293
Case 164 295
Case 165 298
Case 166 299
Case 167 300
Case 168 301
Case 169 302
Case 170 303
Case 171 304

JAYPEE BROTHERS

Section 9: Tumors and Masses

Case 172 306
Case 173 307
Case 174 309
Case 175 311
Case 176 312
Case 177 316
Case 178 318
Case 179 320
Case 180 324
Case 181 326
Case 182 328
Case 183 330
Case 184 332
Case 185 333
Case 186 335
Case 187 339
Case 188 341
Case 189 342
Case 190 343
Case 191 346
Case 192 349
Case 193 352
Case 194 355
Case 195 357
Case 196 359
Case 197 360
Case 198 365
Case 199 367
Case 200 370
Case 201 373
Case 202 377
Case 203 381
Case 204 382
Case 205 383
Case 206 388
Case 207 389
Case 208 391
Case 209 392

JAYPEE BROTHERS

Section 10: Congenital Heart Disease

Case 210 394
Case 211 395
Case 212 398
Case 213 400
Case 214 402
Case 215 404
Case 216 405
Case 217 407
Case 218 410
Case 219 412
Case 220 414
Case 221 416
Case 222 418
Case 223 421
Case 224 424
Case 225 428
Case 226 431
Case 227 432
Case 228 434
Case 229 437
Case 230 439
Case 231 440
Case 232 441
Case 233 443
Case 234 445
Case 235 447
Case 236 450
Case 237 451
Case 238 453
Case 239 456
Case 240 458
Case 241 461
Case 242 465
Case 243 467
Case 244 469
Case 245 470
Case 246 474
Case 247 476

JAYPEE BROTHERS

Section 11: Miscellaneous

Case 248 480
Case 249 482
Case 250 483
Case 251 484
Case 252 485
Case 253 486
Case 254 487
Case 255 488
Case 256 491
Case 257 492
Case 258 493
Case 259 495
Case 260 496
Case 261 497
Case 262 498
Case 263 499
Case 264 500
Case 265 501
Case 266 502
Case 267 503
Case 268 504
Case 269 509
Case 270 510
Case 271 512
Case 272 516
Case 273 517
Case 274 518
Case 275 519
Case 276 520
Case 277 523
Case 278 524
Case 279 525
Case 280 526
Case 281 528
Case 282 531

Index 533

JAYPEE BROTHERS

CASE 32

Inga Vaitenas, Zeina Ibrahim, Kameswari Maganti

A PRESENT FROM NIGERIA

A 72-year-old male with history of hypertension presented to the emergency room with intermittent chest pain for 3–4 weeks. The pain was sharp, substernal, and occurred at rest when he laid down in the right lateral decubitus position. He was otherwise healthy until about 5 months prior to admission when he developed a cough that was persistent. On evaluation in Nigeria, he was found to have a thoracic mass that was determined to be an enlarged aorta. He was deemed not to be a surgical candidate due to lack of ICU facilities in his hometown where he spends part of the year. He came back to his home in USA for further evaluation.

A chest X-ray (Figs. 32.1A and B) revealed a large, lobulated mass in left hemithorax that measured approximately 11.5 cm that was favored to represent the aorta (red bar with arrowheads). This extends from the posterior arch of the thoracic aorta to the midthoracic level with mild rightward deviation of the trachea.

A CT angiogram that was performed demonstrated extensive type B dissection which originates immediately distal to the left subclavian artery and involves the descending thoracic aorta and abdominal aorta extending into the proximal right common iliac artery. The descending thoracic aorta is aneurysmal measuring approximately 10.3 cm × 9.0 cm and shows a large false lumen and a narrow true lumen. In the lower thoracic aortic false lumen there is irregular soft tissue consistent with thrombus. The lower thoracic aorta measures 5.4 × 5.9 cm. At the level of the diaphragmatic aortic hiatus, the aorta measures 9.4 × 7.0 cm with celiac artery originating at this level. The SMA and IMA arise from the true lumen and opacify normally. Both renal arteries arise from the true lumen (Figs. 32.2 to 32.4).

The echocardiogram demonstrated normal left ventricular size and systolic function. The enlarged descending aorta with a dissection flap was once again seen. (Figs. 32.5 and 32.6, 🎥 101 to 103)

The patient underwent resection and replacement of the thoracoabdominal aneurysm with reattachment of celiac artery, superior mesenteric artery and bilateral renal arteries. Five years later, he is doing well without any complaints.

DISCUSSION

Aortic aneurysmal disease is now recognized as a distinct degenerative process involving all layers of the vessel wall. The pathophysiology of aortic aneurysms is characterized by four events: infiltration of the vessel wall by lymphocytes and macrophages; destruction of elastin and collagen in the media and adventitia by proteases, including matrix metalloproteinases; loss of smooth-muscle cells with thinning of the media; and neovascularization.

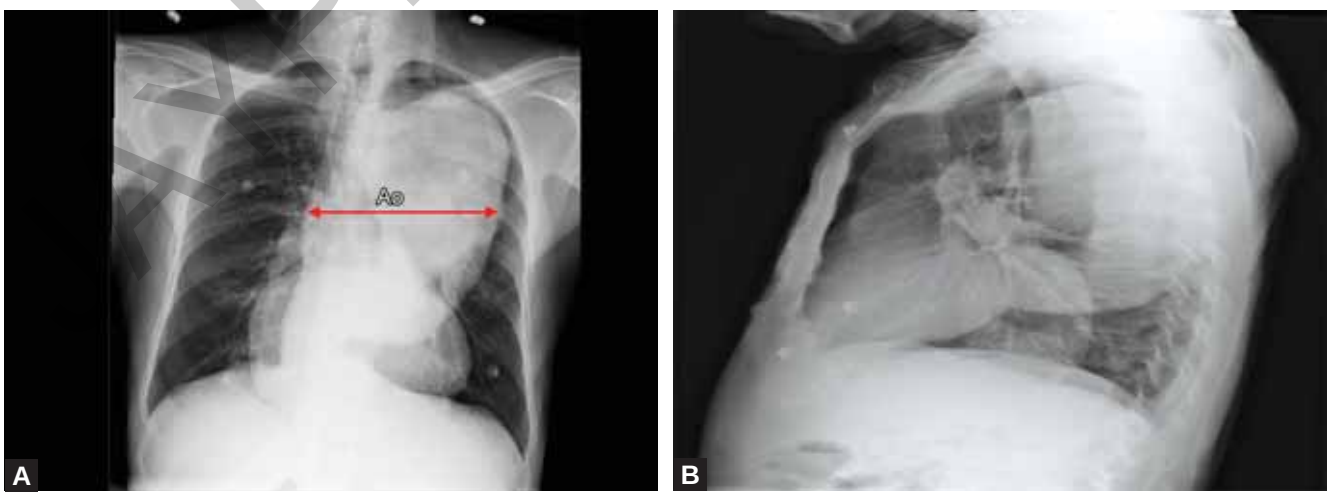

Figs. 32.1A and B: Large soft tissue mass in the left hemithorax as indicated by arrow heads is most indicative of a thoracic aorta aneurysm.

JAYPEE BROTHERS

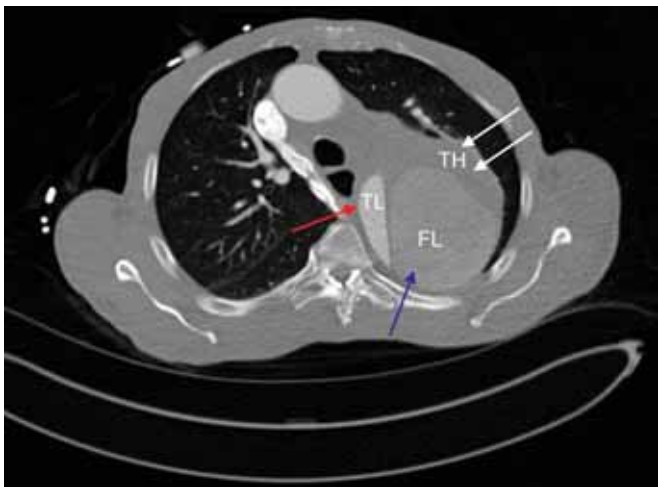

Fig. 32.2: Axial plane of CTA revealing a small true lumen (red arrow), a large false lumen (purple arrow) and a large burden of thrombus (two white arrows).

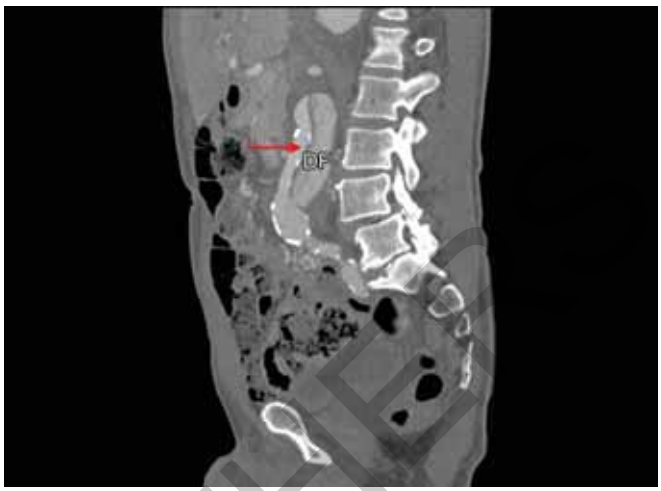

Fig. 32.3: Sagittal plane of CTA demonstrating the extensive dissection flap (red arrow).

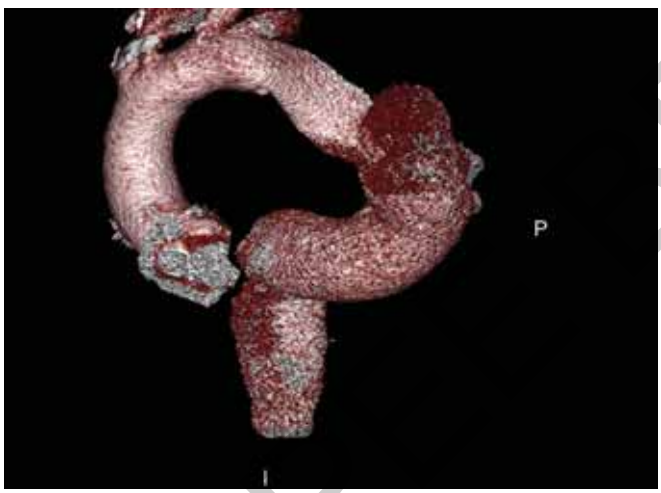

Fig. 32.4: 3D reconstruction of abdominal aorta that reveals aneurysmal aorta which is irregular and tortuous.

Dissection is a distinct process that most often involves the ascending, thoracic, or thoracoabdominal aorta.

The risk factors for abdominal aortic aneurysm[1] include older age, male sex, and a family history of the disorder. The risk of abdominal aortic aneurysm is approximately four times as high among men as among women and four times as high among people with a family history of the disorder as among those without a family history. Smoking, hypertension, hyperlipidemia, obesity, and PAD are other risk factors. Race plays a role as well with abdominal aortic aneurysms more prevalent among whites.[1-4]

Small abdominal aortic aneurysms (3.0 to 5.4 cm in diameter), when identified, should be monitored for expansion. In accordance with Laplace's law, the larger the aneurysm, the higher the rate of expansion. Current guidelines regarding the frequency of monitoring are as follows: for aneurysms with a diameter of 3.0 to 3.4 cm every 3 years; 3.5 to 4.4 cm yearly; and 4.5 to 5.4 cm every 6 months. US Preventive Services Task Force recommendations support screening in men 65 to 75 years of age with a history of smoking and selective screening in men 65 to 75 years of age without a smoking history, although the optimal cohort to be screened remains controversial.

Abdominal aortic aneurysms are usually asymptomatic[1,4] until they rupture, with an ensuing mortality of 85 to 90%. Symptomatic patients require urgent repair. Treatment should always include risk factor modifications.[3] Medical therapy typically includes beta-blockers, ACE-inhibitor, or antibiotics. However, none of the medical therapies have been shown to prevent aneurysm expansion. The usual threshold for elective repair is an aortic diameter of 5.5 cm in men and 5.0 cm in women. Endovascular repair results in lower perioperative morbidity and mortality than open repair, but the two methods are associated with similar mortality in the long term.

1. **In patients with Type B[1,2,4] dissections, what specific findings predicts complicated dissections?**
   (a) Primary entry tear on concavity of distal arch
   (b) Primary entry tear on convexity of distal arch
   (c) Both
   (d) None

Ans. (a)

JAYPEE BROTHERS

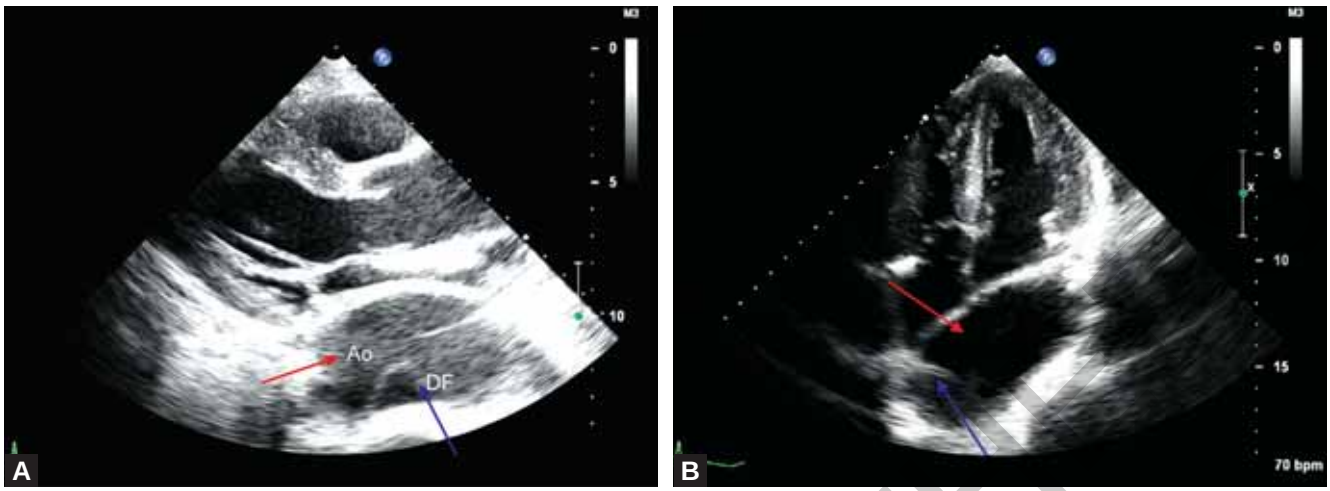

Figs. 32.5A and B: 2D TTE. Parasternal long axis (A) and apical 4 chamber (B) views demonstrating the aneurysmal descending aorta (red arrow) with encroachment on left atrium. The dissection flap is visualized (purple arrow).

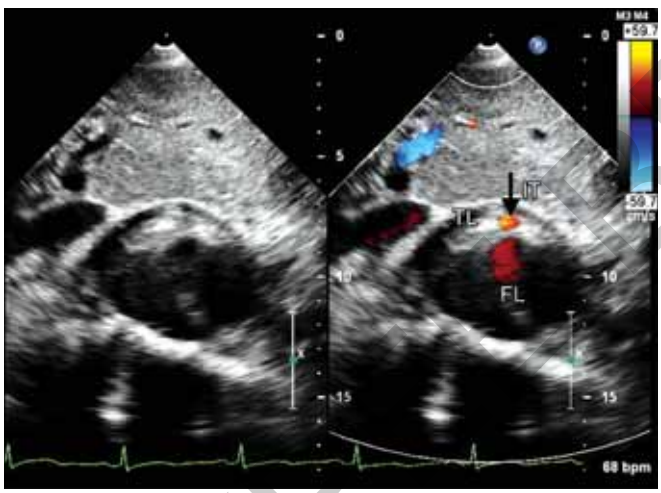

Fig. 32.6: Subcostal view demonstrating an intimal tear (arrow, IT) with blood flow going from a very small true lumen (TL) to a large false lumen (FL).

Complicated dissections are dissections associated with development of shock, periaortic hematoma, spinal cord ischemia, mesenteric ischemia/infarction, acute renal failure, limb ischemia, recurrent or refractory pain, or refractory hypertension. It is felt that dissections that involve concavity of arch tend to have more extensive involvement and often are associated with complicated dissections. Independent predictors of in-hospital mortality for type B dissection were age >70, preoperative limb ischemia, periaortic hematoma, and need for surgical management.

2. What is the test of choice for a patient with suspected type B acute aortic dissection?

(a) Computed tomographic angiography
(b) Magnetic resonance angiography
(c) Transesophageal echocardiogram
(d) All of the above

Ans. (d)

All of the choices above have excellent sensitivity and specificity to diagnose acute aortic dissection with a high sensitivity (>95%) and specificity (>95%). If one of the diagnostic tests is suboptimal, a second test can be used to arrive at the accurate diagnosis.

MOVIE LEGENDS

101 and 102: 2D TTE. Parasternal long axis and apical 4 chamber views demonstrating the aneurysmal descending aorta (red arrow) with encroachment on left atrium. The dissection flap (purple arrow) is visualized.

103: Subcostal view demonstrating an intimal tear (black arrow) with blood flow going from a very small true lumen to a large false lumen.

REFERENCES

1. Kent KC. Clinical Practice, Abdominal aortic aneurysms. N Engl J Med. 2014;371(22):2101-8.
2. Hughes GC. Management of acute type B aortic dissection; ADSORB trial. J Thorac Cardiovasc surg 2015;149:S158-62.
3. Tsai TT, Nienaber CA, Eagle KA. Acute aortic syndromes. Circulation. 2005;112:3802–13.

JAYPEE BROTHERS

4. Hiratzka LF, Bakris GL, Beckman JA, et al. 2010 ACCF/AHA/AATS/ACR/ASA/SCA/SCAI/SIR/STS/SVM guidelines for the diagnosis and management of patients with thoracic aortic disease: a report of the American College of Cardiology Foundation/American Heart Association Task Force on Practice Guidelines, American Association for Thoracic Surgery, American College of Radiology, American Stroke Association, Society of Cardiovascular Anesthesiologists, Society for Cardiovascular Angiography and Interventions, Society of Interventional Radiology, Society of Thoracic Surgeons, and Society for Vascular Medicine. Circulation. 2010;121:e266–369. This consensus guideline document provides comprehensive recommendations for the diagnosis and treatment of patients with acute aortic syndromes.
5. Harris KM, Strauss CE, Eagle KA, et al. Correlates of delayed recognition and treatment of acute type A aortic dissection: the International Registry of Acute Aortic Dissection (IRAD). Circulation. 2011;124:1911–8.
6. Harris KM, Braverman AC, Eagle KA, et al. Acute aortic intramural hematoma: an analysis from the International Registry of Acute Aortic Dissection. Circulation. 2012;126:S91–6.

JAYPEE BROTHERS

CASE 56

Rajesh Janardhanan

PROSTHETIC MITRAL VALVE OBSTRUCTION: REAL-TIME THREE-DIMENSIONAL TRANSESOPHAGEAL ECHOCARDIOGRAPHY-GUIDED DIAGNOSIS AND MANAGEMENT

A 55-year-old female presented with progressive exertional dyspnea, orthopnea and profound fatigue on minimal activity for 5 days. Her medical history was notable for rheumatic fever with severe mitral regurgitation. She had undergone mitral valve repair 5 years earlier. Following the failure of that mitral repair two years later, she underwent a repeat sternotomy and mechanical mitral valve replacement (26 mm Carbomedics valve) due to worsening symptoms. She endorsed nonadherence to warfarin therapy. She denied any recent infection or drug abuse. Examination on arrival revealed bi-basilar pulmonary crackles and bipedal edema. Her cardiovascular exam was notable for a diastolic murmur at the apex with absence of audible prosthetic valve clicks.

The results of routine biochemical tests were within normal limits with the exception of a subtherapeutic International Normalized Ratio (INR) of 1.2. A fluoroscopic view of the prosthesis indicated absent opening and closing of one mechanical disc (153). A transthoracic echocardiogram (TTE) revealed mitral valve obstruction with an increased mean transmitral gradient of 24 mm Hg. 2D-transesophageal echocardiography (2D-TEE) revealed an immobile disc with haziness noted on its atrial side (Fig. 56.1). Images obtained using real time (RT)3D-TEE demonstrated the presence of a mass, with texture and appearance suggestive of a partially obstructive thrombus attached to the atrial side of the mechanical valve restricting the anteromedial disc of the valve (Figs. 56.2 and 56.3, 154).

Due to the patient's comorbidities, two prior sternotomies, and high STS score of 17%, our multidisciplinary team recommended that she undergoes thrombolysis with systemic tissue plasminogen activator (tPa). She received 10 mg IV bolus alteplase, followed by 90 mg infused over one-and-a-half hours and subsequently IV heparin infusion. Post-thrombolysis, her symptoms resolved and a

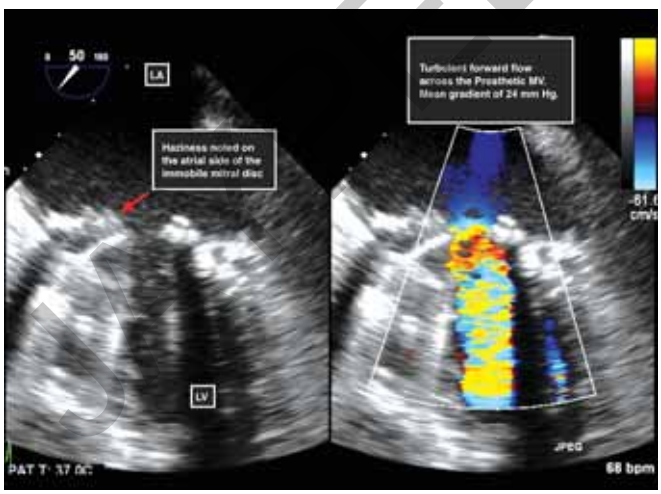

Fig. 56.1: 2D transesophageal echocardiographic view of the prosthetic mitral valve. Haziness noted over the atrial side of the prosthesis (left). Turbulent forward flow across the prosthetic mitral valve with measured mean gradient of 24 mm Hg (right).



Fig. 56.2: Real-time 3D transesophageal echocardiogram of prosthetic mitral valve in closed position showing a mass suggestive of a partially obstructive thrombus attached to the atrial side of the mechanical valve, restricting the anteromedial disc of the valve.

JAYPEE BROTHERS



Fig. 56.3: Real-time 3D transesophageal echocardiogram of prosthetic mitral valve in open position showing a mass suggestive of a partially obstructive thrombus (arrow) attached to the atrial side of the mechanical valve, restricting the anteromedial disc of the valve.

follow-up TTE revealed reduction in mitral valve gradient to 6 mm Hg. The full excursion of the disc was confirmed on fluoroscopy suggesting resolution of obstruction (🎥 155). She was discharged home under stable condition. During the 4-week outpatient follow-up, she reported resolution of all her symptoms. An outpatient TTE was performed 4 weeks after the thrombolysis confirming full excursion of the discs and a normal mitral valve gradient.

In summary, we present a case of an acute thrombus causing obstruction of a mechanical mitral valve. RT3D-TEE provided en face view of the mitral prosthesis that was otherwise not obtainable with routine 2D-TEE. Accurate diagnosis and confirmation of the partial thrombus using RT3D-TEE, was crucial in determining the best management strategy for our high-risk patient, who had undergone two prior sternotomies. The decision to attempt thrombolysis allowed for avoidance of high-risk surgery.

1. **The standard therapy for acute prosthetic valve thrombosis of left-sided valves is:**
   (a) Thrombolysis
   (b) Urgent surgery
   (c) Thrombolysis followed by surgery
   (d) Conservative management

Ans. (b)

2. **The major risk factors for prosthetic valve obstruction include:**
   (a) Mitral location of the prosthesis
   (b) Inadequate anticoagulation therapy
   (c) Aortic location of prosthesis
   (d) Tricuspid location of prosthesis
   (e) (a) and (b)

Ans. (e)

3. **The following imaging modalities can help in the diagnosis of prosthetic valve thrombosis:**
   (a) TTE
   (b) TEE
   (c) Cine-fluoroscopy
   (d) EKG-gated CTA
   (e) All of the above

Ans. (e)

MOVIE LEGENDS

153: Cine-fluoroscopic view of the prosthesis (prethromboysis) indicated absent opening and closing of one mechanical disc.

154: Real time 3D transesophageal echocardiography of the prosthetic mitral valve (view from the atrial side) showing restricted movement of the anteromedial disc due to a partially obstructing thrombus (red arrow).

155: Fluoroscopic video of the opening and closing of the prosthetic mitral valve, postthrombolysis. The full excursion of the valve is appreciated here.

JAYPEE BROTHERS

or detailed information on cardiology books, visit our website www.ejaypee.com, for detailed information on cardiology books, visit our website www.ejaypee.com, for detailed information on ca

Interesting Cases in Echocardiography

This book consists of over 250 instructive/interesting case studies with approximately 1000 movie clips from different contributors throughout the world. It is geared towards all interested in echocardiography and should prove useful to all physicians (cardiologists, internists, family physicians, anesthesiologists, cardiac surgeons, radiologists and intensive care physicians), ultrasound technologists, and paramedical personnel, who already have some background in cardiac ultrasound, but are interested in learning its usefulness in day-to-day clinical practice. This book will serve as a valuable companion to both the *Comprehensive Textbook of Echocardiography* and the *Manual of Echocardiography*.



Navin C Nanda MD is President, International Society of Cardiovascular Ultrasound, and Distinguished Professor of Medicine and Cardiovascular Disease at the University of Alabama at Birmingham, Birmingham, Alabama, USA. He is an internationally renowned cardiologist, who has done pioneering work in echocardiography. He with his group was the first to discover the pulmonary valve by echocardiography, diagnose a bicuspid aortic valve, invent treadmill exercise echocardiography, and introduce color Doppler in USA. He also introduced fetal color Doppler, pioneered the clinical use of real time three-dimensional transesophageal echocardiography and was the first to demonstrate the usefulness of echocardiography in cardiac pacing and electrophysiology. His contributions 'have changed the way cardiology is practiced in the world today' and he has been honored as the *Father of Echocardiography* and *Father of Modern Echocardiography* by many prestigious organizations.

Some of the accolades he has received include the prestigious Ellis Island Medal of Honor, the American College of Cardiology's International Service Award for 'enhancing cardiovascular care throughout the world', first recipient of the Tufts University (Boston) award in echocardiography, the Andreas Gruentzig Award from the Swiss Society of Cardiology, 'Prince of Echocardiography of the Heart and Great Vessels' by the Italian Society of Echocardiography, 'Citizen of Rome' designation by the Mayor of Rome, Special Award by the Government of Egypt, Lifetime Achievement Award by the Government of India and 'the world's best and most respected echocardiographer' designation by the Chinese Society of Ultrasound. He has authored/co-authored over 1000 publications and several books on echocardiography and cardiology.

Shelving Recommendation
CARDIOLOGY

ISBN 978-93-86056-94-8
9 789386 056948

Buy from ejaypee

JAYPEE BROTHERS