peebrothers.com, for detailed information on pathology books, visit our website www.jaypeebrothers.com, for detailed information on pathology book

LIVER BIOPSY
Made Easy

Made Easy

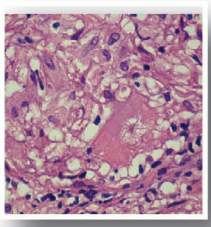
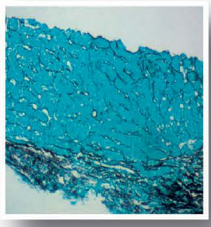
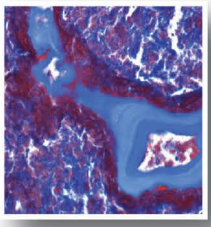

Nalini Bansal Gupta

Foreword
NC Nayak

JAYPEE

Contents

SECTION 1: LIVER BIOPSY

1. Normal Liver **3**
Nalini Bansal Gupta, Apurba Rajbongshi
- *Gross Anatomy 3*
- *Functional Segments 4*
- *Microscopy 4*
- *Hepatocyte Couplet 6*
- *Zonation 6*
- *Space of Disse 8*
- *Biliary System 11*
- *Liver Biopsy Sign Out for Normal Biopsy 13*

2. Important Aspects of Liver Biopsy **15**
Nalini Bansal Gupta
- *Types of Liver Biopsy 15*
- *Liver Biopsy Devices 16*
- *Ideal Liver Biopsy 16*
- *Indications for Liver Biopsy 17*

3. Simple Approach to Liver Biopsy Interpretation **18**
Nalini Bansal Gupta, Chhagan Bihari
- *Interpretation of Liver Biopsy 18*
- *Categorizing the Biopsy 19*
- *Clues to Different Pathologies 20*

4. Special Stains and Immunohistochemistry **21**
Kaushik Majumdar, Puja Sakhuja
- *Special Stains in Hepatopathology Laboratory 21*
- *Immunohistochemistry 29*

5. Acute on Chronic Liver Failure and Clinical Scores **33**
Nalini Bansal Gupta
- *Definition 33*
- *Stages of Cirrhosis 33*
- *Liver Biopsy of ACLF 33*
- *Clinical Scores Used in Liver Diseases 34*
- *Liver Biopsy Sign Out 35*

SECTION 2: HEPATITIC PATHOLOGY

6. Acute Hepatitis **39**
Prasenjit Das, Gaurav Pratap Singh Gahlot, Siddhartha Datta Gupta
- *Definition 39*
- *Epidemiology and Etiology 39*
- *Clinical Course 40*
- *Laboratory Investigations 40*

- *Liver Biopsy 41*
- *Histopathology 41*
- *Histological Sine Qua Non of Acute Hepatitis 43*
- *Patterns of Severe Acute Hepatitis 43*
- *Evolution of Acute Hepatitis 45*
- *Histopathological Differential Diagnosis 45*
- *Etiology-specific Histopathological Changes 45*
- *Liver Biopsy Sign Out 47*

7. Chronic Hepatitis 49

Prasenjit Das, Gaurav Pratap Singh Gahlot, Siddhartha Datta Gupta

- *Definition/General 49*
- *Etiology 49*
- *Clinical Features 49*
- *Laboratory Investigation 50*
- *Indications of Liver Biopsy in Chronic Hepatitis 50*
- *Histological Sine Qua Non 50*
- *Liver Biopsy 50*
- *Special Stains Useful in Chronic Hepatitis 51*
- *Etiology-specific Histopathological Changes 51*
- *Approach to Non-neoplastic Liver Diseases 57*
- *Nomenclature and Scoring 57*
- *Liver Biopsy Sign Out 61*

8. Autoimmune Hepatitis 63

Nalini Bansal Gupta, Chhagan Bihari

- *DefinItion/General 63*
- *Pathogenesis 63*
- *Clinical Features 63*
- *Laboratory Investigation 63*
- *Important Things to Know about Autoimmune Hepatitis 64*
- *Diagnostic Difficulties 64*
- *Scoring System 64*
- *Histopathology 64*
- *Types of Autoimmune Hepatitis 66*
- *Microscopy of Autoimmune Hepatitis 67*
- *Autoimmune Liver Disorders in Children 67*
- *Autoimmune Pediatric Liver Disease 67*
- *Autoimmune Acute Liver Failure 67*
- *Liver Biopsy Sign Out 68*

SECTION 3: STEATOTIC PATTERN

9. Nonalcoholic Fatty Liver Disease 73

Anjali D Amarapurkar

- *Terminology for Fatty Liver Disease 73*
- *Prevalence 74*
- *Common Causes of Fatty Liver Disease 74*
- *Clinical Features 75*
- *Imaging in NAFLD 75*
- *Role of Liver Biopsy in NASH 76*
- *Histopathological Features 76*
- *Scoring System 79*

- *Pediatric NAFLD* 80
- *Liver Biopsy Sign Out* 81

10. Alcoholic Liver Disease **84**
Nalini Bansal Gupta
- *General Aspects* 84
- *Pathophysiology* 84
- *Clinical Features* 84
- *Laboratory Investigation* 85
- *Microscopy* 85
- *Features Suggestive of Alcoholic Steotohepatitis over NASH* 86
- *Liver Biopsy Sign Out* 86

SECTION 4: CHOLESTATIC PATTERN

11. Cholestatic Pathology **89**
Nalini Bansal Gupta
- *Types of Bile* 89
- *Flow of Bile* 89
- *Formation of Bile* 89
- *Role of Bile* 90
- *Constituents of Bile* 90
- *Important Terminologies* 90
- *Etiology* 94
- *Clinical Features* 95
- *Laboratory Investigation* 95
- *Histological Features of Cholestasis* 95
- *Etiological Diagnostic Consideration in Cholestatic Disorders* 96
- *Liver Biopsy Sign Out* 98

12. Biliary Pathology **100**
Nalini Bansal Gupta
- *Definition* 100
- *Etiology* 100
- *Liver Biopsy Sign Out* 105

13. Vanishing Bile Duct Syndrome **108**
Nalini Bansal Gupta
- *Definition/general* 108
- *Intrahepatic Ductal System* 108
- *Etiology* 108
- *Clinical Features* 109
- *Laboratory* 109
- *Radiology* 109
- *Microdescription* 109
- *Immunohistochemistry* 110
- *Treatment* 110
- *Specific Disorders* 110
- *Liver Biopsy Sign Out* 111

14. Overlap Syndrome **112**
Nalini Bansal Gupta
- *Definition* 112
- *Variants of Autoimmune Hepatopathies* 112

- *AIH-PBC Overlap Diagnostic Criteria 112*
- *AIH/PSC Overlap also Known as Autoimmune Sclerosing Cholangitis (ASC) 113*
- *AIH/AIC Overlap 113*
- *Outliers 113*
- *Autoimmune Cholangitis (AIC) 113*
- *Sequential Syndromes 113*
- *Comorbidities 113*
- *Liver Biopsy Sign Out 113*

15. IgG4 Cholangiopathy 115
Nalini Bansal Gupta, Chhagan Bihari
- *General 115*
- *IgG4-related Diseases 115*
- *IgG4 Cholangiopathy/IgG4 Sclerosing Cholangitis/IgG4SC 115*
- *Liver Biopsy Sign Out 116*

SECTION 5: VASCULAR PATTERN

16. Vascular Liver Disorders 121
Chhagan Bihari, Komal Agarwal
- *Inflow Vascular Pathology 121*
- *Outflow Vascular Pathology 127*
- *Liver Biopsy sign Out for BCS 132*
- *Liver Biopsy Sign Out for VOD 132*

SECTION 6: MIXED PATTERN

17. Drug-induced Liver Injury 137
Chhagan Bihari
- *General Aspects 137*
- *Importance of Drug-induced Liver Injury 137*
- *Clinical Sign and Symptoms 137*
- *Risk Factors for Drug-induced Liver Injury 138*
- *Terminology/Mechanisms of DILI 138*
- *Indications of Liver Biopsy in DILI 139*
- *Role of Liver Histopathology 139*
- *Morphological Patterns of DILI in Liver Histopathology 140*
- *Frequency of Types of Liver Injury 140*
- *Pathomorphology of DILI 140*
- *Liver Histology and Outcome in DILI 151*
- *Liver Biopsy Sign Out 151*

SECTION 7: SPECIFIC PATHOLOGIES

18. Wilson's Disease 155
Malini Eapen
- *Definition/General 155*
- *Clinical Features 155*
- *Pathogenesis 156*
- *Laboratory Investigations 157*

- *Liver Biopsy 157*
- *Special Stains 158*
- *Genetic Studies 158*
- *Treatment 159*
- *Liver Biopsy Sign Out 159*

19. Hemochromatosis 160
Malini Eapen
- *Definition/General 160*
- *Common Terminologies 160*
- *Overview of Iron Metabolism 160*
- *Classification of Iron Overload 162*
- *Liver Biopsy Sign Out 166*

20. Important Metabolic Liver Diseases 168
Chhagan Bihari
- *Erythropoietic Protoporphyria 168*
- *Glycogen Storage Diseases 168*
- *Galactosemia 169*
- *Endoplasmic Reticulum Storage Diseases (Alpha 1-Antitrypsin Deficiency) 170*
- *Lysosomal Storage Disease [Glycosyl Ceramide Lipidosis (Gaucher Disease)] 171*
- *Sphingomyelin-Cholesterol Lipidosis (Niemann–Pick Disease) 171*
- *Wolman and Cholesterol Ester Storage Diseases 172*
- *Hereditary Defects of Bilirubin Metabolism 173*

SECTION 8: PEDIATRIC LIVER DISEASES

21. Ductal Plate Malformation 177
Nalini Bansal Gupta
- *History 177*
- *Definition 177*
- *Histology 177*
- *Immunohistochemistry 178*
- *Development of Bile Duct in Portal Tract 178*
- *DPM-related Cystic Disease of Liver 179*

22. Ductal Plate Malformation-related Hereditary Liver Diseases 180
Nalini Bansal Gupta
- *Congenital Hepatic Fibrosis 180*
- *Caroli's Syndrome 182*
- *Caroli's Disease 183*
- *Autosomal Dominant Polycystic Disease 183*
- *Choledochal Cyst 184*
- *Von Meyenberg Complex/Biliary Microhamartoma 185*
- *Liver Biopsy Sign Out 185*

23. Cholestatic Pediatric Diseases 187
Nalini Bansal Gupta
- *Neonatal Hepatitis Syndrome 187*
- *Causes of Neonatal Cholestasis 187*

- *Neonatal Hepatitis 191*
- *Paucity of Intrahepatic Bile Ducts (PFIC) 193*
- *Familial Intrahepatic Cholestasis 194*
- *Alpha 1 Antitrypsin Deficiency 196*
- *Cystic Fibrosis 198*
- *Liver Biopsy Sign Out 199*

SECTION 9: CIRRHOSIS

24. Cirrhosis **203**

Nalini Bansal Gupta

- *Definition 203*
- *Clinical Stages of Cirrhosis 203*
- *Pathophysiology 203*
- *Clinical Features 204*
- *Macroscopically 204*
- *Microscopy 204*
- *Differential Diagnosis 206*
- *Different Types of Cirrhosis Identified on Biopsy 206*
- *Staging of Cirrhosis 206*
- *Regression of Cirrhosis 208*
- *Liver Biopsy Sign Out 208*

SECTION 10: TRANSPLANT PATHOLOGY

25. Transplant Pathology **211**

Nalini Bansal Gupta, Chhagan Bihari

- *Types of Post-transplant Liver Biopsy 211*
- *Spectrum of Diseases Seen in Post-transplant Liver Biopsies 211*
- *Differentials as Per Timing of Biopsy 212*
- *Liver Transplant Rejection 212*
- *Recurrence of Primary Diseases 219*
- *Post-transplant Lymphoproliferative Disorder 221*
- *Opportunistic Infections 222*
- *Vascular Complications 225*
- *Biliary Tract Complication 226*
- *"Small-for-Size" Graft Syndrome 227*
- *De novo Autoimmune Hepatitis/Plasma Cell Hepatitis 228*

SECTION 11: NODULAR LESIONS OF THE LIVER

26. Nodular Lesions of the Liver **235**

Nalini Bansal Gupta

- *Nodular Lesions of the Liver 235*
- *Liver Biopsy Sign Out 248*

Glossary *251*

Index *261*

Chapter 3

Simple Approach to Liver Biopsy Interpretation

Nalini Bansal Gupta, Chhagan Bihari

- Interpretation of biopsy depends upon the type of liver biopsy.
- Whether it is a parenchymal core/transjugular liver biopsy (TJLB)/wedge biopsy will alter the final interpretation
- Parenchymal biopsies are best for analysis of medical/surgical pathologies
- TJL biopsies are fragmented and should be carefully interpreted
- Wedge biopsies often contain subcapsular tissue and overestimates the fibrosis, so the deeper areas should be interpreted for fibrosis and ongoing pathology.

Minimum stains required for reporting–H & E for histology and MT for fibrosis.

INTERPRETATION OF LIVER BIOPSY

- Try to identify the area predominantly involved in low power
  - Lobule predominant
  - Portal tract predominant
- On high power, now see and enumerate following findings:
  - Number of portal tracts in one go, leaving the lobular parenchyma and look for following:
    - Size: Normal or expanded with edema—Indicate obstructive pathology
    - Degree of inflammation: Mild/moderate/severely increased
    - Type of inflammatory cells: Predominantly mononuclear—Viral hepatitis; Lymphoplasmacytic—Autoimmune; Mixed with eosinophils—Drug injury; Neutrophils—Biliary diseases
    - Interface hepatitis: Lymphocytes in portal tract spilling over into periportal hepatocytes.
    - Bile duct status:
      - Ductopenia—Absence of bile duct in >50% of tracts
      - Duct present but sclerosing fibrosis—Sclerosing cholangitis
      - Granulomatous duct destruction—PBC
      - Prominent bile ductular reaction seen in biliary pathology.

JAYPEE BROTHERS

- Hepatic artery: Hypertrophy or hyperplasia of hepatic artery—Indicates bile duct hepatopathy like extrahepatic biliary atresia/congenital hepatic fibrosis etc.
- Portal vein: Present or absent; Absent profiles—noncirrhotic portal fibrosis (NCPF), congenital hepatic fibrosis (CHF).
- **Lobule:** Within a lobule analyze the following aspects:
  - Lobular architecture:
    - Preserved or is showing disarray
    - Preserved architecture means single cell plate thick hepatocyte cords.
- Hepatocytes: Look for evidence of injury
  - Degenerative changes: Ballooning, eosinophilic, hydropic or feathery degeneration (ballooning: rounded cell contours, larger than normal hepatocytes and rarified cytoplasm; eosinophilic—containing mitochondria as seen in other conditions like oncocytoma, etc.; hydropic—rarified cytoplasm but not rounded; feathery: may be rounded or polygonal, containing bile)
  - Intracellular accumulation: Fat droplets—Steatosis/iron/copper/bile, ground glass appearance of cytoplasm
  - Necrosis or apoptosis of hepatocytes-
  - Spotty necrosis (Necrosis of 1–2 hepatocytes)
  - Confluent necrosis—(Necrosis of >3 hepatocytes)
  - Bridging necrosis-Bridges between portal to portal or portal to central vein.
- Apoptosis: Shrunken, pyknotic and intensely eosinophilic hepatocyte also called councilman bodies
- Lobular Inflammation: Activated/cytotoxic lymphocytes scattered within the lobules.
- Sinusoids:
  - Prominence of Kupffer cell with engulfed apoptotic fragments and debris
  - Sinusoidal congestion and endothelial cell injury.
- Zonal distribution of pathology: Whether the pathological changes are seen predominantly in one zone than other.

CATEGORIZING THE BIOPSY

Once these findings are noted, now try to categorize the biopsy into the following categories:

- Hepatitic Pathology: Chronic viral hepatitis or autoimmune hepatitis
- Steatotic: NASH or alcoholic liver disease
- Cholestatic: Cholestatic or biliary diseases
- Mixed: Drug-induced liver injury (DILI)
- Sinusoidal injury pattern with congestion: Vascular diseases.

JAYPEE BROTHERS

CLUES TO DIFFERENT PATHOLOGIES

- *Chronic HBV hepatitis:* Ground glass hepatocytes.
- *Chronic HCV Hepatitis:*
  - Lymphoid aggregate in portal tract
  - Mild steatosis.
- *Autoimmune Hepatitis:*
  - Dense lymphoplasmacytic cell infiltrate with interface activity
  - Hepatocellular pseudorossettes, where inflammation circles around 3–4 hepatocyte groups
  - Areas of parenchymal loss.
- *NASH*
  - Mainly zone 3 steatosis with ballooning degeneration
  - Perisinusoidal fibrosis on MT.
- *ALD (Alcoholic Liver Disease)*
  - Lobular unrest with steatosis, cholestasis,
  - MDB, neutrophilic satellitosis, pericellular fibrosis.
- *Purely intrahepatic cholestatic:* Cellular and canalicular cholestasis with no significant bile duct pathology.
- *Biliary diseases:* Bile duct pathology like granulomatous bile duct destruction as in primary biliary cirrhosis or periductal fibrosis as in primary sclerosing cholangitis.
- *Vascular pathology:* Zone 3 sinusoidal congestion, hepatocyte necrosis and venocentric fibrosis.

JAYPEE BROTHERS

or detailed information on pathology books, visit our website www.jaypeebrothers.com, for detailed information on pathology books, visit our we

LIVER BIOPSY
Made Easy

Salient Features

- A user-friendly book on the subject
- Presents the text in a simple and easy-to-understand manner
- Focuses on basic understanding of normal liver biopsy and specific liver pathologies
- Reviews all the current terminologies, grading and staging systems used in liver biopsies
- Includes glossary of interesting and varied cases of hepatopathology
- Serves as a hands-on guide for the reporting of liver biopsies
- Helpful for the students of pathology as well as practising pathologists.

Nalini Bansal Gupta MD (Gold Medalist), DNB, MNAMS, PDCC (superspecialized in gastro- and hepatopathology) is currently working in the capacity of Senior Histopathologist at SRL Ltd, Fortis Escorts Heart Institute, New Delhi, India. She has over 10 years of experience in the specialty. She has over 35 academic publications. She is an Associate Editorial Board Member of *Indian Journal of Pathology and Microbiology*. She is also reviewer of various journals, pathology outlines and a Member of Indian Association of Study of Liver Diseases, Hans Popper Hepatopathology Society, USA. She is also a scholar of ISN.



Available at all medical bookstores
or buy online at www.jaypeebrothers.com

JAYPEE BROTHERS
Medical Publishers (P) Ltd.
www.jaypeebrothers.com

Join us on facebook.com/JaypeeMedicalPublishers

Shelving Recommendation
PATHOLOGY

ISBN 978-93-86150-26-4