r website **www.jaypeebrothers.com,** for detailed information on surgery books, visit our website **www.jaypeebrothers.com**

Art and Science of Cleft Lip and Cleft Palate Repair







Girish N Amlani

Foreword
Santosh Raibagkar

JAYPEE

Contents

1. Historical Perspective 1
- *History of Cleft Lip 1*
- *History of Cleft Palate 5*

2. Anesthesia 7

3. Embryology 13
- *Classical Theory 13*
- *Mesodermal Reinforcement 13*
- *Etiology 16*

4. Anatomy 22
- *Orbicularis Oris Muscle 23*
- *Cleft Muscles in Unilateral Cleft Lip 24*
- *Anatomy of Unilateral Cleft Lip and Nose 25*

5. Classification 29
- *Davis and Ritchie (1922) 29*
- *Veau (1931) 29*
- *Kernahan and Stark (1958) 30*
- *Kernahan (1971) 30*
- *Millard 30*
- *Harkins and Associates (1962) 36*
- *Spina (1974) 36*

6. Unilateral Cleft Lip Repair 37
- *Clinical Examination 37*
- *Investigation 38*
- *Treatment 38*
- *Preoperative Preparation 38*
- *Postoperative Care 55*

7. Bilateral Cleft Lip Repair 59
- *Operation 61*

8. Cleft Palate Repair 71
- *Ear Pathology 75*
- *Cleft Palate Repair 77*
- *Two-Flap Palatoplasty 78*
- *Postoperative Care 88*
- *Outcomes of Cleft Palate Repair 88*

9. Management of Velopharyngeal Dysfunction 94
- *Assessment of Velopharyngeal Function 94*
- *Posterior Pharyngeal Flap 96*

10. Alveolar Cleft 106
- *Primary Bone Grafting 106*
- *Secondary Bone Grafting 107*
- *Late secondary Bone Grafting 108*
- *Bone Morphogenic Protein 108*

11. Secondary Deformities of the Cleft Lip, Nose and Palate... 109
- *Cleft Lip 109*
- *Cleft Palate Fistula 109*
- *Cleft Nose 113*

12. Nasal Conformer and Nasoalveolar Molding..... 122
- *Grayson's Technique 122*
- *Figuera's Technique 126*
- *Liou's Technique 126*

13. Orthodontic Treatment and Orthognathic Surgery for Cleft Patients 127
- *Primary Dentition 127*
- *Transitional Dentition 127*
- *Permanent Dentition 127*
- *Lefort 1 Osteotomy 128*

14. Rare Craniofacial Cleft 131
- *Number 0 131*
- *Number 1 131*
- *Number 2 132*
- *Number 3 132*
- *Number 4 132*
- *Number 5 133*
- *Number 6 133*
- *Number 7 133*
- *Number 8 136*
- *Number 9 136*
- *Number 10 136*
- *Number 11 136*
- *Number 12 136*
- *Number 13 136*
- *Number 14 136*

Index 139

CHAPTER 3

Embryology

CLASSICAL THEORY

Dursy (1869) and His (1874) postulated that there were five processes of the face, namely the frontonasal, the paired maxillary and mandibular processes. These processes grew towards and fused with each other, to form the face. Failure to fuse was thought to lead to cleft formation. This theory was too pat and did not serve to explain the formation of median clefts. Patten (1971) still believes that the theory of merging of process is essentially true and the mesoderm underneath gradually elevates the depressed lines of juncture.

MESODERMAL REINFORCEMENT

Stark (1954) was stimulated in to a different line of thinking after reading about the work of Hochstetter (1936) who suggested that upper lip and premaxilla are represented by an epithelial wall into which reinforcing mesoderm must migrate to give substance to the lip (Fig. 3.1). This theory was first supported by Veau (1937) and Tondury (1955). Stark managed to six cleft embryos, three of which had bilateral clefts, and after serial coronal section and planimetric



Fig. 3.1: Migration of mesoderm

JAYPEE BROTHERS

measurements, he found of deficiency of mesoderm on the cleft side in every case and postulated his theory of mesodermal penetration.

His theory states that there are three mesodermal masses within that epithelial wall which constitutes the primitive palate. If mesoderm is deficient on one side, then the epithelial wall rupture on that is lacking, the cleft is either complete or incomplete . The Simonart's band which is present in incomplete cleft, was found to have only an epithelial cord of cells with no mesoderm. This served to emphasize the fact that this band was not a dynamic attempt at fusion of the cleft by a stream of mesoderm, as was previously thought, but rather, remnant of the epithelial wall which split up to the nostril, and stop short there.

Cranial neural crest cells give rise to most of the facial tissue including those forming the lip and palate. Much of the blueprint for the midfacial development is laid down very early at about 17th gestational day, in human embryos. Cranial neural crest cells migrate from their original position at the margins of the neural fold. At the most craniocaudal levels and in most specifies they migrate at the time of neural fold closer, either down beside the neural tube or laterally under the surface ectoderm. In the head region, crest cells migrating laterally and ventrally under the surface ectoderm are much more numerous and eventually differentiate in to all of the facial skeletal and connective tissues except the enamel of the teeth.

At the end of their migration crest cells form virtually all the mesenchyme in the upperfacial region, whereas in the visceral arches, the neural crest cells surround cores of mesodermal mesenchyme that were present before migration of endothelial linings of the embryonic blood vessels (Figs 3.2A to F).

The facial development enters a new phase at the end of 5th week of gestational age. It is manifested by the regional growth of visceral arches and facial prominences. A mesenchymal cell process meshwork is found in close contact with underside of epithelial areas. These mesenchymal cells connected by gap junction, mediate the epithelial mesenchymal interaction.

The olfactory placodes are epithelial thickenings, derived directly from the anterior margin in later development.

Initially, the olfactory placodes site over the corner of the forebrain so that its medial edge is more forward than its lateral edge. A curling forward of its lateral margin initiates formation of the lateral nasal process and causes it to grow further rapidly and "catch up" with the medial nasal process which forms at the medial edge and the placode.

The maxillary prominence is formed by the proximal half of first visceral arch, which bends so that its more proximal part end up facing forward under the eye. It then grows forward at its tip, which eventually contacts the medial nasal process and lateral nasal process.

As the morphogenetic movements continue, the lateral nasal process becomes progressively more developed and sweeps forward over the underlying maxillary prominence. The maxillary process has already made

JAYPEE BROTHERS

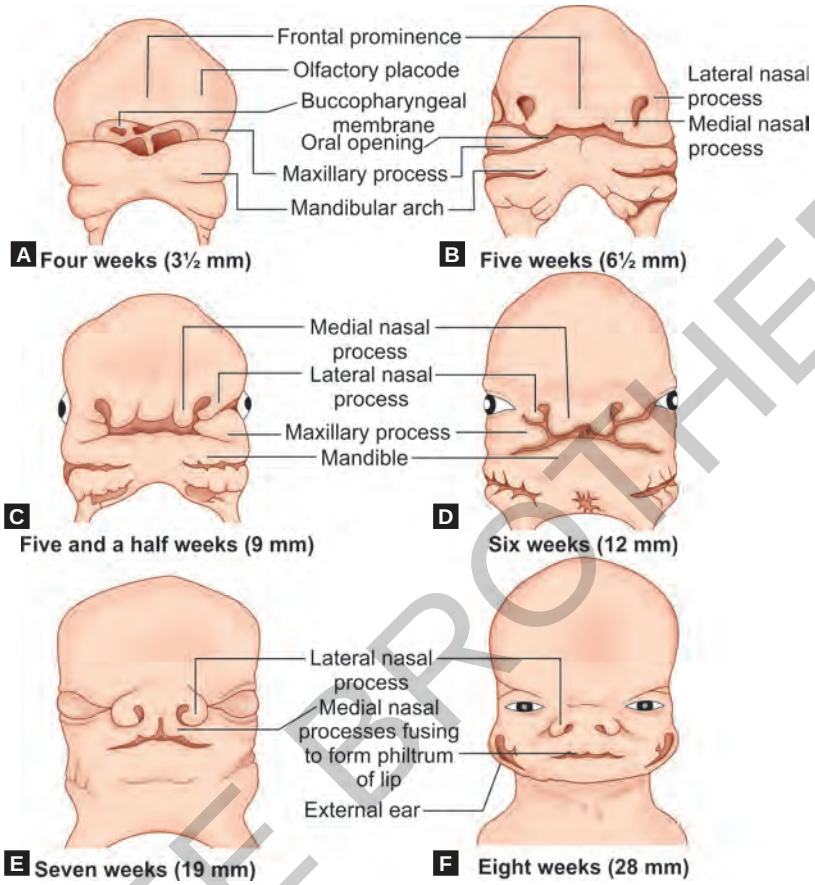

Figs 3.2A to F: Embryology. Normal development of face

contact with medial nasal process. With continue development, mostly growth in forward direction, lateral nasal process comes in contact with the medial nasal process. These prominences then coalesce through the phenomenon of fusion and margin.

Palatal process a plate like shelf grows medially from maxillary process. So, palate is formed by primitive palate, a part of frontonasal process and two palatal processes. Initially palatal shelves extend vertically and then rotate to a horizontal plane dorsal to the tongue.

Single mutation in multiple signaling pathway leads to multifactorial disorder facial cleft. There are three unique features in craniofacial development.

1. Dual origin of craniofacial tissue
   a. Cranial neural crest
   b. Mesoderm
2. Tissue interaction between neuroectoderm and facial ectoderm
3. Passive cell displacement and active cell migration, that defines head development.

JAYPEE BROTHERS

The embryoblast grows and divides into three layers: ectoderm, mesoderm and endoderm. Embryo has cranial and caudal regions. Group of cells of primitive node forms primitive streak at caudal end of embryo. Craniocaudal and mediolateral axes are established. Sonic hedgehog helps subdivision of dumbbell-shaped area of future eye field (Figs 3.3A and B). Loss of shh in medial neural plate is responsible for cyclopia with proboscis. The neural plate rolls up to form neural tube to devide ectoderm in to neuroectoderm and non-neuroectoderm. Bone morphogenetic protein regulates growth in lateral crest cells emerges at junction of neural and non-neural ectoderm. Ephrin and Eph help neural crest cell migration.

TGF-B3 are important for fusion of palatal shelves. Defective in Wnt signaling leads to cleft formation due to insufficient growth of the maxillary prominence.

Forkhead box protein E1 (FOXE1) mutation supresses fusion between maxillary and nasal processes. Interferor regulatory factor (IRF6) deficit causes Van Der Woude syndrome and popliteal pterygium syndrome and isolated cleft lip and cleft palate.

Retinoic acid, a metabolite of vitamin A, in excess or in deficit can lead to microphthalmia, holoprosencephaly, cleft lip and cleft palate. Teratogenic dose of retinoic acid inhibits shh in frontonasal process epithelium.

Fetal alcohol syndrome, prenatal exposure to alcohol cause physical and mental impairement. Alcohol increases retinoic acid degradation and impairs retinoic acid synthesis. Ethanol disrupt hedgehog signaling activity leading to neural crest cell death and craniofacial defect.

Cyclopamine and jervine are active compound in *Veratrum californicum.* These steroidal alkaloids inhibit cholesterol synthesis and transport leading to cyclopia.

ETIOLOGY

The embryological event occurs leading to cleft lip with or without cleft palate during 3–7 weeks and leading to cleft palate occurs during 5–12 weeks. The cleft

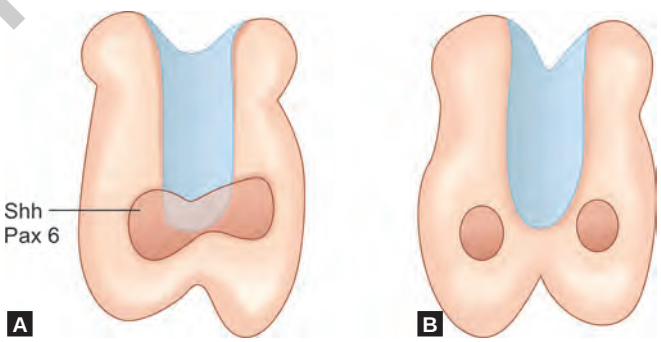

Figs 3.3A and B: Sonic hedgehog helps subdivision of dumbbell shaped area of future eye field

JAYPEE BROTHERS

lip with or without palate in white American occurs one in 700–1000 babies. Boys are affected twice than girls. Cleft palate occurs 0.5 in 1000 population and girls are more affected than boys. Left unilateral cleft lip is more common than right unilateral cleft lip. Fogh-Andersen, 1942 noted distribution according to type of cleft of 25% cleft lip alone, 50% cleft lip and palate and 25% isolated cleft palate. Wilson, 1972 noted the unilateral left sided cleft lip right sided cleft lip and bilateral cleft lip occurs in a 6:3:1 relationship.

Syndromic Cleft Lip with or without Cleft Palate

1. Trisomy 13 and trisomy 21
2. Waardenburg's syndrome
3. Van der Woude syndrome (Fig. 3.4)
4. Velocardiofacial syndrome
5. Stickler syndrome
6. Treacher-Collins syndrome
7. Downs syndrome
8. Goldenhar syndrome
9. Fetal alcohol syndrome

There are more than 200 syndromes associated with cleft lip and palate (Figs 3.5 to 3.10).

Environmental Factors

1. Vitamin B deficiency
2. Vitamin A deficiency and vitamin A excess
3. Viral infection during first trimester
4. Exposure to radiation
5. Influence of drugs
   a. Cortisone
   b. Deoxyguanosine



Fig. 3.4: Van der Woude syndrome

JAYPEE BROTHERS





Figs 3.5A and B: Pierre-Robin sequence



Fig. 3.6: Syndactyly: Right unilateral cleft lip

JAYPEE BROTHERS

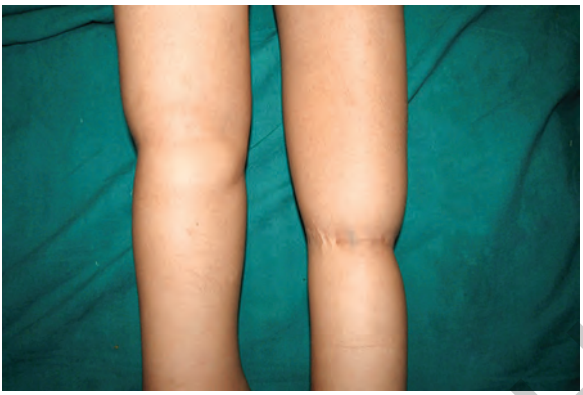

Fig. 3.7: Constriction ring syndrome



Fig. 3.8: Bilateral cleft lip and palate with chest wall deformity



Fig. 3.9: Congenital deformity of right upper limb with bilateral cleft lip

JAYPEE BROTHERS

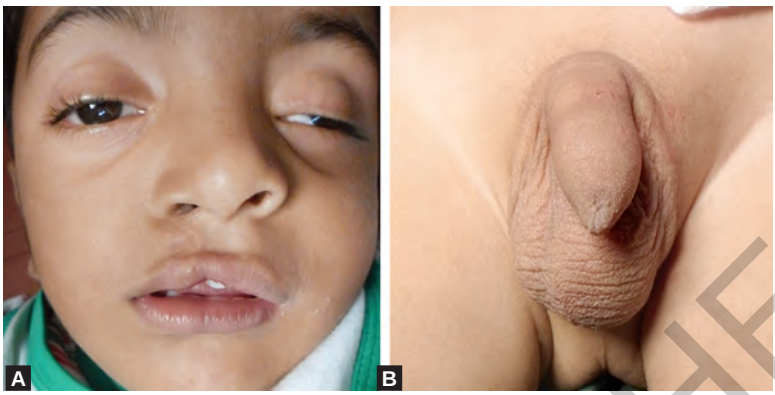

Figs 3.10A and B: (A) Right unilateral cleft lip with (B) Left congenital hydrocele

c. Insulin
d. Alcohol
e. Cyclopamine
6. Anoxia
7. Stress
8. Smoking.

BIBLIOGRAPHY

1. Ardinger HH, Buetow KH, Bell GI, et al. Association of genetic variation of the transforming growth factor—alpha gene with cleft lip and palate. Am J Huin Henet. 1989;45:348-53.
2. Chenevix-Trench G, Jones K, Green AC, et al. Cleft lip with or without cleft palate, associations with transforming growth factor alpha and retinoic acid receptor loci. An J hum Genet. 1992;51:1397-85.
3. Diewart VM, Shiota K. Morphology of human cleft lip embryos. Teratology. 1988;37:452.
4. Falconer DS. The inheritance of liability to certain diseases estimated from incidence among relatives. Ann Hum Genet. 1965;29:51.
5. Fraser FC. William allan memorial award Adress: evolution of a palatable multifactorial threshold model. Am J Hum Genet. 1980;32:796-813.
6. Fogh-Andersen P. Inheritance of harelip and cleft palate. Copenhagen: Nyt Nordisk Forlag. 1942.
7. Jones MC. Facial clefting. Etiology and developmental pathogenesis. Clin Plast Surg. 1993;20:599-606.
8. Lidral AC, Remitti PA, Basarat AM, et al. Association of MSx1 and TGFB3 with nonsyndromic clefting in humans. An J Hum Genet. 1998;63:557-68.
9. McKusick VA. Online Mendelian Inheritance in Man (OMIM). McKusick-Nathans Institute for Genetic Medicine, Johns Hopkins University (Baltimore, MD) and National Centre for Biotechnology Information, National library of Medicine, 2004.
10. Prescott NJ, Winter RM, Malcolm S. Nonsyndromic cleft lip and palate: complex genetics and environmental effects. Ann Hum Genet. 2001;65:505-15.

JAYPEE BROTHERS

11. Rollnick BR, Pruzansky S. Genetic services at a centre for craniofacial anomalies. Cleft palate J. 1981;18:304-13.
12. Spritz RA. The genetics and epigenetics of orofacial clefts. Curr Opin Pediatr. 2001;13:556-60.
13. Tolarova. Periconceptional supplementation with vitamin and folic acid to prevent recurrence of cleft lip. Lancet. 1982;2:217.
14. Tondury G. On the mechanism of cleft formation. In: Pruzansky S, (Ed). International symposium on congenital anomalies of the face and associated structures (Charles C Thomas: Springfield 1961). 85-101.
15. Wyszynki DF, Maestry N, McIntosh I, et al. Evidence for an association between markers on chromosome 199 and nonsyndromic cleft lip with or without cleft palate in two groups of multiplex families. Hum Genet. 1997;99:22-26.

JAYPEE BROTHERS

for detailed information on surgery books, visit our website **www.jaypeebrothers.com,** for detailed information on surgery bo

Art and Science of

Cleft Lip and Cleft Palate Repair

Salient Features

- A brief and simple text on the subject
- Presents useful description on embryology and anatomy related to cleft lip and cleft palate
- Includes excellent illustrations of cleft lip and palate surgery
- Helps students understand well the various surgical procedures and operative steps of cleft lip and cleft palate surgeries through clinical photographs
- Nerve blocks will help anesthetist to reduce morbidities and mortalities and postoperative pain in patients with cleft lip and palate
- Very useful for the students of plastic surgery and oral surgery.



Girish N Amlani MS (General surgery) MCh (Plastic surgery) is an honorary plastic surgeon at Shri NM Virani Wockhardt Hospital, Sterling Hospital, Sri HJ Doshi General Hospital, Shri GT Sheth Orthopaedic Hospital and Gokul Hospital, Rajkot. He has also rendered his services for cleft lip and palate cases at Gokul Newtech Hospital, Jamnagar, Mahatma Gandhi Institute of Medical Sciences, Vardha, Ramkrishna Sahyadri Hospital, Gandhidham and Wockhardt Hospital, Bhavnagar, Gujarat, India. He has performed more than 4,000 cleft lip and palate cases. He is the main author of the book *Pectoralis Major Myocutaneous Flap in Head and Neck Reconstruction: A Color Atlas*.

Available at all medical bookstores
or buy online at www.jaypeebrothers.com



JAYPEE BROTHERS
Medical Publishers (P) Ltd.
www.jaypeebrothers.com

Join us on facebook.com/JaypeeMedicalPublishers

Shelving Recommendation
SURGERY

