thers.com, for detailed information on pediatric books, visit our website www.jaypeebrothers.com, for detailed information on pediatric books

Practical Pediatric Digest

Publication of IAP Chennai City Branch

Editor-in-Chief
A Parthasarathy

Executive Editor
A Somasundaram

Publication Editor
P Sudhakar

Chief Academic Editors
PSN Menon
MKC Nair
K Nedunchelian
P Ramachandran

Academic Editors
Alok Gupta
S Thangavelu
Jaydeep Choudhury
NC Gowrishankar

Associate Editors
R Remesh Kumar
S Narmada
RV Dhakshayani
Hemchand K Prasad

Ex-Officio Editorial Advisers
R Somasekar
T Muthusamy
S Vasanth Kumar
TN Manohar
S Babu

Forewords
Pramod Jog
Anupam Sachdeva
S Sachidananda Kamath
Major K Nagaraju
R Somasekar

JAYPEE

Contents

1. Newborn **1**
Reviewers: *PSN Menon, Alok Gupta, R Remesh Kumar, K Nedunchelian, Jaydeep Choudhury, RV Dhakshayani*

1.1 Neonatal Sepsis Screen **2**
Giridhar Sethuraman, Satish Datla

1.2 Screening for Inborn Errors of Metabolism **7**
S Mangalabharathi

2. Fluid and Electrolyte **13**
Reviewers: *K Nedunchelian, Jaydeep Choudhury, RV Dhakshayani, P Ramachandran, NC Gowrishankar, Hemchand K Prasad*

2.1 Approach to Arterial Blood Gas Analysis **14**
R Ezhilarasu

2.2 Changing Concepts in Maintenance Fluid Therapy **16**
S Thangavelu

3. Allergy and Immunology **23**
Reviewers: *K Nedunchelian, Jaydeep Choudhury, RV Dhakshayani, P Ramachandran, NC Gowrishankar, Hemchand K Prasad, MKC Nair, S Thangavelu, S Narmada*

3.1 Pediatric Allergy Testing: What, When and How to Do? **24**
S Narmada

3.2 Urticaria: Relieving the Itch **33**
S Narmada

3.3 Investigating a Rheumatologic Disorder: A Pediatrician's Nightmare **38**
Mahesh Janarthanan

4. Infections **45**
Reviewers: *MKC Nair, S Thangavelu, S Narmada, P Ramachandran, NC Gowrishankar, Hemchand K Prasad*

4.1 Investigating Malaria and Typhoid (*Old Wine in a New Bottle*) **46**
U Umadevi

4.2 Diagnostic Armamentarium in Dengue, Leptospirosis and Scrub Typhus **53**
Somu Sivabalan, MVN Malleswari

4.3 Insight into the Tests for Intrauterine Infections **61**
Palani Gunasekaran

4.4 Malaria: Treatment Guidelines **66**
P Ramachandran

4.5 Being Rational with Acute Pharyngotonsillitis **72**
A Somasundaram

5. Neurology **77**
Reviewers: *P Ramachandran, NC Gowrishankar, Hemchand K Prasad, MKC Nair, S Thangavelu, S Narmada*

5.1 Status Epilepticus: What is New in Therapy? **78**
TS Ekambaranath, S Shanthi

5.2 Approach to Single-enhancing CT Lesions **83**
N Thilothammal

5.3 Microbes in Meningitis: Laboratory Diagnosis **89**
T Sivaraman

6. Cardiology **95**
Reviewers: *PSN Menon, Alok Gupta, R Remesh Kumar, MKC Nair, S Thangavelu, S Narmada, K Nedunchelian, Jaydeep Choudhury, RV Dhakshayani*

6.1 X-ray in Pediatric Cardiology **96**
Gnanasambandam Subramaniyan, Vadavil Suhas Das

6.2 Laboratory Backup in Kawasaki Disease and Rheumatic Fever **102**
Gnanasambandam Subramaniyan, J Ritchie Sharon Solomon, Vadavil Suhas Das, Gopala Krishnan

6.3 Timing of Intervention in Congenital Heart Diseases **110**
Gnanasambandam Subramaniyan, J Ritchie Sharon Solomon

6.4 Kawasaki Disease: Therapy Revisited **117**
VV Varadarajan

7. Pulmonology **121**
Reviewers: *PSN Menon, Alok Gupta, R Remesh Kumar, MKC Nair, S Thangavelu, S Narmada*

7.1 The X-ray Chest in the Diagnosis of Respiratory Distress **122**
G Vijayalakshmi, Balakrishnan Natarajan

7.2 Tests for Microbiological Diagnosis in Childhood TB **129**
NC Gowrishankar

8. Gastroenterology **135**
Reviewers: *PSN Menon, Alok Gupta, R Remesh Kumar, K Nedunchelian, Jaydeep Choudhury, RV Dhakshayani*

8.1 Liver Enzymes and Hepatitis Markers: How to Interpret? **136**
Dheivamani Nirmala

8.2 Stool Examination and Cracking Malabsorption Syndromes **142**
Sumathi Bavanandam, P Thirumal

8.3 Constipation **146**
Sumathi Bavanandam

8.4 Neonatal Cholestasis Syndrome **151**
B Bhaskar Raju

8.5 Contrast Studies in Pediatric Gastroenterology **157**
Ganga Devi Rajapandian, Balakrishnan Natarajan

9. Nephrology **165**
Reviewers: *K Nedunchelian, Jaydeep Choudhury, RV Dhakshayani, MKC Nair, S Thangavelu, S Narmada*

9.1 Nephritic and Nephrotic Syndrome: An Investigatory Approach **166**
Sangeetha

9.2 Urinalysis and More in Urinary Tract Infection **169**
A Somasundaram, S Kirupa

10. Hematology **175**
Reviewers: *PSN Menon, Alok Gupta, R Remesh Kumar, MKC Nair, S Thangavelu, S Narmada, K Nedunchelian, Jaydeep Choudhury, RV Dhakshayani*

10.1 ABC of CBC **176**
Ramamurthi Palaniraman

10.2 Acute Phase Reactants: How Do They Help? **180**
P Sudhakar

10.3 Interpretation of Coagulation Tests in Office Practice **185**
M Deenadayalan

11. Endocrinology **191**
Reviewers: *K Nedunchelian, Jaydeep Choudhury, RV Dhakshayani*

11.1 Hypothyroidism and Hypocalcemia: How to Diagnose Early? **192**
Hemchand K Prasad, Umamaheshwari B

11.2 Evaluation of a Child with Short Stature **196**
G Duraiarasan

12. Critical Care **201**
Reviewers: *P Ramachandran, NC Gowrishankar, Hemchand K Prasad*

12.1 Envenomation in Snakebite and Scorpion Sting **202**
Janani Sankar

12.2 Diabetic Ketoacidosis: Thinking Beyond Insulin **207**
V Poovazhagi

13. Radiology **213**
Reviewers: *PSN Menon, Alok Gupta, R Remesh Kumar*

13.1 Reading a Skiagram: Chest **214**
S Muralinath, Mugil Varman Rajasekaran

13.2 Practical Pediatric Nuclear Medicine **219**
Ethiraj Prabhu, Sampath Santhosh

13.3 Computed Tomographic Imaging: What We Need to Know? **225**
Kathirvelu Gopinathan, Karnan Sudha

13.4 Magnetic Resonance Imaging: A Simplified Interpretation **233**
C Amarnath

14. Miscellaneous **243**
Reviewers: *P Ramachandran, NC Gowrishankar, Hemchand K Prasad, PSN Menon, Alok Gupta, R Remesh Kumar*

14.1 Timing of Surgery in Pediatric Surgical Disorders **244**
R Velmurugan

14.2 ROP/Cataract/Squint: When and How to Intervene? **246**
Vasumathy Vedantham

14.3 Skeletal Dysplasias: A Radiographic Approach **252**
M Prabakaran

Index *263*

13

CHAPTER

Radiology

Reviewers: *PSN Menon, Alok Gupta, R Remesh Kumar*

- Reading a Skiagram: Chest
  S Muralinath, Mugil Varman Rajasekaran
- Practical Pediatric Nuclear Medicine
  Ethiraj Prabhu, Sampath Santhosh
- Computed Tomographic Imaging: What We Need to Know?
  Kathirvelu Gopinathan, Karnan Sudha
- Magnetic Resonance Imaging: A Simplified Interpretation
  C Amarnath

JAYPEE BROTHERS

13.1 Reading a Skiagram: Chest

S Muralinath, Mugil Varman Rajasekaran
Reviewers: *PSN Menon, Alok Gupta, R Remesh Kumar*

INTRODUCTION

Radiographs play a pivotal role in the evaluation of respiratory diseases in pediatric practice. Plain radiography is the best and the most commonly performed initial investigation having the least radiation exposure. It is unique in the sense that no other imaging modality offers a two-dimensional planar perspective of the regional anatomy under study. Added to this is the fact that the collective knowledge and cumulative wisdom accrued through decades of practice have honed the art of interpreting plain skiagrams to a state of near perfection. In the current scenario, despite the rapid advances in imaging technology and sophistication in techniques, the plain radiograph is still the first and most important imaging study utilized in the evaluation of lower respiratory tract infections. Its very simplicity and the wealth of diagnostic information that it offers have resulted in its universal acceptance.

The emphasis in this chapter is on a practical systematic approach in interpretation of a skiagram. The image should be interpreted with a sound clinical knowledge and understanding of the core pathology. The following steps are critical in interpretation of skiagrams:

- Assessing technical adequacy of the study.
- Interpretive approach to study a radiograph in a systematic manner.

TECHNICAL ADEQUACY

To begin with, look for the penetration, rotation, adequacy of inspiratory effort and motion. It should be adequately penetrated so that the pulmonary details are well brought out, which is essentially the vascular markings. When the penetration is adequate, the intervertebral disc spaces and the vessels posterior to the heart are seen well. The degree of rotation is evaluated by noting the distance between the center of the vertebral bodies and the lateral aspect of the ribs, thereby evaluating the bilateral symmetry. Classically, aeration or volume of the lungs is assessed by noting the level of the diaphragm. With adequate inspiration, the diaphragm should be at the level of the 6th rib anteriorly or the 8th rib posteriorly and evaluation of the degree of inspiration in infants often is more a matter of experience than science.

An image should always be assessed bearing these factors in mind as these can cause spurious findings which should always be interpreted with caution. For example, retrocardiac consolidation may be missed if there is poor penetration.

INTERPRETIVE APPROACH TO STUDY A RADIOGRAPH IN A SYSTEMATIC MANNER

The radiographic patterns of respiratory diseases vary with the age of the patient and with the pathogenesis and extent of the disease. Review of the entire respiratory disease in pediatrics using radiographs is beyond the scope of this chapter; hence we concentrate mainly on chest infections. Certain anatomical and functional factors that are unique in a child determine the patterns of pulmonary inflammatory disease, sequelae and the radiological appearance. This is reviewed along with the terminology used to describe pulmonary infections in children.

Thymus

The thymus is seen in the superior aspect of the anterior mediastinum. It is prominent on the chest radiograph of an infant as the thoracic cavity is relatively small; however, normal

JAYPEE BROTHERS

variations in radiographic appearances are common. It grows during early childhood to reach a maximum by approximately 15 years of age after which it undergoes regression. Thymus is the most common cause of widened mediastinal shadow, mistaken for mass or consolidation.

Heart

The mediastinum and cardiac contours are relatively large in an infant, and the transverse diameter of a normal heart may approach 60% of the thoracic transverse diameter.

Airways

The small airways of infants are extremely susceptible to inflammatory narrowing. The formation of bronchial tree is complete by 16th week of gestation. Airways in children remain relatively as well as absolutely smaller than in the adult. Conductance (the reciprocal of resistance) of the peripheral airways is at least five times that of the central airways in the adult, but equal to that of the central airways in the infant and young child. Air trapping or atelectasis is common.

Airspace

Alveolar development continues after birth. Alveoli add up to approximately 50–100 million at birth and 300 million in an adult. Saccular proliferation is rapid in the first few years of life, less rapid thereafter and slows after 8 years. The size of the lung acinus varies with age. It is approximately 1 mm in diameter at birth and gradually increases to 6–10 mm in diameter by early adolescence. Destructive pulmonary process or infection during infancy can alter this normal pulmonary alveolar development. Collateral ventilation in the infant is less efficient than in the adult. This is due to the relatively under-developed ventilatory channels (pores of Kohn and channels of Lambert) as well as the thick connective tissue septae and the small alveolar size.

Radiologists usually try to determine whether the disease process has primarily affected the airways or the airspaces and when parenchymal opacities are present as well as whether the abnormality is due primarily to airspace disease or interstitial disease. It is interesting to note that the appreciation of these basic patterns permits an etiologic inference to a good extent. *By and large, acute airway and interstitial disease tend to be viral in origin, whereas acute airspace disease tends to be bacterial in origin more often than not.*

Radiological Pattern and Terminology

The commonly used radiological terms include:

- Airway disease
- Airspace disease
- Airway/Airspace disease

Pneumonia

- *Airspace consolidation:* It is usually bacterial in origin. It can also be seen in viral pneumonia superadded by bacterial infection.
- *Interstitial:* It is viral in origin more often than not.

Patterns in Chest Radiographs

These are usually described as findings in airways and airspaces as shown in **Table 13.1.1**.

RADIOLOGIC FINDINGS IN AIRWAY DISEASES

Chest film may be normal or any or all of the following may be present:

- *Air trapping*
  - Can be diffuse or focal
  - May need expiratory film to assess adequately

Table 13.1.1: Patterns in chest radiographs as seen in airway and airspace

Airway	*Airspace*
• Conducting zone	• Exchange zone
• Intracellular organism	• Extracellular organism
• Infiltrative	• Exudative
• Center to periphery	• Periphery to center

JAYPEE BROTHERS

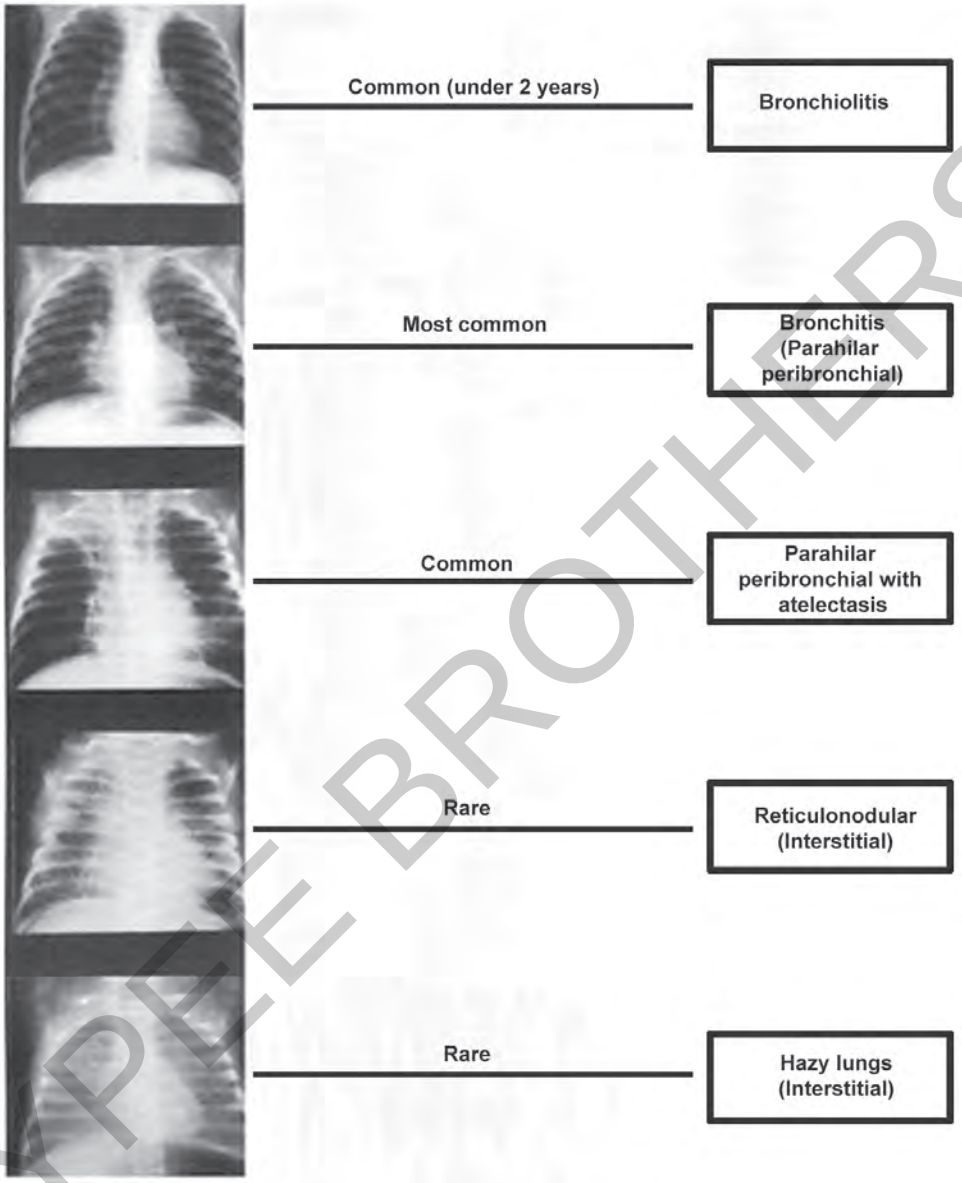

Fig. 13.1.1: Viral lower respiratory tract infections—basic radiographic spectrum

- *Bronchial wall thickening*
  - Ring and tramline shadows
- *Small nodular opacities*
- *Atelectasis*
  - May be streaky and sub-segmental
  - If lobar, right middle lobe is the most common.

Figure 13.1.1 shows the basic radiographic spectrum commonly observed in viral lower respiratory tract infections.

Round pneumonia is a form of airspace consolidation pneumonia peculiar to the pediatric age group. It presents as well-circumscribed round or oval densities. Round pneumonia is

JAYPEE BROTHERS

invariably bacterial in etiology and most often it is the pneumococcal infection that presents as oval or spherical masses in the early consolidative phase. When unaware of this process, it could be baffling and may mislead the clinician to think in terms of pulmonary mass or nodule. The diagnosis is rather simple once the clinical picture is taken into account. Unwarranted further evaluation for pulmonary nodule or mass is done away with once the physician is aware of this entity and appropriate antibiotic therapy will solve the issue.

RADIOLOGICAL APPROACH TO UNILATERAL HYPERLUCENCY

The first step is to identify the side of abnormality. To identify, it one has to follow the following important steps:

- *Look at the pulmonary vasculature.* The side with decreased vascularity is abnormal and the side with increased or normal vascularity is usually normal.
- *Assess the degree of variation between inspiratory and expiratory films.* The side which changes least on expiration is usually abnormal.
- *Finally look at the size of hemithorax.* The small, opaque hemithorax is usually abnormal rather than hyperlucent hemithorax, which in most cases, is due to compensatory hyperinflation **(Flow chart 13.1.1)**. In such situations, one has to again look at vascularity of the hyperlucent side which will not be decreased.

In children a unilateral hyperlucent lung is mostly due to a foreign body which should not be missed.

RADIOGRAPHS IN SUSPECTED CARDIAC DISEASE

Table 13.1.2 lists the common features to be assessed on a chest radiograph in an infant with suspected cardiac disease.

Flow chart 13.1.1: Unilateral hyperlucent hemithorax

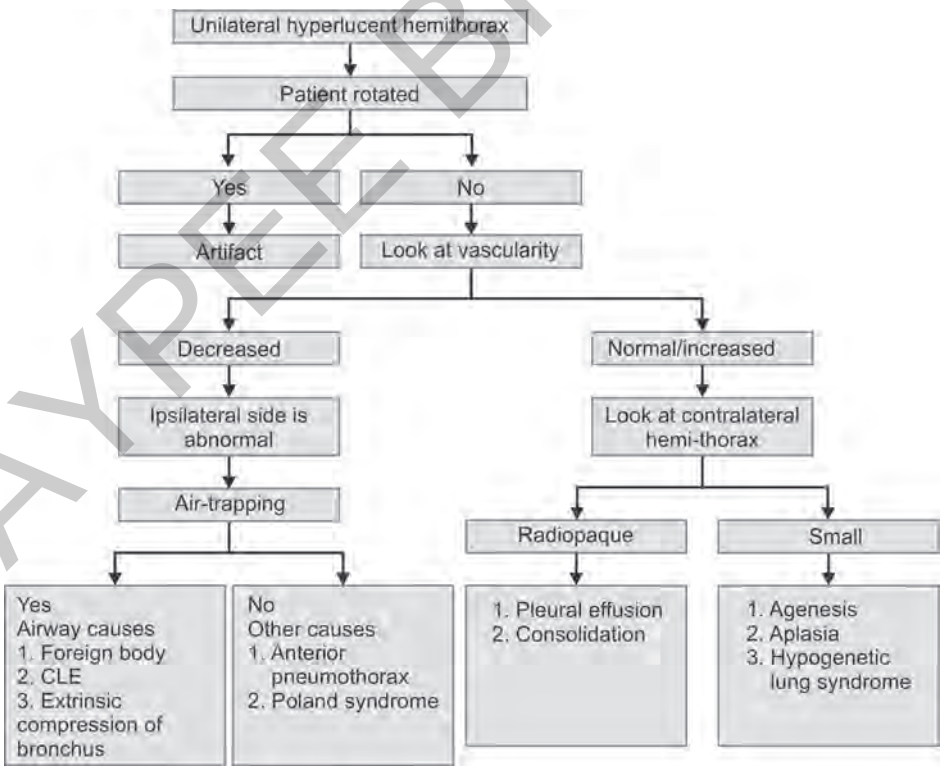

JAYPEE BROTHERS

Table 13.1.2: Features to assess on chest radiograph in infant with suspected cardiac disease

Feature	*Comment*
Quality of film	Adequate inspiration Normal penetration Centered on mid-chest Non-rotation
Abdominal/ Bronchial situs	Normal/inverted/ambiguous
Aortic arch side	Left/right
Heart	Side Direction of apex Size Contour
Lung vasculature	Plethora/Oligemia/Pulmonary venous congestion
Diaphragm	Distinct Diaphragm at the side of cardiac apex should be more caudal
Lung fields	Any pathology
Musculoskeletal	Vertebral/ rib abnormalities Fracture

CONCLUSION

Children are not little adults. Knowledge gained from imaging of the adult cannot be applied to imaging in pediatrics. Awareness of peculiarities in the developmental anatomy and physiology along with a comprehensive knowledge of the pathology and pathophysiology unique to children are essential prerequisites in practice of pediatric imaging.

BIBLIOGRAPHY

1. Arthur R. Interpretation of the paediatric chest X-ray. Current Paediatrics. 2003;13:438-47.
2. Dillman JR, Sanchez R, Ladino-Torres MF, Yarram SG, Strouse PJ, Lucaya J. Expanding upon the unilateral hyperlucent hemithorax in children. Radiographics. 2011;31:723-41.
3. Garcia-Pena P, Guillerman RP. Pediatric Chest Imaging, 3rd edn. Berlin Heidelberg; Springer-Verlag, 2014.
4. Kirks DR. The pediatric ER chest: What every radiologist should know. In: Harwood-Nash DC and Pettersson H (Eds). NICER Series on Diagnostic Imaging; Pediatric Radiology. 1992. pp. 154-75.
5. Kuhn JP, Slovis TL, Haller JO. Caffey's Pediatric Diagnostic Imaging, 10th edn, Pennsylvania; Mosby, 2004.
6. Meerstadt PWD, Gyll C. Manual of Neonatal Emergency X-ray Interpretation, 2nd edn. Philadelphia; WB Saunders, 1995.
7. Rennie JM, Robertson NRC. Textbook of Neonatology, 3rd edn. Philadelphia; Elsevier Churchill Livingstone, 1999.
8. Swischuk LE. Emergency Radiology of the Acutely Ill or Injured Child, 2nd edn. Baltimore; Williams and Wilkins, 1986.
9. Swischuk LE. Imaging of the Newborn, Infant and Young Child, 3rd edn. Baltimore; Williams and Wilkins, 1989.
10. Swischuk LE. Imaging of the Newborn, Infant and Young Child, 5th edn. Baltimore; Lippincott Williams and Wilkins, 2004.
11. Swischuk LE, John SD. Differential Diagnosis in Pediatric Radiology. Philadelphia; Lippincott, Williams and Wilkins, 1995.

JAYPEE BROTHERS

13.2 Practical Pediatric Nuclear Medicine

Ethiraj Prabhu, Sampath Santhosh
Reviewers: *PSN Menon, Alok Gupta, R Remesh Kumar*

INTRODUCTION

Pediatric nuclear medicine is a clinical discipline involving use of open, short-lived, medical grade radioactive substances *in vivo* or *in vitro* in the field of pediatrics for diagnosis, therapy (theragnosis) and research. These radioactive drugs (ligands) emit energy in the form of gamma rays, characteristic X-rays, beta, alpha particles and positrons for a short duration (seconds to minutes). They are administered in very minute quantities (nanogram or picogram) levels and hence are called as 'tracers.'

BACKGROUND

Pediatric nuclear medicine studies were performed as early as in 1946. Nuclear Regulatory Commission in the United States of America reports that more than 1000 nuclear medicine studies were performed on children and adolescents between 1946 and 1948. Subsequent developments were slow till the 1960s because many of the commercially available radioisotopes at that period of time had long half-lives and were also particle emitters which delivered high radiation dose to the tissues. The development of the Gamma camera between 1952 and 1958 by Hal Anger at the Donner Laboratories, California; joining of Alex Gottschalk in University of Chicago in 1962 as well as introduction of radioactive technetium (^{99m}Technetium pertechnetate) by a general surgeon, Paul Harper at the University of Chicago led to rapid development of pediatric nuclear medicine subsequently.

The Department of Nuclear Sciences and Applications of the International Atomic Energy Agency instituted Nuclear Medicine Section as a part of its Human Health Program for establishing best medical practices in nuclear medicine, appropriate use and quality management as well as sharing of expertise among various countries. A nuclear medicine database was initiated in 2007 for collecting and maintenance of updated information among its member countries. It found that on an average over 3 years, annually 25–28% of nuclear medicine studies, were bone scans, 24% were thyroid scans, 17% were renal scans and about 13% were cardiac scans in developing countries. There was a steady (25%) increase in therapeutic applications annually since 2008. During early days, significant contributions in pediatric nuclear medicine were from practitioners of adult nuclear medicine, urologists, oncologists and non-clinical scientists. However, with the current understanding of the varying physiology and strategic needs, there is significant change in the current practice of pediatric nuclear medicine.

PATIENT PREPARATION FOR NUCLEAR MEDICINE STUDIES

In a busy clinical setting, utmost importance is accorded in identification, preparation and scheduling of the patient in any pediatric nuclear medicine facility. The parents are clearly explained about the procedures involved. Support of the pediatrician is sought in terms of fixing IV access and maintenance, optimum hydration and for infant feeding tubes or urinary catheters. Extra time is allotted to complete the procedure because of several unexpected disruptions like difficulty to start an IV line, child refusing to drink adequate water, unhappy, shy and nervous children—especially when it requires undressing and voiding in front of the Gamma camera for performing voiding cysto-urethro-scintigram.

JAYPEE BROTHERS

Table 13.2.1: List of various formulas in current practice

S. No.	Method	Formula
1.	Body surface area-based	(BSA m^2/1.73 m^2) × Adult dose
2.	Clark	(Weight lbs/150) × Adult dose
3.	Solomon (Fried)	(Age in months/180) × Adult dose
4.	Young	(Age in years/age in years + 12) × Adult dose
5.	Weight-based	(Weight in kg/70) × Adult dose
6.	Webster's formula	(Age + 7) adult dose/(age +1)
7.	European Association of Nuclear Medicine Pediatric Dose Card	Baseline activity multiple (based on weight and radiopharmaceutical-dependent factors)

CALCULATION OF THE RADIOPHARMACEUTICAL ACTIVITY IN PEDIATRICS

Optimum administration of radiopharmaceutical has to be ensured in order to get the best possible results in pediatric nuclear medicine practice. At the same time, ALARA (As Low as Reasonably Achievable) practice is strictly followed so as to ensure that only appropriate amount of activity is administered so that the radiation dose delivered to the patient is as low as possible.

Body surface area (BSA) is calculated by applying the following formula:

$$BSA = \text{Weight (kg)}^{0.425} \times \text{Height (cm)}^{0.725} \times 0.007184$$

Table 13.2.1 lists the various methods commonly followed across the world.

Several software ALARA-based formulas are currently available with various vendors to easily determine the safe amount of activity being administered in a busy clinical setting for pediatric patients.

SEDATION AND POSITIONING IN DIAGNOSTIC NUCLEAR MEDICINE PROCEDURES

Every nuclear medicine institution has its own policy of immobilizing the pediatric patients like the use of toys and distractions, counseling, restraints and finally sedatives as a last resort. The policies vary completely from institution to institution when compared with certain established guidelines such as the European Association of Nuclear Medicine (EANM) or Society of Nuclear Medicine (SNM) guidelines. In general, parents are made aware of the method of immobilization of the pediatric patients, possibly with some soft-padded restraints, bundling of sheets, and strategic placement of pillows, etc. failing which, informed consent is obtained and sedation is administered if required with the support of anesthesiologist.

Positioning of pediatric patients for nuclear medicine studies is highly individualized according to the physiological information sought and the purpose of the procedure. Usually positioning is comfortable and the study time is short because of smaller targets, shorter bodies; at times, it can become difficult when the patient is highly uncooperative or continuously moving.

COMMON PEDIATRIC NUCLEAR MEDICINE PROCEDURES

Tables 13.2.2 to 13.2.6 detail the various nuclear medicine studies usually performed in clinical problems related to musculoskeletal system, genitourinary system, endocrine system, gastrointestinal system, and other common systems respectively in children.

PHARMACOLOGICAL INTERVENTION STUDIES

Pharmacological intervention studies are commonly performed in nuclear medicine in order to enhance the physiology and understand

JAYPEE BROTHERS

Table 13.2.2: Musculoskeletal system

S.No.	*Clinical problem*	*Nuclear medicine study*
1.	Evaluation of acute/chronic mono- or polyarthritis, stress/occult fractures, Trauma (accidental/non-accidental), primary or metastatic bone disease, Other musculoskeletal inflammation or infections, evaluating child abuse, Metabolic bone disease, Bone grafting (viability, infarcts, necrosis), Pain of suspected musculoskeletal etiology, Heterotopic calcification, juvenile rheumatoid arthritis, Any abnormal radiological, clinical finding, Osteoblastic activity evaluation for palliative bone pain therapy, Other conditions like Paget's disease, fibrous dysplasia, Langerhan's cell histiocytosis, congenital or developmental anomalies	Radionuclide bone scan ^{99m}Technetium MDP (methylene di phosphonate) or Fluorine 18-sodium fluoride (^{18}F-FDF) 1. Planar scans 2. SPECT scan 3. 3-phase bone scans 4. PET scans 5. Hybrid scans (SPECT/CT; PET/CT)
2.	Differential diagnosis of osteomyelitis and cellulitis, vascularity of bone tumor, reflex sympathetic dystrophy syndrome	Three-phase bone scan and whole body bone scan ^{99m}Tc-MDP
3.	Differential diagnosis of infection or loosening of total hip replacement prosthesis, differential diagnosis of osteomyelitis and cellulitis	Osteomyelitis study (^{99m} Tc-MDP and ^{67}Ga)
4.	Malignant bone tumor, osteogenic sarcoma, Ewing's sarcoma. Evaluate for low-back ache; sacroiliitis in systemic disease such as ankylosing spondylitis, psoriatic spondylitis, osteoarthritis, systemic lupus erythematosus (SLE), Crohn's disease, ulcerative colitis	Whole body bone scan ^{99m}Tc-MDP Quantitative sacroiliac scan (common in adults)

Table 13.2.3: Genitourinary system

S.No.	*Clinical problem*	*Nuclear medicine study*
1.	Glomerular filtration rate (GFR), quantitative renal function, urinary stone, acute renal failure, acute kidney injury, chronic kidney disease, acute and chronic rejection, neurogenic bladder, renal transplant	^{99m}Technetium – MAG3 (mercaptoacetyltriglycine), ^{99m}Tc – EC (ethylenedi-cysteine)
2.	Pyelonephritis, renal scarring, urinary tract infection (UTI), renal infarct, renal trauma, horseshoe kidney, ectopic kidney, renal cyst, renal abscess, renal tumor, relative renal function, fetal lobulation, cortical nodular hyperplasia	^{99m}Tc DMSA renal cortical study with SPECT
3.	Refractory hypertension and study for functionally significant renal artery stenosis	Captopril renogram
4.	Effective renal plasma flow (ERPF), relative renal function, obstructive uropathy, acute tubular necrosis (ATN), transplant renal function	^{99m}Tc MAG3 or ^{99m}Tc EC scan for evaluation of tubular function
5.	Scrotal varicocele, hydrocele, hernias, orchitis, epididymitis, hydrocele	^{99m}Tc RBCs scan
6.	Torsion testis evaluation and epididymo-orchitis with their DDs, hydrocele, hematocele, abscess, acute scrotal pain	$^{99m}TcO_4$ Pertechnetate testicular scan
7.	Renal tuberculosis (TB), UTI	^{67}Ga for renal tumor/inflammation survey and SPECT
8.	Bipedal edema in diabetes, filariasis, trauma, establishing the cause of swelling of lower/upper limbs, sentinel node imaging	^{99m}Tc nanoalbumin or sulfur nanocolloid injection in web space of the digits
9.	Skin viability for skin grafting, identification of suitable site, etc.	^{99m} Tc nanoalbumin intradermal injection

JAYPEE BROTHERS

Table 13.2.4: Endocrine system

S. No.	*Clinical problem*	*Nuclear medicine study*
1.	Goiter, nodule goiter, hyperthyroidism, exophthalmos, Graves' disease, thyroiditis, children with thyroid disease, ectopic thyroid/sublingual thyroid	$^{99m}TcO_4$ thyroid scan – to study the trapping function of the thyroid follicle
2.	Thyroid cancer, sublingual thyroid, intrathoracic goiter, ectopic thyroid, hypothyroidism, thyroiditis, goiter, nodular goiter, hyperthyroidism, exophthalmos, Graves' disease	^{131}I thyroid uptake and low dose (50 microcurie) scan (24 hours)—to study the organification function of the thyroid follicle
3.	Detection of metastasis of thyroid cancer of papillary and follicular types following total thyroidectomy	^{131}I thyroid whole body scan (High dose – 5 millicurie) to study the presence of functioning thyroid metastasis
4.	Treatment of metastasis and thyroid cancer of papillary and follicular types, hyperthyroidism in old age	^{131}I thyroid (therapy dose 70 to 200 millicurie) treatment for differentiated carcinoma of thyroid and 6 to 10 millicurie for toxic goiter
5.	Medullary thyroid cancer, undifferentiated thyroid cancer, breast cancer, osteogenic sarcoma, cancer treatment response	^{99m}Tc (V) DMSA scan, ^{201}Tl scan, ^{68}Ga DOTATATE scan, ^{99m}Tc-SESTAMIBI scan, ^{18}F –FDG PET scan
6.	Hyperparathyroidism, hypercalcemia, parathyroid hyperplasia, parathyroid adenoma, shortened operation time after one or more previous surgical exploration	^{99m}Tc-SESTAMIBI scan for evaluation of parathyroid glands
7.	Cushing's syndrome, aldosteronism, adrenal adenoma, adrenal hyperplasia	NP59 adrenal cortical scan—rarely done in India
8.	Pheochromocytoma, extra-adrenal metastasis, medullary thyroid cancer, paraganglioma, neuroblastoma cardiac failure, lead position in cardiac resynchronization therapy	Adrenal medullary scan with ^{131}I MIBG, ^{99m}Tc HYNIC-TOC scan, ^{18}F –FDG PET scan
9.	Tumor regression and apoptosis	^{99m}Tc HYNICTOC, annexin V scan

the mechanism of dysfunction. These changes may not be obvious and easily observed under basal studies **(Table 13.2.7)**.

CONCLUSION

Pediatric nuclear medicine studies are very helpful in objectively establishing the clinical diagnosis with the help of short-lived, open, unsealed radioligands and sophisticated computerized equipment like the SPECT–CT and the PET–CT. There are significant capital investments involved in establishing a full-fledged department—although, any modern nuclear medicine department can perform almost all the relevant investigations and manage them. Few small items like colorful books, toys and appropriate environment can provide children-friendly atmosphere. Lack of availability of this facility and inadequate exposure of the practicing pediatricians, and unfound fear of radiation injury, are some of the constraints resulting in suboptimal utilization of this specialty. This specialty is now heading towards the development of personalized pediatric nuclear medicine.

JAYPEE BROTHERS

Table 13.2.5: Gastrointestinal system

S. No.	Clinical problem	Nuclear medicine study
1.	Mumps, xerostomia, salivary obstruction, scleroderma, post-radiation therapy, parotid tumor	$^{99m}TcO_4$ salivary gland scintigraphy with vitamin C or lemon drops challenge
2.	Recurrent aspiration or respiratory infections, reflux esophagitis, dysphagia, motility disorders for liquids and solids	^{99m}Tc sulphur colloid dynamic esophageal transit study (Radionuclide milk scan) ^{99m}Tc mebrofenin entero-gastro-esophageal reflux study.
3.	Meckel's diverticulum; Batter's ulcer of esophagus	$^{99m}TcO_4$ Meckel's diverticulum scan
4.	GI bleeding, progressive blood loss – identification of site and quantification Hemangiomas, AV malformations in the liver and the intestines	GI bleed scan with $^{99m}TcO_4$ labeled autologous RBCs, ^{99m}Tc sulphur colloid GI bleed scans
5.	Indian childhood cirrhosis, portal hypertension, liver abscess, liver rupture, congenital anomalies of liver, focal nodular hyperplasia, space-occupying lesions in liver, splenomegaly, splenic infarcts, accessory spleen	^{99m}Tc sulphur colloid/phytate and ^{18}F-FDG PET CT of the abdomen
6.	Acute cholecystitis, biliary atresia, Caroli's disease, neonatal hepatitis, colonic transit studies, biliary leak, biliary reflux, partial liver transplantation, hepatohydrothorax	^{99m}Tc mebrofenin scans
7.	Le–Veen shunt obstruction	^{99m}Tc DTPA shunt patency study

Table 13.2.6: Other common systems in pediatric nuclear medicine

S. No.	Clinical problem	Nuclear medicine study
1.	LV ejection fraction, RV ejection fraction, left to right shunt study with quantification, heart failure, post-chemotherapy, heart transplant recipient, cardiomyopathies, valvular heart disease, aneurysms, vascular anomalies, superior vena cava obstruction, inferior vena cava obstruction, hepatoma	$^{99m}TcO_4$ RBCs radionuclide ventriculography (RNV), first pass RNV, ^{99m}Tc SESTAMIBI scans
2.	Pulmonary embolism, childhood asthma, juvenile COPD, pre-pulmonectomy evaluation, pulmonary hypertension evaluation and lung malignancies	^{99m}Tc macroaggregated albumin (MAA)
3.	Anemia, polycythemia, bone marrow distribution, bone marrow depression, leukemia, ectopic hemopoiesis, bone marrow metastasis	Bone marrow scan with I/V ^{99m}Tc nanoalbumin and ^{32}phosphorus for treatment
4.	Spleen imaging, spleen infarction, spleen abscess, accessory spleen, autosplenosis, spleen trauma, functional asplenism, spleen tumor	Heat denatured ^{99m}Tc autologous RBCs spleen scan
5.	Hodgkin's disease, non-Hodgkin's lymphoma, melanoma, lung cancer, hepatoma, leukemia, gastric cancer, esophageal cancer	^{67}Gallium whole body scan, ^{99m}Tc SESTAMIBI scan for unknown primary, ^{18}F-FDG scan for staging
6.	Seizure disorder, head injury, vasculitis, recurrent brain tumor, craniotrauma, intracerebral bleed, dementia evaluation and radiation necrosis	^{99m}Tc HMPAO, ^{99m}Tc ECD, ^{18}F-FDG scan, ^{201}Tl brain blood flow scan
7.	V–P shunt obstruction, normal pressure hydrocephalus, CSF leakage	^{9m}Tc – DTPA dynamic CSF scan
8.	Ephiphora–nasolacrymal duct function/patency evaluation	^{9m}Tc–DTPA dacryoscintigram

JAYPEE BROTHERS

Table 13.2.7: Pharmacological intervention studies

S.No.	Drug	Mechanism of action	Side effects
Genitourinary system			
1.	Furosemide	Primarily inhibits the absorption of sodium and chloride, almost throughout the nephron	Tinnitus, allergic reactions and contraindicated in anuria
2.	Captopril/Enalapril	Prevents the conversion of angiotensin I to angiotensin II resulting in reduction of GFR	Dry cough, postural hypotension, anaphylactoid reaction, angioedema and contraindicated in pregnancy
3.	Aspirin	Inhibits prostaglandin synthesis and reduces renin secretion	Epigastric distress, nausea, GI bleed
Endocrine system			
4.	rh-TSH	Stimulates radioiodine uptake in the residual thyroid tissue as well as raises serum thyroglobulin levels	Nausea, allergic reaction and a very low risk of tumor stimulation
Gastrointestinal system (GI motility studies)			
5.	Metoclopramide	Dopamine antagonistic, stimulates GI motility, independent of vagus nerve	Nausea, diarrhea, drowsiness, fatigue, extrapyramidal symptoms, tardive dyskinesia. Contraindicated in mechanical obstruction and pheochromocytoma
6.	Erythromycin	Binds to antral and duodenal motilin receptors and initiates phase III of interdigestive motor complex	Nausea, vomiting, diarrhea, jaundice, transient deafness
Meckel's diverticulum imaging			
7.	Ranitidine	Histamine H-2 receptor blocker that inhibits secretion of $^{99m}TcO_4$ (technetium pertechnetate) by mucus and parietal cells	Headache, dizziness, diarrhea, muscular pain, hallucinations and confusions
8.	Pentagastrin	Stimulates uptake of $^{99m}TcO_4$ (technetium pertechnetate) gastric mucosa in the Meckel's diverticulum and stomach	Nausea, vomiting and tachycardia
9.	Glucagon	Reduces peristalsis which allows accumulation of tracer in the Meckel's diverticulum	Nausea, vomiting, weakness, dizziness, hypersensitivity, poor control of blood glucose, pheochromocytoma, insulinoma, glucagonoma
Hepatobiliary scintigraphy			
10.	Cholecystokinin–8	Stimulates contraction of gallbladder and simultaneously relaxes the sphincter of oddi	Abdominal pain, urge to defecate, flushing, dizziness, allergic reaction
11.	Morphine	Constricts sphincter of oddi and increases the pressure within the sphincter and the CBD	Respiratory depression, nausea, vomiting, hypotension, dysphoria, urinary retention and contraindicated in COPD and chronic liver disease
12.	Phenobarbitone	Induces the hepatic enzymes and enhances the radiotracer uptake and biliary excretion	Sedation, anxiety

JAYPEE BROTHERS

for detailed information on pediatric books, visit our website **www.jaypeebrothers.com,** for detailed information on pediatric books, visit our w

Practical Pediatric Digest


A Parthasarathy


A Somasundaram


P Sudhakar


PSN Menon


MKC Nair


K Nedunchelian


P Ramachandran


Alok Gupta


S Thangavelu


Jaydeep Choudhury


NC Gowrishankar


R Remesh Kumar


S Narmada


RV Dhakshayani


Hemchand K Prasad

Salient Features

- A unique book which contains 42 selected topics in pediatric and adolescent care presented in various continuing medical educations (CMEs) with updated practical guidelines in management and diagnosis
- Contributors of national fame have burnt midnight oil to present the text in a reader-friendly format
- Designed to serve as a Desk-Top reference volume for practitioners, faculty and medical students as well
- Contains selected topics covering newborn to adolescent care
- All the topics covered have undergone review and edit process at three different levels by a formidable team of editors of national fame

Available at all medical bookstores
or buy online at www.jaypeebrothers.com

JAYPEE BROTHERS
Medical Publishers (P) Ltd.
www.jaypeebrothers.com
Join us on facebook.com/JaypeeMedicalPublishers

Shelving Recommendation
PEDIATRICS

ISBN 978-93-86150-86-8
9 789386 150868