iled information on anatomy books, visit our website **www.jaypeebrothers.com,** for detailed information on anatomy books, visit our website **www.jaypeebrothers.com**

HISTOLOGY

Laboratory Manual

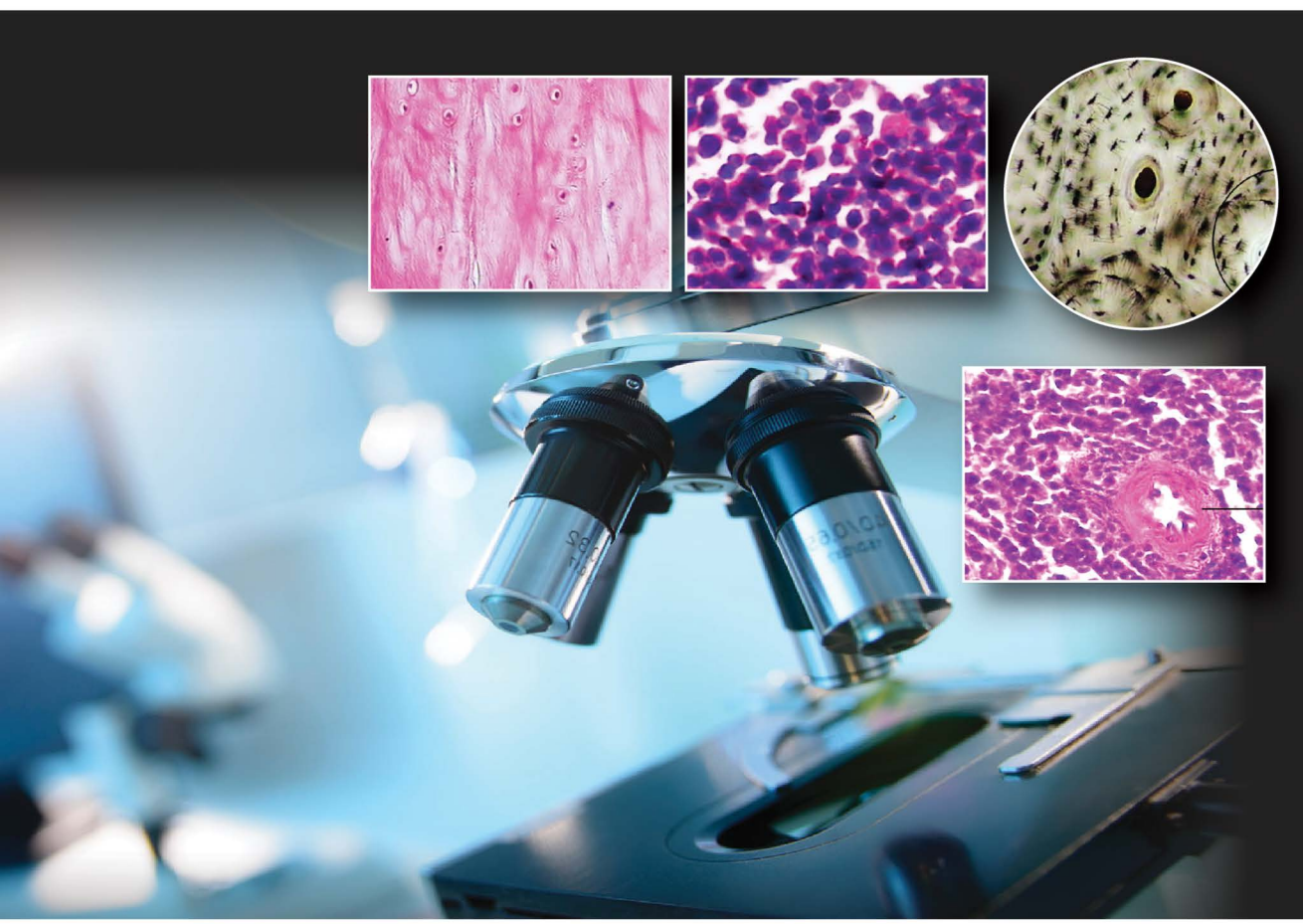

Sayee Rajangam
Leelavathy N
RN Kulkarni

Foreword
Flossie Jayakaran

JAYPEE

Contents

1. Microscope 1
- Frame *1*
- Illuminating System *1*
- Magnifying System *1*
- Total Magnification *1*

2. The Cell 3

3. Epithelial Tissue 4
- Shape *4*
- Stratification *4*
- Specializations *4*

4. Connective Tissue 7
- Loose Connective Tissue *8*
- Cartilage *8*
- Bone *14*

5. Muscular Tissue 19
- Smooth Muscle *19*
- Skeletal Muscle *20*
- Cardiac Muscle *23*

6. Nerve Tissue 26
- Peripheral Nerve *26*
- Dorsal Root or Spinal Ganglion *26*
- Sympathetic Ganglion or Autonomic Ganglion *29*

7. Vascular Tissue 32
- Arteries *32*
- Veins *32*
- General Arrangement of the Layers in the Walls of the Arteries and Veins *32*
- Muscular Artery or Medium-sized Artery *33*
- Large Artery or Elastic Artery *35*
- Large Vein *36*

8. Lymphatic Tissue 39
- Lymph Node *39*
- Thymus *41*
- Tonsil *42*
- Spleen *44*

9. Glandular Tissue 49
- Serous Salivary Gland *50*
- Mucous Salivary Gland *50*
- Mixed Salivary Gland *52*

10. Integumentary Tissue 56
Thin Skin *58*

11. Respiratory System 61
- Trachea *61*
- Lung *62*
- Differences between the Parts of Bronchial Tree *67*

12. Digestive System 68
- Tongue *68*
- Esophagus *72*
- Stomach *74*
- Small Intestine *79*
- Large Intestine *83*
- Appendix *84*
- Liver *88*
- Gallbladder *91*
- Pancreas *91*

13. Urinary System 96
- Kidney *96*
- Ureter *98*
- Urinary Bladder *100*

14. Male Reproductive System 104
- Testes *104*
- Epididymis *106*
- Ductus Deferens or Vas Deferens *107*
- Prostate *109*

15. Female Reproductive System 113
- Ovary *113*
- Uterine Tube *116*
- Uterus *117*
- Placenta *120*
- Umbilical Cord *121*

16. Endocrine Glands 125
- Hypophysis Cerebri *125*
- Thyroid and Parathyroid *127*
- Adrenal Gland *129*

17. Eye 135
- Cornea *135*
- Retina *138*
- Optic Nerve *140*

18. Central Nervous System 143
- Spinal Cord *143*
- Cerebrum *145*
- Cerebellum *147*

Bibliography 151

Index 153

CHAPTER

3

Epithelial Tissue

- Epithelial tissue is comprised of uninterrupted layers of cells and covers nearly all the external and internal surfaces of the body.
- Epithelium is the derivative of ectoderm, mesoderm and endoderm.
- Epithelial cells are mostly classified by the shape, the layers, i.e. stratification and the specializations on the surface (cilia/microvilli).
- Cells resting on basement membrane are tightly linked to each other.
- Cells polar in nature have apical and basal parts.
- Cells are avascular, but have high regenerative capacity.

SHAPE

- *Squamous*: Thin and flat
- *Cuboidal*: Short cylinders, but from the side appears like cubes
- *Columnar:* Looks like columns or cylinders.

STRATIFICATION

- *Simple*: One layer of cells
- *Stratified*: Two or more layers, one stacked above the basement layer
- *Pseudostratified*: One layer, but irregular lengths.

SPECIALIZATIONS

- Keratinized cells contain the protein, keratin
- Ciliated cells have the cilia.

Types	*Simple squamous epithelium (Fig. 3.1A)*	*Simple cuboidal epithelium (Fig. 3.1B)*	*Simple columnar epithelium (Fig. 3.1C)*
Cells	• One cell layer • All cells rest on the basement membrane • Width and depth of the cells greater than the height • Pavement epithelium • Regular hexagonal pattern	• One cell layer • All cells rest on the basement membrane • Cells cuboidal in shape • Width, depth and height are of the same dimensions	• One cell layer • All cells rest on the basement membrane • Height of the cells more than the depth and width
Nuclei	Flat or round or oval in shape, central in position	Centrally placed spherical nuclei	Oval elongated nuclei, towards the base of the cells
Function	Diffusion of gas or fluid	Absorption, excretion secretion	Absorption, secretion
Example	Mesothelium (peritoneal, pleural and pericardial cavities), Endothelium (heart, blood and lymph vessels), alveoli of lung	Collecting tubules of kidney, small excretory ducts of salivary glands and pancreas	Stomach, small intestine, gallbladder

Types	*Pseudostratified ciliated columnar epithelium/respiratory epithelium (Fig. 3.1D)*	*Transitional epithelium/urothelium (Fig. 3.1G)*
Cells	• Single layer of cells with cilia • All cells rest on the basement membrane, but short cells do not extend to the lumen	In the relaxed state, cells in the • Deep layers, cuboidal • Intermediate layers, polygonal • Superficial layers, large umbrella shaped cells In the stretched state, cells in the intermediate and surface layers, flattened
Nuclei	At different levels	Round or oval Cells may be multinucleated and covered by glycocalyx
Function	Propulsion of the mucus and the trapped particles to the pharynx	Accommodation of stretch and withstanding the toxicity of the urine
Example	Trachea	Ureter, urinary bladder

Types	*Stratified squamous nonkeratinized epithelium (Fig. 3.1E)*	*Stratified squamous keratinized epithelium (Fig. 3.1F)*
Cells	2 or more cell layers, only the basal cells rest on the basement membrane Cells in the • Deep layers, cuboidal or columnar • Intermediate layers, polyhedral • Superficial layers, squamous	Structure same as in the stratified squamous nonkeratinized epithelium, except for the superficial cells consisting of the protein keratin, dead and fibrous
Nuclei	All cells are nucleated	All cells, except the cells in the superficial layers, nucleated
Function	Withstanding the abrasion	Withstanding the abrasion and dessication
Example	Esophagus	Thick skin

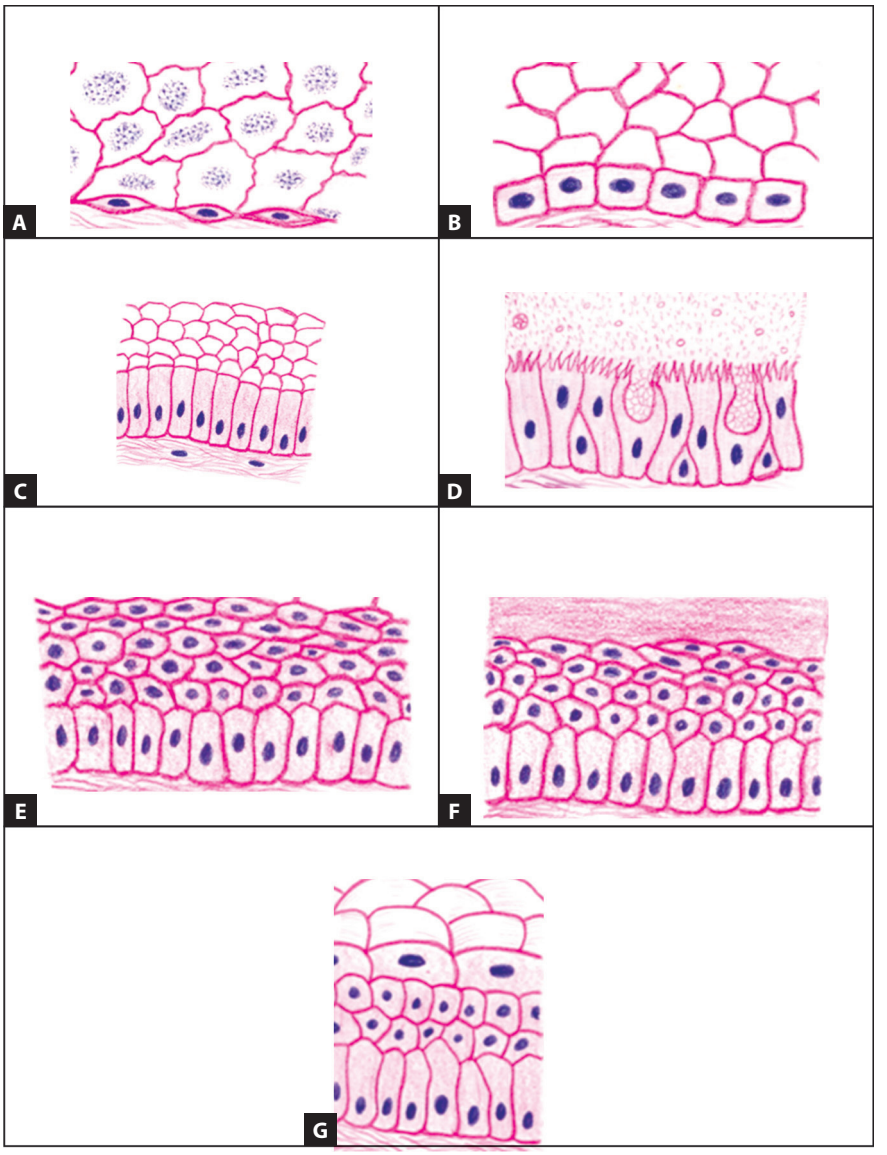

FIGURES 3.1A TO G Epithelial tissue. (A) Simple squamous epithelium; (B) Simple cuboidal epithelium; (C) Simple columnar epithelium; (D) Pseudostratified ciliated columnar epithelium; (E) Stratified squamous nonkeratinized epithelium; (F) Stratified squamous keratinized epithelium; (G) Transitional epithelium (urothelium)

for detailed information on anatomy books, visit our website **www.jaypeebrothers.com,** for detailed information on anatomy books, visit our website **www.jaypeebroth**

HISTOLOGY: Laboratory Manual

Salient Features

- An overview of the topic is given at the start of the chapter; hence the topics become understandable.
- The microscopic pictures are captured under the scanner, low power and high power of the same field and labeled in detail, so that each part could be understood.
- The well-labeled pictures of the tissues and or organs are also narrated as per whether they are under scanner or low power or high power; which definitely is of great help to Postgraduates in Anatomy.
- At the end of the chapters, a precise summary is given in the form of table or points which are easy to grasp in the last minute and can be reproduced.'



Sayee Rajangam served St John's Medical College, Bengaluru, Karnataka, India, in various positions from 1971 to 2007. She was Professor and Head, Division of Human Genetics, St John's Medical College, Bengaluru. From 2008 to 2014, she worked as Professor of Anatomy in International Medical School, Bengaluru. Her fields of interest are anatomy, cytogenetics and medical education. To her credit, she has several awards—Best Researcher Award, Faculty Brand Awards, Kolkata (2015),15th Karnataka Chapter of Anatomists, Bengaluru (2013), Oration on 'Phenomenon of Nondisjunction', Golden Jubilee Year of St John's Medical College, St John's National Academy of Health Sciences, Bengaluru, felicitation to Teachers (2013), Award of Excellence for Women Staff, International Women's Day, MS Ramaiah Memorial Hospital, Gokula Education Foundation (M), Bengaluru (2012), Dr SP Jain Memorial Oration, National Anatomical Society of India, Belagavi (2009), St John's National Academy of Health Sciences Incentive Scheme for publications in Indexed Journals (4 times), (1998–2007), Award of Excellence for Social Harmony (2005), Shristi Special Academy, Bengaluru. She was guide and co-guide for 10 PhD students and 5 MS students. She has been life member in 48 various organizations, delivered 206 invited lectures, handled 166 research projects, written/edited 32 books, and published 225 articles in various national and international peer-reviewed journals.



Leelavathy N worked in St John's Medical College, Bengaluru from 1995 to 2008. She then joined International Medical School (2009) as an Assistant Professor. At present, she is working as Professor in Sapthagiri Institute of Medical Sciences and Research Center, Bengaluru. Her fields of interest are anatomy and genetics. She has received SS Misra Memorial Award for best unpublished work titled Genetic Studies in Patients with Primary Menorrhea from National Academy of Medical Sciences. She has 20 publications in national and international peer-reviewed journals and is co-author for 10 books.



RN Kulkarni passed his BSc (1966), Government Arts and Science College, Kalaburagi, Karnataka, India, and completed MBBS (1973) from MR Medical College, Kalaburagi. He joined Mahatma Gandhi Institute of Medical Sciences (MGIMS), Sewagram, Wardha, Maharashtra, as Lecturer in Anatomy (1975), and completed MS (Anatomy) from the same institute in the year 1980. He served in MS Ramaiah Medical College, Bengaluru, as Professor (1992), Professor and Head (1995) and Senior Professor and Head (2002). He has been postgraduate guide under Bangalore University and Rajiv Gandhi University of Health Sciences (RGUHS), Karnataka. He joined International Medical School, under the MS Ramaiah Group of institutions as Professor and Head of Anatomy (2006–2013). He has published many papers in national and state journals. He has been life member of Indian Medical Association (IMA), Archaeological Survey of India (ASI) and Karnataka Chapter of Anatomists.

Available at all medical bookstores
or buy online at www.jaypeebrothers.com

JAYPEE
JAYPEE BROTHERS
Medical Publishers (P) Ltd.
www.jaypeebrothers.com

Join us on facebook.com/JaypeeMedicalPublishers

Shelving Recommendation
ANATOMY

ISBN 978-93-86150-94-3