halmology books, visit our website www.jaypeebrothers.com, for detailed information on ophthalmology books

Textbook of Pterygium Management

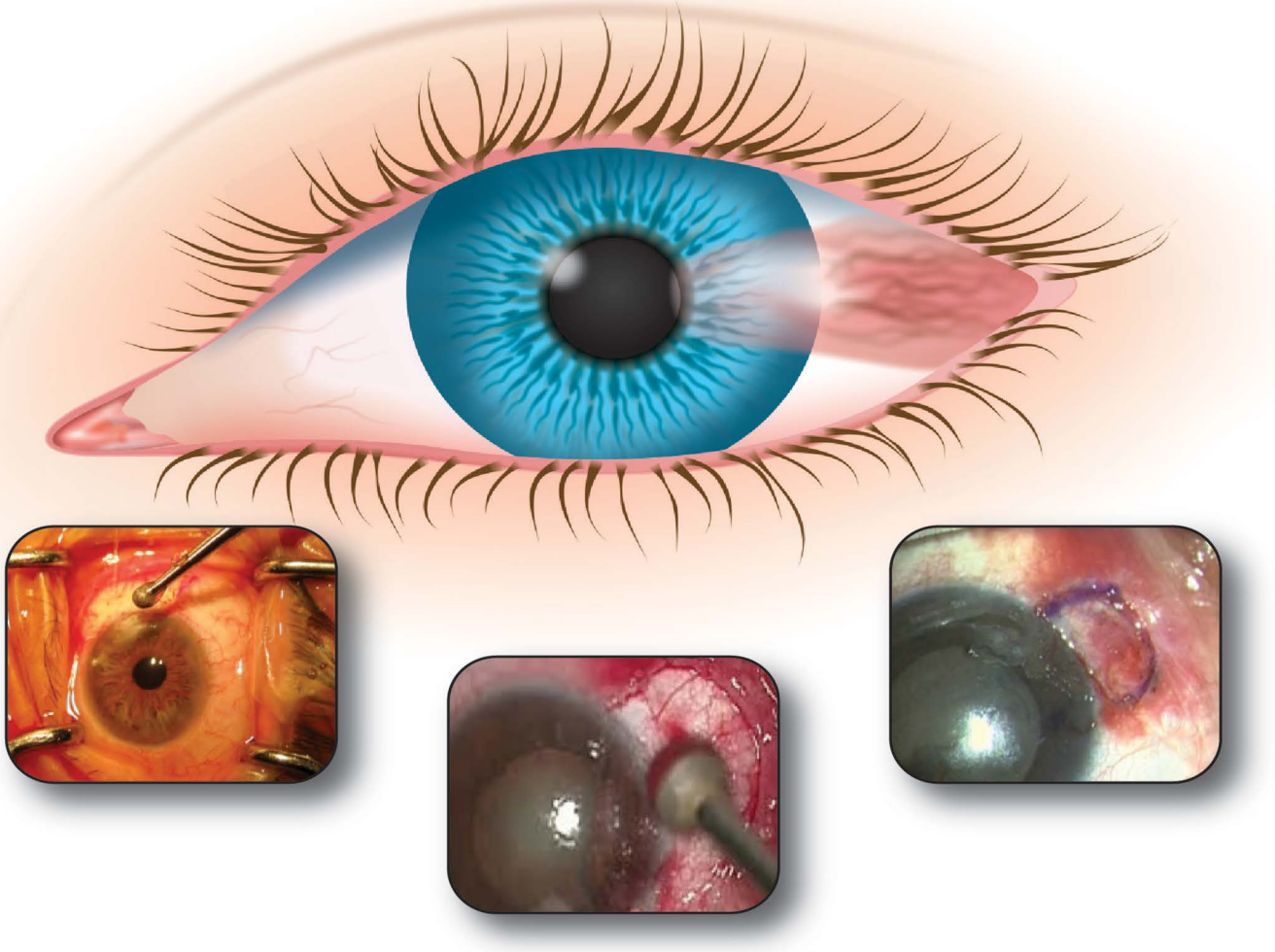

Editors
Tushar Agarwal
Shikha Gupta
Namrata Sharma

Includes Interactive DVD-ROM

JAYPEE

Contents

SECTION I PTERYGIUM: WHAT, WHY AND WHEN?

1. **Etiopathogenesis of Pterygium** 3
Shikha Gupta, Tushar Agarwal
◆ Ultraviolet Radiations *3* ◆ Angiogenesis and Inflammation *4*
◆ Lymphangiogenesis *4* ◆ Tumorigenesis *4* ◆ Genetics *5*

2. **Workup of a Case of Pterygium** 9
Shikha Gupta, Tushar Agarwal
◆ Clinical History Taking in a Case of Pterygium *9*
◆ Counseling Patient Regarding Expectations from Pterygium Excision *13*

SECTION II SURGICAL MANAGEMENT OF PTERYGIUM

3. **Pterygium Excision with Conjunctival Autografting Using Glue** 17
Tushar Agarwal, Shikha Gupta, Namrata Sharma
◆ Indications *17* ◆ Advantages and Disadvantages *17* ◆ Surgical Procedure *18*

4. **Pterygium Excision with Conjunctival Autograft (Suture Technique)** 27
Elsie Chan
◆ Technique *27* ◆ Results *28* ◆ Complications *29*

5. **Conjunctival Excision and Extended Tenectomy with Conjunctival Autograft for Primary Pterygium** 31
Chintan Malhotra, Arun K Jain, Vikash Rohilla
◆ Indications *31* ◆ Current Role *31* ◆ Surgical Steps for Crater Technique *32*

6. **Pterygium Excision with Inferior Conjunctival Autografting** 37
Qi Chen, Fan Xu, Min Li, Li Jiang, Jiping Xu
◆ Indications *37* ◆ Current Role *37* ◆ Outcomes *37* ◆ Surgical Technique *37*

7. **Pterygium Excision with Narrow-strip Conjunctival Autograft** 42
Angelique Pillar, Bennie H Jeng, David M Meisler, William J Dupps
◆ Indications *42* ◆ Outcomes *42* ◆ Surgical Technique *43*

8. **Conjunctival Excision with Autograft Using Sandwich Technique** 45
Ali Fadlallah, Marc Fava, Steve Robinson, Catherine Choi, Georges El Mollayess, Samir Melki
◆ Indications *45* ◆ Current Role *45* ◆ Outcomes *45* ◆ Surgical Technique *46*

9. **Pterygium Surgery with Autograft Affixation Using Blood** 48
Kanhaiya Mittal, Shikha Gupta, Tushar Agarwal
◆ Indications *48* ◆ Current Role *48* ◆ Outcomes *49* ◆ Surgical Technique *50*

10. Pterygium Excision by Mini-flap Technique 53
Kyoung Yul Seo, Sang Min Nam, Ji Won Jung
◆ Indications 53 ◆ Current Role 54 ◆ Outcomes 54 ◆ Surgical Technique 54

11. Conjunctival Excision with Amniotic Membrane Grafting with or without Sutures 58
Prafulla Kumar Maharana, Namrata Sharma
◆ Rationale for Use 58 ◆ Indications 58 ◆ Surgical Technique 59
◆ Complications 60 ◆ Outcomes 61

12. Minor Ipsilateral Simple Limbal Epithelial Transplantation 64
Erick Hernandez-Bogantes, Enrique O Graue-Hernandez
◆ Principle of Mini-SLET 64 ◆ Indications 64 ◆ Surgical Technique 64

13. Antimetabolites in Pterygium Management 67
Puneet Jain, Shikha Gupta, Tushar Agarwal
Mitomycin C 67
◆ Indications 67 ◆ Contraindications 67 ◆ Advantages and Disadvantages 67 ◆ Outcomes 68 ◆ Preparation and Uses 68
5-Fluorouracil 71
◆ Indications 71 ◆ Contraindications 71 ◆ Advantages and Disadvantages 71 ◆ Outcomes 71 ◆ Preparation and Uses 71

14. Antivascular Endothelial Growth Factor Agents 74
Shikha Gupta, Puneet Jain, Tushar Agarwal
◆ Indications 74 ◆ Contraindications 74 ◆ Advantages and Disadvantages 74 ◆ Outcomes 75 ◆ Preparation and Uses 77

15. Adjunctive Therapy in Pterygium Management 79
Puneet Jain, Shikha Gupta, Tushar Agarwal 79
◆ Beta Irradiation 79 ◆ Interferon Alpha-2b (IFN α-2b) 81 ◆ OLOGEN® 82

SECTION III MANAGEMENT OF RECURRENT PTERYGIUM

16. Conjunctival Excision with Limbal Conjunctival Autograft or Amniotic Membrane Grafting, with or without Mitomycin-C in Recurrent Pterygium 85
Tarun Arora, Shikha Gupta, Tushar Agarwal
◆ Indications 85 ◆ Current Role 85 ◆ Outcomes 85 ◆ Surgical Technique 85

17. Combined Ipsilateral Autologous Limbus and Homologous Amniotic Membrane Transplantation for Recurrent Symblepharopterygium 89
Berthold Seitz, Cord RH Huchzermeyer
◆ Indications 90 ◆ Advantages and Disadvantages 90 ◆ Surgical Techniques 90
◆ Outcomes 91

18. Sealing the Gap for Managing Pterygium 94
Anny MS Cheng, Wei-li Chen, Scheffer CG Tseng
◆ Principle Behind the Technique 95 ◆ Advantages of Using Amniotic Membrane Transplant 96 ◆ Surgical Technique 97 ◆ Postoperative Care 103

SECTION IV CHALLENGING SITUATIONS IN PTERYGIUM MANAGEMENT

19. Double-headed Pterygium: Split Conjunctival Grafts 107
Neelima Aron, Shikha Gupta, Tushar Agarwal

◆ Indications of Split Conjunctival Grafting *107* ◆ Advantages of Split Conjunctival Grafting *107* ◆ Disadvantages of Split Conjunctival Grafting *107* ◆ Surgical Technique *107* ◆ Outcomes *111*

20. Management of Pterygium with Coexisting Cataract 112
Koray Gumus, Cynthia I Tung, Zaina Al-Mohtaseb

◆ The Impact of Pterygium on Visual Parameters *112* ◆ Simultaneous Pterygium and Cataract Surgery *113* ◆ Timing of the Cataract Surgery: Before or After the Pterygium Excision *113* ◆ Surgical Technique for Pterygium Surgery *114*

21. Management of Corneal Opacity after Pterygium Surgery 117
Manpreet Kaur, Anubha Rathi, Tushar Agarwal

◆ Predisposing Factors *117* ◆ Prevention *117* ◆ Preoperative Considerations *118* ◆ Management *118*

22. Management of Pterygium with other Coexisting Ocular Surface Conditions 121
Pooja Bandivadekar, Tushar Agarwal, Shikha Gupta

Pterygium and Ocular Surface Squamous Neoplasia 121
◆ Indications *121* ◆ Investigations *121* ◆ Management *121*

Corneal Opacity and Pterygium 123
◆ Management *123*

23. Pterygium and Glaucoma 125
Shalini Mohan, Mohit Khattri, Surendra Kumar Sachan

◆ Timing of Surgery *125* ◆ Preoperative Considerations and Evaluation *125*

24. Complications after Pterygium Surgery 128
Manpreet Kaur, Shikha Gupta, Namrata Sharma

◆ Graft-related Complications *128* ◆ Host and Donor Site Complications *132*
◆ Generalized Ocular Side Effects *134*

25. Autologous Advanced Tenon Grafting Combined with Conjunctival Flap for Scleromalacia 136
Jong-Soo Lee

◆ Materials for Ocular Surface Reconstruction *136* ◆ Indications *137*
◆ Advantages and Disadvantages *137* ◆ Surgical Technique *137*
◆ Postoperative Care *138* ◆ Outcomes *139*

26. Tectonic Lamellar Graft in Post Pterygium Surgery Corneoscleral Melt 142
Anubha Rathi, Manpreet Kaur, Shikha Gupta

◆ Clinical Presentation *142* ◆ Pathophysiology *142* ◆ Approach to Management *142* ◆ Surgical Technique *143* ◆ Outcomes *144*

Index *147*

Chapter 4

Pterygium Excision with Conjunctival Autograft (Suture Technique)

Elsie Chan

INTRODUCTION

Until the mid-1980s, pterygium excision leaving bare sclera was the most widely performed procedure for management of pterygia. Despite the simplicity of the technique, it resulted in an unacceptably high rate of recurrent pterygia. This led to the subsequent rise in popularity of pterygium excision followed by a conjunctival autograft, a technique popularized by Kenyon. The use of a conjunctival autograft has now become standard practice for the surgical management of primary or recurrent pterygia. While it takes more time to learn and to perform, it is a more effective and safe procedure, with a significantly lower recurrence rate.

The conventional technique of pterygium excision with a conjunctival autograft technique uses sutures to secure the autograft to the limbus and underlying sclera. This chapter will cover the surgical technique, results and complications associated with the surgery.

TECHNIQUE

Pterygium excision with a conjunctival autograft can be performed as a day case procedure. Usually, topical anesthesia combined with subconjunctival infiltration with a local anesthetic agent is sufficient for the procedure. Periocular (i.e. peribulbar or retrobulbar) anesthesia is recommended in cases of recurrent pterygia where significant scarring occurs or where it is the surgeon's and patient's preference. Where periocular anesthesia is used, a traction suture in the superior location is helpful if a surgical assistant is not available.

To excise the pterygium, the body is dissected 2–4 mm from the limbus, taking care to ensure that the superior and inferior extent of the pterygium is completely excised to avoid recurrence from these areas. The body is then reflected to allow dissection of the head of the pterygium from the cornea. For primary pterygia, pulling on the head or blunt dissection is often sufficient. However, in recurrent pterygia, more careful dissection is required with a Beaver or crescent blade. Residual fibrovascular tissue should then be dissected off the scleral bed. Removal of the Tenon's layer should also be performed beyond the conjunctival edge. In recurrent pterygia, identification of the rectus muscle using a muscle hook may be prudent during this step as the presence of scarring may disrupt normal anatomical planes. Minimal or no cautery is usually required for hemostasis for primary pterygium excision although is usually necessary in recurrent pterygia.

The area of bare sclera is measured using calipers. The globe is rotated downwards and a gentian violet ink marker used to outline the size of the superior conjunctival autograft that is required, usually 1 mm wider and longer than the scleral defect. Subconjunctival local anesthetic is then injected in this area. The conjunctival graft is then harvested: after an initial, small incision in the epithelial layer, blunt dissection using Westcott (or similar) scissors can allow the successful separation of the conjunctival layer from the underlying Tenon's layer. Care should be taken not to cause button holing of the conjunctiva. Rarely, a graft from the inferior conjunctiva or from the superior conjunctival of the contralateral eye may be required, such as in cases where a trabeculectomy is present. The graft is then placed over the bare sclera and oriented with the epithelial-side upwards, and with the limbal edge adjacent the limbus of the recipient site.

The autograft is then secured into position using sutures. The choice of sutures commonly includes 8/0, 9/0 or 10/0 polyglactin (e.g. Vicryl, Ethicon) or 10/0 nylon, depending on surgeon preference. Four interrupted sutures are placed in the cardinal positions-superiorly and inferiorly along the limbus and then the remaining two peripheral corners. Each cardinal suture should include the underlying episclera to anchor the autograft into place, preventing its movement with ocular movements following surgery. For the two peripheral corners, it is also important to avoid fibers of the underlying rectus muscle and large episcleral vessels. The limbal edge of the graft does not usually require further sutures, although some surgeons choose to place an additional single suture at the central limbus, to prevent forwards or backwards displacement. The remaining free edges of the autograft are then apposed to the host conjunctival margin using interrupted sutures. These sutures can remain unburied.

As an alternative to interrupted sutures, a continuous suture can be used alone, or in combination with interrupted sutures. Where a continuous suture is used alone, anchoring

JAYPEE BROTHERS

passes through the episclera at each of the four corners of the graft are still recommended for stabilization.

The operating time for a pterygium excision with a sutured conjunctival graft typically ranges between 20 and 90 minutes, with more time required for complex cases such as recurrent pterygia where there is significant scarring requiring careful dissection. In case of double-headed pterygia, sequential operations are normally advised to allow re-epithelialization of the superior conjunctiva, thus permitting the use of an autograft for both pterygia.

Postoperatively, antibiotic and corticosteroid drops are prescribed. Antibiotic drops can be ceased after re-epithelialization of the cornea and conjunctiva, although corticosteroid drops should be continued for at least one month, with more extended corticosteroid use required in cases with a higher risk of recurrence such as in recurrent pterygia or in the presence of significant inflammation. The patient should also be instructed not to rub their eye to avoid dislodging the graft. Nylon sutures can be removed after 10–14 days. Remaining polyglactin sutures should also be removed to minimise ongoing discomfort and inflammation, the latter of which may promote recurrence of the pterygium. Apart from surgeon's preference, the choice of sutures should also take into consideration the degree of discomfort associated with removing sutures in some patients.

RESULTS

Pterygium excision with a sutured conjunctival autograft provides an excellent cosmetic result compared to other techniques such as primary closure and amniotic membrane grafting. While it requires more operating time than bare sclera excision and primary conjunctival closure, the primary advantage in this technique is its significantly reduced recurrence rate.

Recurrence is the most important outcome measure following pterygium surgery. Recurrence is typically defined as any fibrovascular proliferation extending more than 1 mm onto the cornea from the original pterygium site. A wide range of recurrence rates ranging from 0.4% up to 39% have been reported, although a rate of less than 15% is more common. Up to 90% of recurrences occur within the first year, and thus follow-up for at least 12 months following surgery is recommended. The recurrence rate for recurrent pterygia is usually higher, with Luanratanakorn et al. reporting a rate of 21.4% for recurrent pterygia, compared to 12.3% for primary pterygia in their series.

The recurrence rates using a conjunctival autograft compares favorably to the rates following bare sclera excision, where recurrence rates of up to 80% are reported. Tan et al. report a recurrence rate of 61% for primary pterygia and 82% for recurrent pterygia, whereas De Keizer et al. report a 68% recurrence rate within 4 months. The addition of an intraoperative antimetabolite such as mitomycin C may reduce the recurrence rate with bare sclera excision but remains more than double the rate following a conjunctival autograft (38% versus 15% respectively reported by Koranyi et al.). The use of beta radiation may reduce the rate of recurrence even further to 4% although there are associated risks of long-term complications. Recurrence rates following conjunctival autograft are also lower compared to primary closure and after pterygium excision with amniotic membrane grafting. Prabhasawat et al. reported a recurrence rate of 45% and a mean time to recurrence of 3.7 months following primary closure and a rate of 10.9% after a mean of 4.1 months after amniotic membrane grafting, compared to a rate of 2.6% after a mean of 11.1 months following conjunctival autograft.

The wide range of recurrence rates following pterygium surgery may be due a number of factors. These include different environmental factors, as the amount of ongoing sun exposure following surgery may impact on regrowth. Patient age may also be a factor, with some studies reporting that a younger age increases the risk of recurrence. However, this may also be due to the greater likelihood of more fleshy pterygia in younger patients compared to atrophic pterygia in the older age group, as pterygium morphology may affect recurrence rate. Different surgical techniques may also affect the recurrence rate as a more extended Tenon's layer dissection may lead to a reduced risk. However, the size of the autograft (>1 mm, within 1 mm or less than 1mm than the scleral bed) has not been shown to affect the recurrence rate. Postoperatively, differing topical corticosteroid regimens may affect recurrence. In the published literature, variable recurrence rates may also be related to reported sample sizes and lengths of follow-up.

The possible influence of the size and type of suture on recurrence rates has also been studied. Early publications involving conjunctival autografts used larger sutures such as 7/0 polyglactin. However, smaller sutures became more widely used due to decrease in postoperative discomfort. Some surgeons prefer using 10/0 nylon over polyglactin, as nylon may cause less inflammation in the postoperative period. To determine if suture type and size influenced the rate of pterygium recurrence, Wong et al. conducted a prospective, randomised, controlled trial comparing the use of 10/0 nylon to 8/0 polyglactin sutures. The authors found that 8/0 polyglactin sutures was associated with more postoperative discomfort (although not statistically significant) and increased graft hyperemia compared to 10/0 nylon sutures. However, the recurrence rate was similar (12% or 2 eyes in the nylon group and 7% or 1 eye in the polyglactin group).

Varsanno et al. published a retrospective cohort study of 182 pterygium procedures where the autografts had been sutured using 6/0 to 10/0 polyglactin or 10/0 nylon, reflecting changes in their technique over a period of time. Overall, the recurrence rate was 11.4%. Comparing recurrence rates between different suture types and sizes, they reported that overall, larger suture

JAYPEE BROTHERS

sizes, such as 6/0 to 8/0 materials had a higher recurrence rate compared to 9/0 or 10/0 materials (p=0.005). On further analysis, they found that there was only a marginal difference in the recurrence rate between nylon and polyglactin when similar suture sizes were compared, with the use of polyglactin leading to a slightly shorter (but not significant) time to recurrence. The size of polyglactin sutures (6/0 to 8/0 compared with 9/0 or 10/0) also had a marginal effect on recurrence (p=0.075). Similarly, there was also no difference in the time to recurrence when interrupted, continuous, or a combination of both suturing methods were used.

Alternative techniques to secure the conjunctival graft, such as the use of tissue adhesives, e.g. fibrin glue, are now gaining popularity, primarily due to the decrease in operating time compared to suturing and the possible further reduction in rates of recurrence and postoperative discomfort. Sutures can lead to increased inflammation compared with tissue adhesives. Conversely, fibrin glue has a theoretical risk of transmitting infectious diseases, although this has yet to be reported.

COMPLICATIONS

While recurrence is the most important complication following pterygium surgery, other complications following excision with conjunctival autograft can occur, albeit uncommonly. Most of these complications are common to all conjunctival autograft techniques irrespective of whether sutures are used, and occur at rates of less than 5%.

A number of complications associated with the graft can occur. These include dehiscence or loss, which can result from trauma (e.g. from eye rubbing) and premature suture loosening, or graft retraction due to an insufficient graft size or excessive Tenon's tissue under the graft. Graft necrosis can also occur following unintentional inversion of the autograft. In the immediate postoperative period, a degree of graft edema is common, however significant edema or a hematoma as the result of insufficient intraoperative hemostasis can lead to the formation of a corneal dellen.

Complications can also occur as the result of abnormal healing. These include conjunctival epithelial inclusion cysts, granulomas including suture-related granulomas, and symblepharon formation. Cysts and granulomas may settle with topical corticosteroid treatment but can be excised if they persist or are large. Symblephara may need to be released in cases where diplopia or lid malposition results.

Other important complications include corneal scarring leading to astigmatism, infectious keratitis and corticosteroid-induced ocular hypertension. Tan et al. reported a 7.7% rate of ocular hypertension following a weaning course of 0.1% dexamethasone over 2 months. One of their cases progressed to glaucoma, subsequently managed with a successful trabeculectomy despite previous pterygium surgery. Thus, regular monitoring of intraocular pressure is necessary in all patients requiring prolonged steroids, especially in individuals who have risk factors, such as a personal or family history of glaucoma or high myopia.

Overall, the safety profile of a conjunctival autograft surgery is more favorable than other techniques such as bare sclera with beta-radiation or intraoperative mitomycin C. Beta-radiation has been reported to cause vision and eye-threatening complications including cataract, scleral thinning (leading to scleritis) and endopthalimitis where as mitomycin C may cause delayed epithelial healing and corneo-scleral thinning.

CONCLUSION

The technique of using a conjunctival autograft with suture fixation remains the mainstay of pterygium surgery in many parts of the world. While it requires more operating time than older techniques such as bare sclera or primary conjunctival closure, the recurrence rate is significantly lower. The use of sutures is also more cost effective than the more recent modification in autograft surgery where tissue adhesives are used.

BIBLIOGRAPHY

1. Chen PP, Ariyasu RG, Kaza V, LaBree LD, McDonnell PJ. A randomized trial comparing mitomycin C and conjunctival autograft after excision of primary pterygium. Am J Ophthalmol. 1995;120:151-60.
2. de Keizer RJ, Swart-van den Berg M, Baartse WJ. Results of pterygium excision with Sr 90 irradiation, lamellar keratoplasty and conjunctival flaps. Doc Ophthalmol. 1987;67:33-44.
3. Gris O, Guell JL, del Campo Z. Limbal-conjunctival autograft transplantation for the treatment of recurrent pterygium. Ophthalmol. 2000;107:270-3.
4. Hirst LW. Prospective study of primary pterygium surgery using pterygium extended removal followed by extended conjunctival transplantation. Ophthalmol. 2008;115:1663-72.
5. Kaufman SC, Jacobs DS, Lee WB, Deng SX, Rosenblatt MI, Shtein RM. Options and adjuvants in surgery for pterygium: a report by the American Academy of Ophthalmology. Ophthalmol. 2013; 120:201-8.
6. Kenyon KR, Wagoner MD, Hettinger ME. Conjunctival autograft transplantation for advanced and recurrent pterygium. Ophthalmol. 1985;92:1461-70.
7. Koranyi G, Artzen D, Seregard S, Kopp ED. Intraoperative mitomycin C versus autologous conjunctival autograft in surgery of primary pterygium with four-year follow-up. Acta Ophthalmol. 2012;90:266-70.
8. Luanratanakorn P, Ratanapakorn T, Suwan-Apichon O, Chuck RS. Randomised controlled study of conjunctival autograft versus amniotic membrane graft in pterygium excision. British J Ophthalmol. 2006;90:1476-80.
9. Pan HW, Zhong JX, Jing CX. Comparison of fibrin glue versus suture for conjunctival autografting in pterygium surgery: a meta-analysis. Ophthalmol. 2011;118:1049-54.

JAYPEE BROTHERS

10. Prabhasawat P, Barton K, Burkett G, Tseng SC. Comparison of conjunctival autografts, amniotic membrane grafts, and primary closure for pterygium excision. Ophthalmol. 1997;104:974-85.
11. Ratnalingam V, Eu AL, Ng GL, Taharin R, John E. Fibrin adhesive is better than sutures in pterygium surgery. Cornea. 2010;29:485-9.
12. Tan DT, Chee SP, Dear KB, Lim AS. Effect of pterygium morphology on pterygium recurrence in a controlled trial comparing conjunctival autografting with bare sclera excision. Arch Ophthalmol. 1997;115:1235-40.
13. Uy HS, Reyes JM, Flores JD, Lim-Bon-Siong R. Comparison of fibrin glue and sutures for attaching conjunctival autografts after pterygium excision. Ophthalmol. 2005;112:667-71.
14. Varssano D, Shalev H, Lazar M, Fischer N. Pterygium excision with conjunctival autograft: true survival rate statistics. Cornea 2013;32:1243-50.
15. Wong VW, Rao SK, Lam DS. Polyglactin sutures versus nylon sutures for suturing of conjunctival autograft in pterygium surgery: a randomized, controlled trial. Acta ophthalmologica Scandinavica. 2007;85:658-61.

JAYPEE BROTHERS

or detailed information on ophthalmology books, visit our website **www.jaypeebrothers.com**, for detailed informa

Textbook of Pterygium Management

Salient Features

- Discusses the current understanding of the pterygium etiopathogenesis and its management protocols including the ways to deal with the complications following surgery
- Involves the chapters on surgical management of primary and recurrent pterygia with 12 case-based videos on the surgical techniques by leading experts. These videos provide the details of finest aspects of surgical technique, enhanced with voice-over, and are especially useful for the budding ophthalmologists and the cornea surgeons alike to replicate the surgical steps for their respective patients
- Offers the detailed step-by-step management for most surgical techniques described by the innovators including combined ipsilateral autologous limbus and homologous amniotic membrane transplantation for recurrent symblepharopterygium, sealing the gap, sandwich technique for use of glue for autograft, minor ipsilateral simple limbal epithelial transplantation (mini-SLET), mini flap technique with inferior conjunctival autografting and narrow strip conjunctival autograft amongst others.



Tushar Agarwal is Professor (Ophthalmology), Dr Rajendra Prasad Centre for Ophthalmic Sciences, All India Institute of Medical Sciences (AIIMS), New Delhi, India. He graduated in Medicine from Delhi University and completed postgraduation in Ophthalmology from AIIMS. Subsequently, he obtained superspecialty training in corneal and refractive surgery. He has been on the Faculty of AIIMS since 2005. He has co-authored over 90 peer-reviewed research papers in the area of corneal and refractive surgery. He is currently conducting research in the genetic basis and pathogenesis of pterygium and methods to further improve outcomes in pterygium surgery. He has received the Achievement Award from the American Academy of Ophthalmology and the Asia-Pacific Association of Ophthalmology. He is also the recipient of the Indian National Science Academy's Young Scientist Medal. His surgical videos have been recognized with the Best of Show Award on multiple occasions by the American Academy of Ophthalmology.



Shikha Gupta is an Assistant Professor, Dr Rajendra Prasad Centre for Ophthalmic Sciences, All India Institute of Medical Sciences (AIIMS), New Delhi, India. She graduated in Medicine and completed postgraduation in Ophthalmology from AIIMS. Subsequently, she obtained superspecialty training in cornea, refractive surgery, pediatric cataract and glaucoma from the same institution. She has co-authored over 65 peer-reviewed research papers in Ophthalmology. She has received research awards and Young Investigator awards by various international and national societies such as the American Academy of Ophthalmology, Asia ARVO, All India Ophthalmological Society, Glaucoma Society of India, and the Delhi Ophthalmological Society on multiple occasions. Her surgical video on repair of post-traumatic cyclodialysis has been recognized as amongst the best by the World Glaucoma Congress. She was also awarded Professor HK Tiwari Trophy, Professor LP Aggarwal Trophy and Satyanand Gold Medal at AIIMS.



Namrata Sharma is presently working as a Professor of Ophthalmology (Cornea, Cataract and Refractive Surgery Services) at Dr Rajendra Prasad Centre for Ophthalmic Sciences, All India Institute of Medical Sciences (AIIMS), New Delhi, India. She has over 500 publications to her credit with more than 350 publications in international peer-reviewed journals. She has co-authored 9 books based on various aspects of ophthalmology, and has filed 2 patents. She has been the Organizing Secretary for several national and international conferences; has held 9 administrative posts; and, currently, holds the position of the Secretary, Eye Bank Association of India. She has won over 20 international and national awards for her achievements and excellence in the field of ophthalmology, and has been actively involved in undergraduate, postgraduate and postdoctoral teachings for the last 20 years.

Available at all medical bookstores or buy online at www.jaypeebrothers.com

JAYPEE BROTHERS
Medical Publishers (P) Ltd.
www.jaypeebrothers.com

Join us on facebook.com/JaypeeMedicalPublishers

Shelving Recommendation
OPHTHALMOLOGY

ISBN 978-93-86261-54-0