rothers.com, for detailed information on microbiology books, visit our website www.jaypeebrothers.com, for detailed information on microbiology books

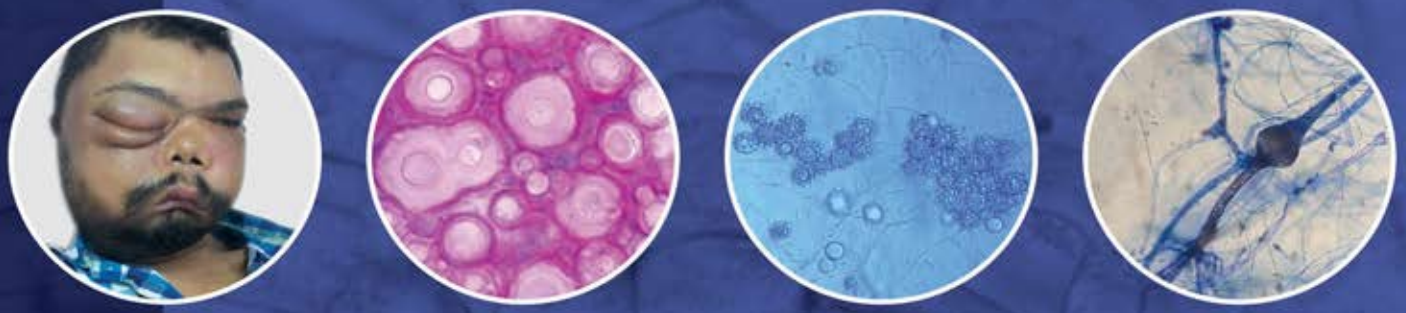

Textbook of Medical Mycology

4th Edition

Jagdish Chander

Foreword
Niranjan Nayak

JAYPEE

Textbook of
MEDICAL MYCOLOGY

Dr. Jagdish Chander MD DNB MAMS
Professor & Head
Department of Microbiology
Government Medical College Hospital
Chandigarh, India

JAYPEE BROTHERS

JAYPEE *The Health Sciences Publisher*
New Delhi | London | Panama

Contents

Acronyms and Abbreviations

Section I. General Topics in Medical Mycology

1. Introduction *3*
2. Fungal Morphology *24*
3. Fungal Taxonomy *39*
4. Immunity to Fungal Diseases *59*
5. Diagnosis of Fungal Diseases *71*
6. Antifungal Therapy *102*

Section II. Superficial Cutaneous Mycoses

7. Malasseziosis *127*
8. Tinea Nigra *145*
9. Piedra *154*
10. Dermatophytosis *162*

Section III. Subcutaneous Mycoses

11. Mycetoma *203*
12. Sporotrichosis *229*
13. Chromoblastomycosis *251*
14. Phaeohyphomycosis *269*
15. Lacaziosis *297*

Section IV. Systemic Mycoses

16. Histoplasmosis *311*
17. Blastomycosis *342*
18. Coccidioidomycosis *356*
19. Paracoccidioidomycosis *379*

Section V. Opportunistic Mycoses

20. Candidiasis *401*
21. Cryptococcosis *434*
22. Pneumocystosis *473*
23. Microsporidiosis *494*

JAYPEE BROTHERS

24. Talaromycosis *506*
25. Aspergillosis *524*
26. Mucormycosis *554*
27. Entomophthoramycosis *597*
28. Miscellaneous Opportunistic Mycoses *613*

Section VI. Miscellaneous Mycoses

29. Oculomycosis *639*
30. Otomycosis *669*
31. Hyalohyphomycosis *682*
32. Adiaspiromycosis and Emergomycosis *707*
33. Allergic Fungal Diseases *722*
34. Fungal Rhinosinusitis *737*
35. Mycotoxicoses and Mycetismus *762*
36. Mycology Laboratory Contaminants *780*

Section VII. Pseudofungal Infections

37. Protothecosis and Chlorellosis *797*
38. Rhinosporidiosis *811*
39. Pythiosis and Lagenidiosis *828*

Section VIII. Appendices

A Fungal Culture Media *847*
B Fungal Reagents and Stains *856*
C Conventional Mycological Techniques *868*
D Antifungal Susceptibility Testing *874*
E Quality Control, Preservation and Culture Collections of Fungi *888*
F Bibliography *894*
G Glossary *912*

Index *921*

JAYPEE BROTHERS

Acronyms and Abbreviations

ABCD	Amphotericin B colloidal dispersion
ABLC	Amphotericin B lipid complex
ABPA	Allergic bronchopulmonary aspergillosis
ABPM	Allergic bronchopulmonary mycoses
AFAD	Allergic fungal airway disease
AFLP	Amplified Fragment Length Polymorphism
AFRS	Allergic fungal rhinosinusitis
AFST	Antifungal Susceptibility Testing
AmB	Amphotericin B
APACHE	Acute Physiology and Chronic Health Evaluation (scores)
API	Analytical Profile Index
APMIS	Acta Pathologica Microbiologica Immunologica Scandinavica
AP-PCR	Arbitrarily primed PCR
ATCC	American Type Culture Collection
AUC	Area under curve
BAL	Bronchoalveolar lavage (fluid)
BCE	Brown Color Effect
BDG	Beta-D-Glucan
BHI	Brain-heart infusion (agar/broth)
BMBL	Biosafety in Microbiological and Biomedical Laboratories
BMD	Broth microdilution
BLAST	Basic Local Alignment Search
BMT	Bone marrow transplant
BOD	Biochemical/Biological oxygen demand
BSA	Bird seed agar
BSL	Biohazard safety levels
CAB	Centre for Agriculture and Biosciences
CAPD	Continuous ambulatory peritoneal dialysis
CARD	Caspase-associated recruitment domain 9
CBS	Centraalbureau voor Schimmelcultures (Now, Westerdijk Fungal Biodiversity Institute)
CCSG	Coccidioidomycosis Cooperative Study Group
CDC	Centers for Disease Control and Prevention
Cf	Compare from
cfc	Continuous flow culture
CFPA	Chronic fibrosing pulmonary aspergillosis
CFU	Colony-forming unit
CFW	Calcofluor white (stain)
CGB	Canavanine glycine bromothymol blue
CHEF	Contour-clamped homogeneous electric field gel electrophoresis
CHHA	Cysteine-heart and hemoglobin agar
CIE	Counterimmunoelectrophoresis
CIOMS	Council for International Organization of Medical Sciences
CLSI	Clinical and Laboratory Standards Institute (since January 1, 2005, formerly NCCLS)
CMA	Cornmeal agar
CMCC	Chronic mucocutaneous candidiasis
CMI	Cell-mediated immunity
CMI	Commonwealth Mycological Institute
CNPA	Chronic Necrotizing Pulmonary Aspergillosis
CPA	Chronic pulmonary aspergillosis
CPA	Cyclopiazonic acid
CT	Computed tomography
CYP	Cytochrome P450 (enzymes)
D-AmB	Deoxycholate amphotericin B
DBB	Diazonium Blue B (dye)
DD	Double diffusion/disk diffusion
DHPS	Dihydropteroate synthase
DIM	Dermatophyte identification medium
DIN	Deutsches Institut für Normung, Germany
DMSO	Dimethyl sulfoxide
DPX	Dibutylphthalate xylene
DRBC	Dichloran Rose Bengal Chloramphenicol (agar)
DRIP	Dermocystidium, rosette agent, Ichthyophonus and Psorospermium (clade)
DTH	Delayed-type hypersensitivity
DTM	Dermatophyte test medium
e	Electronic (edition)
EAPCRI	European *Aspergillus* PCR Initiative
e.g.	*exempli gratia* - for example
ECIL	European Conference on Infections in Leukemia
ECMM	European Confederation of Med. Mycology
ed/edn	Editor(s)/Edition(s)
EDTA	Ethylene diamine tetra acetic acid
EIA	Enzyme immunoassay
ELISA	Enzyme-linked immunosorbent assay
EMBO	European Molecular Biology Organization
EORTC	European Organization for Research and Treatment of Cancer

JAYPEE BROTHERS

et al	*et alii* 'and others' (more than one author)
EUCAST	European Committee for Antimicrobial Susceptibility Testing
f. sp.	*formae speciales*/special form
FA	Fluorescent antibodies
FEMS	Fed. of European Microbiological Societies
FESS	Functional Endoscopic Sinus Surgery
FFPE	Formalin fixed, paraffin-embedded
FIRE	Fungal Infection Risk Evaluation
FISH	Fluorescence *in situ* hybridization
FNA	Fine needle aspiration (biopsy/cytology)
FSSAI	Food Safety and Standards Authority of India
GAFFI	Global Action Fund for Fungal Infections
GalXM	Galactoxylomannan
GF	Gridley fungal (stain)
GLC	Gas liquid chromatography
GlcNAc	N-acetylglucosamine
GMS	Grocott-Gomori methenamine silver (stain)
Gr.	Greek
GTT	Germ tube test
GXM	Glucuronoxylomannan
GYE	Glucose-yeast extract (agar)
H&E	Hematoxylin and eosin (stain)
HA	Hemagglutination
HAI	Healthcare-associated infections
HACCP	Hazard Analysis Critical Control Point
HEPA	High efficiency particulate air (filter)
HPLC	High performance liquid chromatography
HRL	Histoplasmosis Reference Laboratory
HSCT	Hematopoietic Stem Cell Transplantation
Hsp	Heat shock proteins
i.e.	*id est* 'that is'
IA	Invasive aspergillosis
IARC	International Agency for Research on Cancer
ICBN	Internat. Code of Botanical Nomenclature
ICN	International Code of Nomenclature for Algae, Fungi and Plants
ICTF	Internat. Committee on Taxonomy of Fungi
ICZN	Internat. Code of Zoological Nomenclature
ID	Immunodiffusion
IFA	Indirect fluorescent antibodies
IFD	Invasive fungal disease
IFI	Invasive fungal infection
IFN	Interferon
IFT	Invasive fungal tracheobronchitis
IGS	Intergenic Spacer Region
IHRB	Industrial Health Research Board
IL	Interleukin
IMA	International Mycological Association
IMC	International Mycological Congress
IMI	International Mycological Institute
IPA	Invasive pulmonary aspergillosis
IRIS	Immune Reconstitution Inflamm. Syndrome
ISHAM	International Society for Human and Animal Mycology (Founded in July 1954, Paris)
ITS	Internal Transcribed Spacer
ITIS	Integrated Taxonomic Information System
kDa	Kilo Dalton
KOH	Potassium hydroxide
LA	Latex agglutination
La.	Latin
L-AmB	Liposomal amphotericin B
LAMP	Loop-Mediated Isothermal Amplification
LCB/LPCB	Lactophenol cotton blue (mount)
Lf	Lactoferrin
LFA/D	Lateral Flow Assay/Device
LIFE	Leading International Fungal Education
LPA	Latex particle agglutination
LSD	Lysergic acid diethylamide
LSU	Large-subunit
M	Mycelial (Saprotrophic phase of fungus)
mAb	Monoclonal antibody
MALDI	Matrix Assisted Laser Desorption Ionization
MEA	Malt-extract agar
MEC	Minimum effective concentration
MFC	Minimum fungicidal concentration
MIC	Minimum inhibitory concentration
MFSS	Masson-Fontana silver stain
MGG	May-Grunwald Giemsa (stain)
MLEE	Multi-locus enzyme electrophoresis
MLSA	Multi-locus sequence analysis
MLST	Multi-locus sequence typing
MOPS	Morpholinopropane Sulfonic acid (buffer)
MRI	Magnetic resonance imaging
MRL	Mycology Reference Laboratory
MS	Mass spectrometry (also see MALDI TOF)
MSG	Mycoses Study Group
MTCC	Microbial Type Culture Collection
MTT	Methylthiazyl tetrazolium
NCBI	National Center for Biotech. Information
NCCLS	National Committee for Clinical Laboratory Standards (now CLSI since January 1, 2005)
NCPF	National Collection of Pathogenic Fungi
NCTC	National Collection of Type Cultures
NCYC	National Collection of Yeasts Cultures
NDM	Non-dermatophytic molds

JAYPEE BROTHERS

NTDs	Neglected Tropical Diseases
NSM	Non-sporulating molds
NIH	National Institute of Health (USA)
OSHA	Occupational Safety & Health Administration
OTA	Ochratoxin A
PAGE	Polyacrylamide gel electrophoresis
PAP	Papanicolaou (stain)
PATH	Prospective Antifungal Therapy
PAS	Periodic acid-Schiff (stain)
PBS	Phosphate-buffered saline
PCM	Paracoccidioidomycosis
PCP	*Pneumocystis* pneumonia
PJP	*Pneumocystis jirovecii* pneumonia
PCR	Polymerase chain reaction
PDA	Potato dextrose agar
PDT	Photodynamic therapy
PFBK	Primary fetal bovine kidney
PFGE	Pulsed field gel electrophoresis
PFGGE	Pulsed field gradient gel electrophoresis
PHLS	Public Health Laboratory Service (UK)
PHOL	Pal, Hasegawa, Ono, Lee (Stain)
PIM	Prototheca isolation medium
PIV	Pythium insidiosum vaccine
PMS	Pyrolysis-mass spectrometry
PNA	Peptide nucleic acid (PNA-FISH)
PNS	Paranasal sinuses
POCT	Point-of-Care Testing
ppb/ppm	Parts-per-billion (1×10^{-9})/million (1×10^{-6})
PRM	Peptidorhamnomannan (antigen)
PYG	Peptone-yeast extract glucose
QMAP	Quantamatrix Multiplexed Assay Platform
qPCR	Quantitative polymerase chain reaction
RAPD	Randomly amplified polymorphic DNA
RFLP	Restriction fragment length polymorphism
RIA	Radioimmunoassay
RPLA	Reverse passive latex agglutination
RPMI	Roswell Park Memorial Institute (Medium)
RSA	Rice starch agar
RT-PCR	Reverse transcriptase-PCR
SAFS	Severe asthma associated fungal sensitivity
SAM	Sinobronchial Allergic Mycosis
S/Suppl	Supplement (Issue of journal)
SD	Seborrheic dermatitis
SDA,SGA	Sabouraud dextrose (glucose) agar
SDD	Susceptible dose-dependent
SDS	Sodium dodecyl sulfate
SIHAM	Society for Indian Human and Animal Mycologists (Founded in 1996, Jabalpur, MP)
SMX/SMZ	Sulfamethoxazole
SOD	Superoxide dismutase
SOT	Solid organ transplant
Sp/Spp.	Species (Singular/Pleural)
SSA	Sunflower seed agar
SSCP	Single-stranded conformation polymorphism
SSKI	Saturated solution of potassium iodide
SSU	Small-subunit
Syn.	Synonymous (name)
TDM	Therapeutic drug monitoring
TD-PCR	Touchdown polymerase chain reaction
TEM	Transmission electron microscopy
TLC	Thin Layer Chromatography
TLR	Toll-like receptors
TMP	Trimethoprim
TOF	Time of flight (MALDI TOF MS)
TRANSNET	Transplant-Associated Infection Surveillance Network
TRM	Tetrazolium reduction medium
TSB	Tryptic soy broth
var.	Variety (of a fungal strain)
VFCE	Valley Fever Center for Excellence
vs.	Versus
WGST	Whole-Genome Sequence Typing
Y	Yeast or Parasitic phase of dimorphic fungi
YCB	Yeast carbon base
YEA	Yeast extract agar
YNB	Yeast nitrogen base
ZEN	Zearalenone (Mycotoxin)

JAYPEE BROTHERS

CHAPTER

32

Adiaspiromycosis and Emergomycosis

JAYPEE BROTHERS

The genus ***Emmonsia*** currently consists of **two** medically significant species associated with human diseases *i.e.* ***Ea.crescens*** and ***Ea.parva***. Both species are known for the last half a century and are responsible for unique granulomatous zoonotic pulmonary disease called as **adiaspiromycosis**. It is very rarely reported among humans also.

On the other hand **emergomycosis** is a systemic fungal infection presenting with cutaneous and disseminated clinical manifestations among immunocompromised patients. This is caused by three dimorphic fungi belonging to a newly described genus ***Emergomyces*** *i.e. Emergomyces pasteurianus* comb. nov., *Emergomyces africanus* sp. nov. and *Emergomyces orientalis* sp. nov., which were formerly classified under genus *Emmonsia* either as *Emmonsia pasteuriana* or *Emmonsia*-like species. As nomenclature of genus is replaced for these unique fungal species from *Emmonsia* to *Emergomyces*, consequently disease name is also changed from emmonsiosis to emergomycosis for the convenience of deliberations.

Emergomyces pasteurianus however known for quite some time but came to limelight recently by causing clinical entity due to its strong association with immunocompromised conditions. *Es.africanus*, another dimorphic fungal species, recently reported particularly among cluster of cases in South Africa and other places. This is very close to *Es.pasteurianus*, not reported till date in any of the animal or environmental niche but has come to the international attention.

However, for convenience of discussion both these diseases (adiaspiromycosis and emergomycosis), caused by various species of genus ***Emmonsia*** ***(****Ea.crescens* and *Ea.parva****)*** and ***Emergomyces*** ***(****Es.pasteurianus* and *Es.africanus* and *Es.orientalis)* are clubbed together in this Chapter and described comprehensively as separate clinical entities.

I. ADIASPIROMYCOSIS

This disease is primarily fungal infection of rodents and lower animals of wildlife. It is prevalent worldwide mainly involving respiratory system of mice, rats, rabbits, squirrels, etc, which live or burrow in the soil. However, man can rarely be an incidental host and get infection by inhaling dust-borne conidia of causative saprobic soil fungi of genus *Emmonsia*. There are two clinically important species of this genus *i.e. Ea.crescens* and *Ea.parva*, which cause **adiaspiromycosis**. This had also been known by various synonym like **haplomycosis** and **adiaspirosis** but the name recommended by ISHAM is popularly used *i.e.* **adiaspiromycosis**. However, when the term emergomycosis is used, it is meant for the disease caused by three opportunistic dimorphic species of genus *Emergomyces - Es.pasteurianus, Es.africanus* and *Es.orientalis* given in detail in later part of this very Chapter.

Historical Perspective

In 1942, Chester Wilson Emmons and Ashburn, during an active search for another fungus *i.e. Coccidioides immitis* in Lower Sonoran Deserts (Arizona), unexpectedly encountered a new fungus in the lungs of rodents. This was forming spherule-like structure in lung tissue, measuring up to 20 µm having thick laminated walls however without any budding or endosporulation. They also observed that large spherule grew from smaller asexual conidia (2-4 µm) thereby classified the fungus as *Haplosporangium parvum* thinking it to be a mucormycete because of its resemblance to *Haplosporangium bisporale*. The fungus was subsequently transferred to a new genus *Emmonsia* as *Ea.parvum*.

Five years later in 1947, Dowding in Alberta, Canada isolated a similar type of organism from rodents but

spherules were about six times larger than that of previously discovered fungus in Arizona. A close relationship of both fungal isolates of Arizona and Canada, prompted classification of this newly described fungus also, in the genus *Haplosporangium* and therefore disease was initially named as **haplomycosis**. In 1959, Ciferri *et al,* isolated *Haplosporangium parvum* from soil in Italy. They renamed the isolate and placed it in the genus earlier described *i.e. Emmonsia* as *Emmonsia parvum*.

As *Emmonsia* species differed on the basis of size of mature adiaconidia hence fungal isolate from Arizona was named as *Emmonsia parva* whereas Canadian isolate was designated as *Emmonsia crescens* (Latin = ***'crescens'*** - to grow or come forth) due to its **larger** size observed in the tissues. As the larger adiaconidia were being discovered in material from Canada and northern USA, therefore, in the year 1960, strains that produced spherules with a diameter up to 400-500 µm were all designated under new species as *Emmonsia crescens*.

Subsequently due to taxonomical changes, it became imperative to propose a new name for this infection in **wild animals**, as disease was not known to cause infection in man at that time. Thus haplomycosis gave way to a new name as **adiaspiromycosis** due to production of unique structure (adiaconidia/adiaspore). The name of disease as adiaspiromycosis (***a-*** = not or without + ***dia-*** = through + ***speirein-*** = to scatter or disperse) suggested by Emmons and Jellison, literally translating as mycotic infection of lungs in which there is no multiplication or dissemination of inhaled organism beyond its site of implantation.

The term adiaconidium (formerly **adiaspore**) is derived from typical conidia of causative fungi, which exhibit a unique property of progressive enlargement of its size without replication *in vivo* as well as *in vitro* at an elevated temperature of approximately 37°C or even more. But other workers considered it as a variety of genus *Chrysosporium*. Hence in 1962, *Ea.crescens* was re-named as *Chrysosporium parvum* var. *crescens*.

In 1964 Doby-Dubois *et al*, while demonstrating a solitary pulmonary nodule, reported the first case of human adiaspiromycosis from France. In 1979, Kamalam *et al,* reported two cases of cutaneous infection from India caused by *Emmonsia (Chrysosporium) crescens.* In 1997, a case of disseminated bilateral pulmonary adiaspiromycosis was reported in a two year old Finnish girl. She was rather the first human case of adiaspiromycosis in Scandinavia, the youngest child with this disease reported so far and recovered successfully after treatment with amphotericin B. Later on more cases were reported from other continents as well, substantiating it to be a significant disease not only in wild animals but humans as well.

Mycology

Adiaspiromycosis is caused by two species of genus *Emmonsia i.e.* ***Ea.parva*** and ***Ea.crescens***. Earlier they were called as *Chrysosporium parvum* var. *parvum or Emmonsia parva* var. *parva* and *Chrysosporium parvum* var. *crescens or Emmonsia parva* var. *crescens*, respectively. Both the organisms have recently been given independent **species** status as *parva* and *crescens* instead of designating them with their **variety** names. The genus name, *Emmonsia,* is favored over *Chrysosporium* as correct generic name for agents of adiaspiromycosis.

These species of *Emmonsia* produce non-replicating cells called as adiaconidia, which are globose, thick-walled, mono-or multinucleate cells commonly found in enlarged cyst-like structures in the lungs of rodents and other small terrestrial wild animals. The term adiaconidium/adiaspore was derived from Greek verb - ***'-speirein'*** meaning to scatter or disperse, with ***'adia-'*** being negative and was proposed for spherule which enlarges from inhaled asexual conidium signifying increasing size without its replication under influence of elevated temperature. This feature is seen *in vivo* as well as *in vitro*. The terminology **adiaconidium** is frequently used interchangeably as **adiaspore** also but former one is correct. Adiaspiromycosis is the term used when such development occurs within animal or human body.

These two species of genus *Emmonsia* differ in their growth requirement of tolerable temperature (37°C for *Ea.crescens* versus 40°C for *Ea.parva*), sensitivity to cycloheximide, size of adiaconidia, host range, ability to form a teleomorph as well as their geographical distribution. The optimum temperature required for the growth of *Ea.crescens* is 37°C forming adiaconidia and at 40°C it is inhibited, whereas at 37°C *Ea.parva* grows as mycelial fungus but at 40°C it is converted to adiaconidium. The adiaconidia of *Ea.crescens* are about 5-10 times larger than that of *Ea.parva* (250-400 µm *vs.* 10-25 µm) and wall thickness is about 20-70 µm as compared to 2 µm in case of *Ea.parva*. This remains as **mononucleate** in *Ea.parva* even on attaining its full size but in *Ea.crescens* becomes **multinucleate** when it begins its phenomenal increase in size. The differentiating features between *Ea.crescens* and *Ea.parva vis-a-vis* species of *Emergomyces* are given in **Table 32.1**.

JAYPEE BROTHERS

Table 32.1. Differentiating Features among Species of Genera *Emmonsia* and *Emergomyces*.

Characteristics	*Ea.crescens*	*Ea.parva*	*Es.pasteurianus*	*Es.africanus*	*Es.orientalis*
Adiaconidia (Adiaspores)	Produced	Produced	Not produced	Not produced	Not produced
Size of Adiaconidia	50-500 µm (Max. 700)	10-25 µm (Max. 40)	Not applicable	Not applicable	Not applicable
Spherule Wall Thickness	20-70 µm	2 µm	Not applicable	Not applicable	Not applicable
Nucleus	Multinucleate	Mononucleate	Not applicable	Not applicable	Not applicable
Growth at 37°C	Adiaconidia	Mycelial	Yeasts (2-4 µm)	Yeasts (2-4 µm)	Yeasts (4-10 µm)
Growth at 40°C	Inhibited	Adiaconidia	-	-	-
Cycloheximide	Reduced growth	No inhibition	No inhibition	No inhibition	-

The taxonomy pertaining to causative fungi of adiaspiromycosis has been controversial. These fungi were placed in family **Moniliaceae** of class **Hyphomycetes** in phylum **Deuteromycetes**. Traditionally nomenclature of fungus as genus ***Emmonsia*** was designated as a tribute to **Chester Wilson Emmons** (1900-1985) eminent mycologist of 20th century but adiaspiromycosis is currently accepted name for this clinical entity caused by *Ea.crescens* and *Ea.parva* as per the ISHAM recommendations.

The teleomorph state has recently been demonstrated in *Ea.crescens*. It is also a member of *Ajellomyces* clade, which belongs to the family Ajellomycetaceae. The genus *Ajellomyces* contained heterothallic species, *A.dermatitidis*, *A.capsulatus* and *A.crescens*, anamorphs of which are placed in different genera *i.e. Blastomyces*, *Histoplasma* and *Emmonsia,* respectively. Now, newly described genus is also added to this family *i.e. Emergomyces*. The taxonomic arrangement of the group is currently in flux, complicated by the fact that the type species, *Ea.parva*, appears more related to *Blastomyces* than to *Ea.crescens*.

The teleomorphic state of *Ea.crescens* has been named *Ajellomyces crescens* in the same genus as most of the dimorphic fungi. This designation was given because *A.crescens* closely resembles *Ajellomyces dermatitidis*, teleomorph state of *Blastomyces dermatitidis* and is causative dimorphic fungus of systemic disease, blastomycosis. The phylogenetic analysis of 18S rDNA sequences of *Ea.crescens* places this pathogen within order **Onygenales** where various **dimorphic fungi** are placed in genus *Ajellomyces* and taxonomically it may also be taken as a dimorphic fungus. There is no known sexual state in *Emmonsia parva* but phylogenetic diversity from one group to other and to *B.dermatitidis* strains suggest diverging groups, may be varieties or sibling species. Therefore, *Emmonsia* genus is also grouped under **dimorphic fungi** as its species are converted from mycelial to adiaconidia at the body temperature.

The species of another genus, *Emmonsiellopsis,* were morphologically found to be related to thermally dimorphic fungi of family Ajellomycetaceae but analysis of ITS region of rDNA and domains D1 and D2 of the 28S rRNA gene sequences confirmed that they were different from all species described in that family. They were accommodated in new genus *Emmonsiellopsis* as *E.coralliformis* sp. nov. and *E.terrestris* sp. nov. and neither related to adiaspiromycosis nor to emergomycosis.

Epidemiology

Adiaspiromycosis is a worldwide, non-infectious, non-arthropod transmitted fungal infection of lower vertebrates, most commonly among the rodents. The humans become an accidental host by inhaling dust-borne aerosolized conidia of the saprophytic soil fungus of genus *Emmonsia*. It is primarily a respiratory infection of burrowing rodents with worldwide geographical and ecological distribution. The disease has been reported in 124 mammalian species and sub-species. Despite its ubiquitous nature occurring in lower wild animals, disease rarely affects man. The mammals become hosts following inhalation of minute globose asexual **conidia** (2-4 µm) that eventually develop into large, thick-walled **adiaconidia** in lung tissue of host and may persist for rest of their lives. The conidia are **aleurioconidia** as these are solitary ones released by lytic disintegration of part of supportive hyphal cell. The adiaconidia in large number can significantly damage pulmonary tissue and respiratory capacity of the infected animals. The disease name represents this long described mycosis mainly infecting rodents and is characterized by presence of adiaconidia.

The rodents may serve as zoonotic reservoir of the disease although fungus causing infection in **rodents**, *Ea.parva***, rarely** infects **humans**. *Emmonsia crescens* is

JAYPEE BROTHERS

found in nature predominantly in temperate zones and likely mode of human infection is accidental inhalation of asexual fungal conidia aerosolized from contaminated soil. There is development of scattered pulmonary granulomas due to development of conidia into adiaconidia. *Ea.crescens* is prevalent worldwide in temperate zones except in Africa and Australia whereas *Ea.parva* is associated with fewer animal hosts and geographically more restricted as it is only confined to south-western USA, Eastern Europe, Kenya and Australia.

Doby-Dubois *et al,* reported first case of human adiaspiromycosis in 1964 from France in formalin-fixed lung tissue of a patient suffering from aspergillosis with cystic disease. The majority of human infections are caused by *Ea.crescens*. Only two patients with underlying AIDS have been found to be infected with *Ea.parva.* The natural habitat of *Ea.crescens* and *Ea.parva* is soil. It is an under-reported as well as misdiagnosed pulmonary infection among humans. The disease is non-communicable in nature as animal-to-animal transmission has not been documented. The infection is more common in male patients engaged in outdoor activities and/or occupations.

Emmonsia parva and *Ea.crescens* are etiologic agents of adiaspiromycosis. Usually this presents as an asymptomatic pulmonary infection in animals and more recently in immunocompromised patients after the inhalation of the fungal conidia. Lung biopsy may be necessary to diagnose the illness, as the organisms may not be present in sputa or bronchial alveolar lavages. Dissemination of the infection may occur more readily in immunocompromised hosts. *Ea.crescens* is more commonly isolated from humans while *Ea.parva* is isolated more often from animals.

Human adiaspiromycosis is uncommon but there are nearly **seventy** cases reported in the literature from various countries like Israel, India, Czechoslovakia, erstwhile USSR, France, Germany, Spain, Finland, Argentina, Brazil, Venezuela, Guatemala, Honduras and USA. There were reports of this disease among animals in England but in 2009 a human case has also been described by Denson *et al*, who was primarily suspected to be having pulmonary adenocarcinoma. Since the original report of human pulmonary infections, *Ea.parva* has also been isolated from nail, skin, sinuses and bones, where it produces severe osteomyelitis. As it is with pulmonary disease, skin and nail infections occur in immunocompetent individuals. However, disseminated infection has been reported in immunocompromised patients.

Immunity

In adiaspiromycosis, delayed-type of hypersensitivity reaction to antigens of *Ea.crescens* and precipitating antibodies in sera can be demonstrated in human infections. The environmental exposure to *Emmonsia* species was first detected by positive skin test reactions to antigens prepared from culture extracts in a group of school children. The strain-as well as species-specific antigens were detected by immunodiffusion tests using antisera raised against the partially purified cytoplasmic antigens.

Pathogenesis and Pathology

The adiaconidia may infect normal or underlying diseased lung. After inhalation and reaching alveoli, asexual conidia progressively grows in size as adiaconidia without any replication or budding, etc. Moreover, they neither germinate nor multiply but induce a granulomatous type of chronic inflammatory reaction.

The lesions resemble foreign body or tuberculoid granuloma but without any necrosis or caseation. Adiaconidia are surrounded by granulomatous inflammatory reaction composed of epithelioid cells, macrophages, lymphocytes, plasma cells, scattered neutrophils and fibrous tissue whereas eosinophils are uncommon. These are 4-5 μm in size and on maturity attain size of about 50 to 500 μm, representing about hundred-fold increment. The adiaconidia are closely surrounded by foreign body and Langhans' type of giant cells. They remain in alveoli of host and eventually become calcified in due course of time. The pulmonary lesions produced by enlarging conidia consist of discrete or confluent fibrotic granuloma, each containing one or more adiaconidia.

In adiaspiromycosis, granular proteinaceous radiating material peripheral to outer zone of adiaconidia show Splendore-Hoeppli phenomenon. The huge adiaconidia become encased in granuloma with epithelioid cells and multinucleate giant cells. However, collapsed adiaconidia are seen as crescent-shaped and are believed to be nonviable. The disease is unique among fungal infections as conidia apparently do not multiply in host tissues but only increase in size and illness seems to remain usually confined to the lungs. The thick-walled adiaconidia when mature, are large enough to be seen even with unaided eye. The internal contents of adiaconidia are invariably not seen but when visible, their appearance is variable and may mimic cut-sections of internal organs of helminths.

JAYPEE BROTHERS

Clinical Features

Adiaspiromycosis is an uncommon but chronic pulmonary fungal disease caused by two species of genus *Emmonsia i.e. Ea.crescens* and *Ea.parva*. This is more common in rodents however man may get infection depending upon amount of initial inoculum of inhaled conidia. The majority of documented cases among humans have been found to be asymptomatic. The natural disease, more or less remains confined to the lungs. The patient may become symptomatic as a result of dense and diffuse nodular involvement of lungs. The clinical manifestations are mainly due to the mechanical damage by adiaconidia to its surrounding tissue.

At present the description of this disease is mainly based on clinical manifestations of various case reports available in the literature. There are three clinical forms of human adiaspiromycosis, which are recognized (1) solitary granuloma (2) localized granulomatous and (3) diffuse-disseminated granulomatous disease, which are briefly described here.

1. Solitary Adiaspiromycosis

This clinical form of adiaspiromycosis is an asymptomatic and self-limiting respiratory infection, which is incidentally diagnosed by pathologist during histopathological examination of lung tissue removed for some other reasons. There are no significant radiological abnormalities attributable to this type of infection.

2. Localized Adiaspiromycosis

The disease remains localized at primary implantation site in case of a limited inoculum and pulmonary nodules may be detected radiographically, sometimes incidentally at autopsy or in surgical specimens of lung. The severity of disease depends upon number of conidia inhaled. In a recent report from Brazil, 17 cases of acute conjunctivitis with episcleritis and anterior uveitis were linked to adiaspiromycosis and freshwater sponges in the northern Amazon region. The demonstration of adiaconidia in scleral biopsy specimen from children with severe disease in this outbreak suggest that conjunctival irritation was most likely followed by constant exposure to conidia of this fungus, perhaps in dust caused in part by dry environmental condition, similar to the exposure of respiratory mucosa.

3. Disseminated Adiaspiromycosis

A diffuse and disseminated type of granulomatous adiaspiromycosis is more common as compared to the solitary one. The patient usually presents with low-grade fever, cough, progressive dyspnea, fatigue and night sweats. There are crepitations on auscultation due to compression as well as displacement of distal airways and alveolar parenchyma by gradually expanding granulomas. There is **no** replication of adiaconidia in the lungs. The other organs like skin, peritoneum and bones may rarely be involved as a result of extrapulmonary dissemination causing extensive osteomyelitis. The bone marrow involvement has been found in patient with AIDS, wherein *Ea.parva* was isolated. Moreover, severe cases with inhalation of many conidia can result in acute respiratory failure as it occurs in other well-known dimorphic fungal infections like histoplasmosis and coccidioidomycosis.

Radiodiagnosis

The chest X-rays of granulomatous pulmonary lesions of adiaspiromycosis show multiple nodular shadows of about 1 to 3 mm diameter and usually mistaken for miliary tuberculosis. The most common pattern among these patients is bilateral reticulonodular infiltrates with areas of honeycombing. The tentative diagnosis is invariably based on radiological findings. The high-resolution computed tomography (HRCT) of thorax may also be very useful to delineate lesions, which are eventually confirmed on histopathological examination. The chest radiography of disseminated pulmonary adiaspiromycosis usually shows bilateral reticulonodular infiltrates mimicking those of miliary tuberculosis. As the culture of causative organism from sputum or bronchoalveolar lavage has rarely been achieved and lung biopsy is usually required for diagnosing pulmonary infection, it is difficult to assess that these lesions are caused by tuberculosis, adiaspiromycosis or emergomycosis.

Differential Diagnosis

The most common diseases, which are to be differentiated histopathologically from adiaspiromycosis, are coccidioidomycosis and rhinosporidiosis due to formation of spherule-like structures in all of them. The spherule of *C.immitis* is smaller as its size on an average about 30-60 μm and has 2 μm thick trilaminar walls and contain endospores of 2-5 μm in diameter. Contrarily the center of adiaconidia does not contain any endospore-like structures hence appear empty. The lack of such findings in adiaspiromycosis actually indicates that no intra-host replication occurs.

JAYPEE BROTHERS

The sporangium of *Rhinosporidium seeberi* should be distinguished from this disease, which is 200-300 µm in diameter. Sometimes, adiaconidia may be confused with helminthic nematodes like *Dirofilaria* and *Strongyloides* species in their cut-section. In dirofilariasis, chest x-rays usually show ***'coin-lesion'*** of 2 to 3 cm, much larger than miliary nodules of adiaspiromycosis of size 1 to 2 mm. The degenerated and apparently dead adiaconidia with a flattened and folded aspect may resemble roundworm. The disease should not be confused with miscellaneous structures such as vegetable matter, starch granules of lentil pneumonia or corpora amylacea. The tissue form of *Sporothrix luriei* may sometimes be confused but it has thick-walled horizontal and longitudinal septate and classical eyeglass-shaped cells. The differences in morphological features of spherules and similar structures producing fungal and pseudofungal organisms are given in **Table 5.1 and Table 18.1**.

Another entity, **myospherulosis**, which is a granulomatous type of reaction containing sac-like structures with spherules; associated with lipid medications either being applied to open wounds or being injected leading to solid subcutaneous or dermal nodules. Therefore, it should also not be confused with adiaspiromycosis.

Laboratory Diagnosis

The diagnosis of adiaspiromycosis rests upon radiological and histopathological findings by demonstration of adiaconidia in various stages of their development and/or degeneration. The disease being very rare hence is usually not suspected on clinical grounds because as such there is no pathognomonic feature among these patients. However, it is encountered while examining histopathology specimen for some other disease or accidentally seen during autopsy. In lungs, numerous globose, white to grey nodules can be seen with even naked eye. Moreover, as yet there is no reliable serological test for establishing diagnosis of disease, therefore, significant feature of adiaspiromycosis is finding adiaconidia in biopsy or autopsy tissues.

(a) Direct Examination

The conventional methods of direct examination of fungi are usually utilized to demonstrate organism in fine needle aspiration or biopsy tissue. The respiratory system is invariably involved in adiaspiromycosis but sputum examination and bronchial washing are usually negative for adiaconidia even in a severe case. Therefore, H&E, PAS, GMS, Papanicolaou and Gridley fungal stains are used in biopsy specimen.

The biopsy tissue shows characteristic large thick-walled adiaconidia surrounded by a fibrous granulomatous reaction in lungs **(Figs. 32.1A and B)**. They are symmetrical and round to oval. Neither budding nor endosporulation is seen in any of adiaconidia. Their size range from 50-500 µm and thickness of **trilaminar** wall varying from 20-70 µm. The wall appears **bilaminar** when stained with H&E stain in contrast to other stains like GMS and PAS showing trilaminar wall. The walls of adiaconidia are refractile and when stained with H&E, appear to be comprised of

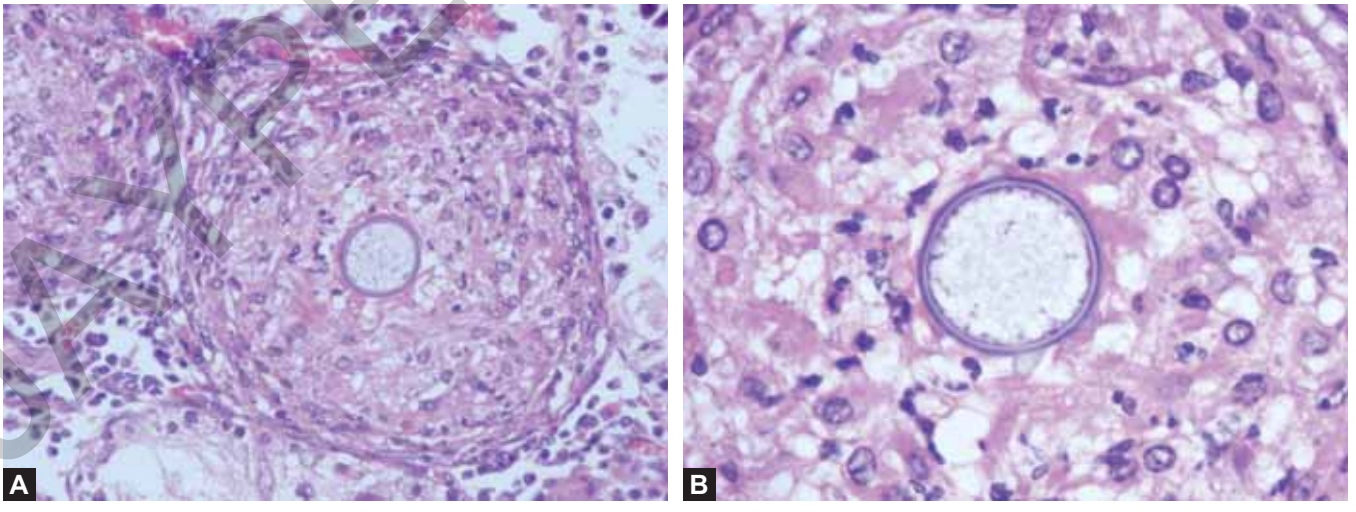

Figs. 32.1A and B. Histopathology shows "honeycomb-like" adiaconidia surrounded by epithelioid macrophages and giant cells of granuloma (H&E × 400 & 1000).

JAYPEE BROTHERS

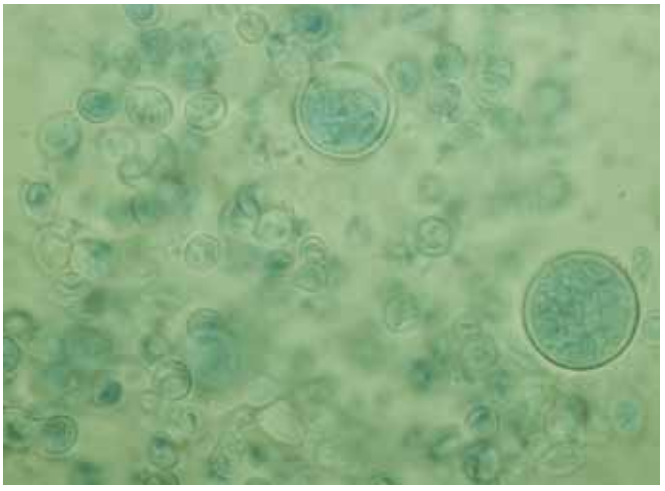

Fig. 32.2. *In vitro* growth of *Emmonsia crescens* showing adiaconidia (LCB × 400).

two layers, a narrow, outer, eosinophilic layer containing periodic fenestrations and a broad, hyaline, inner layer composed predominantly of chitin. Recently fine needle aspiration cytology (FNAC) has also been successfully tried for establishing definitive diagnosis of pulmonary adiaspiromycosis.

The adiaconidia of *Ea.crescens* is about 5-10 times larger than that of *Ea.parva*. Sometimes, especially in *Ea.crescens*, they appear as **empty rings**, which can be seen easily with even naked eye when slide of tissue section is held against source of light as center is always empty. In human lung tissue, adiaconidia are usually empty but may contain small eosinophilic globules along inner surface of walls giving honeycomb-like appearance **(Figs. 32.1A and B)**. The conidial walls stain with GMS, PAS and Gridley fungus stainings but not with Mayer's mucicarmine as in case of rhinosporidiosis or cryptococcosis. The adiaconidia although are empty and round to oval but due to collapse, probably during processing, crescent, sickle or barbell forms can be seen and may also look like a cut-section of helminth.

(b) Fungal Culture

The culture is done on conventional fungal media like SDA and BHI blood agar but **without actidione**. The organism grows moderately rapidly initially as a glabrous to velvety colony that later on produces aerial mycelia. The colonies are white and may have buff to pale brown center, however, on reverse side, the color is cream to pale brown. Microscopically, there are branching septate hyphae with diameter of about 0.5-2 µm. Many conidia, with 2-5 µm diameter, are produced on conidiophores that branch at right angles from vegetative hyphae.

The conidiation in both species is enhanced on potato dextrose agar. For their differentiation, it is mandatory to grow at higher than the ambient temperature *i.e.* 25°C on enriched media. When conidia and hyphae of *Ea.parva* are inoculated on media at **40°C**, mycelium degenerates but **mononucleate** adiaconidia enlarge to a size of 15-25 µm and some of these may develop up to 40 µm or more with a 2 µm thick wall. On the other hand, *Ea.crescens* can grow *in vitro* on **phytone yeast-extract agar** within 10-12 days at **37°C** and not at 40°C. Its thick-walled **multinucleate** adiaconidia may be demonstrated, which attain diameter of 50-500 µm with wall thickness upto 70 µm **(Fig. 32.2)**. Some of the adiaconidia presented with rudimentary hyphae resemble germ tubes.

Urease test found to be positive, which is otherwise commonly seen in basidiomycetes. The exoantigen testing is also helpful to establish an early diagnosis of adiaspiromycosis, which may show non-specific precipitin lines against *B.dermatitidis* and *H.capsulatum* antisera. The PCR amplification and sequencing of rDNA gene fragments of cultured organism is also employed to confirm diagnosis.

(c) Immunodiagnosis

At present there is no reliable serological test available to establish diagnosis of adiaspiromycosis. Haplosporangin skin test has been done in a few case reports in which antigen is prepared from *Ea.parva*. However, there may be cross-reactivity with other dimorphic fungi like *Blastomyces*, *Histoplasma*, *Paracoccidioides* and *Coccidioides* species.

(d) Animal Pathogenicity

Various studies have been carried out experimentally in mice and other rodents. The conidial suspensions of *Ea.crescens* were inoculated through intranasal, intraperitoneal, subcutaneous or intravenous routes. The asexual conidia developed into adiaconidia, which are distributed in almost all soft tissues of body viscera especially lungs, liver and spleen. Experimental animal infected by intraperitoneal inoculation develop adiaconidia within granuloma in liver, spleen, kidneys, peritoneum or other organs.

Treatment and Prophylaxis

For the treatment of adiaspiromycosis, it is yet to establish that antifungal therapy has any significant role or not.

JAYPEE BROTHERS

There are claims of imidazole derivatives like ketoconazole successfully tried among these patients with a dose of 200 mg per day for one year. The disappearance of symptoms and clearing of lungs may be direct result of antifungal therapy with ketoconazole. Thiabendazole has been successfully tried in some patients. Itraconazole may also be given 200 mg per day. Surgical intervention with limited resection may be required if condition of patient progresses to deterioration. The role of corticosteroids in its treatment remains more or less unexplored.

II. EMERGOMYCOSIS

Emergomycosis is a systemic fungal infection presenting with cutaneous and disseminated clinical manifestations. This is caused by three dimorphic fungal species belonging to a newly described genus *Emergomyces i.e. Emergomyces pasteurianus* comb. nov. and *Emergomyces africanus* sp. nov. and *Emergomyces orientalis* sp. nov., which were formerly classified under genus *Emmonsia* either as *Emmonsia pasteuriana* or *Emmonsia*-like species. As the name of the genus is replaced from *Emmonsia* to *Emergomyces*, consequently name of the disease has also been changed from emmonsiosis to emergomycosis.

Only a very few cases of emergomycosis caused by *Es.pasteurianus i.e.* five, have been reported in the literature till date. In South Africa, the etiological agent of this disease is another species *i.e. Emergomyces africanus*, till recently was under taxonomical speciation. It is most closely related to *Es.pasteurianus*, which is a very rare cause of disseminated infection among immunocompromised hosts. It may be merely the "tip of an iceberg" and more cases may be reported in the times to come. This disease highlights the emerging nature of this infection *i.e.* other than those caused by classical dimorphic fungal genera like *Histoplasma* and related fungi. As far as the third species is concerned, *Emergomyces orientalis*, its case report is from China.

The members of the sister genus *Emmonsia* are *Ea.parva* and *Ea.crescens*, the agents of adiaspiromycosis, a granulomatous lung disease of rodents and occasionally humans following inhalation of asexual conidia that once lodge in the lungs, transform into large adiaconidia. This has already been described in the earlier part of this Chapter and now emergomycosis is precisely being described. In this section the geographical distribution, clinical presentation, diagnostic findings and management of five cases caused by *Es.pasteurianus,* first 56 patients with disseminated caused by *Emergomyces africanus* reported in South Africa as well as a case of *Emergomyces orientalis*, are summarized to highlight this disease.

Historical Perspective

On June 5, 1999, at the ECMM Congress held in the historical city Dresden (Germany), Edouard Drouhet delivered amazing lecture on *Emmonsia pasteuriana*, the new dimorphic fungal species of genus *Emmonsia* he had identified and named to commemorate Louis Pasteur, one of the greatest scientist of 19th century. Now, this very species is renamed as *Emergomyces pasteurianus* by Dukik *et al* with its abbreviation as *Es.pasteurianus* in 2017.

The first thermally dimorphic *Emergomyces* species to be recognized was *Es.pasteurianus*, isolated in 1994 from a HIV-infected Italian woman with a disseminated mycosis. Since then, 5 cases have been reported in immunocompromised patients from Spain, China and India. *Es.pasteurianus*, is a non-adiaconidia forming species, had been isolated from one patient from Italy, one patient from Spain and two patients from China. The Indian case is the fifth one of disseminated infection in the world and the first case from India.

A new fungus causing disseminated infections in patients with AIDS was identified in 2009. Molecular identification on the basis of ITS1 and ITS2 sequencing showed that all isolates of this new species were tightly clustered and were most similar to *Es.pasteurianus* and *Ea.parva* and slightly more distantly related to *Histoplasma capsulatum*. Now, it has been named as *Emergomyces africanus* by Dukik *et al* in 2017 and is abbreviated as *Es.africanus.*

The third type of fungal strain, reported from Shanxi (China) by Wang *et al,* in 2005 was identified as *Emmonsia* species in 2009 and subsequently established as novel species of this genus *i.e. Emergomyces orientalis* in 2017 and is abbreviated as *Es.orientalis.* The disease caused by all these three species is called as **emergomycosis**.

Mycology

This polyphyletic group of pathogens includes at least seven separate taxa, among which three species are properly named. In addition, there are two other members of the sister genus, *Ea.parva* and *Ea.crescens*, these do not cause disseminated disease but rather cause a distinct clinical syndrome called adiaspiromycosis. This granulomatous lung

JAYPEE BROTHERS

disease is caused by the host response to adiaconidia, enormous, sessile cells that follow transformation from inhaled conidia. Infection with dimorphic *Emergomyces* species is also presumed to follow inhalation of conidia, however, instead of forming adiaconidia, they transform to yeast-like cells capable of replication, extra-pulmonary dissemination and a full fledged disease.

New species, *Emergomyces africanus*, with phylogenetic and clinical similarities to genera *Blastomyces* and *Histoplasma*, have emerged as causes of systemic human mycoses worldwide. They differ from classical *Emmonsia* species by producing a thermally dependent, yeast-like phase rather than adiaconidia and by causing disseminated infections, predominantly in immunocompromised patients and often with high mortality. Such differences are important for clinicians to consider diagnosis and management of patient as well as for microbiologists who may encounter these fungi with increasing frequency.

At present there are three species of the genus *Emergomyces*, which are known as agents of emergomycosis among the mammals. *Es.pasteurianus* is a recently described species from cases of disseminated cutaneous mycosis in an AIDS patients. This species was morphologically compatible with the genus *Emmonsia* but phylogenetically distinct from *Ea.parva* and *Ea.crescens*. In addition, at 37°C on BHI agar or in host tissue, yeast-like budding cells with a few larger thick-walled cells are formed but adiaconidia are definitely absent. The differentiating features between species of *Emergomyces vis-a-vis Ea.crescens* and *Ea.parva* are given in **Table 32.1**.

At 25°C on light microscopy, preparations show, thin hyaline septate hyphae, 1 to 1.2 µm in diameter, with numerous smooth-walled conidia that are oval to subglobose. The conidia are borne on thin pedicles (0.4 to 0.5 µm wide) that formed perpendicular to an ampulliform vesicle. These vesicles gave rise to single pedicles at first, then four to eight pedicles, each forming a terminal conidium, establishing a **floret** of four to eight conidia grouped together. Conidia are attached to the pedicles by their long axes, appearing flattened on top with slightly rough-ended walls after 21 to 30 days. Scanning electron microscopy can confirm these features.

There are three species grouped in genus *Emergomyces*. One of them was given binomial nomenclature by Drouhet *et al,* in 1999 as *Emmonsia pasteuriana*, which is now re-named as *Emergomyces pasteurianus*. *Emergomyces* is placed in family **Onygenaceae** of order **Onygenales** under class **Plectomycetes** in phylum **Ascomycota**. The mycelial colonies of this fungus have been successfully converted to yeasts in golden hamster by intratesticular inoculation.

Epidemiology

The global epidemiology of thermally dimorphic fungi causing disseminated emergomycosis has recently been reviewed. Very little is known about *Emergomyces* species or the disease caused by this fungus. Emergomycosis is caused by dimorphic fungi, which were very near to the genus *Emmonsia*. Earlier, *Es.pasteurianus* infection was described in a single human case that of an Italian patient with late-stage of AIDS but has not been found in any animal or environmental source.

There are total 56 cases caused by *Emergomyces africanus* till date, with (sub)cutaneous infections have been reported. None of these were identified as *Ea.crescens* or *Ea.parva*. Two disseminated (sub)cutaneous infections due to *Es.pasteurianus*, presented with scattered nodular lesions and some ulcerated with a central necrotic crust. Previously unknown fungus, *Emergomyces africanus* was implicated in disseminated skin infections in a case series of 18 HIV-infected adults in South Africa. Most of the patients concerned had widespread skin lesions, varying from erythematous papules and plaques with or without scales to ulcers and crustation. Only a single patient showed evidence of central umbilication, which is typically observed in dimorphic fungal skin infections such as talaromycosis and histoplasmosis. Similar to the second case of *Es.pasteurianus* infection and case 2 in Heys *et al*'s report, the patient was also an organ transplant recipient who received long-term immunosuppressive therapy. The patient developed respiratory failure soon after admission and CT of the lungs revealed widespread bilateral pulmonary infiltrates with multiple small nodules.

Molecular sequencing has since confirmed that these fungi belong to a cluster of novel *Emergomyces africanus* species. It remains unclear whether this cluster of *Es.africanus* species only emerged recently as human pathogens or whether previous infections were merely underestimated. Support for the latter hypothesis comes from South Africa, where the introduction of molecular identification tools resulted in a dramatic increase in the number of cases of disseminated emergomycosis, commensurate with a decline in the number of cases of confirmed histoplasmosis.

Es.pasteurianus is a thermally dimorphic fungus identified subsequently in very few human cases. There was a

JAYPEE BROTHERS

recent report of case of 43-year-old male renal transplant patient from China presenting with multiple painful skin eruptions on his head, nose and left thigh, later accompanied by respiratory failure. Histopathology of the biopsy collected from the left thigh upper ulcer and occipital nodule both demonstrated chronic inflammation with granuloma formation and yeast-like elements. *Es.pasteurianus* was cultured from two biopsy specimens and their identity was confirmed by sequencing of the rDNA internal transcribed spacer. The patient in intensive care showed marked clinical improvement with antifungal treatment.

Hence only five human cases of *Es.pasteurianus* have been reported, including an Italian woman with AIDS and a transplant recipient with HIV from Spain. The third case of (sub)cutaneous infection due to *Es.pasteurianus*; a fourth, very similar case from the same city, Guangzhou in China, was found recently in a clinic.

On the other hand, the highest burden of emergomycosis appears to be in South Africa, where a novel *Emergomyces africanus* species was recently recognized as the cause of an AIDS-related mycosis. Between 2008 and 2015, when molecular techniques were introduced to augment phenotypic identification of dimorphic fungi in South Africa, 56 cases were diagnosed, although this likely represents the "tip of the iceberg". All cases have occurred in profoundly immunocompromised individuals. Earlier reports of disease in immunocompetent patients were, in fact, due to another novel species of dimorphic fungus endemic to South Africa that appears to be more closely related to *Blastomyces* species, which eventually turned out to be a novel species, *Blastomyces percursus.*

The true geographic range of these organisms is currently unknown, although cases have been reported sporadically from North America, Europe, and Asia. The understanding of the range within sub-Saharan Africa is hampered, in part, by limited capacity for diagnostic mycology in many countries. The possibility is not excluded that other cases have been missed due to lack of awareness of the disease and misidentification of the etiological agent, as was observed with the *Es.africanus* epidemic in South Africa.

Emergomyces is a cosmopolitan soil saprobe found in all temperate climates and lives of decaying organic matter. It has been isolated from a variety of mammalian species, particularly small rodents. The geographic distribution of cases of disseminated emergomycosis was wider than previously reported and patients were diagnosed in 5 of 9 South African provinces. However, it is presumed that the true burden of disease is underestimated. Public hospitals, which provide care to roughly 85% of the population, contributed only 24% of emergomycosis cases described from outside Western Cape Province. In contrast, 92% of cases diagnosed in the Western Cape were from public hospitals.

The pulmonary route is commonly observed in dimorphic fungal disseminated skin infections. This also holds true for other case, where respiratory failure was probably due to pulmonary dissemination of the emergomycosis although no proven infection in the lungs was achieved. Successful antifungal treatment and increasing levels of β-D-glucan on G-Test strongly imply that a pulmonary infection due to *Es.pasteurianus* was the progressive underlying disease.

Disseminated emergomycosis presented a diagnostic challenge, even to experienced clinicians and a quarter of patients died prior to the diagnosis of a deep fungal infection. This series included only cases with a confirmed mycological diagnosis and thus it is likely that the true proportion of patients who remain undiagnosed or misdiagnosed is even higher. The most common diagnostic dilemma encountered by clinicians was differentiating emergomycosis from tuberculosis, inferred by the fact that three-quarters of patients were treated for later disease.

Pathogenesis and Pathology

Reports of *Emergomyces* have increased in recent years, presenting as disseminated cutaneous mycosis in persons with underlying AIDS infections. Unlike *Ea.parva* and *Ea.crescens*, *Emergomyces* does not produce adiaconidia and therefore does not cause adiaspiromycosis. *Emergomyces* species appear as yeasts in infected tissue.

Clinical Features

The clinical presentation of the patients of emergomycosis is very similar to the progressive disseminated histoplasmosis or talaromycosis among the immunocompromised hosts. The clinical features of infection include fever, loss of weight, anaemia, skin lesions similar to those in disseminated histoplasmosis and chest radiograph similar to that noted in pulmonary tuberculosis. There are mainly two types of presentations *i.e.* cutaneous and disseminated, which are being described here:-

1. Cutaneous Emergomycosis

The cutaneous presentation is most common, occurring in more than 95% of patients at the time of diagnosis. Skin

JAYPEE BROTHERS

lesions usually include widespread papules and/or plaques, although other morphologies can also occur. The infection frequently becomes apparent as part of an unmasking immune reconstitution inflammatory syndrome (IRIS), with cutaneous lesions appearing weeks or months after initiating antiretroviral therapy (ART).

Cutaneous manifestations of emergomycosis are also commonly misdiagnosed, most often as varicella, Kaposi sarcoma and drug reactions. The protean nature of cutaneous involvement is highlighted by the fact that deep fungal infections were considered unlikely or not considered at all, in the documented differential diagnoses of dermatologists in more than one-quarter of the cases examined by them.

All the patients are found to be anemic and all had widespread skin lesions. Morphologically, these lesions varied from erythematous papules and plaques with or without scales to ulcers and crusted, boggy plaques. The larger plaques and ulcers healed with marked scarring and the smaller lesions healed with residual hyperpigmentation. Mucosal ulceration of the penis was noted in one patient and another had scaly papules on the lips. The lesions in two patients showed evidence of central necrosis and in one there was evidence of central umbilication.

2. Disseminated Emergomycosis

The dissemination emergomycosis may lead to multifocal disease that involve extrapulmonary sites also. In retrospect, ART was usually started, along with empiric antitubercular therapy, in response to constitution and pulmonary symptoms that likely represented protean manifestations of the disease. In addition to cutaneous and lung disease, any of the body system may become involved, including hepatic, reticuloendothelial and gastrointestinal systems. Most of these patients have clinically advanced HIV disease with very low CD4+ T-cell counts.

Differential Diagnosis

The clinical findings of emergomycosis are non-specific and pulmonary disease can easily be mistaken for bacterial or *Pneumocystis* pneumonia, tuberculosis or Kaposi's sarcoma. It should be differentiated from tuberculosis where caseation is the prominent feature. The chest radiography are frequently abnormal, even when respiratory symptoms are not part of the presenting complaint. Over the last four decades, reports have emerged of patients with unusual mycoses: in the laboratory, cultures have isolated molds with asexual reproductive structures that resembled *Emmonsia* but clinical and histopathological pictures were more compatible with blastomycosis or histoplasmosis than adiaspiromycosis. At various stages of development, *Emergomyces* species may resemble other fungi in their phenotypic stages such as *Histoplasma capsulatum*, *Blastomyces dermatitidis*, *Paracoccidioides brasiliensis*, *Talaromyces marneffei* and *Chrysosporium* species.

Laboratory Diagnosis

As such any case of emergomycosis is defined when a patient with a clinically compatible illness has laboratory confirmation of infection with *Emergomyces* species, identified either by fungal culture or nucleic acid detection from the clinical specimens. The skin biopsy is a valuable diagnostic tool, with yeasts seen on histology in majority of the biopsied patients. Skin biopsy for histological examination is also inexpensive, non-invasive technique and has the potential for earlier turnaround of results than culture-based diagnostics.

(a) Direct Examination

The causative fungus is dimorphic in nature hence direct demonstration of yeast form is pertinent to establish the diagnosis by using various conventional and molecular techniques. The biopsy of affected tissue for histopathology is the most expedient way to diagnose a deep-seated fungal infection, although features are identical to those of other dimorphic mycoses including histoplasmosis and sporotrichosis. Therefore, KOH/CFW wet mounts, H&E, PAS and GMS stains are usually used for establishing the diagnosis. The typical yeast cells with narrow-base budding are visualized.

Emergomyces species are usually present in the infected tissue as intrahistiocytic budding yeast cells. Hence this can be easily mistaken for other fungal and/or protozoal infections characterized by the presence of histiocytes with phagocytosed organisms. While doing histopathological examination, it should be differentiated from other intracellular organisms like *H.capsulatum* and *Talaromyces marneffei*, the dimorphic fungi in their yeast phase as well as two protozoa - *Leishmania donovani* and *Toxoplasma gondii*. *L.donovani* contains kinetoplast, which is not present in the yeasts. The tachyzoites of *T.gondii*, being protozoa are not stained with GMS stain.

(b) Fungal Culture

Culture of skin biopsy tissue or blood on standard fungal media is usually diagnostic, although growth may take

JAYPEE BROTHERS



Fig. 32.3. Growth of *Emergomyces pasteurianus* showing yeast-like colonies on SDA at 37°C.



Fig. 32.4. Growth of *Emergomyces pasteurianus* showing mycelial growth on SDA at 25°C.



Fig. 32.5. *Emergomyces pasteurianus* showing thin hyaline septate hyphae, perpendicular slender conidiophore and terminal single or multiple conidia (LCB × 400).

up to four weeks of incubation. The sensitivity of blood cultures is enhanced by use of mycobacterial/fungal blood culture bottles. Bone marrow cultures may also yield the diagnosis.

Emergomyces is not inhibited by cycloheximide and therefore can be grown on media containing this selective agent. It exhibits slow to moderate growth at 30°C, with a colony diameter of about 25 mm after 10 days and 60 mm after 21 days. The colony appears velvety to powdery in texture with folded, wrinkled or cerebriform surface contours **(Fig. 32.3)**. The colony spontaneously acquired splits in the surface as it aged. The colony is primarily white in color and remains so and may develop a light brown color as it ages **(Fig. 32.4)**. The reverse is tan or light brown in color. On potato dextrose agar at 25°C, colonies grow moderately rapid, white to tan colored. The colonies produce no diffusible pigment as seen in *Talaromyces marneffei*. Slide cultures of the mycelial growth shows hyaline, septate hyphae. The conidia are one-celled, sessile or on stalks alongside hyphae or on ampulliform conidiophores. Initially a conidium may be found at the end of delicate pedicle, which may then develop further to form four to eight pedicles with conidia, establishing a **'floret'**. The conidia occurring in small bunches, each on its own pedicle, branching off from a central delicate pedicle **(Fig. 32.5)**.

The pure, single-conidium subcultures are obtained from primary cultures grown on Sabouraud dextrose agar, incubated at 25°C in the dark. In general, colonies grow at a slow-to-moderate rate, reaching a diameter of 15 to 25 mm after 7 to 14 days, up to a maximum of 50 to 60 mm in 21 days. They appear glabrous in some early cultures or showed densely white growth, taking on a folded, wrinkled or cerebriform appearance and became light brown with powdery segments over time. Cultures grew well at 30°C on both Sabouraud dextrose agar and brain-heart infusion agar, forming slightly larger colonies as compared with those grown at 25°C. No diffusible pigment is noted and reverse side of colonies is either tan or yellow-brown, with darker brown pigment in the folds or groves of older colonies. None of the strains grow at 40°C and no adiaconidia are produced at this temperature.

Emergomyces is a dimorphic fungus as it exhibits the filamentous form at one temperature and the yeast form

JAYPEE BROTHERS

at another. The filamentous fungus form can be converted to the yeast form by incubating a freshly inoculated culture at 37°C for 10 to 14 days. The conversion is enhanced by cultivation on the nutritionally richer Brain-Heart Infusion (BHI) agar. Smooth, butyrous colonies appear cream to beige in color, which may darken as they age. Colonies consist of globose to oval yeast colonies, which may show narrow-based budding.

The mycelial cultures are converted to the yeast phase by incubating streaked or single-colony subcultures on brain-heart infusion agar at 37°C after 10 to 14 days. Yeast colonies appeared smooth, with a cream-to-beige color that became light brown with age. Light microscopy reveals small, thin-walled, globose-to-oval yeasts (2-4 µm), with mostly single but occasionally multiple, polar budding yeasts formed from a narrow base attachment. The macroscopic and microscopic features of these isolates are indistinguishable from those of *Es.pasteurianus.*

At 37°C on brain heart infusion agar, a rough and wrinkled yeast-like colony are is formed. Light microscopy reveal budding yeast-like cells, some with larger, thick-walled cells at the tip of short hyphae. There are no adiaconidia are seen at 37°C.

The cultured isolates are confirmed as *Emergomyces* species with a broad-range fungal polymerase chain reaction (PCR) and sequencing of the internal transcribed interspacer region or based on phenotypic characteristics of colonies based on macroscopic and microscopic examination. To confirm the identity of the isolate, molecular verification of mycelium and yeast-like cells are performed. Internal transcribed spacer (ITS) rDNA is amplified using primers ITS 5 and ITS 4.3. ITS sequences of standard strains showing 99.3% similarity with the type strain of *Es.pasteurianus*. Molecular investigation and histopathological observations confirm and expand the mycological diagnosis, leading to a final diagnosis of a disseminated mycosis due to *Es.pasteurianus.*

(c) Immunodiagnosis

Urine *Histoplasma* antigen may prove a useful diagnostic tool, given the apparent cross-reactivity with *Emergomyces* species. Infection, wherein 2 of 3 patients with disseminated emergomycosis give positive tests. It has been noted that some cross-reaction giving false positive results may occur between *Emergomyces* species and *Blastomyces dermatitidis* with both DNA probe and direct immunofluorescent-antigen tests.

(d) Animal Pathogenicity

The yeast tissue phase of *Es.pasteurianus* was demonstrated by inoculating in golden hamster through intratesticular route establishing the dimorphic nature of the newly emerged fungal species.

Treatment and Prophylaxis

There are no significant prospective studies conducted on emergomycosis for evaluating treatment for future strategies. Therefore, in the absence of more definitive data, it is empirically recommended to follow the IDSA guidelines applied to other endemic mycoses in immunocompromised hosts. As such amphotericin B appears to be important followed by suppressive itraconazole therapy until immune reconstitution. An optimal timing of ART initiation among such patients remains unknown and clinicians should be aware of the potential for clinical worsening due to the IRIS.

The disseminated emergomycosis is invariability fatal if remain untreated. The patients are treated with an antifungal regimen that included amphotericin B are more likely to survive than those treated with a triazole alone. Moreover, both the triazoles *i.e.* fluconazole and itraconazole are associated with poor outcomes. However, in most patients treated with fluconazole, which is prescribed incidentally for esophageal candidiasis in doses and for durations considered inadequate for the treatment of severe disseminated disease caused by other endemic mycoses.

Further Reading

1. Anstead GM, Sutton DA, Graybill JR. Adiaspiromycosis causing respiratory failure and a review of human infections due to *Emmonsia* and *Chrysosporium* spp. *J Clin Microbiol.* 2012; **50:** 1346-54.
2. Bambirra EA, Nogueira AMMF. Human pulmonary granulomas caused by *Chrysosporium parvum* var. *crescens (Emmonsia crescens). Am J Trop Med Hyg.* 1983; **32:** 1184-5.
3. Barbas Filho JV, Amato MB, Deheinzelin D, *et al.* Respiratory failure caused by adiaspiromycosis. *Chest.* 1990; **97:** 1171-5.
4. Borman AM, Simpson VR, Palmer MD, *et al.* Adiaspiromycosis due to *Emmonsia crescens* is widespread in native British mammals. *Mycopathologia*. 2009; **168:** 153-63.
5. Bottone EJ. Histologic diagnosis of cutaneous adiaspiromycosis in the absence of successful culture of *Emmonsia crescens* or *Emmonsia parva*. *Clin Microbiol Newsletter*. 2011; **33:** 131-4.
6. Buyuksirin M, Ozkaya S, Yucel N, *et al.* Pulmonary adiaspiromycosis: The first reported case in Turkey. *Resp Med CME*. 2011; **4:** 166-9.

JAYPEE BROTHERS

7. Chandler FW, Kaplan W, Ajello L. Adiaspiromycosis. *In:* Histopathology of Mycotic Diseases. Wolfe Medical Publications, London: 1980; 30-3 & 138-43.
8. Ciferri R, Montemartini A. Taxonomy of *Haplosporangium parvum*. *Mycopathol Mycol Appl*. 1959.**10:** 303-16.
9. Cueva JA, Little MD. *Emmonsia crescens* infection (adiaspiromycosis) in man in Honduras. Report of a case. *Am J Trop Med Hyg*.1971; **20:** 282-7.
10. de Almeida Barbosa A, Moreira Lemos AC, Severo LC. Acute pulmonary adiaspiromycosis - Report of three cases and a review of 16 other cases collected from the literature. *Rev Iberoam Micol*.1997; **14:** 177-80.
11. Denson JL, Keen CE, Froeschle PO, *et al*. Adiaspiromycosis mimicking widespread malignancy in a patient with pulmonary adenocarcinoma. *J Clin Pathol.* 2009; **62:** 837-9.
12. Doby-Dubois M, Chevrel ML, Doby JM, *et al*. 1st human case of adiaspiromycosis, caused by *Emmonsia crescens*, Emmons and Jellison, 1960. *Bull Soc Pathol Exot*. 1964; **57:** 240-4.
13. dos Santos VM, Fatureto MC, Saldanha JC, *et al*. Pulmonary adiaspiromycosis: Report of two cases. *Rev Soc Bras Med Trop*. 2000; **33:** 483-8.
14. Dot JM, Debourgogne A, Champigneulle J, *et al*. Molecular diagnosis of disseminated adiaspiromycosis due to *Emmonsia crescens*. *J Clin Microbiol*. 2009; **47:** 1269-73.
15. Dowding ES. The pulmonary fungus, *Haplosporangium parvum* and its relationship with some human pathogens. *Can J Res Sect E Med Sci*. 1947; **25:** 195-206.
16. Drouhet E, Huerre M. Yeast tissue phase of *Emmonsia pasteuriana* inoculated in golden hamster by intratesticular way. *Mycoses.* 1999; **42 (Suppl. 2):** 11-8.
17. Drouhet E, Gueho E, Gori S, *et al.* Mycological, ultrastructural and experimental aspects of a new dimorphic fungus *Emmonsia pasteuriana* sp. nov. isolated from a cutaneous disseminated mycosis in AIDS. *J Mycol Med.* 1998; **8:** 64-77.
18. Dukik K, Munoz JF, Jiang Y, *et al.* Novel taxa of thermally dimorphic systemic pathogens in the Ajellomycetaceae (Onygenales). *Mycoses*. 2017; **60:** 296-309.
19. Echevarria E, Cano EL, Restrepo A. Disseminated adiaspiromycosis in a patient with AIDS. *J Med Vet Mycol*. 1993; **31:** 91-7.
20. Emmons CW, Ashburn LL. The isolation of *Haplosporangium parvum* n. sp. and *Coccidioides immitis* from wild rodents. *Public Health Rep*. 1942; **57:** 1715-27.
21. Emmons CW, Jellison WL. *Emmonsia crescens* sp. nov. and adiaspiromycosis (haplomycosis) in mammals. *Ann N Y Acad Sci*. 1960; **89:** 91-101.
22. England DM, Hochholzer L. Adiaspiromycosis: An unusual fungal infection of the lung: Report of 11 cases. *Am J Surg Pathol*. 1993; **17:** 876-86.
23. Feng P, Yin S, Zhu G, *et al.* Disseminated infection caused by *Emmonsia pasteuriana* in a renal transplant recipient. *J Dermatol.* 2015. **42:** 1179-82.
24. Filho JVB, Amato MBP, Deheinzelin D, *et al*. Respiratory failure caused by adiaspiromycosis. *Chest*. 1990; **97:** 1171-5.
25. Gori S, Drouhet E. Cutaneous disseminated mycosis in a patient with AIDS due to a new dimorphic fungus. *J Mycol Med.* 1998; **8:** 57-63.
26. Heys I, Taljaard J, Orth H. An *Emmonsia* species causing disseminated infection in South Africa. *N Engl J Med.* 2014; **370:** 283-4.
27. Hubalek Z, Burda H, Scharff A, *et al.* Emmonsiosis of subterranean rodents *(Bathyergidae, Spalacidae)* in Africa and Israel. *Med Mycol.* 2005; **43:** 691-7.
28. Hubalek Z, Nesvadbova J, Halouzka J. Emmonsiosis of rodents in an agro-ecosystem. *Med Mycol.* 1998; **36:** 387-90.
29. Hubalek Z. Emmonsiosis of wild rodents and insectivores in Czechland. *J Wildl Dis.* 1999; **35:** 243-9.
30. Kamalam A, Thambiah AS. Adiaspiromycosis of human skin caused by *Emmonsia crescens*. *Sabouraudia*. 1979; **17:** 377-81.
31. Kappagoda S, Adams JY, Luo R, *et al*. Fatal *Emmonsia* sp. infection and fungemia after orthotopic liver transplantation. *Emerg Infect Dis*. 2017; **23:** 346-9.
32. Kemna ME, Weinberger M, Sigler L, *et al.* A primary oral blastomycosis-like infection in Israel. Abstr. F-75. 94th General Meeting of ASM. Washington, DC; 1994. p.601.
33. Kenyon C, Bonorchis K, Corcoran C, *et al.* A dimorphic fungus causing disseminated infection in South Africa. *N Engl J Med.* 2013; **369:** 1416-24.
34. Kenyon C, Corcoran C, Govender NP. An *Emmonsia* species causing disseminated infection in South Africa. *N Engl J Med.* 2014; **370:** 283-4.
35. Kodousek R, Vortel V, Fingerland A, *et al*. Pulmonary adiaspiromycosis in man caused by *Emmonsia crescens*: Report of a unique case. *Am J Clin Pathol*. 1971; **56:** 394-9.
36. Krivanec K. Adiaspiromycosis in Czechoslovakian mammals. *Sabouraudia*. 1977; **15:** 221-3.
37. Latge JP. Oh, to be new. *N Engl J Med.* 2013; **369:** 1464-6.
38. Lochan H, Naicker P, Maphanga T, *et al.* A case of emmonsiosis in an HIV-infected child. *S Afr J HIV Med.* 2015; **16:** 1-4.
39. Malik R, Capoor MR, Vanidassane I, *et al.* Disseminated *Emmonsia pasteuriana* infection in India: A case report and a review. *Mycoses.* 2016; **59:** 127-32.
40. Maphanga TG, Britz E, Zulu TG, *et al*. *In vitro* antifungal susceptibility of the yeast- and mould-phases of the dimorphic fungal pathogen, *Emergomyces africanus* (formerly *Emmonsia* species) from HIV-infected South African patients. *J Clin Microbiol*. 2017; **55:** 1812-20.
41. Marin-Felix Y, Stchigel AM, Cano-Lira JF, *et al. Emmonsiellopsis*: A new genus related to the thermally dimorphic fungi of the family Ajellomycetaceae. *Mycoses*. 2015; **58:** 451-60.
42. Matsuda K, Niki H, Yukawa A, *et al*. First detection of adiaspiromycosis in the lungs of a deer. *J Vet Med Sci.* 2015; **77:** 981-3.
43. Mendes MO, Moraes MA, Renoiner EI, *et al*. Acute conjunctivitis with episcleritis and anterior uveitis linked to adiaspiromycosis and freshwater sponges, Amazon region, Brazil, 2005. *Emerg Infect Dis*. 2009; **15:** 633-9.

JAYPEE BROTHERS

44. Munoz JF, Gauthier GM, Desjardins CA, *et al.* The dynamic genome and transcriptome of the human fungal pathogen *Blastomyces* and close relative *Emmonsia*. *PLoS Genet.* 2015; **11:** e1005493. PMID: 26439490.
45. Mutyaba A, Sonderup MW, Locketz M, *et al.* Disseminated *Emmonsia* in an HIV-HBV co-infected man. *ID Cases*. 2015; **2:** 35-6.
46. Nuorva K, Pitkanen R, Issakainen J, *et al*. Pulmonary adiaspiromycosis in a two-year old girl. *J Clin Pathol*. 1997; **50:** 82-5.
47. Otcenasek M, Ditrich O. Comparative susceptibility of the agents of adiaspiromycosis to imidazole derivatives *in vitro*. *Sabouraudia*. 1983; **21:** 239-42.
48. Pelegrin I, Alastruey-Izquierdo A, Ayats J, *et al.* A second look at *Emmonsia* infection can make the difference. *Transpl Infect Dis.* 2014; **16:** 519-20.
49. Pelegrin I, Ayats J, Xiol X, *et al*. Disseminated adiaspiromycosis: Case report of a liver transplant patient with human immunodeficiency infection and literature review. *Transpl Infect Dis*. 2011; **13:** 507-14.
50. Peres LC, Figueiredo F, Peinado M, *et al*. Fulminant disseminated pulmonary adiaspiromycosis in humans. *Am J Trop Med Hyg*. 1992; **46:** 146-50.
51. Peterson SW, Sigler L. Molecular genetic variation in *Emmonsia crescens* and *Emmonsia parva*, etiologic agents of adiaspiromycosis and their phylogenetic relationship to *Blastomyces dermatitidis* (*Ajellomyces dermatitidis*) and other systemic fungal pathogens. *J Clin Microbiol*. 1998; **36:** 2918-25.
52. Pfaller MA, Diekema DJ. Unusual fungal and pseudofungal infections of humans. *J Clin Microbiol.* 2005; **43:** 1495-504.
53. Randhawa HS. Respiratory and systemic mycoses: An overview. *Indian J Chest Dis Allied Sci.* 2000; **42:** 207-19.
54. Roy P, Sahni AK, Sriram R *et al. Sporotrichum pruinosum* causing a rare invasive infection in an immunocompromised patient. *Med J Armed Forces India*. 2015; **71:** S456-9.
55. Sanche S, Wong A, Sigler L, *et al.* Invasive infection caused by a novel *Emmonsia* species in a renal transplant patient. *Focus on Fungal Infections.* Miami; 2005. Abstract 87.
56. Schwartz IS, Govender NP, Corcoran C, *et al.* Clinical characteristics, diagnosis, management and outcomes of disseminated emmonsiosis: A retrospective case series. *Clin Infect Dis.* 2015; **61:** 1004-12.
57. Schwartz IS, Kenyon C, Feng P, *et al.* 50 years of *Emmonsia* disease in humans: The dramatic emergence of a cluster of novel fungal pathogens. *PLoS Pathog.* 2015; **11:** e1005198.
58. Schwartz IS, Kenyon C, Thompson III GR. Endemic mycoses: What's new about old diseases? *Curr Clin Micro Rpt.* 2016; **3:** 71-80.
59. Schwarz J. Adiaspiromycosis. *Pathol Annu*. 1978; **13:** 41-53.
60. Severo LC, Geyer GR, Camargo JJ, *et al*. Adiaspiromycosis treated successfully with ketoconazole. *J Med Vet Mycol*. 1989; **27:** 265-8.
61. Sigler L, Peterson SW. Molecular genetic analysis supports recognition of new species among *Emmonsia* and *Blastomyces* isolates. *Int J Antimicrob Agents.* 2009; **34:** S593.
62. Sigler L. *Ajellomyces crescens* sp. nov. taxonomy of *Emmonsia* spp. and relatedness with *Blastomyces dermatitidis* (teleomorph *Ajellomyces dermatitidis*). *J Med Vet Mycol*. 1996; **34:** 303-14.
63. Stebbins WG, Krishtul A, Bottone EJ, *et al.* Cutaneous adiaspiromycosis: A distinct dermatologic entity associated with *Chrysosporium* species. *J Am Acad Dermatol.* 2004; **51:** S185-9.
64. Sun Y, Bhuiya T, Wasil T, *et al.* Fine needle aspiration of pulmonary adiaspiromycosis: A case report. *Acta Cytol*. 2007; **51:** 217-21.
65. Tang XH, Zhou H, Zhang XQ, *et al.* Cutaneous disseminated emmonsiosis due to *Emmonsia pasteuriana* in a patient with cytomegalovirus enteritis. *JAMA Dermatol.* 2015; **151:** 1263-4.
66. Thammayya A Sanyal M. *Chrysosporium parvum* from eczematous lesions in man. *Bull Calcutta Sch Trop Med*. 1973; **21:** 23-4.
67. Tomssikova A, Hejtmanek M. Antigenic activity of *Emmonsia crescens* mutants. *Mycopathologia*. 1978; **66:** 83-90.
68. Turner D, Burke M, Bashe E, *et al*. Pulmonary adiaspiromycosis in a patient with acquired immunodeficiency syndrome. *Eur J Clin Microbiol Infect Dis*. 1999; **18:** 893-5.
69. van Hougenhouck-Tulleken WG, Papavarnavas NS, Nel JS, *et al.* HIV-associated disseminated emmonsiosis, Johannesburg, South Africa. *Emerg Infect Dis.* 2014; **20:** 2164-6.
70. Wang P, Guo LN, Fan HW, *et al.* A dimorphic fungus *Emmonsia* sp. caused a disseminated infection in a diabetic patient in China. Abstr. ISHAM Satellite Congress, Beijing, 2009; 92.
71. Wang P, Kenyon C, de Hoog S, *et al*. A novel dimorphic pathogen, *Emergomyces orientalis* (Onygenales), agent of disseminated infection. *Mycoses*. 2017; **60:** 310-9.
72. Watts JC, Callaway CS, Chandler FW, *et al*. Human pulmonary adiaspiromycosis. *Arch Pathol*. 1975; **99:** 11-5.
73. Watts JC, Chandler FW. Adiaspiromycosis: An uncommon disease caused by an unusual pathogen. *Chest*. 1990; **97:** 1030-1.
74. Wellinghausen N, Kern WV, Haase G, *et al*. Chronic granulomatous lung infection caused by the dimorphic fungus *Emmonsia* sp. *Int J Med Microbiol*. 2003; **293:** 441-5.

JAYPEE BROTHERS

for detailed information on microbiology books, visit our website **www.jaypeebrothers.com,** for detailed information on microbiology books, visit

Textbook of
Medical Mycology

The fourth edition of *Textbook of Medical Mycology* is thoroughly revised, updated and enlarged. This has been designed to comprehensively cover the rapid and extensively expanding information in the field of Medical Mycology in a concise, lucid and easily understandable manner. This edition is also incorporating several new reader-friendly features.

Salient Features

- All the chapters have been rewritten and arranged in eight sections including one section on Appendices dealing with technical details, which is designed to supplement the basic text of the book by providing more clarity on the topics. However, one of the Appendices is devoted on AFST, keeping in view difficulties faced in choosing an appropriate drug.
- The colored photographs and photomicrographs have been inserted in the text throughout. The illustrations and tables have been designed concisely to summarize the text, making the subject matter more vivid and easy to recall.
- The section on Pseudofungal Infections is given separately, keeping in view that they are looking very similar to the fungal diseases and have emerged in recent times.
- As there are unprecedented developments in taxonomy of fungi, hence, the corresponding disease names have been changed according to those of the respective fungal genera, like Malasseziosis, Talaromycosis, and Emergomycosis. Microsporidia species are now treated as fungi. Hence, a full chapter is devoted on Microsporidiosis.
- All the important references from January 2009 to June 2017 are added as Further Reading in each Chapter.

Prof. L. N. Mohapatra, former Professor & Head, Department of Microbiology, AIIMS, New Delhi.

……..This book is written for use of medical students and practitioners. The author has endeavored to incorporate information about the unprecedented progress made in this field. It provides basic information about the pathogenic fungi covering the nomenclature, biological characters, diseases caused by them, laboratory diagnosis and treatment of mycoses seen in humans. Some reports of mycotic infections from India are included in the text, with references. The efforts of the author will be rewarded if the index of suspicion is raised and laboratories are geared to provide good diagnostic services.

—Foreword to the First Edition (May 8, 1995)



Dr Jagdish Chander passed his MBBS and MD (Microbiology) from the prestigious Pt. BDS PGIMS, Rohtak, Haryana. After serving in HCMS for a few months, he joined as Senior Resident in the Department of Medical Microbiology at the PGIMER, Chandigarh, where he subsequently joined the faculty as Assistant Professor and was posted in the Division of Medical Mycology.

When the Union Territory of Chandigarh commenced a new medical institution, he joined the founder faculty as Assistant Professor in the Department of Microbiology at the GMCH, Chandigarh in the year 1992. He conceived the idea of writing Textbook of Medical Mycology in January 1994 and published its first edition in July 1995. After getting favorable response from the readers, he launched its second edition in April 2002, third edition in January 2009, and now the fourth edition of this textbook in 2017.

Dr Jagdish Chander is now working as Professor & Head, Department of Microbiology, GMCH, Chandigarh for the past twenty-five years. He has extensive knowledge in diagnostic medical mycology applicable to the patient-care services. He has traveled worldwide participating in various international as well as national workshops/conferences in Medical Mycology. He has vast experience of teaching paramedical staff, undergraduates and postgraduates in medical microbiology.

Besides the publication of this textbook, he has published a number of scientific papers of his work on diagnostic mycology in national and international journals. He is on the reviewers' panel of various scientific journals, particularly dealing with Medical Mycology. He is also an active member of International Society for Human and Animal Mycology, British Society of Medical Mycology, Netherlands Society of Mycology as well as Society for Indian Human and Animal Mycologists.

He also got exposure in the field of Medical Mycology during the training courses and workshops at the Centre for Advanced Research in Medical Mycology, PGIMER, Chandigarh; Institute of Microbial Technology, Chandigarh; HPA Mycology Reference Laboratory, Bristol; and Regional Mycology Laboratory, Wythenshawe Hospital, Manchester, UK. He was awarded fellowship through Netherlands Fellowship Programmes for undergoing 'Short Course in Medical Mycology' held at Westerdijk Fungal Biodiversity Institute (formerly CBS-KNAW), Utrecht, The Netherlands. He was awarded 'Commonwealth Academic Staff Fellowship' by the Commonwealth Scholarship Commission in the United Kingdom at the University of Manchester as the Visiting Professor under the aegis of Association of Commonwealth Universities, London.

He is actively involved in extensive philanthropic work and in analyzing contemporary socio-medical issues in a right perspective.

Available at all medical bookstores
or buy online at www.jaypeebrothers.com

JAYPEE BROTHERS
Medical Publishers (P) Ltd.
www.jaypeebrothers.com

Join us on facebook.com/JaypeeMedicalPublishers

Shelving Recommendation
MICROBIOLOGY

ISBN 978-93-86261-83-0