rdiology books, visit our website www.ejaypee.com, for detailed information on cardiology books, visit our website www.ejaypee.com, for detailed information on cardiology books

Complimentary Online Videos

Color Atlas of Cardiology

Challenging Cases

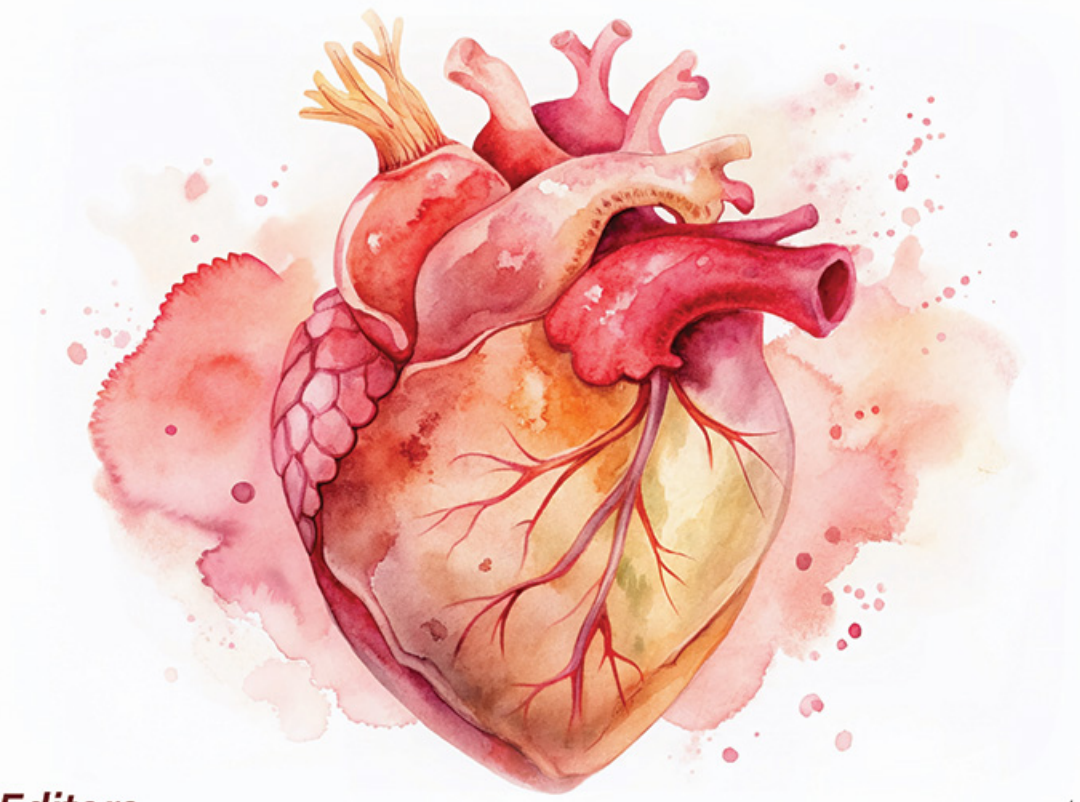

Editors
Majid Maleki
Azin Alizadehasl

JAYPEE

Contents

Chapter 1 History and Physical Examination of the Heart 1
Majid Maleki

Chapter 2 Electrocardiography Challenging Cases 10
Mohammad Javad Alemzadeh-Ansari

Chapter 3 Chest X-ray Challenging Cases 61
Hamidreza Pouraliakbar

Chapter 4 Exercise Stress Testing 84
Sedigheh Saedi

Chapter 5 Clinical Points of Echocardiography in Daily Practice 88
Azin Alizadehasl

Chapter 6 Common Coronary Angiography: Views and Courses of Catheters 121
Sedigheh Saedi

Chapter 7 Cardiovascular Hemodynamic Study 134
Sedigheh Saedi

Index ***147***

DVD Contents

Case 1: Severe Mitral Valve Stenosis, Fresh LAA Clot

Case 2: Severe Aortic Regurgitation

Case 3: Mitral Valve Prolapse and Regurgitation

Case 4: Severe Aortic Stenosis

Case 5: Dilated Cardiomyopathy

Case 6: Restrictive Cardiomyopathy

Case 7: Hypertrophic Cardiomyopathy

Case 8: Atrial Septal Defect Secundum Type

Case 9: Aortic Dissection (Ascending Aorta)

Case 10: Cardiac Myxoma

Chapter 4

Exercise Stress Testing

Sedigheh Saedi

Exercise stress testing (EST) is a simple and noninvasive method of evaluation of response to physiologic stress of exercise and increased myocardial demand.

ECG CHANGES INTERPRETATION

If myocardial ischemia exists, the ST segment becomes progressively more horizontal with exercise. The PQ segment is used for comparison and interpretation of ST segment depression.

ST segment depression of 1 mm or more as compared to PQ segment occurring 80 milliseconds (ms) after the J point (ST80) in three consecutive beats without baseline shifts, is an abnormal response hinting myocardial ischemia. In heart rates above 130, ST60 point (60 ms after J point) should used for the purpose of interpretation.

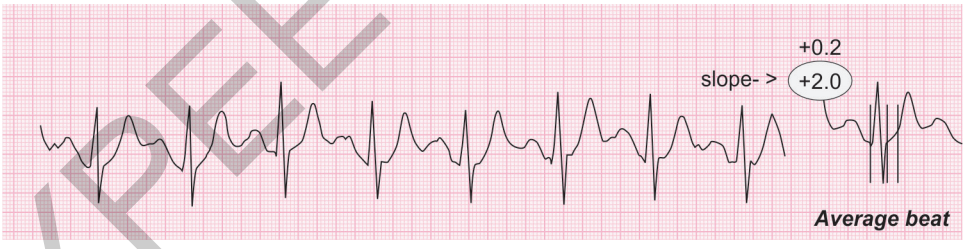

Figure 1 Normal findings

- *Normal response:* There is progressive shortening of PR, QRS, and QT. PR segment down sloping and J point depression are also normal findings **(Figure 1)**.
- *Rapid up sloping changes:* It is a normal exercise response and is more common in older patients. The ST60 or 80 depression is less than 1.5 mm and slope is sharply positive (>1 mV/sec) and upgoing **(Figure 2)**.

JAYPEE BROTHERS



Figure 2 Rapid upsloping changes, The ST60 point depression is about 1 mm and slope is sharply positive

- *Slow upsloping ST depression:* The ST60 or 80 depression is equal to or more than 1.5 mm but slope is positive (>1 mV/sec) and upward going. It is an abnormal response especially if there is coronary risk factors or the patient has a high pretest probability of coronary artery disease (CAD) **(Figure 3)**.



Figure 3 Slow upsloping changes. The ST60 point depression is about 1.5 mm but slope is still upward

- *Horizontal ST depression:* This is the main abnormal response pointing to presence of CAD. There is a ST 60 or 80 depressions of 1mm or more with a slope near zero **(Figure 4)**.

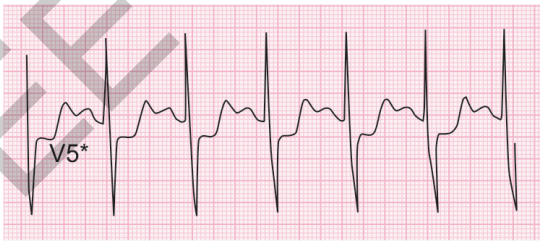

Figure 4 Horizontal changes. The ST60 point depression is about 2 mm and the slope is almost zero

- *Minor ST depression:* It is a the same response as horizontal ST depression but the depression is less than 1mm and should be considered when the exercise has been terminated in less than maximal workload (i.e. less than about 10 METs). For example, ST depression of 0.8 mm with a slope near zero in a patient who has exercised only up to 5 METs is an abnormal response **(Figure 5)**.

JAYPEE BROTHERS



Figure 5 Minor ST depression less than1mm in a patient who exercise test was terminated after 4 minutes

- *Downsloping ST depression:* These changes are also indicator of myocardial ischemia. There is ST 60 or 80 depressions of 1mm or more with a negative, down going slope **(Figure 6)**.



Figure 6 Downsloping ST-depressions

- *ST elevation (in non-Q wave leads):* ST elevation during EST is a sign of severe ischemia and high risk patient. Exercise should be terminated immediately. ECG shows J point and ST 60 or 80 elevations of 1mm or more **(Figure 7)**.

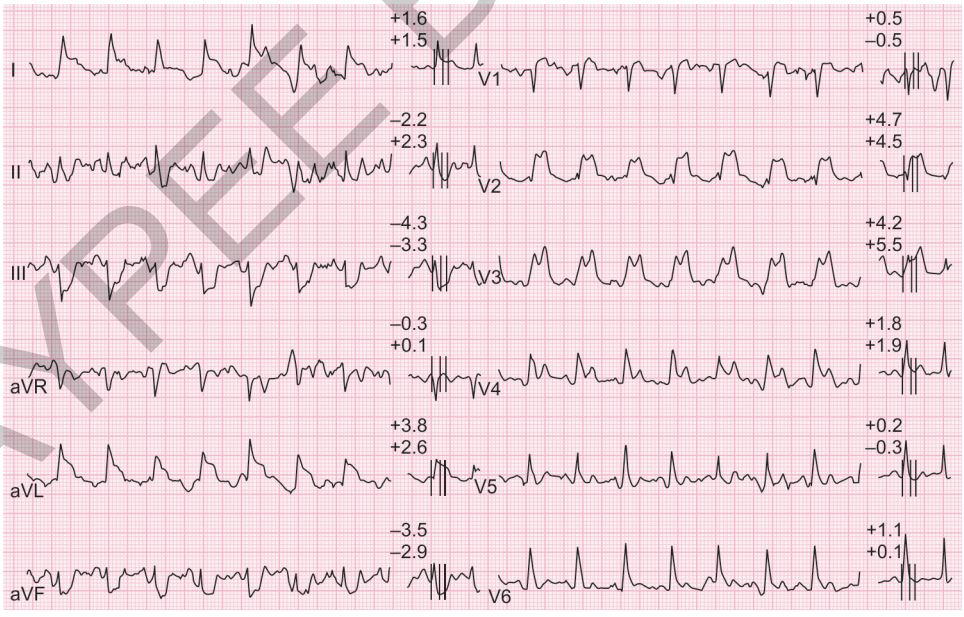

Figure 7 ST-elevation during exercise in inferior, lateral and precordial leads

JAYPEE BROTHERS

- *ST elevation (in Q wave leads):* These changes are usually an indicator of severe regional wall motion abnormality in patients with previous myocardial infarction.[1-3,5]

INDICATIONS FOR TERMINATION OF EST[4]

Absolute

- Significant ST-segment elevation in leads without Q waves (except aVR, aVL, and V1)
- Significant drop in systolic blood pressure
- Development of considerable angina, dizziness, presyncope
- Sustained ventricular tachycardia or heart block
- Inability to monitor the ECG and blood pressure
- Patient's request

Relative

- Significant ST depression (>2 mm)
- Other arrhythmias (except sustained ventricular tachycardia or heart block) that might progress to make the patient unstable
- Severe hypertensive response (systolic blood pressure >250 mm Hg or diastolic blood pressure >115 mm Hg)

REFERENCES

1. Fuster V, Walsh RA, Harrington RA, eds. Hurst's The Heart. 13th ed. New York: McGraw-Hill; 2011.
2. Mann DL, Zipes DP, Libby P, Bonow RO. Braunwald's heart disease: a textbook of cardiovascular medicine. Elsevier Health Sciences; 2014.
3. Fletcher GF, Ades PA, Kligfield P, et al: Exercise standards for testing and training: A scientific statement from the American Heart Association. Circulation. 2013;128:873.
4. American College of Sports Medicine Guidelines for Exercise Testing and Prescription. 9th ed. Philadelphia; Lippincott, Williams & Wilkins; 2013.
5. Froelicher VF, Quaglietti S. Handbook of Exercise Testing. 1996.

JAYPEE BROTHERS

for detailed information on cardiology books, visit our website www.ejaypee.com, for detailed information on cardiology books, visit our website www.ejaypee.com, for detailed info

Color Atlas of Cardiology
Challenging Cases

Salient Features

- A simple and brief guidebook
- Designed as a digest for rapid reference
- Presents basic information about different aspects on cardiology
- Provides an easy and ready access to key aspects of the diagnosis and treatment of cardiovascular conditions
- Focuses on the important points that are sine qua non in the day-to-day practice
- Intended for all the training residents, fellows and beginner cardiologists
- Also serves as a reminder for experienced practitioners of cardiology.

Majid Maleki MD FACC FESC FAPSC is a Professor of Cardiology, Interventional Cardiologist, and an Echocardiologist at Cardiogenetic Research Center, Rajaie Cardiovascular Medical Center, Iran University of Medical Sciences, Tehran, Iran. He is also an Affiliate Member of the Medical Devices Chair located at the University of Ottawa Heart Institute.



Azin Alizadehasl MD FACC FASE is an Associate Professor of Cardiology and a Fellowship of Echocardiography at Echocardiography Research Center, Cardiogenetic Research Center, Rajaie Cardiovascular Medical Center, Iran University of Medical Sciences, Tehran, Iran.



Shelving Recommendation
CARDIOLOGY
ISBN 978-93-86322-14-2
9 789386 322142

Buy from ejaypee
JAYPEE BROTHERS