rmation on pgmee books, visit our website www.jaypeebrothers.com, for detailed information on pgmee books, visit our website www.jaypeebrothers.com

DBMCI NEET/DNB

Pattern Question Bank Latest Exam Questions (2013-2016)



Edited by
Mukesh Bhatia

JAYPEE

Contents

1. Anatomy 1
2. Physiology 33
3. Biochemistry 59
4. Pathology 79
5. Pharmacology 105
6. Microbiology 134
7. Forensic Medicine and Toxicology 151
8. Orthopaedics 165
9. Ophthalmology 177
10. ENT 189
11. Preventive and Social Medicine 201
12. Medicine 229
13. Surgery 282
14. Paediatrics 301
15. Obstetrics and Gynaecology 328
16. Dermatology 353
17. Anaesthesia 371
18. Radiology 381
19. Psychiatry 398

CHAPTER

4

Pathology

1. A 61-year-old man has had back pain for 5 months. He recently developed a cough productive of yellowish sputum. On physical examination he has no lymphadenopathy or splenomegaly. His temperature is 37.8°C. A radiograph of the spine reveals several 1 to 2 cm lytic lesions of the vertebral bodies. His serum urea nitrogen is 28 mg/dL and creatinine 3.0 mg/dL. A sputum culture grows *Streptococcus pneumoniae*. A bone marrow biopsy is performed, and the marrow smear is shown here. Which of the following laboratory test findings is most likely to be present in this man?

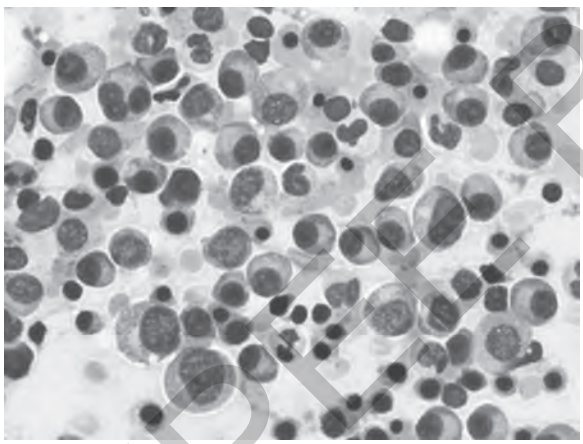

A. Markedly elevated D-dimer
B. Tear drop cells in peripheral blood
C. Decreased leukocyte alkaline phosphatase
D. Hypergammaglobulinemia

2. A 26-year-old man has the sudden onset of severe chest, back, and abdominal pain. On physical examination he is afebrile. He has no lymphadenopathy or splenomegaly. He has right upper quadrant tenderness. His peripheral blood smear is shown here. Which of the following conditions is he most likely to have?

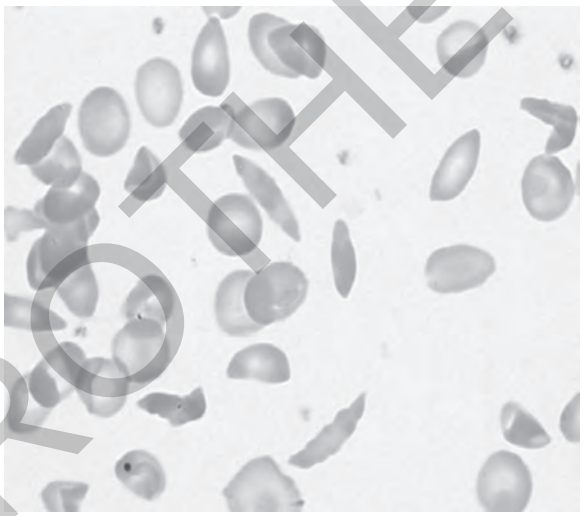

A. Epstein-Barr virus infection
B. Chronic atrophic gastritis
C. Pigmented gallstones
D. Hepatitis A infection

3. Germ cell tumors of ovary are following *except*:

A. Teratoma
B. Dysgerminoma
C. Brenner's tumor
D. Endodermal sinus tumor

4. Which of the following is immature teratoma irrespective of maturity of its elements?

A. Ovarian teratoma in children
B. Testicular teratoma in children
C. Ovarian teratoma in post-pubertal female
D. Testicular teratoma in post-pubertal male

5. "Cytoplasmic mulberries" (morulae) are seen in blood granulocytes in which of the following infection?

A. Chlamydial infection
B. R. Typhi infection
C. Scrub typhus
D. Ehrlichiosis

JAYPEE BROTHERS

6. Relationship between HIV and CCR5 with homozygous mutation in an individual is:

A. Protected against HIV infection
B. Slow progression of the disease
C. Increased susceptibility to the disease
D. None

7. Unfavourable prognostic factor in neuroblastoma:

A. Triploidy
B. DNA ploidy
C. N-MYC amplification
D. Tyrosine kinase receptor inactivation

8. Which of the following is the reliable indicator of malignant transformation of carotid body tumor?

A. Mitoses
B. Pleomorphism
C. Vascular invasion
D. None

9. Solitary fibrous tumor of pleura is associated with:

A. CD34+
B. Keratin negative
C. Asbestos exposure
D. All of the above

10. Single most prognostic factor in colorectal cancer:

A. Stage
B. Grade
C. Histological type
D. None

11. "Single file (one cell thick)" pattern of tumor cells is seen with:

A. Tubular carcinoma breast
B. Papillary carcinoma breast
C. Medullary carcinoma breast
D. Invasive lobular carcinoma breast

12. Key difference between 'mycosis fungoides and sezary syndrome':

A. Characteristic cerebriform nuclei
B. Three clinical stages
C. Indolent course
D. Tumor of CD4 helper T cells

13. Mildly increased incidence of NHL and 10–15 times increased incidence of squamous oesophageal cancer:

A. Celiac sprue
B. Crohn's disease
C. Lactase deficiency
D. Whipple's disease

14. HIV-associated nephropathy is morphologically characterized by:

A. Collapsing variant of FSGS
B. Focal cystic dilatation of tubule segments filled with proteinaceous material
C. Large number of tubuloreticular inclusions within endothelial cells
D. All

15. Which of the following type of multiple myeloma is maximally and most commonly associated with increased risk of hyperviscosity syndrome?

A. IgM
B. IgG
C. IgD
D. IgA

16. In a normal healthy person the arterial oxygen is considered satisfactory if SpO_2 is more than:

A. 80
B. 85
C. 90
D. Any of the above

17. Raised levels of alkaline phosphatase with absence of increase in aminotransferases and normal bilirubin levels is seen in:

A. Amyloidosis
B. Congestive cardiac failure
C. Diabetes mellitus
D. All of the above

18. Which of the following is false about cystic fibrosis?

A. Autosomal recessive inheritance
B. Associated with misfolding of proteins
C. The gene for cystic fibrosis is on chromosome 7q
D. The defect in the respiratory tract is decreased sodium absorption

19. Which of the following is associated with hepatitis C?

A. Anti-LKM1
B. Anti-LKM2
C. Anti-LKM3
D. Anti-mitochondrial

20. A 65-year-old man has had worsening renal failure for the past 10 years. He now requires hemodialysis. An abdominal ultrasound reveals that both his kidneys are enlarged. Based upon this gross appearance of his kidneys shown here, which of the following conditions is he most likely to have?



JAYPEE BROTHERS

A. Systemic lupus erythematosus
B. Renal cell carcinoma
C. Urinary tract obstruction
D. Dominant polycystic kidney disease

21. Wrong about Menkes' disease?
A. Defect in a copper-binding ATPase
B. Poor growth, Lax joints and thin skin
C. Hepatitis and cirrhosis
D. Reduced levels of Ceruloplasmin

22. Which of the following syndrome is not associated with increased risk of malignancy?
A. Down's syndrome.
B. Fanconi's syndrome
C. Bloom's syndrome
D. Fragile X syndrome

23. Which of the following Human malignancy is highly malignant, rapidly progressive and delay in Rx of even 1–2 days can lead death?
A. Hodgkin's lymphoma
B. Neuroblastoma
C. Burkett's Lymphoma
D. Mycosis fungoides

24. Alpha Feto-protein are raised in:
A. Endodermal sinus tumor
B. Liver tumor
C. Embryonal cell tumor
D. All of the above

25. Klatskin's tumor is situated at:
A. Confluence of cystic duct and Come hepatic duct
B. Confluence of right and left hepatic duct
C. Confluence of Pancreatic duct and Come bile duct
D. Intra-hepatic bile duct

26. HLA B27 is associated with all *except*:
A. Ankylosing spondylitis
B. Psoriatic arthritis
C. Reiter's disease
D. Behçet's syndrome

27. Forerunner of carcinoma of stomach:
A. Chronic duodenal ulcer
B. Chronic gastric ulcer
C. Gastritis
D. Post-bulbar ulcer

28. Which type of polyp is most commonly seen in rectum?
A. Inflammatory
B. Hyperplastic
C. Adenomatous
D. Hamartomatous

29. HeLa cell are used for:
A. Apoptosis studies
B. Tumor marker studies
C. Parvo virus culture
D. All of the above

30. Rh incompatibility is which type of reaction?
A. Type I
B. Type II
C. Type III
D. Type IV

31. 'Rokitansky Aschoff' sinuses are seen in:
A. Breast
B. Gallbladder
C. Uterus
D. Liver

32. Which of the following test is almost always abnormal in essential mixed cryoglobulinemia?
A. Low complement level
B. Raised level of rheumatoid factor
C. Raised hepatitis C antibodies
D. Raised level of cryoglobulin

33. Hypersensitivity Pneumonitis is:
A. Allergic Reaction
B. Cytotoxic T cell reaction
C. Delayed Hypersensitivity reaction
D. Immune complex deposit reaction

34. Karyotype is useful in:
A. Autosomal recessive diseases
B. X-linked recessive diseases
C. Chromosomal abnormalities
D. Biochemical abnormalities

35. Type of Amyloidosis in multiple myeloma:
A. B2
B. AA
C. AL
D. MM

36. See the histological slide given below. What is your diagnosis?

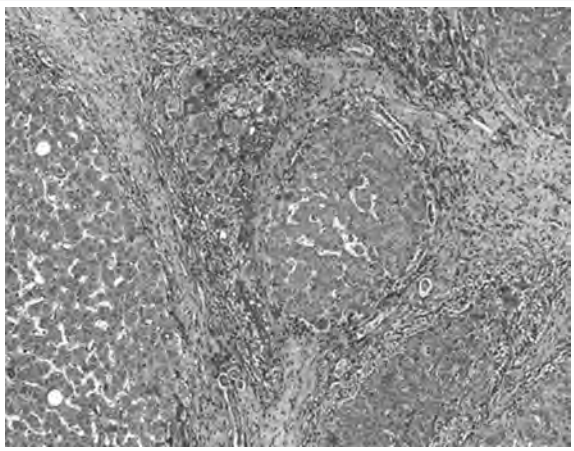

A. Acute hepatitis A
B. Acute hepatitis B
C. Cirrhosis of liver
D. Hepatoma

JAYPEE BROTHERS

37. This is the peripheral smear of which disease?

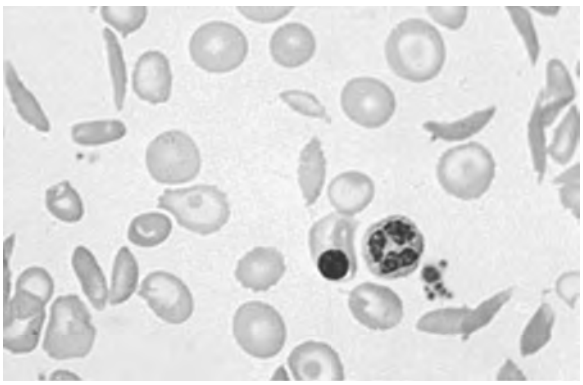

A. Thalassemia
B. Iron deficiency anemia
C. Sickle cell anemia
D. Sideroblastic anemia

38. The given type of leukaemia is not characterised by:

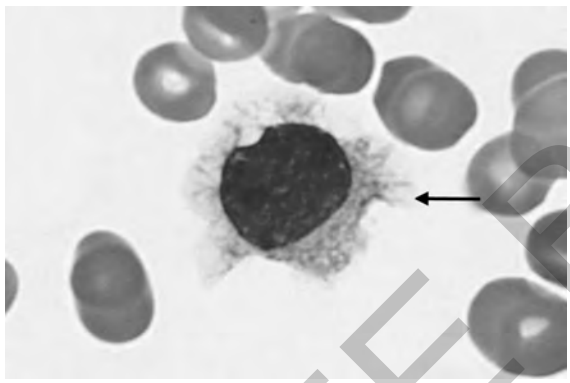

A. Hepatomegaly B. Splenomegaly
C. Lymphadenopathy D. Pancytopenia

39. The following type of cell is seen in:

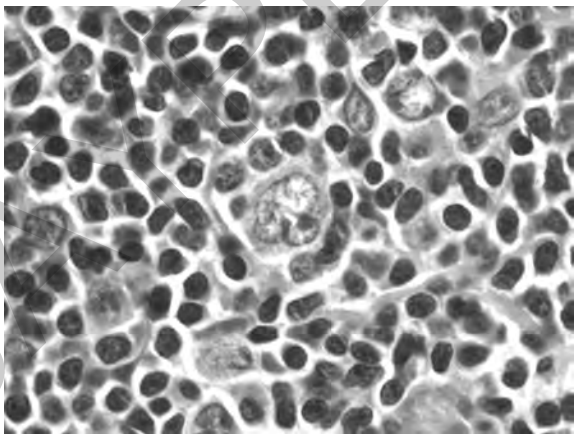

A. Follicular center lymphoma
B. Lymphocyte depleted Hodgkin's disease
C. Nodular sclerosis Hodgkin's disease
D. Lymphocyte predominant Hodgkin's disease

40. The following type of cells are seen in:



A. Sezary syndrome
B. Infectious mononucleosis
C. Chronic lymphocytic leukaemia
D. Burkitt's lymphoma

41. B cell marker are all *except*?

A. Cd19 B. Cd20 C. Cd10 D. CD135

42. Karyotyping under light microscopy:

A. G-banding B. Q-banding
C. C-banding D. FUdR-banding

43. Which of the following is false?

A. Bcl-6-burkitts lymphoma
B. Bcl-2-follicular lymphoma
C. CD-10 mantle cell lymphoma
D. CD 34 in DLBCL

44. Accumulation of lipofuscin, granules in cells is typically seen in which of the following conditions?

A. Atrophy
B. Hypertrophy
C. Hyperplasia
D. Metaplasia

45. A vasculitis affects arteries in many visceral organs of a 29-year-old male. There is focal fibrinoid necrosis of the small arterial and arteriolar vascular media along with intravascular microthrombi. Scattered neutrophils are seen in these areas of necrosis. Which lab test findings would you expect for this patient?

A. Increased IgE
B. Neutropenia
C. Decreased C3 complement
D. Tuberculin skin test positivity

JAYPEE BROTHERS

46. A 38-year-old female presents with abdominal distention, and a CT scan demonstrates bowel obstruction with a 6-cam mass in the jejunum. A Burkitt lymphoma of the small bowel is resected, and a portion of the tumor sent for flow cytometry analysis shows a high S phase. Mutational activation of which oncogene is likely to be present in this tumor?

A. c-erb B2
B. p53
C. ras
D. myc

47. A 15-year-old male presents with high fever of 10 days duration. Examination reveals scattered petechial hemorrhages. No enlargement of liver or spleen or lymph nodes. BM examination is normal. CBC demonstrates Hb 13.2 g/dL, PCV 38.9%, MCV of 93 fL, platelet count of 175,000/dL, with DLC shows N1 L98 M1. Most likely diagnosis:

A. Acute lymphocytic leukemia
B. Acute myeloid leukemia
C. Aplastic anemia
D. Overwhelming bacterial infection

48. In which condition that cause polycythemia, is the serum erythropoietin extremely low?

A. Dehydration
B. Renal cell carcinoma
C. Polycythemia vera
D. Cyanotic heart disease

49. A 7-year-old boy has painful, swollen lymph nodes in his right inguinal region that have worsened over the past week. An inguinal lymph node biopsy is performed. Histologically, the node has large germinal centers containing numerous mitotic figures. There are numerous neutrophils about the follicles and in the sinuses. Most likely cause is:

A. Acute lymphoblastic leukemia
B. Sarcoidosis
C. Follicular lymphoma
D. Acute lymphadenitis

50. A 41-year-old male has been HIV positive for the past 8 years. His CD4 lymphocyte count is now 285/dL. For the past 2 weeks, he has experienced pain on swallowing. There is no hematemesis. He has no nausea or vomiting. Which lesion best accounts for these findings?

A. Esophageal squamous cell carcinoma
B. Achalasia
C. Lower esophageal fibrosis with stenosis
D. Herpes simplex esophagitis

51. A 15-year-old male presents with hematuria. He has previous diagnoses of deafness and corneal dystrophy. Urinalysis shows 1+ protein, no ketones, no glucose, 1+ blood, and no leukocytes. A renal biopsy reveals tubular epithelial foam cells by light microscopy. By EM, the glomerular basement membrane shows areas of attenuation, with splitting and lamination of lamina densa in other thickened areas. Diagnosis is:

A. Acute tubular necrosis
B. Berger disease
C. Membranous glomerulonephritis
D. Alport syndrome

52. A cervical biopsy is performed after an abnormal Pap smear result is obtained on a 42-year-old female. Her previous Pap smear was 10 years ago. The biopsy shows that dysplastic cells occupy the full thickness of the epithelium above the basement membrane. A cervical conization is performed because.

A. She has a high risk for invasive carcinoma
B. HPV infection cannot be treated
C. She is perimenopausal
D. CIN I is present

53. Specific cell surface proteins, such as alkaline phosphatase, and lipoprotein lipase, are anchored to the cell membrane. This anchoring is accomplished by covalent binding through an oligosaccharide bridge to component of the cell membrane. This component is:

A. Sphingomyelin
B. Phosphatidic acid
C. Phosphatidylserine
D. Phosphatidylinositol

54. Which is seen more commonly in rheumatoid arthritis than in ankylosing spondylitis?

A. An HLA-B27 haplotype
B. Sacroiliitis
C. Increased incidence in men
D. Autoantibody against IgG

55. Nodular masses have developed in the periarticular tissue of the proximal and distal interphalangeal joints of the right hand of a 58-year-old man with a 10-year-history of gout. Which of the following choices best describes the characteristics of these masses?

A. Pathognomonic lesion of chronic gout
B. Histologically similar to a rheumatoid nodule
C. Contains weekly positives birefringent monosodium urate crystals
D. Associated with fibrinoid necrosis

JAYPEE BROTHERS

56. In which of the following combinations of auto antibodies are both antibodies used in the diagnosis of the same autoimmune disease?

A. Anti-SS-A (Ro) and anti-centromere antibodies
B. Anti-smith (Sm) and anti-double-stranded DNA antibodies
C. Anti-ribonucleoprotein and anti-histone antibodies
D. Anti-SS-B (La) antibodies and anti-single –stranded DNA antibodies

57. A routine Wright-Giemsa stain of peripheral blood detects:

A. Peripheral blood reticulocytes
B. Heinz bodies
C. Coarse basophilic stippling
D. Globin chain inclusions in sever β-thalassemia

58. The following type of bodies are characteristically seen in:

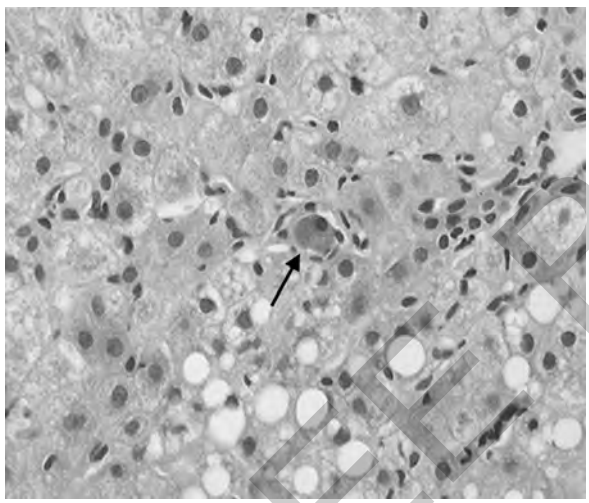

A. Alcoholic cirrhosis
B. Wilson's disease
C. Acute viral hepatitis
D. None of the above

59. The following condition is seen most likely in which condition:

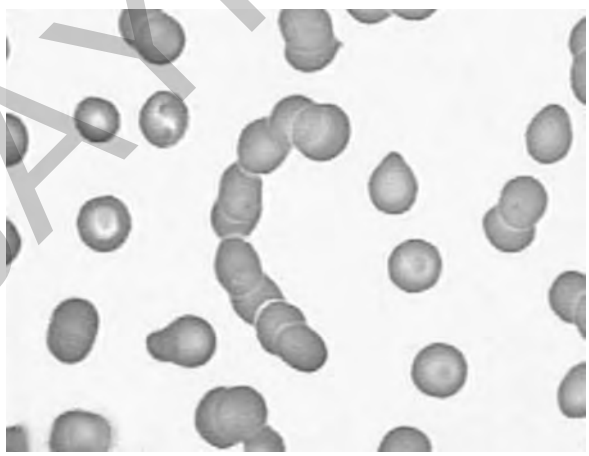

A. CMM
B. CLL
C. Multiple myeloma
D. AML

60. Coagulative necrosis is seen in:

A. TB
B. Sarcoidosis
C. Gangrene
D. Cryptococcal infection

61. Which of the following is not compatible with ageing?

A. Decrease cross linkage
B. Decrease superoxide dismutase
C. Increase accumulation free radicals
D. Accumulated mutations in somatic cell

62. All are true about Xanthogranulomatous inflammation *except*:

A. Associated with TB
B. Giant cells present
C. Yellow nodules present in organ
D. Cholesterol laden macrophages (foamy cells) present

63. Which type of renal stones are this?



A. Oxalate
B. Phosphate
C. Cystine
D. Urate

64. This type of cast in urine is seen in which condition?

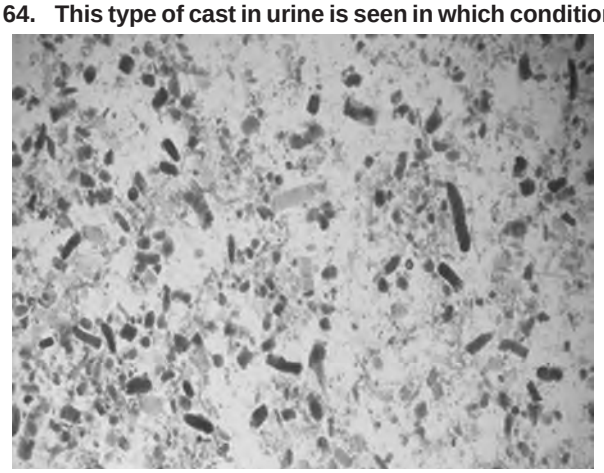

JAYPEE BROTHERS

A. CRF B. ARF
C. Acute glomerulonephritis D. Acute pyonephritis

65. In which of the following forms of pulmonary carcinoma is the classic progression of metaplasia to dysplasia to carcinoma in situ observed?
A. Small-cell carcinoma
B. Adenocarcinoma
C. Large-cell carcinoma
D. Squamous cell carcinoma

66. A 33-year-old sexually active woman, a week after her menstrual period, develops a painful, swollen right knee. The most likely causative organism has which of the following characteristics?
A. Both hyphae and spores
B. Can live within neutrophils
C. Cannot make ATP
D. No true cell wall

67. All of the following enhances insulin sensitivity; *except*:
A. Adipopectic (or ACRP 30)
B. Leptin
C. TNF-α
D. Thiazolidinediones

68. The most common intracranial tumour to calcify is:
A. Oligodendroglioma B. Ependymoma
C. Glioblastoma multiforme D. Meningioma

69. Monckeberg's calcific sclerosis affects the medium sized muscular arteries by involving:
A. Intima B. Media
C. Adventitia D. All of the above

70. Runt's disease is associated with:
A. Acute rejection B. Hyperacute rejection
C. GVHD D. Chronic rejection

71. In cirrhosis of liver collagen is laid down by:
A. Hepatocytes B. Hepatic Stellate cell
C. Biliary epithelial cell D. Kupffer cells

72. Guardian of human genome is:
A. p53 B. bcl2
C. bmp D. None

73. Most common type of anemia seen in CRF is:
A. Microcytic B. Normocytic
C. Macrocytic D. All of the above

74. Neuroendocrine secretory granules are present in:
A. Carcinoid tumor
B. Cystadenocarcinoma ovary
C. Carcinoma cervix
D. Retinoblastoma

75. Acute transplant rejection occurs:
A. Within 1 hour B. Within 12–15 days
C. Within 6 months D. Within few years

76. ANCA is seen in all *except*:
A. Wegener's granulomatosis
B. Henoch Schonlein purpura
C. Microscopic polyangiitis
D. Churg Strauss disease

77. Macrocytic anaemia is caused by:
A. Hookworm infestation
B. IDA
C. Diphyllobothrium latum infestation
D. All of the above

78. What is your most likely diagnosis?

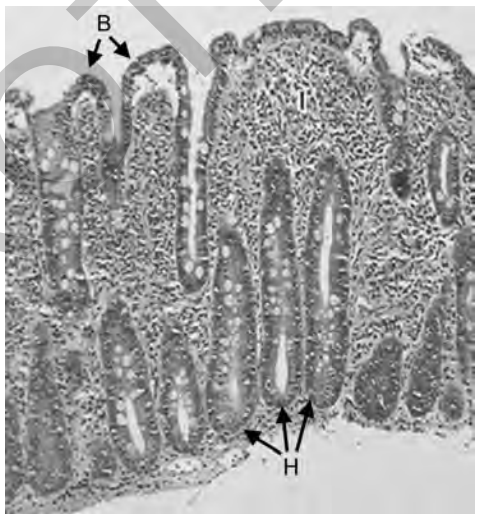

A. Ulcerative colitis B. Chron disease
C. Celiac disease D. Whipple disease

79. The structure marked by arrow is seen in which condition?

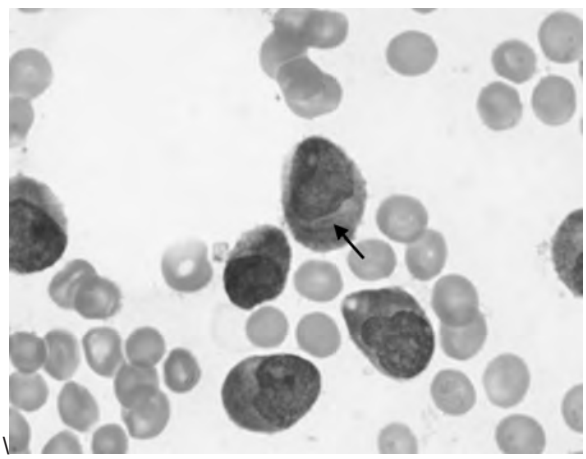

A. AML B. ALL
C. CLL D. CML

JAYPEE BROTHERS

Answers with Explanations

1. Ans. (D) Hypergammaglobulinemia

The increased numbers of plasma cells in this smear indicates multiple myeloma. Monoclonal immunoglobulin is elaborated, detected as an M-protein 'spike' with serum or urine protein electrophoresis.

2. Ans. (C) Pigmented gallstones

The sickled erythrocytes seen here are indicative of sickle cell anemia, which in the homozygous state is marked by 'crises' of sickling of erythrocytes that plug vessels and lead to ischemia with marked pain. The chronic hemolysis increases bilirubin which contributes to gallstone formation.

3. Ans. (C) Brenner's tumor

Ref: Robbin's 8th/Pg. 1041

Brenner's tumor is surface epithelial tumor

Germ cell tumors of ovary

a. Teratoma
b. Dysgerminoma
c. Choriocarcinoma
d. Endodermal sinus tumor

4. Ans. (C) Ovarian teratoma in post-pubertal female

Ref: Robbins pathology, 8th ed. Pg. 1047

The most benignn teratomas are cystic and known in clinical paralance as dermoid cysts.

Cystic teratomas are ususally found in young women during active reproductive years.

5. Ans. (D) Ehrlichiosis

Ref: Robbin's 8th ed./Pg. 3803

Ehrlichiosis

i. Two distinct Ehrlichia species and one Anaplasma species cause human infections that can be severe and frequent.
ii. E. chaffeensis, the agent of human monocytotropic ehrlichiosis (HME), infects predominantly mononuclear phagocytic cells in tissues and blood monocytes. E. ewingii and A. phagocytophila infect cells of myeloid lineage, particularly neutrophils.
iii. Confusion may arise from the facts that Anaplasma phagocytophila is the agent of the disease originally designated human granulocytotropic ehrlichiosis (HGE) and Ehrlichia ewingii is a human granulocytotropic pathogen.
iv. Ehrlichiae are small, obligately intracellular bacteria with a gram-negative-type cell wall that grow in cytoplasmic vacuoles to form clusters called morulae.

6. Ans. (A) Protected against HIV infection

Ref: Robbin's 8th ed./Pg. 239

Relationship between HIV and ccr5 with homozygos mutation

i. Certain viral infections impair mononuclear phagocyte function. For example, influenza virus infection causes abnormal monocyte chemotaxis.
ii. Mononuclear phagocytes can be infected by HIV using CCR5, the chemokine receptor that acts as a co-receptor with CD4 for HIV.
iii. T lymphocytes produce IFN-gamma, which induces FcR expression and phagocytosis and stimulates hydrogen peroxide production by mononuclear phagocytes and neutrophils.

HIV utilizes its envelope glycoprotein (gp) 120 to enter host cells by binding to both CD4 and one of two receptors for chemokines (designated CCR5 and CXCR4).

HIV2 is an RNA virus whose hallmark is the reverse transcription of its genomic RNA to DNA by the enzyme reverse transcriptase.

iv. The replication cycle of HIV begins with the high-affinity binding of the gp120 protein via a portion of its V1 region near the N terminus to its receptor on the host cell surface, the CD4 molecule.
   a. The CD4 molecule is a 55-kDa protein found predominantly on a subset of T lymphocytes that are responsible for helper or inducer function in the immune system.
   b. It is also expressed on the surface of monocytes/macrophages and dendritic/Langerhans cells.
   c. Once gp120 binds to CD4, the gp120 undergoes a conformational change that facilitates binding to one of a group of co-receptors.
   d. The two major co-receptors for HIV-1 are CCR5 and CXCR4.

JAYPEE BROTHERS

e. Both receptors belong to the family of seven-transmembrane-domain G protein-coupled cellular receptors, and the use of one or the other or both receptors by the virus for entry into the cell is an important determinant of the cellular tropism of the virus.
f. Certain dendritic cells express a diversity of C-type lectin receptors on their surface, one of which is called DC-SIGN, that bind with high affinity to the HIV gp120 envelope protein, allowing the dendritic cell to facilitate the binding of virus to the CD4+ T cell upon engagement of dendritic cells with CD4+ T cells.
g. Since CCR5 is the major co-receptor for R5 or macrophage-tropic strains of HIV and since individuals who are homozygous for the CCR5-gamma32 deletion are, with rare exceptions, protected against HIV infection, the potential mechanism for slow progression in heterozygotes is clear.
h. In addition, certain single nucleotide polymorphisms in the CCR5 promoter have been shown to be associated with slower progression of disease.
i. The RANTES-28G mutation increases RANTES expression, which is the natural ligand for CCR5 nd may thus inhibit infection with R5 viruses.

7. Ans. (C) N-MYC amplification

Ref: Robbin's 8th ed. Pg. 477

	Favorable	*Unfavorable*
Stage	1, 2a, 2b, 4S	3 and 4
Age	< 18 mo	> 18 mo
Histology-differentiation	Present	Absent
Mitosis (karyohhexis)	< 200/5000 cells	> 200/5000 cells
DNA ploidy	Hyperdiploid or near triploid	Near diploid
N-myc	Not amplified	Amplified
Chro 17Q gain	Absent	Present
Chro 1p loss	Absent	Present
Chro 1q loss	Absent	Present
TRK expression	Present	Absent
TRKB expression	Absent	Present
Telomerase expression	Low/absent	Highly expressed

8. Ans. (D) None

Ref: Robbin's 8th ed./Pg. 756

Unfortunately, it is almost impossible to judge the clinical course of a carotid body tumor – mitoses, pleomorphism, and even vascular invasion are not reliable indicators.

9. Ans. (A) CD34 +

Ref: Robbins 8th ed./ Pg. 732

Solitary fibrous tumor:

a. Has propensity for of pleura and less commonly for lungs and others
b. Previously known as benign mesothelioma
c. Rarely it may be malignant
d. CD34+
e. Keratin positive
f. No relation with asbestos exposure

10. Ans. (A) Stage

Ref: Robbins 8th ed./Pg. 852

Although poorly differentiated and mucinous histologies of cancer colon are associated with poor prognosis, the two most vital prognostic factors are depth of invasion and presence or absence of lymph node metastases.

11. Ans. (D) Invasive lobular carcinoma breast

Ref: Robbins and Cotran Pathologic basis of Disease, 7th ed., Pg. 344

Breast cancer

a. Most common : Ductal carcinoma (80%)
b. Most favorable prognosis : Colloid, medullary and tubular
c. Most malignant (bad prognosis) : Inflammatory carcinoma
d. Bilateral : Invasive Lobular carcinoma
e. 'Indian file' or 'single file' pattern : Invasive Lobular carcinoma

12. Ans. (B) Three clinical stages

Ref: Robbins 's 8th ed./ 616

i. Characteristic Cerebriform nuclei = Leukemia of Sezary cells.
ii. Three clinical stages = myosis fungoides (premycotic; plaque; tumor phase)
iii. Indolent course = both
iv. Tumor of CD4 helper T cells = both.

13. Ans. (A) Celiac sprue

Ref: Robbins and Cotran, Pathologic basis of disease, 8th ed., Pg. 796

Celiac disease

i. Celiac disease (also referred to as celiac sprue, gluten-sensitive enteropathy) is a chronic disease, in which there is a characteristic mucosal

JAYPEE BROTHERS

lesion of the small intestine and impaired nutrient absorption, which improves on withdrawal of wheat gliadins and related grain proteins from the diet.

ii. The fundamental disorder in celiac disease is a sensitivity to gluten, which is the alcohol-soluble, water-insoluble protein component (gliadin) of wheat and closely related grains (oat, barley, and rye).

iii. The hallmark of this disease is a T-cell mediated chronic inflammatory reaction with an autoimmune component, which most likely develops as a consequence of a loss of tolerance to gluten.

iv. Interplay between genetic predisposing factors, the host immune response, and environmental factors is central to disease pathogenesis.

v. The small intestinal mucosa, when exposed to gluten, accumulates intraepithelial CD8+ T cells and large numbers of lamina propria CD4+ T cells, which are sensitized to gliadin.

vi. The recognized epitopes are confined to residues 57–75 of gliadin.

vii. It has been long known that family history is important in celiac disease.

viii. Almost all individuals with celiac disease share the major histocompatibility complex class II HLA-DQ2.

14. Ans. (D) All

Ref: Robbins 8th ed./Pg. 928

HIV-associated nephropathy is morphologically featured by:

a. Collapsing variant of FSGS
b. Focal cystic dilatation of tubule segments filled with proteinaceous material.
c. Large number of tubuloreticular inclusions within endothelial cells.

15. Ans. (A) IgM

Ref: H-17th/704; Robbin's 7th ed./Pg. 680

Hyperviscosity syndrome in multiple myeloma (MM)

i. Hyperviscosity syndromes may develop in MM depending on the physical properties of the M component.

ii. It is most common with IgM, IgG3, and IgA paraproteins.

iii. Hyperviscosity is defined on the basis of the relative viscosity of serum as compared with water.

iv. Normal relative serum viscosity is 1.8 (i.e., serum is normally almost twice as viscous as water).

v. Symptoms of hyperviscosity occur at a level of 5–6, a level usually reached at paraprotein concentrations of:
   a. 40 g/L (4 g/dL) for IgM,
   b. 50 g/L (5 g/dL) for IgG3, and
   c. 70 g/L (7 g/dL) for IgA.

vi. Hypercalcemia may produce lethargy, weakness, depression, confusion, headache, fatigue, visual disturbances, and retinopathy.

16. Ans. (C) 90

Ref: H-17th ed./1590-91; Pg. A-15

In a normal healthy person the arterial oxygen is considered satisfactory if SPO_2 is more than 90.

17. Ans. (D) All of the above

Ref: H-17th ed./1925

In the absence of jaundice or elevated aminotransferases, an elevated alkaline phosphatase of liver origin often, but not always, suggests early cholestasis and, less often, hepatic infiltration by tumor or granulomata. Other conditions that cause isolated elevations of the alkaline phosphatase include Hodgkin's disease, diabetes, hyperthyroidism, congestive heart failure, amyloidosis, and inflammatory bowel disease.

18. Ans. (D) The defect in the respiratory tract is decreased sodium absorption

Ref: H-16th ed./Pg. 1544

CF is autosomal recessive disease due to defect in chro 7.

Raised Na+ absorption is a feature of CF airway epithelia.

Diseases caused by lack of a particular functioning protein, due to its degradation as a consequence of misfolding, include cystic fibrosis (misfolded CFTR protein), Marfan syndrome (misfolded fibrillin), Fabry disease (misfolded alpha galactosidase), Gaucher's disease (misfolded beta glucocerebrosidase) and retinitis pigmentosa 3 (misfolded rhodopsin). In addition, some cancers may be associated with misfolding, and hence ineffective functioning, of tumour suppressor proteins such as von Hippel Lindau protein or p53.

JAYPEE BROTHERS

19. Ans. (A) Anti-LKM-1

Ref: Harrison Medicine 17th ed. Table 300-1

Type of hepatitis	*Diagnostic Test(s)*	*Auto-antibodies*	*Therapy*
Chronic hepatitis B	HBsAg, IgG anti-HBc, HBeAg, HBV DNA	Uncommon	IFN-α, PEG IFN-α, lamivudine, adefovir, entecavir
Chronic hepatitis C	Anti-HCV, HCV RNA	Anti-LKM1	PEG IFN-α plus ribavirin
Chronic hepatitis D	Anti-HDV, HDV RNA, HBsAg, IgG anti-HBc	Anti-LKM3	IFN-α, PEG IFN-α
Auto-immune hepatitis	ANA (homogeneous), anti-LKM1(±), Hyperglobulinemia	ANA, anti-LKM1, anti-SLA	Prednisone, azathioprine
Drug-associated	—	Uncommon	Withdraw drug
Cryptogenic	All negative	None	Prednisone (?), azathioprine

20. Ans. (D) Dominant polycystic kidney disease

The large cysts are characteristic for DPKD, which remains silent until middle age or beyond. It is important to know about this condition, because other family members may be affected.

Urinary tract obstruction causes unilateral dilation of pelvicalyceal system generally.

21. Ans. (C) Hepatitis and cirrhosis

Menke's disease, an alteration in a copper-binding ATPase. Dysfunction of the ATPase imprisons copper in cells and prevents its normal absorption from the intestine. Enzymes that use copper as cofactor have diverse roles in metabolism, including some that modify and degrade amino acids in collagen. This accounts for the connective tissue symptoms (lax joints, thin skin) in Menke's disease. Wilson's disease is also caused by mutations in a copper-binding ATPase that lead to copper storage in liver (causing hepatitis and cirrhosis) and the brain (sometimes causing psychosis). Ceruloplasmin, the major copper transporter in serum, is decreased in both diseases.

22. Ans. (D) Fragile X syndrome

Ref: Harrison Principles of Internal Medicine, 16th ed., 631)

Chromosomal breakage syndromes

i. These are a group of genetic disorders that typically are transmitted in an autosomal recessive mode of inheritance and are characterized by a defect in DNA repair mechanisms or genomic instability, and patients with these disorders show increased predisposition to cancer.
ii. All patients are sensitive to UV radiation, although the major feature of one of the disorders, ataxia telangiectasia (Louis-Bar syndrome), is hypersensitivity to ionizing radiation.
iii. These disorders are relatively rare and often lethal.

These include:

1. Ataxia telangiectasia (AT)
2. Bloom syndrome (BS)
3. Fanconi's anemia (FA)
4. Xeroderma pigmentosum (XP)

iv. These syndromes are characterized by different types of cancer; including leukemia, lymphoma, and solid tumors (e.g., skin cancer).
v. In addition, the syndromes are associated with other traits, such as cerebellar ataxia, immunodeficiencies, growth retardation, microcephaly, skeletal abnormalities, hypogonadism, pancytopenia, and abnormal pigmentation.

23. Ans. (C) Burkett's Lymphoma

Ref: Robbin's Pathology, 7th ed., Pg. 672

Burkett's lymphoma

i. Burkett's lymphoma is very aggressive tumor but responds well to short term high dose chemotherapy.
ii. Most children and young adults can be cured, however outcome is guarded in adults.
iii. A high mitotic index and apoptotic cell death are typical.
iv. **"Starry sky" pattern** is characteristic.
v. **Chromosome 8, EBV, t (2, 8), t (8, 22**) and myc gene translocation are associated with Burkett's lymphoma.
vi. Hodgkin's lymphoma, Mycosis fungoides are indolent tumors.

JAYPEE BROTHERS

24. Ans. (D) All of the above

Ref: Harrison's Internal Medicine 16th ed., Pg. 381, 566, 43gt)

Alpha-fetoprotein

1. **Introduction**
   i. Alpha-fetoprotein is a glycoprotein (M.W. 70 kDa). It is produced initially by the yolk sac and then by the fetal liver. Considerably smaller amounts are also produced in the fetal gut and kidneys. Early in embryonic life AFP functions as the major serum protein. While the fetal AFP concentration falls after 16 weeks, the membranes and placenta become increasingly leaky leading to a progressive rise in maternal serum AFP from 14 weeks onwards.
2. **Clinical Significance and Indications**
   - ***Antenatal Screening***
     i. Neural tube formation is usually complete very early in gestation (by the end of the 4th week after fertilization). Failure of the embryo to complete neural tube fusion successfully results in permanent developmental defects of the brain or spinal cord such as anencephaly, spina bifida, or myelomeningocoele. Approximately 90–95% of these defects are 'open'. Some proteins gain access in smaller but significant amounts to the maternal circulation.
     ii. A second use for the AFP is in calculation of a Down's syndrome risk estimate. In this situation, a low AFP is characteristic of an affected pregnancy.
3. **Tumor Marker**
   i. In fetal life, AFP is synthesized in the liver. Consequently, when hepatic cells become tumorous there is a tendency for them to start producing AFP again. Thus in situations where hepatic tumors are thought to be a possibility, an elevated serum AFP level may be a diagnostic pointer.
   ii. Germ cell tumors (seminomas, teratomas, ovarian tumors etc.), and trophoblastic tumors (choriocarcinoma) normally secrete AFP and HCG. Both of these substances can therefore be used in assessing whether an un-diagnosed mass is a tumor and in following Rx.
4. **Reference Range**
   i. For antenatal screening: AFP MoM > 2.2 indicates further investigation required
   ii. As a tumor marker: 0–6.4 kIU/L.

25. Ans. (B) Confluence of right and left hepatic duct

Ref: Harrison's, Internal Medicine, 16th ed., Pg. 536

Klatskin's tumor

1. **Definition**
   i. Bile duct cancer of the upper part of the bile duct is also called Klatskin's tumor. Klatskin's tumors involve the upper part of the bile duct as divides to enter the right and the left parts of the liver, i.e. *at the confluence of the right and left hepatic ducts*.
2. **Diagnosis and staging of Klatskin's tumors**
   i. The diagnosis is made by an *ERCP* or a *PTC*. These procedures also allow placement of stent to relieve the jaundice.
   ii. A CT scan is then obtained to stage the tumor (Once diagnosis of a Klatskin's tumor is made then the goal of the work up is to assess for possible removal of the tumor by surgery. Klatskin's tumors often invade the blood vessels called hepatic artery and the portal vein. The goal of staging prior to surgery is to assess whether the blood vessels of the liver are free of the tumor).
3. **Rx of Klatskin's tumor**
   i. Complete removal of the tumor is the only effective and potentially curative Rx.
   ii. *Klatskin's tumors are removable if:*
      a. Blood supply to one side of the liver is not affected by the tumor
      b. The bile duct to one side of the liver is free of tumor
      c. Unresectable Klatskin's tumor
      d. Klatskin's tumor is unresectable if it invades the blood supply to both sides of the liver and/or the hepatic duct to the both sides of the liver. In general these tumors respond poorly to Rx.

26. Ans. (D) Behçet's syndrome

HLA B27 is associated with (PRRAJakta):

1. Psoriatic arthritis
2. Reiters disease
3. Reactive arthritis
4. Ankylosing spondylitis
5. Juvenile rheumatoid arthritis

JAYPEE BROTHERS

etailed information on pgmee books, visit our website www.jaypeebrothers.com, for detailed information on pgmee books, visit our website www.jaypeebro

DBMCI
NEET/DNB

Pattern Question Bank—Latest Exam Questions
(2013-2016)

Salient Features

- Book covers all latest exam pattern questions from 2013 to 2016
- This book is complete in itself in all aspects.
- Book includes latest exam questions of all 19 subjects with explanations along with authentic references.
- All the questions are solved by subject faculty of DBMCI



Mukesh Bhatia is a graduate of MAMC, New Delhi. He is the first person in the whole of India who has conceived the idea of PG Entrance Exam. He is the founder of these courses and the pioneer in the field. He is an eminent educationist, an excellent teacher of Medicine, author of bestselling books, a very good orator and an excellent guide to students in choosing their career (branch and college). He has been teaching PG aspirants for more than 20 years. Till date, he has taught entire medicine to more than 1.25 lac students all over India, Nepal and China. He has a unique, crisp and concise style of teaching medicine. He summarizes the entire subject of Medicine in such a way that after attending his classes, students can revise the whole Medicine in just 3 hours! He is considered as 'God of Medicine' by the students.

For any suggestions and comments, please email at contactdrbhatia@gmail.com.

Available at all medical bookstores
or buy online at www.jaypeebrothers.com

JAYPEE BROTHERS
Medical Publishers (P) Ltd.
www.jaypeebrothers.com

Join us on facebook.com/JaypeeMedicalPublishers

ISBN 978-93-86322-23-4
9 789386 322234