ur website www.jaypeebrothers.com, for detailed information on neurology book, visit our website www.jaypeebrothers.com

Neurological Society of India

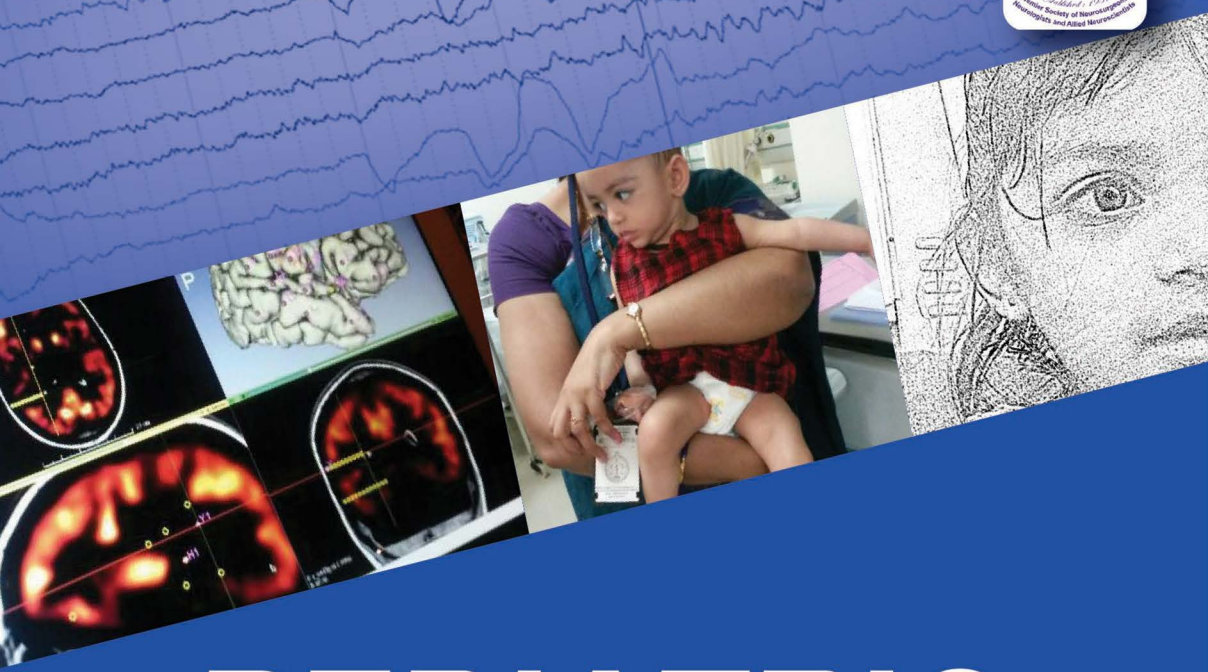

PEDIATRIC EPILEPSY SYNDROMES

Seizures, Syndromes, Approach and Management

Ashalatha Radhakrishnan

Forewords
Elaine Wyllie
Ingrid E Scheffer

JAYPEE

Contents

1. **Frontal Lobe Epilepsy** **1**
   Samhita Panda, Gopal Krishna Dash, Raghavendra S
   - Demographic Data *1*
   - Etiology *1*
   - Semiological Classification *1*
   - Examination *5*
   - Differential Diagnoses *5*
   - Management *5*
2. **Temporal and Pseudotemporal Lobe Epilepsy in Children** **14**
   Haseeb Hassan, AtmaRam Bansal, Paresh Zanzmera
   - Surgical Treatment for TLE *19*
3. **Pediatric Posterior Head Region Epilepsy** **23**
   Pramod Krishnan, Pandurang Wattamwar, Anis Jukkarwala
   - Etiopathogenesis *23*
   - Seizure Semiology *26*
   - Radiological Features *29*
   - Management *32*
4. **Reflex Epilepsy Syndromes** **38**
   Shiva Kumar R, Malcolm Jeyaraj, Pradeep N Nair
   - Reflex Epilepsy *38*
   - Classification *38*
   - Management *43*
   - Jeavons Syndrome *44*
   - Eating Induced Seizures *48*
   - Startle Induced Seizures *49*
5. **Genetic Epilepsy with Febrile Seizures Plus (GEFS+) and Idiopathic Generalized Epilepsy (IGE) Syndromes** **51**
   Sandeep Padmanabhan, Atampreet Singh, Sujit Jagtap
   - Febrile Seizures (FS) and Febrile Seizures Plus (FS+) *51*
   - Clinical Presentation *52*
   - Diagnostic Evaluation *53*
   - Management *53*
6. **Benign Seizure Susceptibility Syndromes** **63**
   Mini S, Jeevan S Nair, Prasanth Varghese
   - Benign Childhood Epilepsy with Centrotemporal Spikes *63*
   - Benign Occipital Epilepsy Syndromes *75*
7. **Neonatal Seizures and Epilepsies** **84**
   Joseph Samuel P, Ramshekhar N Menon
   - Classification *85*
   - Diagnosis and Management *89*

- Prognosis *92*
- Neonatal Epilepsy Syndromes *93*
- MPSI *94*

8. Early Infantile Epileptic Encephalopathies **106**
Suresh Babu P, Ramshekhar N Menon, Atampreet Singh

- Early Infantile Epileptic Encephalopathy (Ohtahara Syndrome) *106*
- Early Myoclonic Encephalopathy *110*
- Malignant Migrating Partial Seizures of Infancy (MMPSI) *113*
- EEG *115*

9. West Syndrome **118**
Ramshekhar N Menon

10. Migrating Partial Seizures of Infancy and Febrile Infection-related Epilepsy Syndrome **126**
Sujit Jagtap

- Migrating Partial Seizures of Infancy (MPSI) *126*
- Febrile Infection-related Epilepsy Syndrome *128*

11. Dravet Syndrome **131**
Neeraj Baheti

- Demographic Data *131*
- Etiology *131*
- Clinical Manifestations *131*
- Diagnostic Procedures *132*
- Differential Diagnosis *132*
- Treatment *133*
- Long-term Outcome *134*

12. Lennox-Gastaut Syndrome **136**
Ajith Cherian

- Differential Diagnosis *139*
- Pathogenesis *140*
- Treatment *142*

13. Landau-Kleffner Syndrome **144**
Hardeep Kumar, Sanjeev V Thomas

- Epidemiology *145*
- Etiopathogenesis *145*
- Investigations *146*
- Imaging in LKS *146*
- Differential Diagnosis *149*
- Treatment *150*

14. Approach to Myoclonic and Atonic Seizures of Children **152**
Sai Satish, Ashalatha Radhakrishnan

- Approach to Myoclonic Seizures of Childhood *153*
- Approach to Atonic Seizures of Childhood *154*
- Atonic Seizures *163*

15. Familial Autosomal Dominant Focal Epilepsies **166**
Ramesha K Nekkare
- Commonly Recognized Autosomal Dominant Familial Focal Epilepsy Syndromes *166*
- Other Rare Possible Autosomal Dominant Familial Focal Epilepsy Syndromes *166*
- Familial Temporal Lobe Epilepsy *168*

16. Autoimmune Encephalitis in Children **173**
Kalyani Karkare, Himanshu Soni
- Etiology *174*
- Clinical Features *175*
- Laboratory Features *176*
- Management *178*
- Recovery Pattern *179*
- Approach to Autoimmune Encephalitis in Children *179*

17. Acute Symptomatic Seizures in Children **182**
Deepak Menon, Rajesh B Iyer
- Defining the Problem *182*

18. Approach to a Child with First Unprovoked Seizure **188**
Ajay Asranna, Rajesh S Iyer
- Characterization of the Paroxysmal Event *188*
- Investigations in Children with FUS *189*

19. Newer Antiepileptic Drugs in Pediatric Epilepsy Syndromes **194**
Keni Ravish Rajiv, Vikash Agarwal
- Current Status of Newer AEDs in Pediatric Epilepsy Syndromes *195*
- Current Status of Newer AEDs in India *199*

20. Status Epilepticus in Children **202**
Deepak Menon, Suvasini Sarma
- Epidemiology *202*

21. Imaging in Pediatric Epilepsy **212**
Krishna Vadan BM, Bejoy Thomas
- Substrates of Pediatric Intractable Epilepsy Syndromes: Therapeutic Strategies Based on Imaging *212*
- Imaging Plan in Epilepsy Patients *213*
- Magnetic Resonance Imaging of the Epileptogenic Substrates—Representative Cases *216*

22. Surgically Remediable Pediatric Epilepsy Syndromes **230**
Ramshekhar N Menon, Ashalatha Radhakrishnan
- Basic Principles in Selection of Surgical Candidates *231*
- Structural Surgically Remediable Epilepsies *232*
- Distinctive Constellations (Including Neurocutaneous Syndromes) *239*
- Special Considerations *245*

23. Approach to a Child with Infantile Hemiparesis and Refractory Epilepsy **250**
Deepak Menon, Kesavadas C, George Vilanilam, Mathew Abraham
- Timing of Surgery *251*

24. Referral Patterns in Pediatric Epilepsy Surgery **258**
Ajay Asranna, Ashalatha Radhakrishnan

25. Evolution of Classification of Various Pediatric Epilepsy Syndromes: Has it Made a Difference? **265**
Chandana Gaddipati, Jitesh Goyal
- History of Nosology *265*
- Pitfalls of the ILAE Classification of Seizures (1981) in the Context of Pediatric Epilepsies *266*
- Pros and Cons of ILAE, 1989, Revised Classification of Epilepsies and Epileptic Syndromes in the Context of Pediatric Epilepsies *268*
- ILAE, 2001, Diagnostic Scheme and Other Proposals *270*
- Changes in Pediatric Epilepsy in ILAE Proposal for Revised Terminology for Organization of Seizures and Epilepsies, 2010 and 2011–2013 Report *271*
- ILAE, 2016, Ongoing Task Force: Operational Classification of Seizure Types and Classification of the Epilepsies *276*
- Pediatric Epilepsy Surgery *276*
- Few Scenarios Where the Evolution of Classification has Led to the Diagnosis of Epilepsy/Epilepsy Syndrome *278*
- Epileptic Encephalopathy *279*
- Future Directions *279*

Index **283**

CHAPTER
3

Pediatric Posterior Head Region Epilepsy

Pramod Krishnan, Pandurang Wattamwar, Anis Jukkarwala

INTRODUCTION

Posterior head region or posterior cortex epilepsies (PCE) encompass a group of epilepsies arising from the occipital lobe or adjacent regions of the posterior temporal or parietal lobes, or from any combination of these regions. In contrast to frontal lobe seizures, parietal and occipital lobe seizures are generally not recognized as constituting a specific clinical syndrome and have been regarded as a heterogeneous group. The immature brain is generally considered to be more epileptogenic than the mature brain as suggested by the high incidence of seizures in the first year of life. This reflects the high-risk of exposure to cerebral insult in the neonatal period as well as the higher susceptibility of the immature brain to generate seizures in reaction to injury.[1] This results in a higher incidence of seizures in the pediatric age group, especially in infancy. In developed countries, developmental abnormalities of cortical architecture, i.e. malformations [focal cortical dysplasia (FCD), periventricular heterotopia, band heterotopia and polymicrogyria], tuberous sclerosis and tumors constitute the major causes. Experience from developing nations and past studies from many developed nations implicate perinatal insults as major contributors for remote symptomatic epilepsy originating from the posterior head region.[2] Parieto-occipital gliosis and ulegyric cortex due to perinatal ischemic injury is one of the major cause of PCE in India.[3,4]

ETIOPATHOGENESIS

The etiology of symptomatic epilepsy arising from the posterior head region in the pediatric age group, especially in infancy, is different from those at other ages (Table 3.1).

JAYPEE BROTHERS

Table 3.1: Etiology of posterior cortex epilepsy

Malformations of cortical development
- Abnormal neuronal and glial proliferation or apoptosis
  - Focal cortical dysplasia
- Abnormal neuronal migration leading to
  - Periventricular heterotopias
  - Subcortical band heterotopias
- Abnormal cortical organization leading to
  - Polymicrogyria

Tumours
- Benign (gangliogliomas, dysembryoplastic neuroepithelial tumors, etc.)
- Neoplastic (astrocytomas, oligodendrogliomas, etc.)

Trauma/vascular
- Epilepsy with bilateral occipital calcifications
- Perinatal anoxic-ischemic injury
- Ulegyria
- Perinatal posterior cerebral artery occlusion
- Post-traumatic occipital gliosis
- Post-stroke infarction or hemorrhage
- Sturge-Weber syndrome

Metabolic and neurodegenerative
- Mitochondrial disorders
- Progressive myoclonus epilepsies

Infective/inflammatory
- Rasmussen's encephalitis
- Arteritis
- Localized infection (tuberculoma, cysticercosis, etc.)

Idiopathic
- Early-onset childhood epilepsy with occipital spikes
- Late-onset childhood epilepsy with occipital spikes
- Idiopathic photosensitive epilepsy

Perinatal Insult/Ulegyria

Perinatal ischemic injury leading to parieto-occipital gliosis and ulegyric cortex is one of the leading causes of PCE in India.[3] In term neonates, hypoxic-ischemic injury causes lesions called 'water shed lesions' predominantly in the posterior cerebral artery territory or in the arterial border zone between middle and posterior cerebral arteries and may result in ulegyria.[5] This is invariably over the parietal association cortex, with variable inter-individual extension to the occipital, central and less often, the temporal areas. In the newborn brain there is greater perfusion in the apices of the gyri than in the cortex at the depth of the sulci. For this reason, tissues at the bottom of the gyri are more susceptible to hypoxic injury resulting in atrophy mainly of the deep portion of the convolution with relative sparing of the apex.[5] The shape of the affected convolution is described as 'mushroom gyri' (Fig. 3.1).

The concept that 'cortical scars' alone cause epilepsy in patients with perinatal insult is an oversimplification. Seizures are most likely generated within 'acquired cortical dysplastic changes' which have progressed over time after the initial hypoxic ischemic event.[6] This concurs with the observation that children who have suffered perinatal hypoxic injury often have a history

JAYPEE BROTHERS

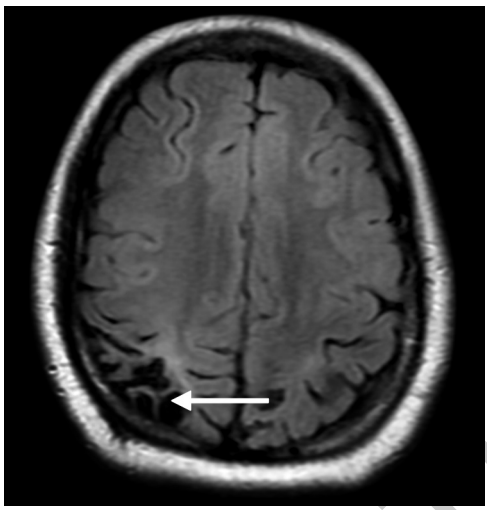

Fig. 3.1: T2 fluid attenuated inversion recovery (FLAIR) axial MRI brain images showing ulegyria (arrow) in the posterior cortex in an 8-year-old girl with refractory seizures and history of perinatal hypoxia

of perinatal seizures, followed by long periods of seizure freedom, often for many years, before the onset of a focal or multifocal epilepsy.

Occipital Seizures in Progressive Myoclonus Epilepsies

The progressive myoclonus epilepsies (PMEs) are a group of rare heterogeneous disorders characterized by myoclonic and generalized seizures and progressive neurological deterioration. Focal seizures, especially occipital and posterior epileptiform abnormalities are most frequent and characteristic of Lafora disease. In Lafora disease, occipital seizures can be the presenting or dominating early clinical manifestation. Lafora disease is best diagnosed by skin biopsy. 80% of patients with Lafora disease have a mutation in the laforin gene on chromosome 6q. Other PMEs, where occipital seizures may occur, include juvenile neuronal ceroid lipofuscinoses (NCLs), myoclonus epilepsy ragged-red fibre syndrome (MERRF) and Unverricht-Lundborg disease (ULD).

Epilepsy with Bilateral Occipital Calcifications

Epilepsy with bilateral occipital calcifications has now emerged as a distinct entity often associated with celiac disease. Seizure onset is usually in the first decade of life and comprises partial seizures with visual and/or motor adversive signs with or without secondary generalization. Rarely, they may present with an epileptic encephalopathy and intellectual deterioration may occur. The occipital calcifications are usually bilateral, symmetrical, linear, involving the flocculonodular, cortical and subcortical layers, without contrast enhancement or cortical atrophy.[7] Frequently there is a history of anemia or malabsorption in the first 3 years of life. A gluten-free diet may result in a reduction in seizure frequency and even seizure freedom. The chance of seizure freedom is related to the age of commencement of a gluten-

JAYPEE BROTHERS

free diet, and is inversely related to the duration of epilepsy, emphasizing the need to begin early therapy.

Sturge-Weber Syndrome

The occipital calcifications seen in cases with Celiac disease are similar to those found in Sturge-Weber syndrome. However, Sturge-Weber syndrome presents with cutaneous angioma, glaucoma and often with focal neurological deficits. Neuroimaging in Sturge-Weber syndrome shows lobar or hemispheric atrophy and cortical calcifications which are unilateral and ipsilateral to the cutaneous angioma.

Idiopathic Occipital Epilepsies

Idiopathic occipital epilepsies account for 20–30% of the benign childhood partial epilepsies. There are now three recognized forms of idiopathic occipital epilepsy.[8]

1. Early onset childhood epilepsy with occipital spikes [Panayiotopoulos syndrome (PS)]
2. Late-onset childhood epilepsy with occipital spikes (Gastaut syndrome)
3. Idiopathic photosensitive occipital epilepsy (IPOE).

The etiology is currently unknown, although an increasing number of partial epilepsy syndromes with a genetic basis are being recognized. These syndromes are similar because affected children have normal development and neurological examination, normal laboratory and imaging findings, and show equal sex distribution, yet differ with regard to age of onset, seizure frequency and duration, circadian rhythm, clinical characteristics, ictal EEG patterns, and prognosis.[9] (Table 3.2).

SEIZURE SEMIOLOGY

Epileptic seizures of parietal and occipital origin are heterogeneous and are mainly characterized by sensory auras, although the most dramatic clinical manifestations may reflect spread, and overshadow the focal origin (Table 3.3).[11] Different seizure types in a single patient may indicate different areas of seizure origin, but are often also just the result of different routes of seizure spread from a single focus.[12] The pattern of seizures is most commonly simple partial seizures, with occasional secondary generalization, and may sometimes be mistaken for auras associated with migraine (Table 3.4).[9]

Occipito-parietal seizures may be provoked by various stimuli. The most common precipitating factor is photic stimulation, but other well-known inducers are tactile stimuli, reading, drawing, calculation and other mental activity. Post-ictal phenomena associated with parietal and occipital seizures are transient numbness, inability to move despite no loss of power in affected limbs and postictal blindness.

The clinical manifestations and seizure semiology differ significantly in pediatric age groups, especially in infancy as compared to older children and adults because of lack of cortical maturity in infants.[1] Infants may present

JAYPEE BROTHERS

Table 3.2: Essential features of idiopathic occipital epilepsies

Feature	*Panayiotopoulos syndrome*	*Gastaut syndrome*	*IPOE*[10]
Prevalence	6%	0.5–1%	–
Peak age of onset	3–6 years	8–11 years	5–17 years
Typical symptom(s)	Autonomic symptoms with emesis	Elementary visual hallucinations	Elementary visual hallucinations
Ictus emeticus	Common and often at onset	Rare, not at onset	Not reported
Autonomic symptoms other than vomiting, hypersalivation	Common and often at onset	Exceptional	Exceptional
Visual symptoms	Uncommon, not at onset	Common, at onset	Common, at onset
Ictal behavioral changes	Common, at onset	Not reported	Not reported
Duration	More than 5 minutes	1–3 minutes	1–3 minutes
Partial status epilepticus	In more than 40%	Exceptional	Rare
Total number of seizures	1–15	Daily seizures	
Frequent seizures	10%	90%	
Nocturnal seizures	Common (64%)	Exceptional	Uncommon
Remission within 1–2 years of first seizure	Common	Rare, usually 2–5 years or more	Rare, usually 2–5 years or more
Seizures after the age of 13 years	Exceptional	Common	Common
Occipital spikes	65%	90%	Common
Spikes in other locations	Frequent	Exceptional	Infrequent
Photosensitivity	Exceptional	20–30%	Prominent
Ictal EEG	Slow activity with spikes	Fast spikes	Occipital spikes
Treatment	May not be needed in all patients. CBZ or VPA.	CBZ	VPA

Abbreviations: IPOE = Idiopathic photosensitive occipital lobe epilepsy, CBZ = Carbamazepine, VPA = Valproate

JAYPEE BROTHERS

Table 3.3: Symptomatology of posterior cortex epilepsies

Symptomatology	*Localization*	*Lateralization*
Simple visual	Primary visual cortex (areas 17, 18, 19)	Contralateral
Complex visual	Temporo-occipital junction and basal temporal cortex	Contralateral (if unilateral)
Nystagmus	Occipital cortex, parieto-occipital region	Contralateral to the fast component
Multisensorial	Mediobasal limbic cortex, temporal neocortex, temporo-parieto-occipital (TPO) junction	Non-lateralizing
Somatosensory	Primary somatosensory cortex (areas 1,2,3)	Contralateral
	Secondary somatosensory cortex	Ipsilateral (if unilateral)

Table 3.4: Differences between occipital seizures and migraine with visual auras

Occipital seizure	*Migraine with visual aura*
Progression of aura is rapid, takes few seconds	Usually takes several minutes
Moves fast within seconds towards the center of the visual field and contralateral to the side of onset	Moves slowly in minutes and towards the periphery of the visual field and ipsilateral to the side of onset
Usually with bright colors and circular shapes	Usually achromatic or black and white linear zig-zag patterns
Usually lasts 1–3 minutes	Usually lasts over 15 minutes
Eye deviation, eyelid flutter and sometimes convulsions may be noted.	Scotoma, hemianopia, hemianesthesia, hemiparesis, vertigo, ataxia, bilateral weakness and dysesthesias may be noted

with focal or generalized seizures. Many children have associated mental subnormality and are incapable of reporting auras, but hints of visual auras can sometimes be observed like sudden expression of fear, unexplained sudden laughter, rubbing eyes, etc. Such signs are sometimes the only signs of focality. Epileptic spasms and tonic seizures, asymmetric or symmetric, are the most prominent seizure types later on, but other seizure types like atypical absences, focal clonic or psychomotor seizures are also frequently noted. The severe epilepsies constitute about 10–20% of epilepsies in the pediatric age group and upto 50% in specialty clinics.[3] Epileptic encephalopathies are syndromes in which the recurrent seizures are responsible for cognitive deterioration, and amelioration of seizures or regression of abnormal rhythms on EEG results in clinical improvement. Although there is paucity of information on this subject from India, a study showed that nearly 50% of patients had West syndrome and they noted evolution from severe myoclonic

JAYPEE BROTHERS

epilepsy of infancy (SMEI) to West syndrome (WS) and to Lennox-Gastaut syndrome (LGS).[3] Prenatal causes or perinatal brain damage were found to be the most common risk factors.[4]

Other Neurological Impairments

Frank visual impairment is seen in children with severe bilateral parieto-occipital injury. Less subtle deficits may be identified only after a formal visual field testing which should be performed in all children with PCE, especially if they are candidates for surgery. Visual deficits may not be reported in children with severe cognitive impairment and such children may not be amenable for detailed testing.[13] Apart from visual impairment, strabismus and nystagmus may be noted on examination. A common deficit identified is homonymous hemianopia contralateral to the side of predominant atrophy. Bilateral field defects may be noted in children with significant bilateral parieto-occipital injury. Less subtle findings include quadrantanopsia.[13] Cognitive deficits require full intelligence testing and are common in children with perinatal insult and major malformations of cortical development. Attention deficit hyperactivity disorder and learning disability may be present. Presence of mental subnormality, behavioral problems, microcephaly and motor deficits indicate extensive cerebral damage.[14]

RADIOLOGICAL FEATURES

In occipital lobe epilepsy, three-quarters of patients may have underlying abnormalities on MRI.

Malformation of Cortical Development (MCD)

Focal cortical dysplasias (FCD) can easily be overlooked on MRI scans unless the posterior head region is carefully examined, and the reader is familiar with the complex gyral anatomy of the posterior cortex. Characteristic findings include poor delineation of the grey/white matter interface, focal cortical thickening and subcortical white matter T2 prolongation. Other malformations which can be seen in the posterior cortex on MRI are focal periventricular heterotopia, subcortical band heterotopia and polymicrogyria.[15]

A heterotopion is identified on MRI studies as isointense to cortical grey matter on all pulse sequences and does not enhance with gadolinium (Fig. 3.2). An important differential diagnosis is tuberous sclerosis. Heterotopia may be differentiated by their isointensity to grey matter as well as their ovoid and smooth shape, whereas subependymal nodules of tuberous sclerosis are iso or hypointense to white matter, calcified, elongated, irregular in shape, and may enhance with gadolinium.

Polymicrogyria has heterogeneous causes but is regarded as an abnormality of post-migratory cortical organization (Fig. 3.3). It may be caused by genetic conditions such as Zellweger's syndrome, by disorders of perfusion and hypoxia (from the 6th month in-utero onwards), infectious agents and toxic

JAYPEE BROTHERS

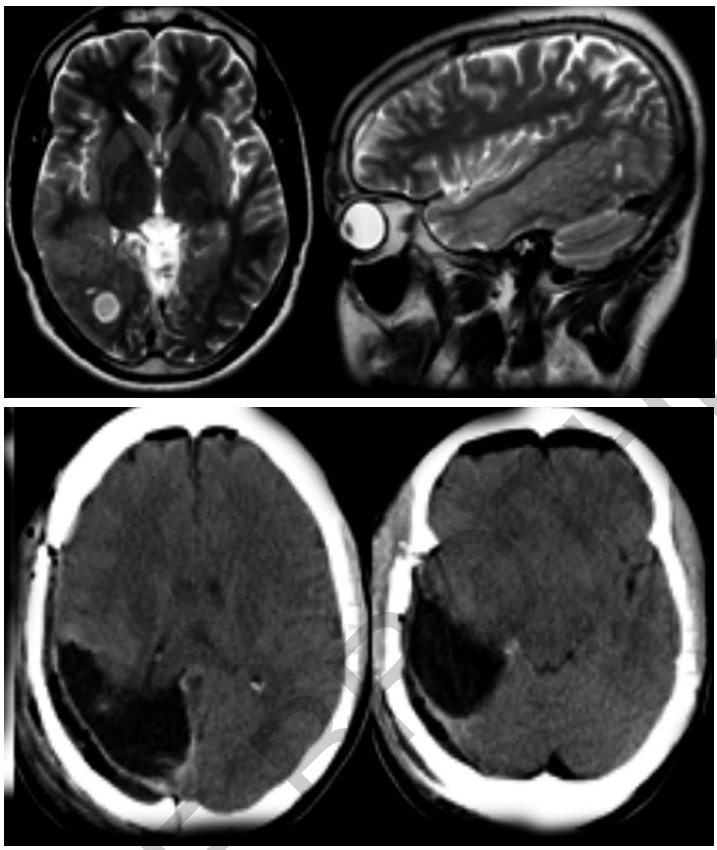

Fig. 3.2: A 3-year-old boy with refractory epilepsy due to nodular heterotopias in the right posterior cortex; seizure-free for 2 years following lesionectomy



Fig. 3.3: T1W axial MRI brain images of a 6-year-old boy with bilateral parasaggital parieto-occipital polymicrogyria (arrows)

JAYPEE BROTHERS

insults.[15] Polymicrogyria should be distinguished from ulegyria as both are noted in the watershed areas. The MRI appearance of polymicrogyria varies; it may be hard to distinguish from pachygyria where there are broadened gyri, cortical thickening and an irregular grey-white matter interface.

Perinatal Insult

The parieto-occipital areas are usually the most affected and MRI usually shows unilateral or often bilateral (but asymmetric) atrophy. Affected areas can be small or widespread, depending on the severity of the hypoxic-ischemic event. A characteristic finding in more severe cases is the presence of asymmetric bilateral cortical and subcortical scars within the parieto-occipital areas and a generalized atrophy.[16] Care should be taken to differentiate areas of cortical damage (e.g. ulegyria) from subcortical damage (which is not epileptogenic), although this may be challenging at times. Ulegyria can be distinguished from polymicrogyria by MRI features such as the presence of white matter abnormalities and peculiar mushroom-shaped gyri (Fig. 3.4).

Suggested MRI criteria for ulegyria are:[5]

- Atrophy and thinning of the cortex involving mainly the deep portion of the convolution and sparing the apex, resulting in mushroom-shaped gyri.
- White matter signal abnormalities on T2-weighted and fluid-attenuated inversion recovery (FLAIR) sequences.

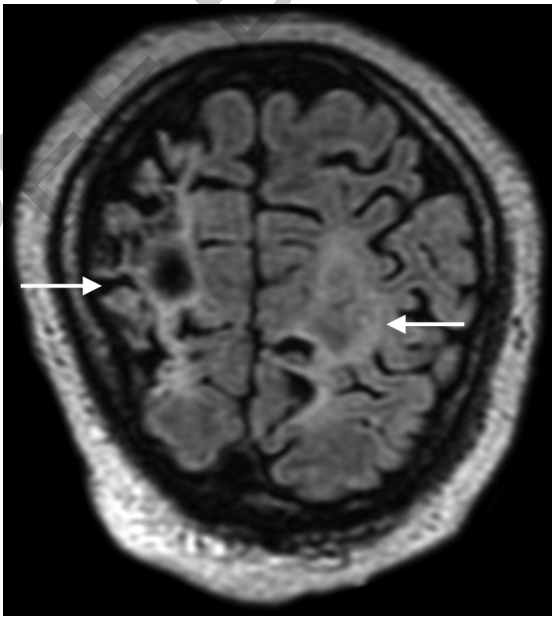

Fig. 3.4: T2 FLAIR coronal MRI brain images in a 8-year-old girl with perinatal hypoxia and refractory seizures showing bilateral occipital gliosis (right more than left, arrows), with ulegyria prominent on the right side

JAYPEE BROTHERS

EEG in Prenatal Insult

Interictal EEG

Background activity is often (but not always) slow because of parieto-occipital damage. Bilateral (bi-parieto-occipital) spikes or spike-wave complexes may indicate bilateral epileptogenic areas but are often the result of spread (secondary bilateral hypersynchrony). Spikes or spike-wave-complexes may be recorded over other areas, usually representing larger areas of spread in the immature brain, rather than extensive cerebral injury.

Ictal EEG

This may be lateralizing and/or localizing, but is often misleading too. In extensive gliosis and atrophy, ictal rhythm may be recorded over the ipsilateral occipital region or from areas distant from the margins of the gliosis, but away from the occipital region. Generalized fast activity mimicking LGS may be identified as the ictal rhythm even in patients with focal lesion or gliosis.

MANAGEMENT

Once the clinical and electrical data suggests a possibility of occipital epilepsy, the syndromic classification needs to be established: idiopathic/benign occipital epilepsy versus symptomatic epilepsy. The most important step is to review the developmental status, electrical and neuroimaging data carefully. Metabolic investigations, muscle or skin biopsy are required if mitochondrial disorders or PME are suspected. A screening for Celiac disease should be considered in a patient presenting with bilateral occipital calcifications.

Medical Treatment

Principles of therapy are similar to other localization related epilepsies. Most patients respond to carbamazepine or oxcarbazepine. In idiopathic occipital epilepsies, especially in photosensitive occipital epilepsy, sodium valproate is the drug of choice. In children, especially those with perinatal insult, who present with epileptic encephalopathy, treatment should not only aim for the control of clinical seizures, but also for the suppression of subclinical seizures and for the suppression of spikes/spike and wave discharges over undamaged cortical areas, as this is important for the cognitive development in this group of patients in whom the amount of normal brain structure is reduced. Often patients with West syndrome evolve to LGS, and most of these children become medically refractory and have a poor prognosis and require polypharmacy, steroids and even ketogenic diet.

Epilepsy Surgery

Surgery is increasingly being offered for those with medically refractory occipital epilepsy, especially with a structural abnormality on MRI like FCD, tumors and ulegyria. The extent of resection of the lesion is the most important determinant of surgical success and seizure freedom.[17] The focal nature of an occipital lesion, rather than the location of the lesion, has been shown to predict outcome, tumors faring significantly better than developmental

JAYPEE BROTHERS

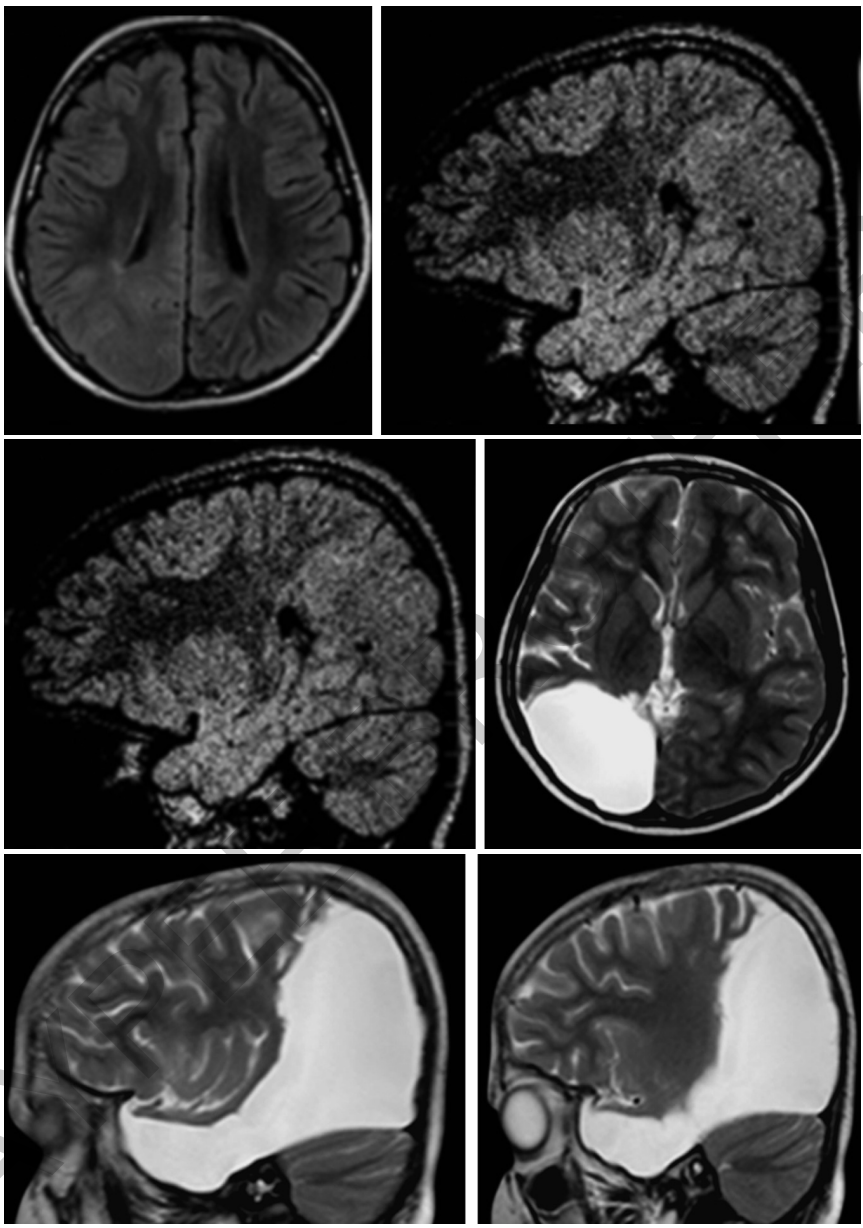

Fig. 3.5: Top row: Axial (first image) and sagittal (second and third image) T2 FLAIR MRI brain images of a 10-year-old girl with right temporo-parieto-occipital malformation of cortical development with refractory seizures since 1 year of age

Bottom row: Axial (first image) and sagittal (second and third image) T2W MRI brain images showing changes after right posterior quadrant resection. She is seizure-free for the last 3 years

malformations.[18] (Fig. 3.5). Vagus nerve stimulation can be considered in those, with widespread or bilateral pathology where focal resection may not be feasible.

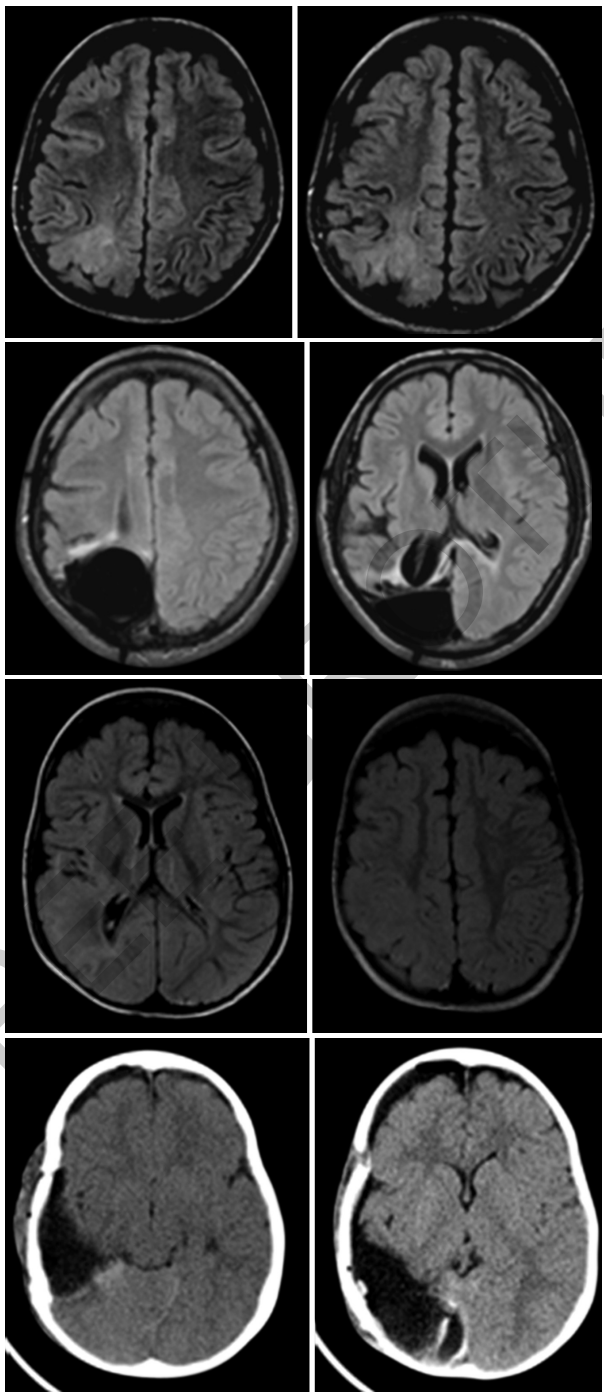

Fig. 3.6: Preoperative and postoperative T2 FLAIR axial MRI images in two patients with malformation of cortical development and refractory posterior cortex epilepsy who underwent posterior quadrant resection with Engel Class 1 outcome

JAYPEE BROTHERS

Until recently, epilepsy surgery in children with perinatal insult was offered only to those with strictly unilateral gliosis and was avoided even in some unilateral cases because of discordant EEG findings. However, numerous studies have clearly demonstrated that resection of the cortical scars result in excellent seizure outcome in a good majority of well-selected patients.[19,20] Because of the complexity of the epilepsies in children with parieto-occipital gliosis, a high level of expertise is required in pre-surgical evaluation and for planning surgery. The extent of resection is determined primarily based on the location and extent of MRI lesions, taking functional cortical areas into account[21] (Fig. 3.6). Invasive EEG has utility limited in identifying the eloquent cortex.[22] In a series of 10 patients with posterior cortex epilepsy, the occipital lobe was completely resected in nine patients, and the adjacent parietal lobe and/or temporal lobe was also resected when necessary. Seizure outcome was Engel class I in four of six patients with bilateral lesions. Therefore, bilateral lesions should not be excluded from presurgical evaluation if the lesions are asymmetric and if EEG and semiology are concordant with the side of predominant atrophy.[16]

Postoperative Changes

In a study that looked at changes in neuropsychological data prior to and 6 months after posterior cortical resections in 28 patients, general intelligence did not change significantly, postoperative verbal intelligence consistently increased, whereas performance intelligence decreased. There was no effect regarding the lesion side, continuation of seizures, or reduction of visual field after surgery.[23] In another study of patients who were evaluated 2 years after surgery, no decline of cognition, including performance intelligence, was detected. Resection of the posterior cortex with ulegyria therefore may bear no risk for decline in intelligence.[23] Though patients without preoperative visual field defect often develop new visual field defects postoperatively, they gradually adapt to the visual field impairment. The visual field impairment is tolerable if the patient becomes seizure-free after surgery. All patients in one study developed postoperative visual field defects, probably because of the removal of the occipital lobe completely in nine out of ten patients.[16]

CONCLUSION

Posterior head region epilepsies comprise a small but significant proportion of children with epilepsy, and though heterogeneous in etiopathogenesis, have fairly recognizable clinical features. While idiopathic occipital epilepsies have a uniformly good prognosis and respond well to therapy, symptomatic epilepsy, especially those due to perinatal insults and developmental defects often become drug resistant and can present with epileptic encephalopathy. If it is observed that the child shows improvement in developmental parameters during times of good seizure control, all efforts, medical and surgical should be made to control the epileptic encephalopathy. Pessimistic attitude towards these patients because of the history of perinatal insult,

JAYPEE BROTHERS

frequent seizures, cognitive impairment, visual deficits, bilateral or extensive EEG abnormalities is to be avoided as evidenced by numerous recent studies showing excellent surgical outcomes in these children.

REFERENCES

1. Rakhade SN and Jensen FE. Epileptogenesis in the immature brain: emerging mechanisms. Nat Rev Neurol. 2009;5(7):380-91.
2. Shorvon SD. The causes of epilepsy: changing concepts of etiology of epilepsy over the past 150 years. Epilepsia. 2011;52(6):1033-44.
3. Singhi P and Ray M. Profile of West syndrome in North Indian children. Brain Dev. 2005; 27(2):135-40.
4. Udani V, Munot P, Ursekar M, et al. Neonatal hypoglycemic brain injury—a common cause of infantile onset remote symptomatic epilepsy. Indian Pediatr. 2009;46(2):127-32.
5. Kuchukhidze G, Unterberger I, Dobesberger J, et al. Electroclinical and imaging findings in ulegyria and epilepsy: a study on 25 patients. J Neurol Neurosurg Psychiatry. 2008;79(5):547-52.
6. Oguni H, Sugama M and Osawa M. Symptomatic parieto-occipital epilepsy as sequelae of perinatal asphyxia. Pediatr Neurol. 2008;38(5):345-52.
7. Rani U, Imdad A and Beg M. Rare neurological manifestation of celiac disease. Case Rep Gastroenterol. 2015;9(2):200-5.
8. Guerrini R and Pellacani S. Benign childhood focal epilepsies. Epilepsia. 2012;53 (Suppl 4):9-18.
9. Panayiotopoulos CP, Michael M, Sanders S, et al. Benign childhood focal epilepsies: assessment of established and newly recognized syndromes. Brain. 2008;131: 2264-86.
10. Yilmaz K and Karatoprak EY. Epilepsy classification and additional definitions in occipital lobe epilepsy. Epileptic Disord. 2015;17(3):299-307.
11. Foldvary-Schaefer N and Unnwongse K. Localizing and lateralizing features of auras and seizures. Epilepsy Behav. 2011;20(2):160-6.
12. Latini F, Hjortberg M, Aldskogius H, et al. The classical pathways of occipital lobe epileptic propagation revised in the light of white matter dissection. Behav Neurol. 2015;2015:872645.
13. Karaoğlu P, Polat AI, Yis U, et al. Parieto-occipital encephalomalacia in children: clinical and electrophysiological features in twenty-seven cases. J Pediatr Neurosci. 2015;10:103-7.
14. Montassir H, Maegaki Y, Ohno K, et al. Long term prognosis of symptomatic occipital lobe epilepsy secondary to neonatal hypoglycemia. Epilepsy Res. 2010;88:93-9.
15. Barkovich AJ, Guerrini R, Kuzniecky RI, et al. A developmental and genetic classification for malformations of cortical development: update 2012. Brain. 2012;135:1348-69.
16. Usui N, Mihara T, Baba K, et al. Posterior cortex epilepsy secondary to ulegyria: is it a surgically remediable syndrome? Epilepsia. 2008;49(12):1998-2007.
17. Davis KL, Murro AM, Park YD, et al. Posterior quadrant epilepsy surgery: predictors of outcome. Seizure. 2012;21(9):722-8.
18. Jehi LE, O'Dwyer R, Najm I, et al. A longitudinal study of surgical outcome and its determinants following posterior cortex epilepsy surgery. Epilepsia. 2009;50(9): 2040-52.

JAYPEE BROTHERS

19. Yang PF, Jia YZ, Lin Q, et al. Intractable occipital lobe epilepsy: clinical characteristics, surgical treatment, and a systematic review of the literature. Acta Neurochir. 2015;157:63-75.
20. Marchi A, Bonini F, Lagarde S, et al. Occipital and occipital "plus" epilepsies: A study of involved epileptogenic networks through SEEG quantification. Epilepsy Behav. 2016;62:104-14.
21. Liava A, Mai R, Tassi L, et al. Paediatric epilepsy surgery in the posterior cortex: a study of 62 cases. Epileptic Discord. 2014;16:141-64.
22. Binder DK, von Lehe M, Kral T, et al. Surgical treatment of occipital lobe epilepsy. J Neurosurg. 2008;109:57-69.
23. Luerding R, Boesebeck F and Ebner A. Cognitive changes after epilepsy surgery in the posterior cortex. J Neurol Neurosurg Psychiatry. 2004;75(4):583-7.

JAYPEE BROTHERS

r detailed information on neurology books, visit our website www.jaypeebrothers.com, for detailed information on neurology

PEDIATRIC EPILEPSY SYNDROMES

Seizures, Syndromes, Approach and Management

This book on pediatric epilepsy is a lucid compilation of all available literature on this subject conforming to the latest evidence-based guidelines. It may be one of its kind in this country considering the scarcity of an easy-reference manual for neurologists, physicians, pediatricians and medical practitioners. This medical book is a really handy compendium of all updated information pertaining to the approach and management of pediatric epilepsy syndromes.



Ashalatha Radhakrishnan is Professor of Neurology. After taking her epilepsy fellowship under the stewardship of Prof Samuel Berkovic and Prof Ingrid E Scheffer at Melbourne in 2007–2008, she joined back R Madhavan Nayar Center for Comprehensive Epilepsy Care (RMNC), Department of Neurology at the prestigious Sree Chitra Tirunal Institute for Medical Sciences and Technology (SCTIMST), Thiruvananthapuram, Kerala, India. She has to her credit several scientific publications in various National and International journals, has authored many chapters in textbooks on epilepsy, and is the editor of books on various aspects of epilepsy including the one on Status Epilepticus which was published by the same publisher. Many honors have come in her way including the latest British Medical Journal (BMJ) award of 2015 for the Best Medical Team of Asia for her Epilepsy team in which she plays a significant role. Her interests are management of drug-resistant epilepsies subjecting them to various resective surgeries, establishing newer imaging techniques in epilepsy and managing emergencies in epilepsy. With a vast experience of treating epilepsies of all types in all age groups, she has accrued immense expertize and a keen interest to channelize her experience in a more creative way, transforming herself as Editor of this book. Only a very astute academician and erudite clinician like her can do the job of compiling and editing the various epilepsy syndromes in children to bring out such a systematically crafted book. This textbook is thus intended to appraise any physician, guiding them to approach and manage pediatric epilepsies in the most systematic and scientific way.

Available at all medical bookstores
or buy online at www.jaypeebrothers.com

JAYPEE BROTHERS
Medical Publishers (P) Ltd.
www.jaypeebrothers.com

Join us on facebook.com/JaypeeMedicalPublishers

Shelving Recommendation
NEUROLOGY

ISBN 978-93-86322-31-9