r website **www.jaypeebrothers.com,** for detailed information on radiology books, visit our website **www.jaypeebrothers.com**

Atlas of Human Anatomy on MRI

Brain, Chest & Abdomen



Hariqbal Singh
Parvez Sheik

JAYPEE

Contents

1. Brain **1**

- Prosencephalon *1*
- Mesencephalon and Rhombencephalon *21*
- Cerebrospinal Fluid and Ventricular System *23*

2. Chest **35**

- Airways *35*
- Pulmonary Circulation *35*
- MR Chest Sequences and Salient Features *36*
- MR Anatomy of Chest Structures *37*

3. Abdomen **62**

Salient Features of MR Abdomen *125*

4. Magnetic Resonance Cholangiopancreatography **127**

Anatomy *127*

5. Female Pelvis Magnetic Resonance Imaging **141**

6. Male Pelvis Magnetic Resonance Imaging **152**

7. Magnetic Resonance Angiography **163**

MRA Indications *163*

Appendix *177*

- Glossary of MRI Terms *177*
- Normal Radiology Measurements *180*

Index *187*

CHAPTER 4

Magnetic Resonance Cholangiopancreatography

ANATOMY

Gallbladder is a hollow muscular organ located in the gallbladder fossa on the posteroinferior aspect of liver; it concentrates bile which can be appreciated on T2W images as high signal intensity fluid (Figs 1 to 6 and 18). The gallbladder has a fundus, body and a narrow neck. The cystic duct originates from the neck region of gallbladder and runs forwards to join the common hepatic duct. The cystic duct is normally about 2–3 cm in length and 2–3 mm in diameter in adults. The cystic artery is a branch of right hepatic artery and supplies the gallbladder. The cystic artery can be located in Calot's triangle formed by the inferior border of liver, the common hepatic duct and the cystic duct. Calcific foci or stones within the gallbladder show as focal signal loss on axial and coronal T2WI.

Common bile duct is formed by the union of common hepatic duct and cystic duct; they are visualized on 3D magnetic resonance cholangiopancreatography (MRCP) MIP images (Figs 1 to 15). The common bile duct courses forwards to empty into the ampulla of Vater situated on the medial aspect of second part of duodenum.

Pancreas is a retroperitoneal structure showing feathery parenchymal structure with few lobulations on axial and coronal MR images in upper abdomen. As most of the pancreas is composed of glandular tissue, they show intermediate to high signal on T2W images (Figs 4 to 14 and 17). The pancreas for descriptive purposes is subdivided into head, neck, body and tail regions. The head of pancreas is located in the concavity of the C-loop of duodenum. The neck of pancreas is a narrow region connecting the head to

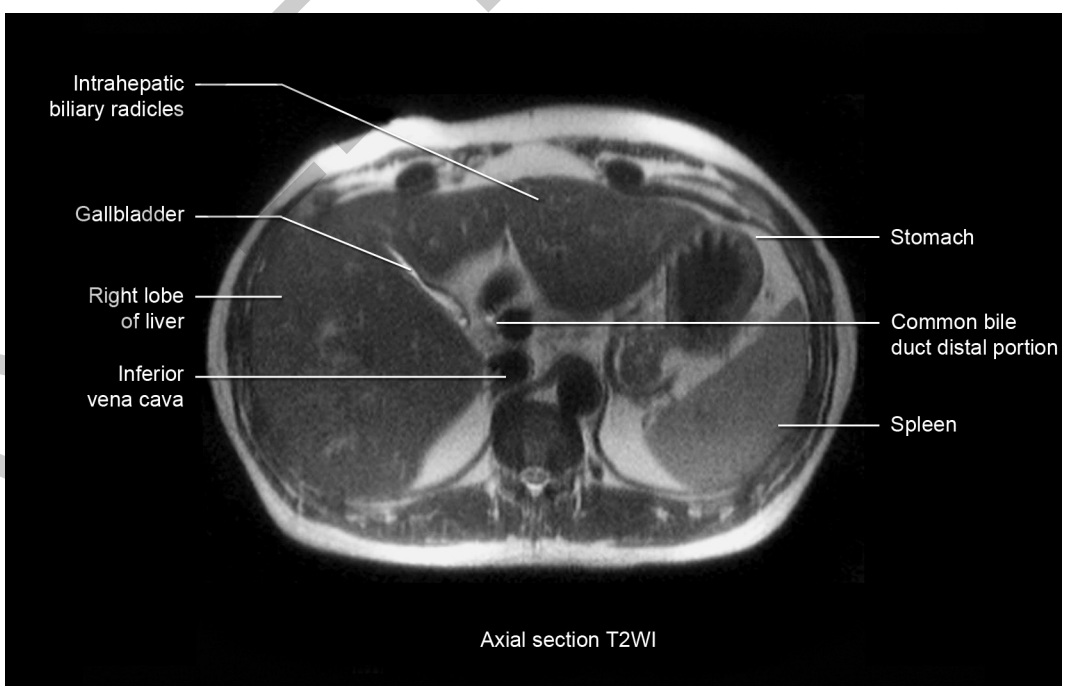

Fig. 1

JAYPEE BROTHERS

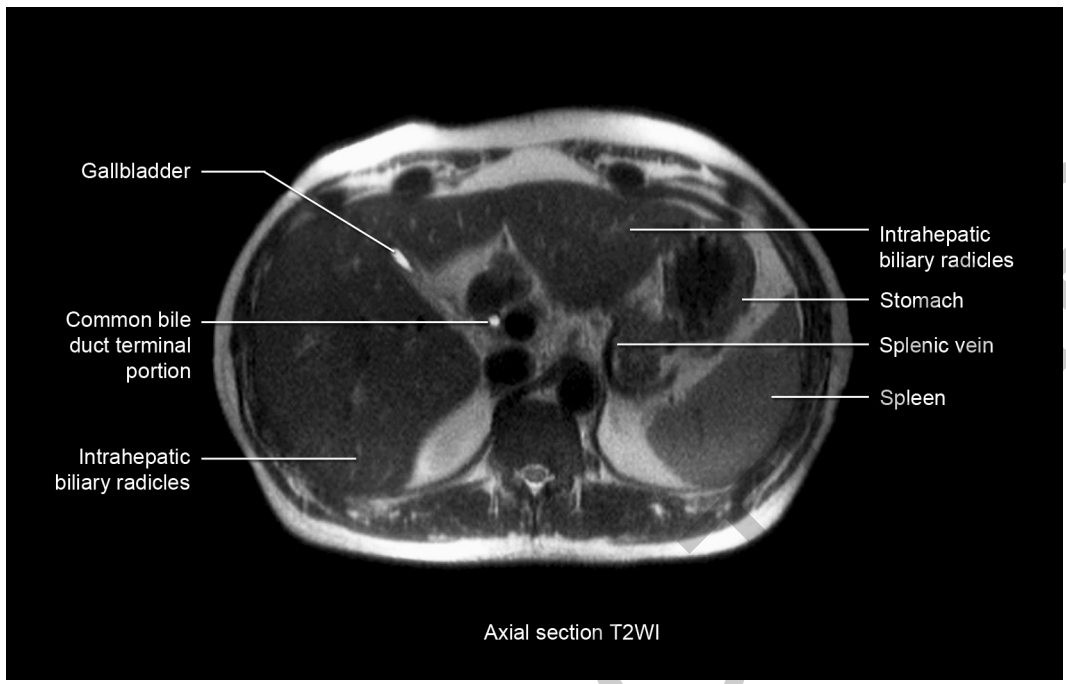

Fig. 2

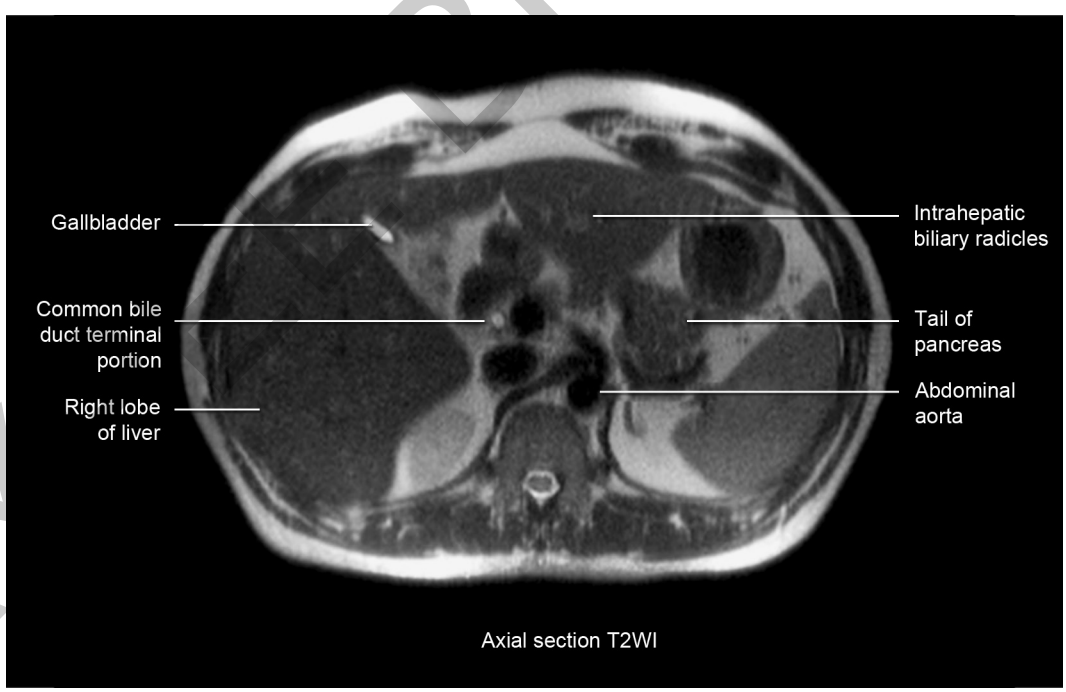

Fig. 3

JAYPEE BROTHERS

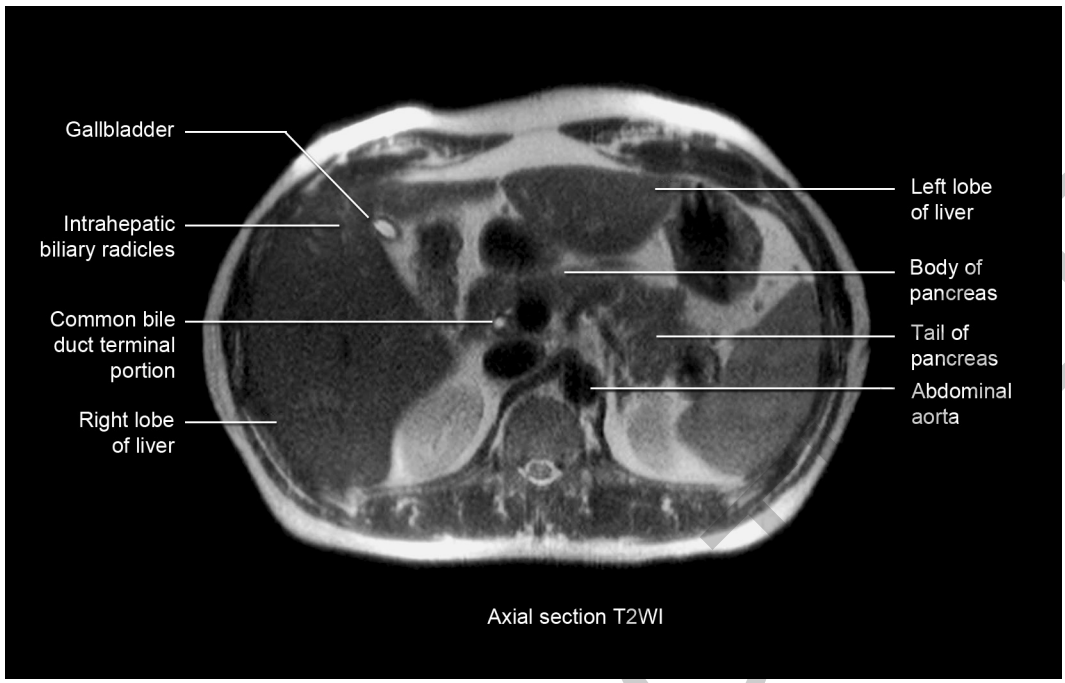

Fig. 4

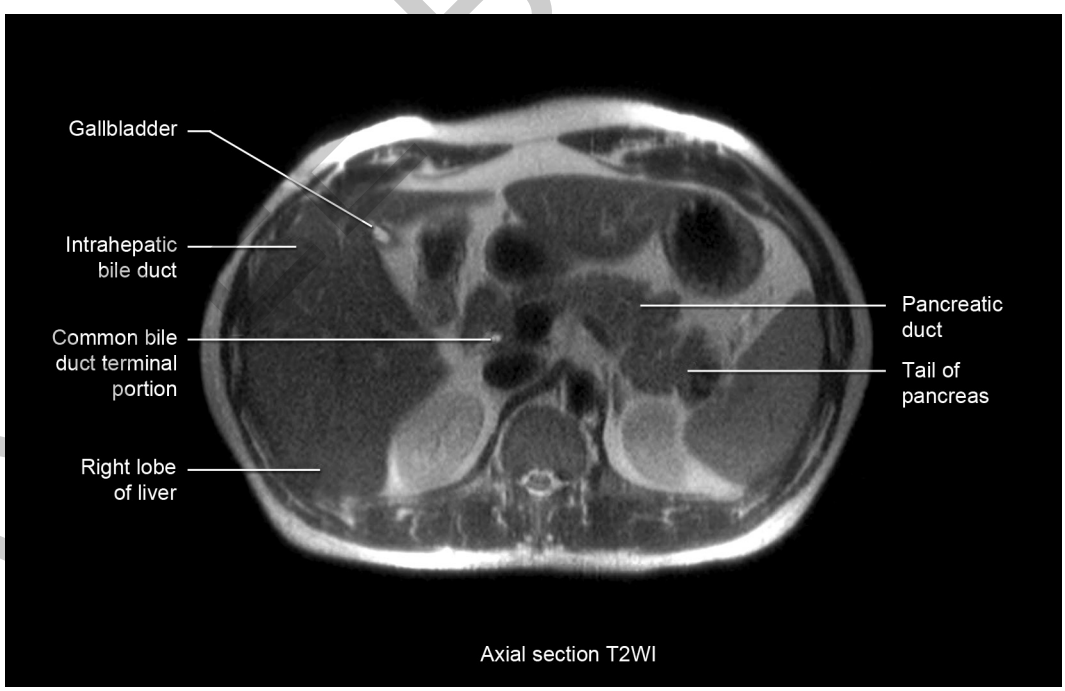

Fig. 5

JAYPEE BROTHERS

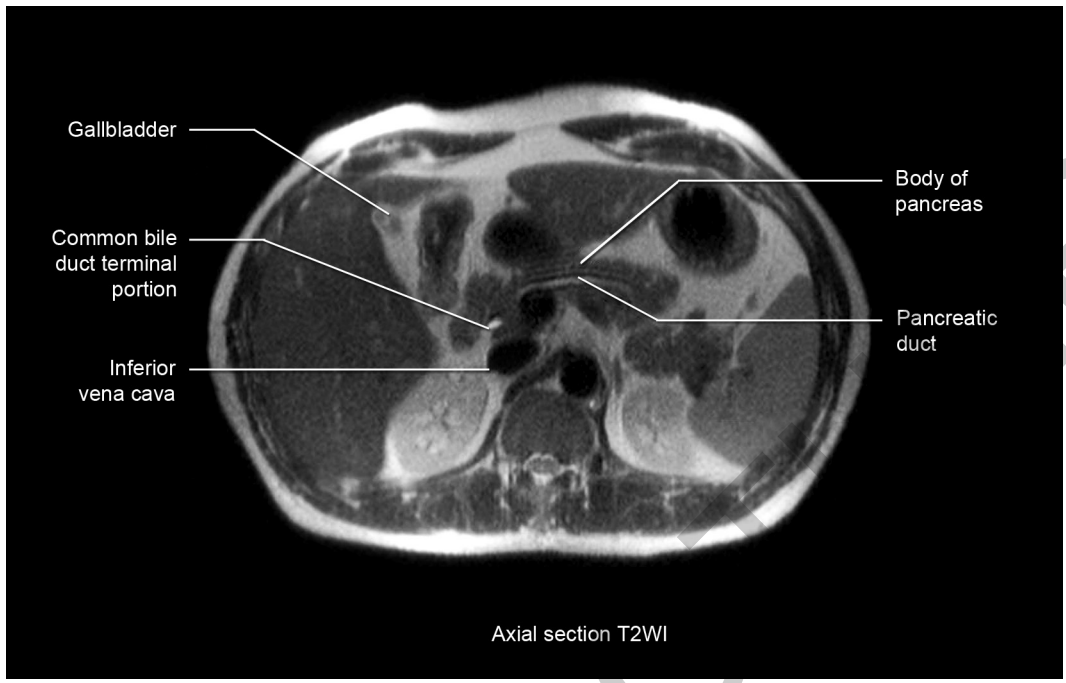

Fig. 6



Fig. 7

JAYPEE BROTHERS

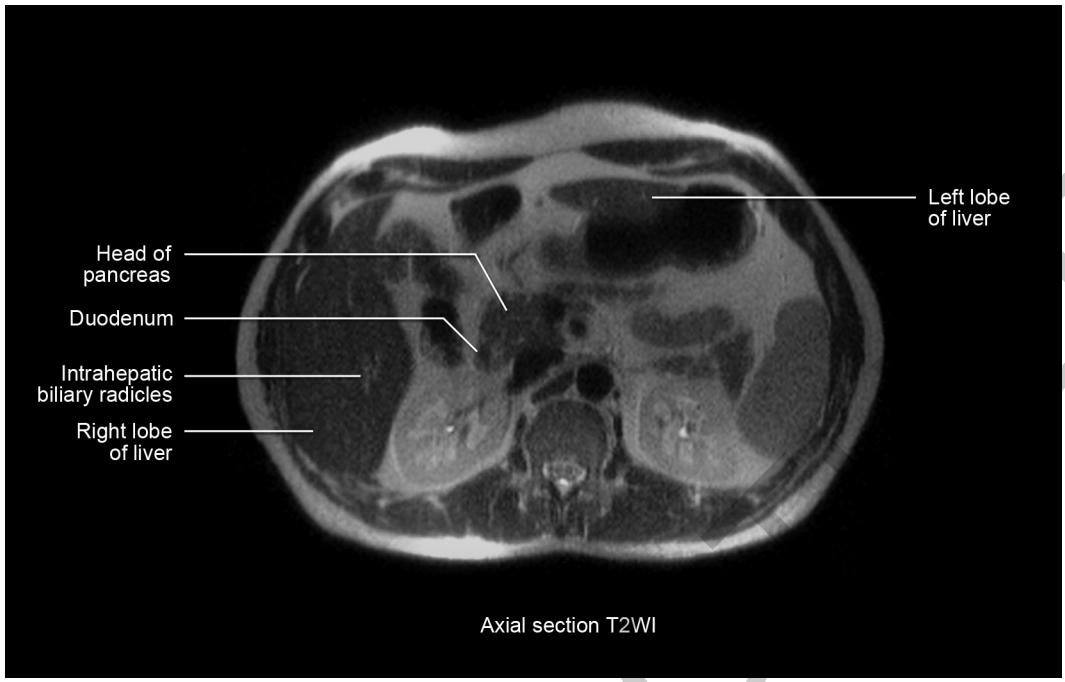

Fig. 8



Fig. 9

JAYPEE BROTHERS

body of pancreas. Behind the neck of pancreas the splenic vein joins the superior mesenteric vein to form the portal vein. The body of pancreas runs transversely across the midline from the right side of abdomen to the left side. The body of pancreas lies anterior to the abdominal aorta. The tail of pancreas is situated near the splenic hilum.

Duodenum is a hollow C- shaped muscular tube. It begins at the pyloric antral region seen on axial and coronal T2W images as intermediate signal intensity structure. The duodenum can be described in four parts—the first part is horizontal (5 cm) on right side of midline at the level of L1 vertebra, second part is vertical (7.5 cm) in right side of midline at the level of L2 vertebra, third part is horizontal (10 cm) crosses the midline to left side at the level of L3 vertebra, fourth part is vertical (2.5 cm) at the level of L2 vertebra (Figs 11, 15 and 17). The head of pancreas is situated within the concavity of C-shape of duodenum. The first part of duodenum is commonly referred to as the duodenal cap; the gallbladder is anterior to the first part of duodenum. The medial aspect of second part of duodenum has the ampulla of Vater which receives the pancreatic duct and common bile duct. The anterior aspect of third part of duodenum is related to the jejunal loops. The fourth part of duodenum ends at the duodenojejunal flexure.

Liver contains hepatocytes which produce bile. The functional unit of liver is the hepatic lobule, a hexagonal shaped structure. At the center of the hepatic lobule is a central vein, the hepatocytes are seen arranged in sheets radiating towards the periphery separated from each other by sinusoids. At the corners of each hepatic lobule is the portal triad which consists of hepatic artery, portal vein and small intrahepatic biliary ductules. Bile produced by the hepatocytes in the hepatic lobule, enters the biliary canaliculi which are situated between the opposing sides of the adjacent hepatocytes. These biliary canaliculi form a meshwork which drains into the bile ductules located at the portal triad. Subsequently the bile ductules unite to form larger intrahepatic bile ducts or radicles (IHBR) which show high signal intensity on T2WI. In biliary obstruction these IHBR appear as dilated structures in liver parenchyma (Figs 11 to 17).



Fig. 10

JAYPEE BROTHERS

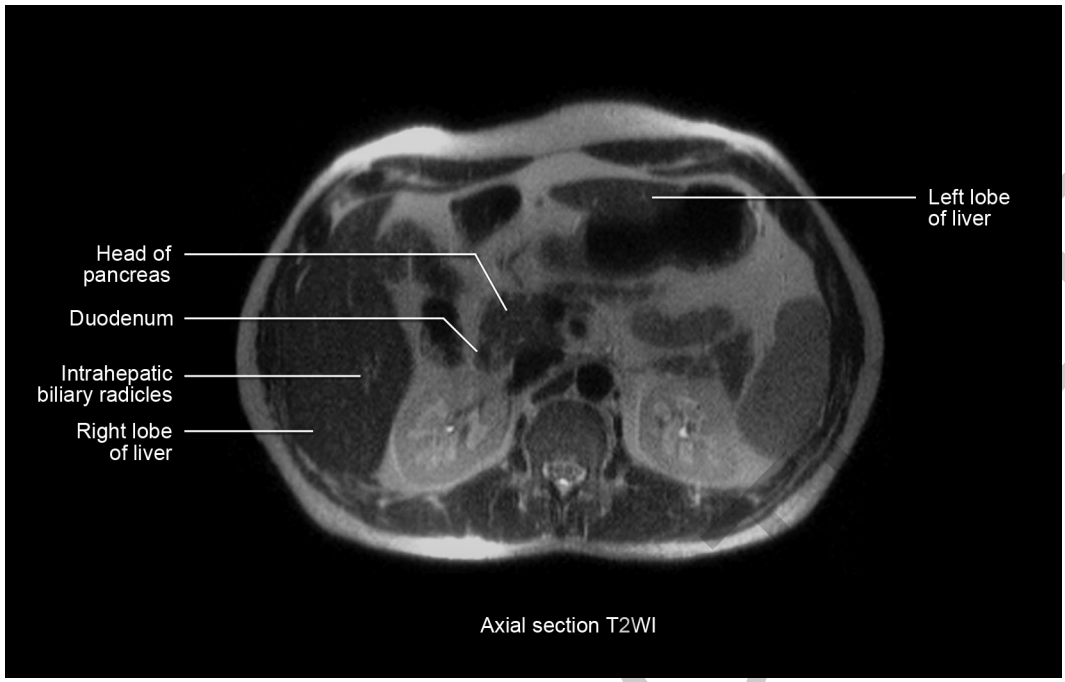

Fig. 11
Figs 1 to 11 MRCP axial T2WI

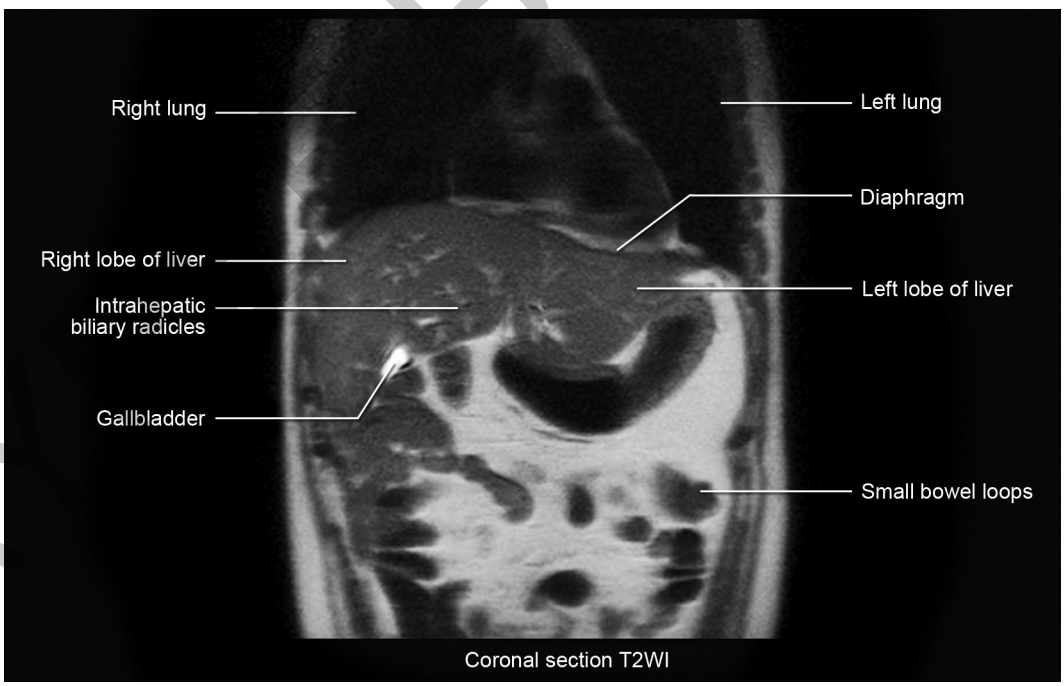

Fig. 12

JAYPEE BROTHERS

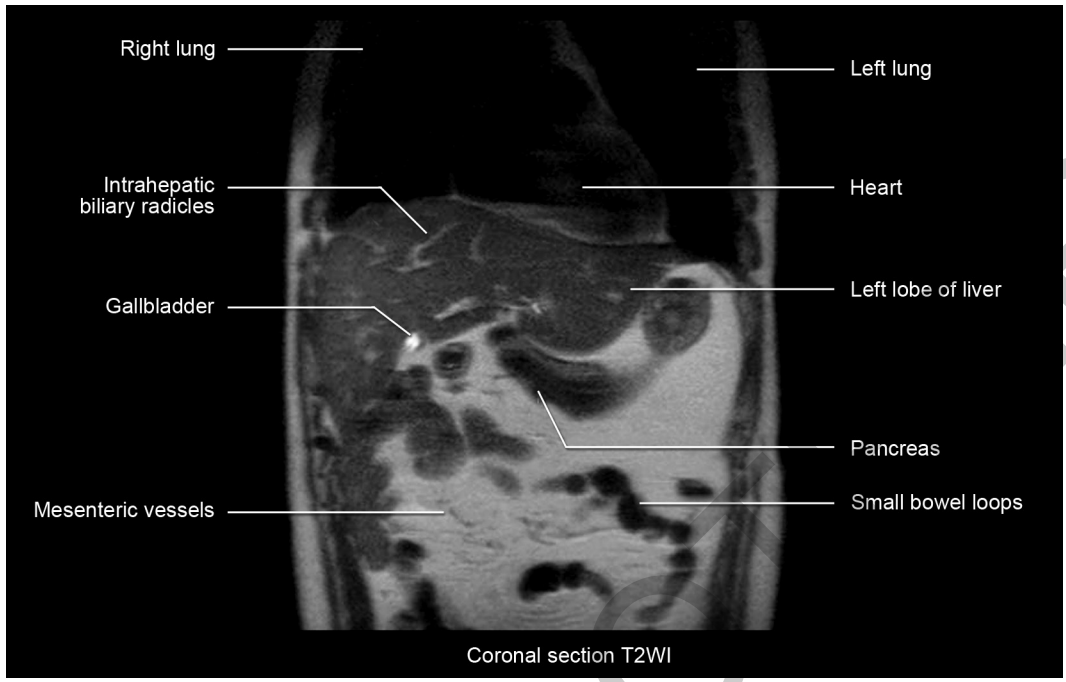

Fig. 13

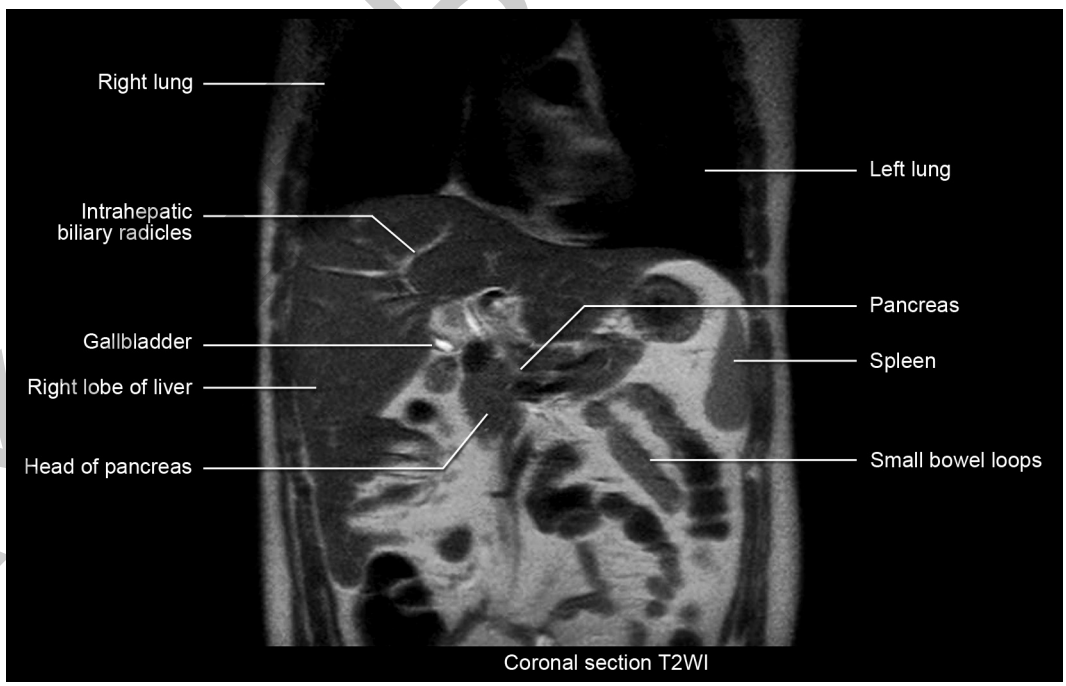

Fig. 14

JAYPEE BROTHERS

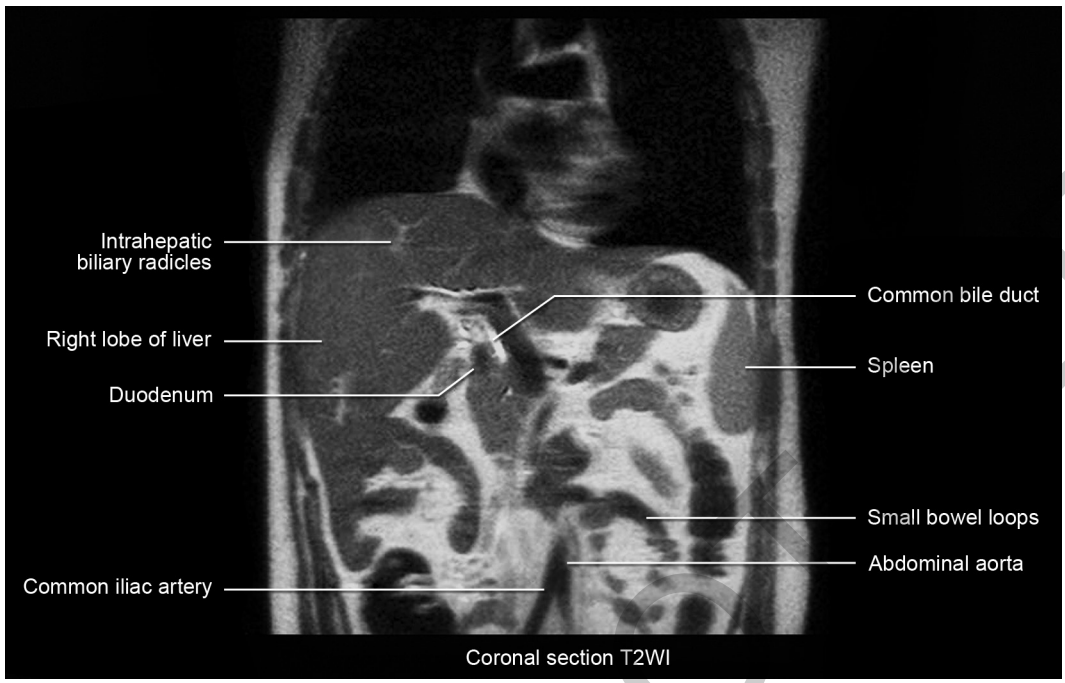
Intrahepatic biliary radicles
Right lobe of liver
Duodenum
Common iliac artery
Common bile duct
Spleen
Small bowel loops
Abdominal aorta
Coronal section T2WI

Fig. 15

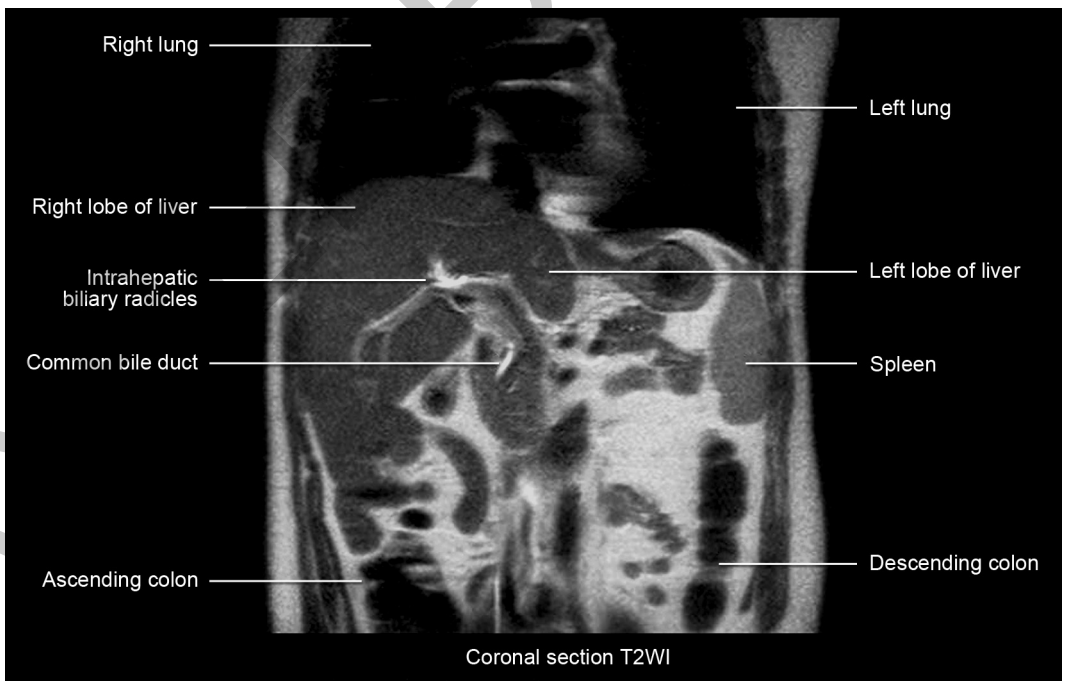
Right lung
Right lobe of liver
Intrahepatic biliary radicles
Common bile duct
Ascending colon
Left lung
Left lobe of liver
Spleen
Descending colon
Coronal section T2WI

Fig. 16

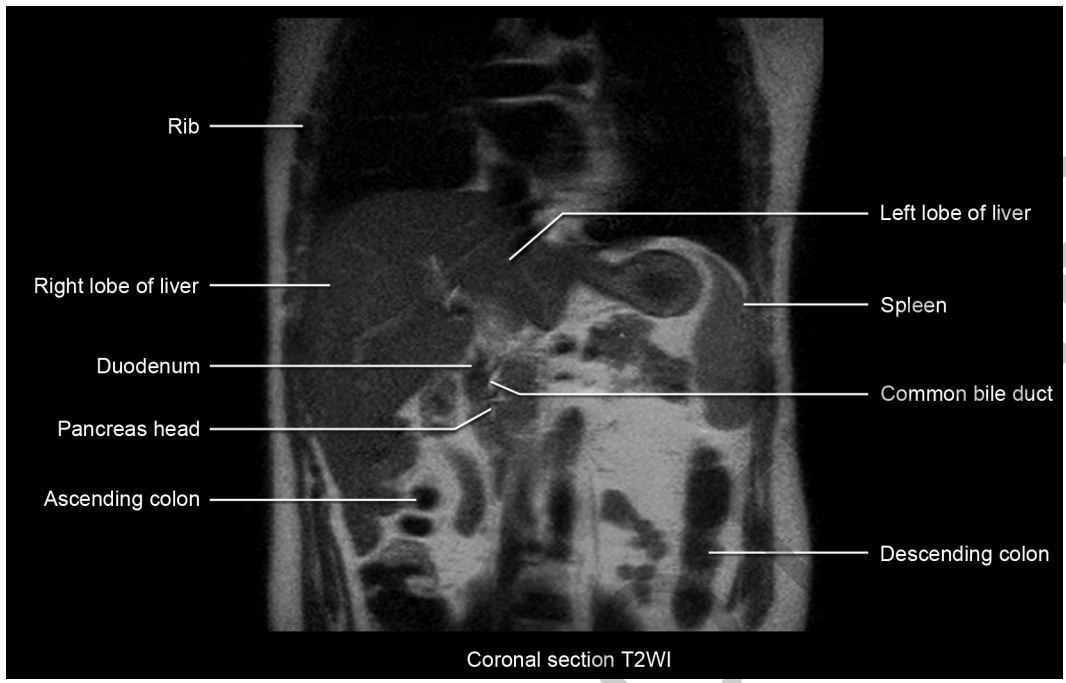

Fig. 17
Figs 12 to 17 Coronal T2W images showing the biliary system

Common hepatic duct is formed by the union of right and left hepatic ducts near the porta hepatis; they are visualized on 3D MRCP MIP images (Figs 18 and 19).

Cystic duct is seen on 3D MRCP MIP images to originate from the neck region of gallbladder and terminates by joining the common hepatic duct to form the common bile duct (Figs 18 and 19). The cystic duct is normally about 2–3 cm in length and 2–3 mm in diameter in adults.

Pancreatic duct is visualized as a thin walled structure from the tail region to the head of pancreas on 3D MRCP MIP images. The pancreatic duct (of Wirsung) terminates at the ampulla of Vater where the common bile duct drains into the 2nd part of duodenum (Figs 18 to 20). The diameter of pancreatic duct is around 2 mm in adults and drains most of the pancreas except for the uncinate process which drains through the small accessory ducts (of Santaroni).

Magnetic resonance cholangiopancreatography (MRCP) is a special technique using MRI to investigate the hepatobiliary system for any mass or lesions. The high resolution images give detailed information about the bile ducts, intrahepatic radicles, cystic duct, common hepatic duct, common bile duct, pancreatic duct, gallbladder and pancreas.

Principle of MRCP: The principle of MRCP is that static or slow-moving fluids such as bile and pancreatic secretions within the biliary tree and pancreatic duct have a much longer T2 than solid tissue does and have high signal intensity (SI) on heavily T2-weighted images whereas background soft tissues have very low SI.

Magnetic resonance cholangiopancreatography (MRCP) should be the preferred over endoscopic retrograde cholangiopancreatography (ERCP) in the following situations: (i) pediatric age group cases (ii) elderly patients

JAYPEE BROTHERS

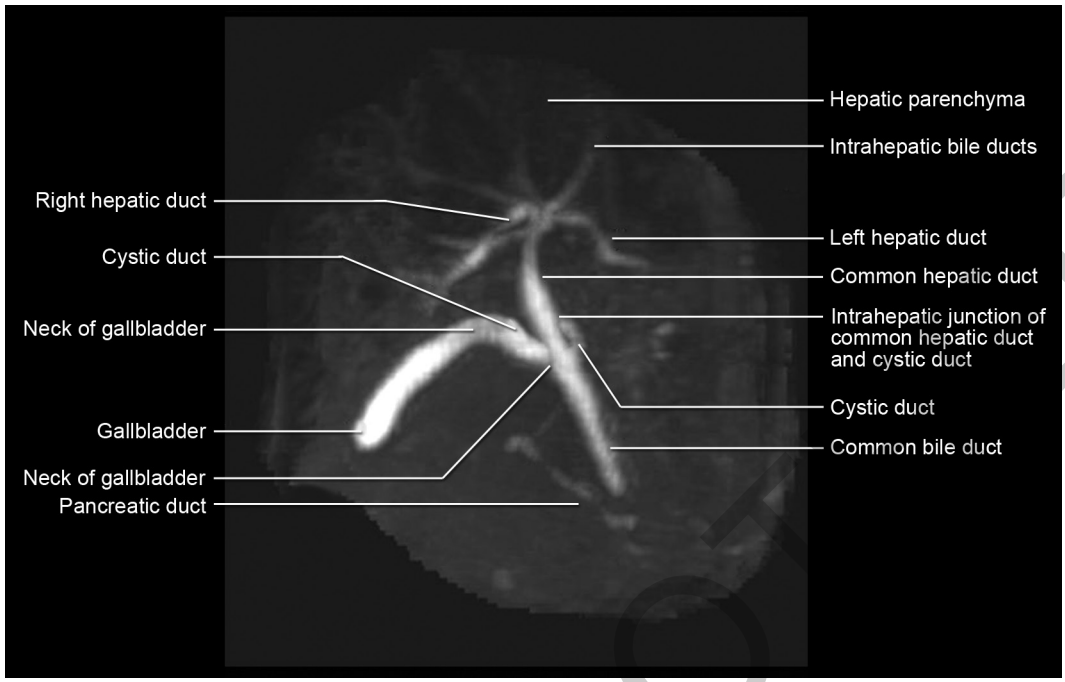

Fig. 18

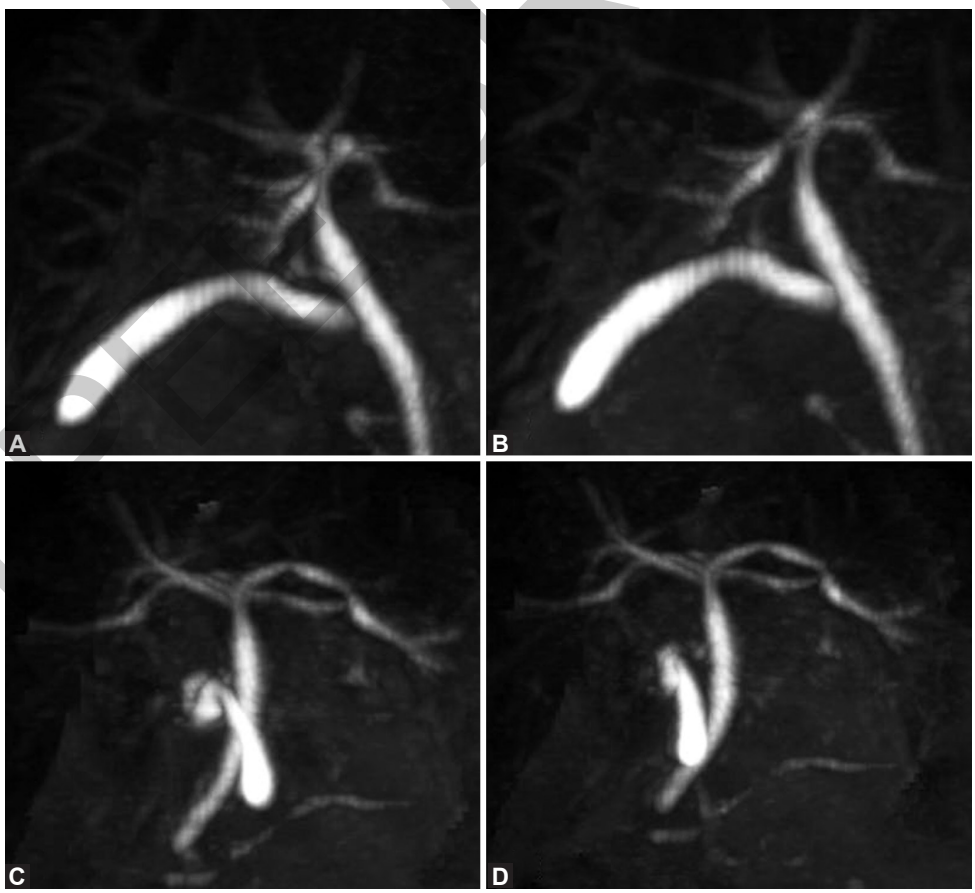

Figs 19A to D

JAYPEE BROTHERS

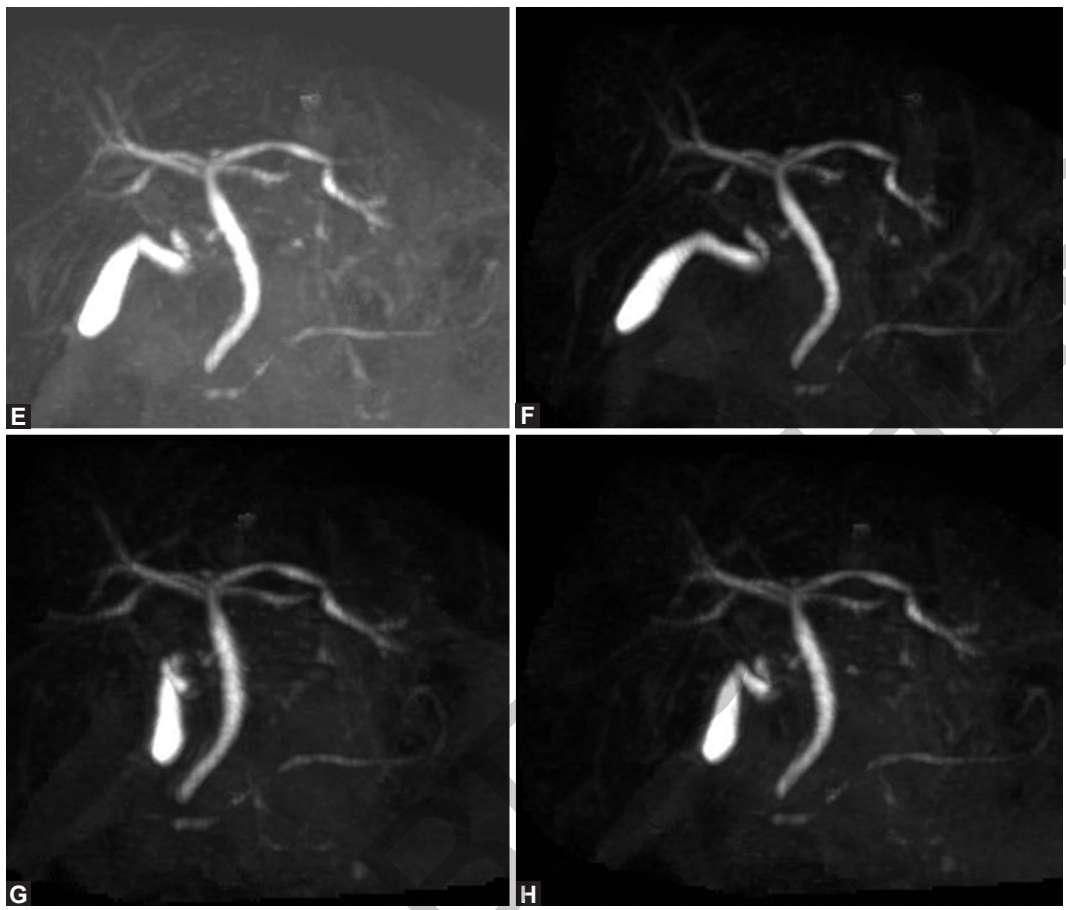

Figs 19E to H
Figs 18 and 19A to H 3D MRCP maximum intensity projection images

and cases with high morbidity (iii) cholangitis (iv) acute pancreatitis.

Patient preparation: No special patient preparation is required for MRCP but fasting 2–3 hours prior to the examination helps to reduce the fluid in gastric pyloric region and duodenum, which may overlap with the common bile duct.

Clinical conditions diagnosed by MRCP are (i) bile duct obstruction can be diagnosed and the level of obstruction determined by MRCP (ii) biliary calculi 6 mm and above can be visualized (iii) multiple irregular strictures involving the bile duct can be diagnosed (iv) benign and malignant strictures can be differentiated (v) MRCP is useful in diagnosing cholangiocarcinoma (vi) postoperative bile duct leaks can be assessed (vii) post liver transplant MRCP provides information about the hepatobiliary system (viii) in evaluating parenchymal abnormalities in developmental anomalies of pancreas, in acute pancreatitis and pancreatic neoplasms MRCP has been valuable.

Advantages of MRCP: (i) It is a noninvasive radiological technique (ii) no ionizing radiation is used (iii) high soft tissue resolution of the hepatobiliary system can be obtained (iv) use of intravenous contrast can enable the anatomical and functional aspect of the hepatobiliary system to be evaluated (v) allergic reaction to contrast is less likely in MRCP (vi) less complications post procedure as compared to ERCP (vii) MRCP has been proven to be invaluable radiological technique to detect early hepatobiliary cancers and follow-up post-surgery (Table 2).

Some risks involved in procedure: (i) some patients might be allergic to the gadolinium contrast (ii) nephrogenic systemic fibrosis may occur with use of intravenous contrast in patients with poorly functioning kidneys (iii) some patients might require sedation for this procedure and the risks of short anesthesia are to be kept in mind (iv) metallic and electronic implants are hazards to the patient as they can dislodge or malfunction under the magnetic field, these implants might interfere with the magnetic field to produce artifacts.

JAYPEE BROTHERS

Table 1 MRCP imaging techniques

2D MRCP 21 second breath hold technique for cooperative patients
2D MRCP 15 second breath hold technique for uncooperative patients
2D MRCP T2W single shot fast spin echo sequences (FSE)
2D MRCP breath hold T1W dual echo spoiled gradient recalled echo
2D MRCP respiratory triggered fat suppressed T2W fast spin echo sequences (FSE)
2D MRCP rapid acquisition with relaxation enhancement (RARE) + fast spin echo sequences (FSE)
2D MRCP Half–Fourier RARE sequences
2D MRCP chemical-shift-selective fat suppression with fast spin echo sequences (FSE)
3D fast recovery FSE MRCP
3D spoiled gradient recalled echo + Intravenous gadolinium
Breath-hold 3D MRCP with segmented echo-planar imaging , volume rendered sequence

MRCP Imaging Sequences

Magnetic resonance cholangiopancreatography (MRCP) provides precise diagnostic accuracy to evaluate biliary disease, especially for calculi measuring >4 mm in size, biliary strictures and dilated intrahepatic biliary radicles. MRCP is useful in planning of interventional procedures or understanding of complex relationships between pathologic and normal duct anatomy. The MRCP examination is done ideally on a 1.5 Tesla or higher system.

With long effective echo times, only fluid–filled compartments are observed with nearly complete background suppression and minimal sensitivity to motion and signal loss due to magnetic susceptibility. Patient cooperation is very important for MRCP sequences as respiratory motion can blur the MRCP images. Ghosting and blurring could be noted with fluids affected by peristalsis and heart pulsation. Ghosting from pulsation of cerebrospinal fluid could be suppressed by means of a presaturation band over the spinal canal. Slow moving blood do not interfere with image quality as the signal from fluid was higher.

MRCP Imaging Techniques (Table 1)

MR sequences T2W single shot FSE, breath hold T1W dual echo spoiled gradient recalled echo, respiratory triggered fat suppressed T2W FSE, 3D fast recovery FSE MRCP, 3D spoiled gradient recalled echo prior to and following Intravenous gadolinium contrast.

Breath-hold imaging requires patient cooperation. For 2D MRCP end–expiration 21 second breath hold technique are used commonly with segmental echoplanar imaging. In some instances the patient might be not be cooperative and short breath-hold time (15 seconds) for two-dimensional MRCP can used to give equivocal results. In those patients with a thin body habitus, major hepatobiliary pathology can be visualized with the use of short breath holds of 15 seconds each and a magnetization recovery interval period of 1 second.

Rapid acquisition with relaxation enhancement (RARE) and fast spin echo sequences are used for MRCP. Also Half–Fourier RARE sequences can be used. By combining 3D fast SE and segmented echo-planar imaging the SNR (signal to noise ratio) is increased with improved resolution in shorter imaging time. This is equivalent to an increase in data density to obtain breath hold volume images of the entire hepatic, bile and pancreatic ducts in 3D acquisitions.

The use of echo-planar imaging makes the image sensitive to geometric distortions and signal loss from susceptibility effects between air-tissue interfaces and metallic implants. These geometric distortions and signal loss can be reduced by the use of small voxels and bandwidths with large frequency–encoding gradients.

Chemical-shift-selective fat suppression is currently applied in fast SE–based MRCP techniques, with short and long effective echo times, to increase the contrast between fluids and surrounding fat or to suppress edge artifacts and ghosting that may arise from fat near the receiver coils. The combination of chemical-shift fat suppression and echo-planar imaging requires the use of local shimming to obtain high quality 2D MRCP images.

Prior to the 3D MRCP sequence a routine MRI abdomen scan using T1W and T2W sequences is obtained. During the 3D MRCP, the patient is positioned in supine position on the MRI table. Body phased-array coils are placed over the liver to give high resolution images. To increase the magnetic field homogeneity nonselective shimming is used. Presaturation bands are placed above and below the imaging volume to suppress the signal from the incoming blood and structures outside the area of interest. Bile fluid ghosting seen in the phase-encoding direction of MRI sequences in coronal and axial planes indicate improper breath holding technique and repeat MRCP sequence is needed. If the cystic duct,

JAYPEE BROTHERS

Table 2 Comparison between MRCP and conventional ERCP

MRCP (Magnetic resonance cholangiopancreatography)	*Conventional ERCP (Endoscopic retrograde cholangiopancreatography)*
Noninvasive imaging study, no use of ionizing radiation to study the hepatobiliary system	Invasive surgical procedure to study the hepatobiliary system
3D MRCP and 2D RARE MRCP sequences with 512 matrix acquisitions provide high resolution images of the entire hepatobiliary system. Volume rendered images helps to visualize the confluence of bile ducts, obstruction caused by stones and stenotic segments	ERCP provides good spatial resolution of hepatobiliary system. Stent placement of narrowed segments can be undertaken, small stones in ducts can be relieved
Biopsies not possible on MRCP as its purpose is to gather high quality images of hepatobiliary system, however, it can be useful to guide biopsies.	Biopsies are possible at the time of examination under direct visualization
Metallic implants are prohibited for patients undergoing MRCP examination.	Metallic implants do not impede the ERCP examination
Nil per orally 3–4 hours prior to the MRCP helps to reduce artifacts from adjacent small bowel and stomach	Nil per orally 6 to 8 hours before the ERCP procedure required
In high-risk groups like complicated geriatric cases and pediatric age groups MRCP is preferable	ERCP is not generally preferred in pediatric age groups and complicated geriatric cases
No post procedure complication, as MRCP is non-invasive	ERCP is invasive so complications like bowel or duct perforation with pneumobilia can occur.
MRCP can be cost-effective diagnostic procedure	ERCP is relatively expensive procedure
Not all hospitals have 1.5 Tesla system for MRCP exams	ERCP is available in most surgical units
Other abdominal pathology can be detected during 2D MRCP examination as cross-sectional imaging is multiplanar	ERCP is limited to the hepatobiliary system

common hepatic duct and pancreatic ducts show atleast 2 mm or more in diameter, the images are considered to be useful for 3D MRCP.

Images in several projections and section thicknesses are obtained from the 3D MRCP data by using maximum intensity projection and volume rendering. Volume rendering is applied to improve data visualization and interpreting the images. Bright structures surrounding the liver and pancreas such as fluid in the gastrointestinal tract, genitourinary tract are segmented before volume rendering. To reduce overlap between structures on 3D images, structure segmenting is done which edits the overlapped structures by identifying a starting point and connecting similar voxels in a signal intensity range, the resulting 3D image has no overlapping of signals from unwanted structures. A 3D acquisition introduces an improvement in SNR proportional to the square root of the number of sections acquired. Fast SE images can have large specific absorption ratios and produce large heat power deposition. The specific absorption ratio is reduced in 3D MRCP with use of fewer refocusing 180° RF pulses with increased spacing.

Breath-hold 3D MRCP with segmented echo-planar imaging can deliver fast imaging of the bile duct system. Volume rendered images enables the radiologist to view the data in multiple planes.

MRCP Versus Conventional ERCP (Table 2)

Conditions in which MRCP is more useful than ERCP include: 1. Obstructive lesions of stomach and esophagus 2. Previous hepatojejunostomy and 3. Gastrojejunostomy

Pitfalls

1. The entire biliary tree and pancreatic duct often are not shown on a single MRCP image. A specific ductal segment may not be depicted, resulting in nonvisualization of a stone or stricture.
2. MRCP provides less spatial resolution than does ERCP, thereby limiting its ability to detect early peripheral duct abnormalities, and cannot always distinguish benign from malignant disease.
3. MRCP shows static changes and any physiological narrowing can mimic disease.

JAYPEE BROTHERS

for detailed information on radiology books, visit our website **www.jaypeebrothers.com,** for detailed information on radiology

Atlas of
Human Anatomy on MRI
Brain, Chest & Abdomen

Salient Features

- Helps to understand the complex MR anatomy in a simple, effortless and straightforward manner
- Offers systemic approach to comprehend MRI anatomy with meticulously labeled illustrations and text, to leave a lasting impression on the readers
- It is steal a look into MRI anatomy in an easy and understandable manner
- It is meant for undergraduates and postgraduates alike, residents in radiology, radiologists, surgeons, general practitioners and other specialists, MRI technical staff and for medical colleges, institutional and departmental libraries, and for standalone MRI establishments.

Hariqbal Singh is the Dean and Professor, Prakash Institute of Medical Sciences and Research, Urun Islampur, Sangli, Maharashtra, India. He has over 37 years of experience in medical practice. He has technical expertise as radiologist in managing resources for the use of imaging technologies with proficient high diagnostic capability, skillful in administration of personnel and resources of large medical institutions. He is an effective communicator with strong analytical, problem-solving and organizational abilities. He has been a postgraduate teacher, examiner and postgraduate guide since 1989 with Pune University; Maharashtra University of Health Sciences, Nashik; Sumandeep University, Vadodara; Maharaja Krishnakumarsinhji Bhavnagar University, Bhavnagar, Gujarat; and Diplomate National Board. He has over 85 publications in national and global medical journals with large number of books on radiology, to his credit.



Parvez Sheik is an enthusiastic and ardent radiologist and a keen observer. He has also been co-author of several imaging books with Dr Hariqbal Singh.



Available at all medical bookstores
or buy online at www.jaypeebrothers.com

JAYPEE BROTHERS
Medical Publishers (P) Ltd.
www.jaypeebrothers.com

Join us on facebook.com/JaypeeMedicalPublishers

Shelving Recommendation
RADIOLOGY

ISBN 978-93-86322-52-4