phthalmology books, visit our website **www.jaypeebrothers.com,** for detailed information on ophthalmology books

OPHTHALMOLOGY

VOLUME 13

Recent Advances in OPHTHALMOLOGY

Editors
HV Nema
Nitin Nema

JAYPEE

Contents

1. SMILE vs LASIK **1**

Jorge L Aliö, Mohamed El Bahrawy

- Recent Evolution of Laser Refractive Surgery of the Cornea *1*

2. Herpetic Eye Disease **11**

Charmaine Chai, Manotosh Ray

- Epidemiology *11*
- Etiology *12*
- Clinical Presentation *12*
- Risk Factors *14*
- Complications *16*
- Management *16*

3. Recent Advances in Management of Ocular Surface Disorders **24**

Jayesh Vazirani, Virender Sangwan, Govinda Jha

4. Intraocular Tuberculosis **32**

Arshee Ahmed, B Sowkath Ali, Jyotirmay Biswas

- Epidemiology *32*
- Pathogenesis *32*
- Management *42*

5. Ocular Sarcoidosis **45**

Eliza Anthony, Parthopratim Dutta Majumder, Jyotirmay Biswas

- Epidemiology *45*
- Etiology *45*
- Clinical Features *46*
- Diagnosis *49*
- Treatment *53*

6. Advances in Intravitreal Therapeutics in Uveitis **56**

Parthopratim Dutta Majumder, Jyotirmay Biswas

7. Current Role of Imaging in Glaucoma Management **65**

Malarchelvi Palani, Sangeetha Rajagopal,
Nivean Madhivanan, Murali Ariga

- Scanning Laser Polarimetry *65*
- Confocal Scanning Laser Ophthalmoscope *69*

- Heidelberg Retinal Tomography III *72*
- Optical Coherence Tomography *73*
- Scanning Laser Polarimetry *81*
- Confocal Scanning Laser Ophthalmoscope *82*
- Optical Coherence Tomography *85*
- Future Developments in Glaucoma Imaging *93*

8. Postoperative Endophthalmitis **99**

Lalit Verma, Arindam Chakravarti

- Bacterial Endophthalmitis *100*
- Fungal Endophthalmitis *108*
- Chronic Endophthalmitis *109*
- Prevention and Prophylaxis *112*
- Newer Intravitreal Antibiotics *113*
- What to Do, in Case of Infection? *114*
- What to Do in Cluster Infections or Outbreak? *114*
- Legal Issues Related to Endophthalmitis *115*

9. Toxic Anterior Segment Syndrome **117**

Kamaljeet Singh, Arshi Misbah

- Epidemiology *117*
- Etiology *118*
- Clinical Features *119*
- Prevention *122*
- Treatment *122*
- Clinical Outcome and Prognosis *122*

10. Control of Infection in Ocular Surgery **125**

Vaibhavi Subhedar

- Progress in Intraocular Cataract Surgery *125*
- Epidemiology of Postoperative Endophthalmitis *126*
- Risk Factors for Endophthalmitis *127*
- Pathogens *128*
- Prophylaxis *129*
- Policy *133*

11. Diabetic Macular Edema **139**

Neha Mohan, Chetan Videkar, Umesh C Behera, Krushna Gopal Panda, TP Das

- Risk Factors *139*
- Pathogenesis *139*
- Classification *141*
- Symptoms and Signs *145*
- Treatment *146*
- Surgery: Vitrectomy *155*

12. New Frontiers in the Treatment of AMD **160**
Suresh R Chandra, Amol D Kulkarni
- Emerging Therapeutic Options in Dry AMD *161*
- Emerging Therapeutic Options in Wet AMD *165*

13. Polypoidal Choroidal Vasculopathy **170**
Lingam Gopal, Mayuri Bhargava, Su Xinyi
- Demographics *170*
- Clinical Presentation *170*
- Management *174*

14. Macular Phototoxicity **185**
Dhananjay Shukla

15. Retinoblastoma **193**
Fairooz P Manjandavida, Santosh G Honavar
- Genetics *193*
- Classification and Staging *194*
- Clinical Features *195*
- Diagnosis *196*
- Management *197*

16. Endovascular Interventions in Ophthalmic Disorders **206**
Hima Pendharkar
- Case 1: Idiopathic Intracranial Hypertension *208*
- Case 2: Intracranial Dural Arteriovenous Fistula *212*
- Case 3: Cavernous Internal Carotid Artery Aneurysms *215*
- Case 4: Carotid Cavernous Fistula *218*
- Case 5: Posterior Communicating Artery Aneurysm *223*
- Case 6: Occipital Arteriovenous Malformation *224*

17. Nystagmus **230**
Mihir Kothari
- Management *244*

18. Cystinosis **255**
Shefali Vyas
- Clinical Manifestations *256*
- Extrarenal Manifestations *256*
- Pathogenesis *257*
- Diagnosis and Management *258*
- Treatment *259*

19. Behçet's Disease **261**
Upender Wali
- Historical Aspect *261*

- Nonocular Manifestations *264*
- Ocular Manifestations of Behçet's Disease *267*
- Behçet's Disease in Children *273*
- Behçet's Disease in Pregnancy *274*
- Ancillary Tests *277*
- Differential Diagnosis in Behçet's Disease *278*
- Treatment *279*
- Prognosis for Vision in Behçet's Disease *282*

Index *289*

Chapter 4

Intraocular Tuberculosis

Arshee Ahmed, B Sowkath Ali, Jyotirmay Biswas

JAYPEE BROTHER

INTRODUCTION

Intraocular tuberculosis (IOTB) is a form of extra-pulmonary tuberculosis, which is caused by the bacillus *Mycobacterium tuberculosis* (Mtb). It is noteworthy that a single organism produces such varied clinical features in a single organ and also that it is rarely isolated from samples which make a definitive diagnosis of this disease elusive in most of the cases.

EPIDEMIOLOGY

According to the WHO Global Tuberculosis Report 2015,[1] out of the 9.6 million new tuberculosis cases in 2014, 58% were in the South-East Asia region and Western Pacific regions. India, Indonesia and China had the largest number of cases (23,10% and 10% of the global total respectively). The WHO has now moved from STOP-TB Strategy (2006–2015) to END-TB Strategy (2016–2035) and aims to attain a world free of TB. India's TB control program is on track as far as reduction in disease burden is concerned. There was 50% reduction in mortality rate by 2013 as compared to 1990 levels. Similarly, there was also a 55% reduction in TB prevalence rate compared to 1990 levels.[2]

PATHOGENESIS

Mycobacterium tuberculosis is an obligate, aerobic, non-motile, non-spore-bearing, slow-growing bacterium. Human beings are the only natural host for this organism. It spreads via inhalation of aerosolized droplets when infected patients cough or sneeze. It usually affects organs with high regional oxygen content like the apices of the lungs, kidneys, bones, meninges and the choroid. The choroid is known to have one of the highest blood flow rates in the human body.

IOTB has been postulated to have pathogenetic mechanisms similar to other forms of extrapulmonary TB. These include the following stages:

1. Bacterial dissemination
   Mycobacterium tuberculosis is engulfed by alveolar macrophages and transported to hilar lymph nodes leading to priming of T cells. Macrophages/dendritic cells carrying *Mycobacterium tuberculosis* or even free bacteria may disseminate to different parts of the eye.
2. Localization in ocular tissues
   Amongst various ocular tissues wherein the bacilli gets lodged, RPE is most suited among different cell types to harbor *Mycobacterium tuberculosis*

3. Bacterial reactivation and initiation of inflammation
   Mycobacterium tuberculosis can remain latent for long periods of time. What factors can lead to reactivation is not known.

Tuberculosis and Uveitis

In patients with latent TB, antigenic mimicry between tubercular and retinal antigens could be a potential cause of uveitis. This hypothesis is supported by cytokine analysis of TB-associated uveitis that showed significantly increased interleukin-6 (IL-6) and other chemokines, but not IL-12, tumor necrosis factor-α (TNF-α) and interferon-γ (IFN-γ) that characterize active TB.[3]

Clinical Features

Ocular manifestations of tuberculosis are shown below (Fig. 4.1).

1. Anterior uveitis
   - Unilateral or bilateral
   - Usually granulomatous; can be non-granulomatous
   - Cornea- mutton fat keratic precipitates
   - AC–cells, flare, fibrinoid reaction
   - Iris nodules (Fig. 4.2) angle nodules
   - Posterior synechiae, peripheral anterior synechiae
   - Complicated cataract
   - Ciliary body granulomata.
2. Intermediate uveitis
   - Low grade, chronic uveitis
   - Vitritis
   - Snowball opacities
   - Snow banking
   - Peripheral vascular sheathing
   - Peripheral retinochoroidal granuloma.
3. Posterior uveitis
   - Choroidal tubercles
     – Unilateral or bilateral

JAYPEE BROTHER

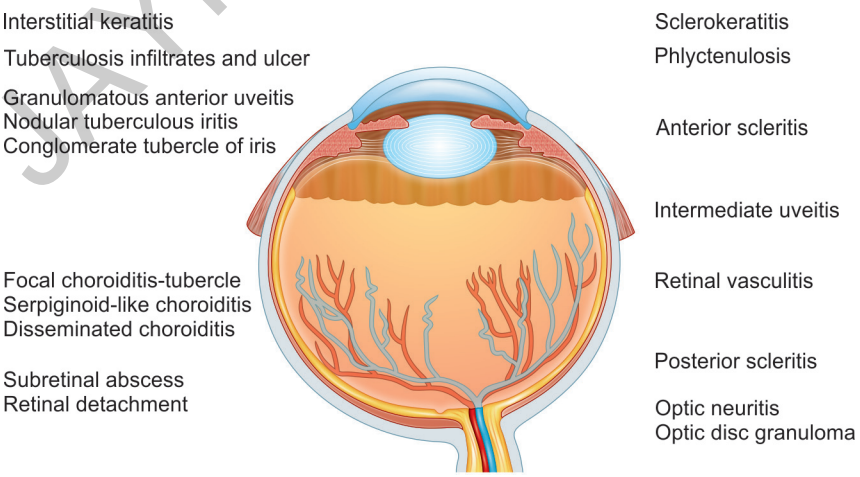

Fig. 4.1: Various anterior and posterior segment manifestations of tuberculosis

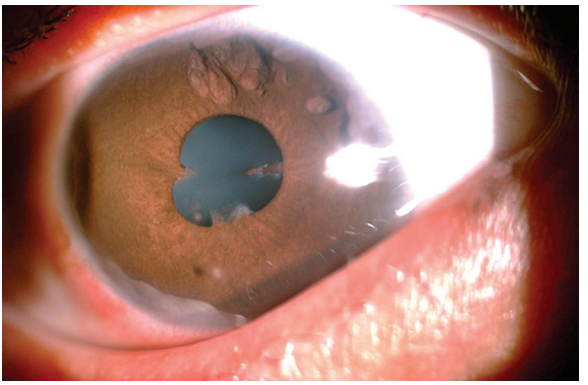

Fig. 4.2: A 21-year-old female patient with tubercular anterior uveitis showing mutton fat keratic precipitates, iris nodules, broad posterior synechiae and peripheral anterior synechiae

  - Tubercles measure between 0.5–3 mm in diameter
  - Overlying serous retinal detachment
  - Respond well to ATT
  - Heal leaving behind pale atrophic areas with variable pigmentation.
- Tuberculoma
  - Large, solitary mass
  - Upto 14 mm in diameter (Figs 4.3A and B)
  - Overlying hemorrhages, retinal folds, serous retinal detachment
  - Respond well to ATT and corticosteroids.
- Serpiginous-like choroiditis
  - Important to differentiate it from serpiginoid choroiditis
  - Chronic inflammation of the retinal pigment epithelium, choriocapillaries

JAYPEE BROTHER



Figs 4.3A and B: A patient who was a known case of spinal tuberculosis presented with blurred vision in the left eye. (A) Fundus photograph of the left eye showing tubercular granuloma involving the macula; (B) MRI scan of the spine showing heterogenous, hyperintense signals from L1-L2 vertebrae with loss of intervening inter-vertebral disc morphology

  - Immune-mediated hypersensitivity reaction in the presence of a few acid-fast bacteria in the choroid or retinal pigment epithelium
  - Seen in TB-endemic countries
  - Significant vitritis
  - Presence of multifocal lesions in posterior pole, juxtapapillary region —gray-white lesions with ill-defined edges, spread centrifugally with multiple recurrences
  - FFA shows early hypofluorescence and late hyperfluorescence
  - Responds well to combination of ATT and corticosteroids
  - Can show paradoxical worsening when treatment is initiated with ATT.[4]
- Subretinal abscess
  - Solitary, yellowish-white, circumscribed mass-like subretinal lesion
  - Often associated with overlying retinal hemorrhages
  - Vitritis
  - Can be diagnosed with the help of aqueous or vitreous samples subjected to PCR, microbial evaluation including smear, culture
  - Treatment must include ATT along with corticosteroids as this lesion responds very well to ATT.[5]
- Retinal vasculitis
  - Cause remains speculative; infective or hypersensitivity response to tubercular antigens
  - Predominantly venular involvement; occlusive vasculitis
  - Vitreous infiltrates (vitritis)
  - Retinal hemorrhages (Figs 4.4A and B)
  - Neovascularization leading to recurrent vitreous hemorrhage
  - Tractional retinal detachment
  - Neuroretinitis
  - Treatment with ATT, corticosteroids, and panretinal photocoagulation to the capillary non-perfusion areas as determined on FFA.
- Eales' disease: An idiopathic vasculitis; affects healthy adults, mostly men, in third to fourth decade of life, characterized by periphlebitis, capillary nonperfusion, neovascularization, recurrent vitreous hemorrhages, and fibrovascular proliferation. Absence of intraocular inflammation and

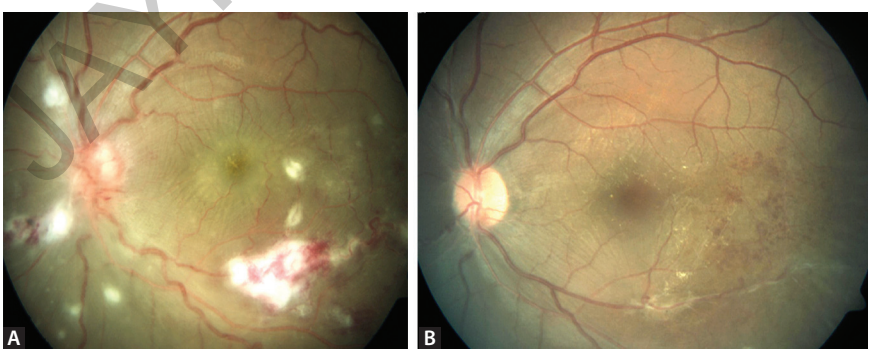

Figs 4.4A and B: Patient with tubercular retinal vasculitis, tested positive on Mantoux test and QuantiFERON TB Gold test with positive findings on HRCT-Chest. (A) Pretreatment fundus photograph of the left eye showing disc edema, cotton wool spots, hemorrhages, ILM folds; (B) Post-treatment with ATT and corticosteroids, vasculitis resolved leaving behind sheathing of the infer-temporal arcade vessel

JAYPEE BROTHER

absence of healed or active choroiditis lesions are important differentiating features from tuberculosis vasculitis. Biswas et al.[6] detected the *Mycobacterium tuberculosis* genome by PCR detection in a significant number of vitreous fluid specimens with Eales' disease, thus suggesting a possible association of *Mycobacterium tuberculosis* in the pathogenesis of Eales' disease.

- Optic nerve involvement
  - Contiguous spread from choroid or hematogenous spread from the primary focus
  - Optic neuritis, ONH granuloma/tubercle, retrobulbar neuritis, neuroretinitis, opticochiasmatic arachnoiditis.
- Endophthalmitis and panophthalmitis
  - Patients with subretinal abscesses can develop endophthalmitis due to treatment with corticosteroids without ATT because of rapid multiplication of bacilli along with liquefaction necrosis.
  - Scleral involvement can lead to panophthalmitis ending in globe perforation.

Pathology

Various ocular structures have been noted to be involved in specimens obtained from enucleated eyes like sclera, cornea, conjunctiva, iris, ciliary body, vitreous adjacent to pars plana ciliaris, retina and choroid.

The histopathology of ocular involvement characteristically reveals granulomatous inflammation with central caseous necrosis, and shows occasional acid-fast organisms. The granulomatous response consists of abundant epithelioid, histiocytes, occasional giant cells of langhans type, and peripheral mononuclear cells, primarily made up of lymphocytes.[3]

The disease should be differentiated from syphilis, leprosy, sarcoidosis, tumors, etc. (Table 4.1).

Diagnostic Techniques (Table 4.2)

- Immunologic
  - Tuberculin skin test (Mantoux test, PPD test)
  - Interferon-g release assays (QuantiFERON-TB GOLD or T-SPOT TB)
- Radiologic
  - Chest X-ray
  - Chest computer-assisted tomography
  - Positron emission tomography PET/CT.

TABLE 4.1: Showing differential diagnosis of tuberculosis

Infectious	Noninfectious	Neoplasia
Syphilis	Sarcoidosis	Retinoblastoma
Leprosy	Serpiginous choroiditis	Malignant melanoma
Toxoplasmosis	Sympathetic ophthalmia	Lymphoma
Histoplasmosis	Vogt–Koyanagi–Harada disease	Metastatic tumor
Borreliosis	Acute posterior multifocal placoid	
Brucellosis	pigment epitheliopathy	
Herpetic retinochoroiditis	Punctate inner choroidopathy	
	Multifocal choroiditis and panuveitis	

JAYPEE BROTHER

TABLE 4.2: Diagnostic modalities for intraocular tuberculosis

Type		Principle	Advantages	Disadvantages
Immunologic	Tuberculin skin test (Mantoux test)	Skin hypersensitivity test for mycobacterial antigens	Low cost Wide availability Larger induration-more specific	Not specific Does not distinguish between latent and active TB May be positive with BCG vaccination/exposure to atypical mycobacteria Maybe negative in immunosuppressed states/children/extrapulmonary or military TB difficulties in test administration and interpretation may lead to false results
	Interferon-γ release assays (QFT-G, T-SPOT TB)	Interferon-γ release test after in vitro stimulation of patients' lymphocytes with *M. tuberculosis* specific antigens	More specific marker of *M. tuberculosis* infection/previous exposure Not influenced by BCG vaccination or exposure to atypical mycobacteria Not as subject to biases and errors of placement and reading as the TST	Higher cost Not widely available Possibly more sensitive to detect latent infection than TST but does not distinguish it from disease May be negative or indeterminate in immunosuppressed states Problems in collecting or transporting blood specimen may decrease the accuracy
Radiologic	Chest X-ray	Look for evidence of pulmonary involvement, either active or healed infection	Low cost and wide availability Useful when a suggestive pattern is found (e.g. upper lobe infiltrates and cavitation, Ghon's focus, miliary disease)	Not specific for tuberculosis Other infectious/granulomatous/lymphoproliferative/occupational disorders may lead to similar patterns Low sensitivity, especially for detection of lymphadenopathy A normal result does not exclude ocular tuberculosis
	CT scan of chest	Look for evidence of pulmonary involvement, either active or healed (postinflammatory)	More sensitive than chest radiograph Modality of choice for detection of lymphadenopathy and for tuberculomas	Higher cost and greater radiation exposure than chest X-ray Not specific for tuberculosis A normal result does not exclude ocular tuberculosis
	PET-CT scan			

Contd...

TYPE PROOF

Contd...

Bacteriologic	Smear	Identify the presence of stained acid-fast bacilli in various clinical samples	Rapid and widely-available method Useful especially in specimens with large bacillary load	Low sensitivity (e.g. for sputum, detection threshold is >5,000 bacilli/mL) Other acid-fast organisms are also identified through this method
	Culture	Detects growth of *M. tuberculosis* after seeding of clinical samples in culture media	Gold standard. Unequivocal proof of microorganism viability Allows identification and drug sensitivity testing	Expensive and cumbersome needs long time for growth May not be widely available Results may take up to 6–8 weeks in solid media
Molecular	Nucleic acid amplification tests	Detects presence of *M. tuberculosis* genomic DNA in clinical samples after amplification (e.g. various PCR techniques)	High specificity Better sensitivity than microscopy Fast results Allows identification and investigation of genetic resistance patterns	Higher cost and limited availability. Variable sensitivity Inferior sensitivity for non-respiratory specimens (not established for ocular samples). Does not allow ruling out tuberculous etiology Detects only DNA (more prone to contamination and microorganisms may not be viable or may be dormant)
	LAMP	Based on the novel loop-mediated isothermal amplification (LAMP) platform; for detection of *Mycobacterium tuberculosis* complex, *Mycobacterium avium*, and *Mycobacterium intracellulare*	Fast, easy operation without sophisticated equipment, results visible to naked eye, robust to inhibitors and reaction conditions that usually adversely affect PCR results, simple enough to use in small-scale hospitals, primary care facilities, and clinical laboratories in developing countries	
Histologic	Histopathology	Stained tissue sections with evidence of granulomatous inflammation (especially with caseous necrosis) support the diagnosis. Finding of AFB in this setting is diagnostic	Allows the observation of the extent of tissue damage	Risks related to invasive procedure to obtain tissue specimen Other microrganisms/noninfectious entities may also lead to granulomatous inflammation Low sensitivity for AFB detection

Source: Daniel V. Vasconcelos-Santos, Manfred Zierhut, Narsing A Rao. Strengths and Weaknesses of Diagnostic Tools for Tuberculous Uveitis, Ocular Immunology and Inflammation. 2009;17(5):351-355.[7]

JAYPEE BROTHER

- Bacteriologic
  - Smear
  - Culture.
- Molecular
  - Nucleic acid amplification tests.
- Histologic
  - Histopathology.

Ancillary Investigations

- ***Fundus Fluorescein Angiography (FFA):*** It is a very useful technique to study the various presentations of IOTB including Tb-serpiginous-like choroiditis, tubercles, tuberculomas, retinal vasculitis and inflammatory choroidal neovascular membranes. Active choroiditis lesions demonstrate hypofluorescence in early phases with hyperfluorescence in the late phases. Serpiginous-like choroiditis, shows an initial hypofluorescent active edge with late hyperfluorescence and diffuse staining of the active advancing edge. In cases of vasculitis, the presence of areas of capillary non-perfusion and neovascularization can be picked up on FFA determining the need and extent of panretinal photocoagulation. Inflammatory CNVM can be diagnosed by the classical appearance of early lacy hyperfluorescence and intense leak with fuzziness of borders in late stages.
- ***Indocyanine Green Angiography (ICG):*** This angiography is useful in determining the extent of the choroidal lesion and the stage of disease and in evaluating treatment results. Herbort et al.[8] suggested that hypofluorescent lesions seen in all phases of ICGA represent full-thickness choroidal granulomas or atrophic lesions. ICGA changes are reversible and therefore, help in monitoring the disease.
- ***Wide-field Imaging (WFI):*** It is especially useful in cases with vasculitis involving the peripheral vessels, usually veins in patients with Eales' disease. Standard field FFA can miss the abnormalities in the peripheral retina. But with WFI, capillary non-perfusion areas in the periphery can be picked up earlier, preventing complications like neovascularization and bleeding.
- ***Fundus Autofluorescence (FAF):*** It is a novel, non-invasive technique which can help in differentiating active from inactive choroiditis. Gupta A and Biswas J[9] described the serial FAF pattern of serpiginous choroiditis and reported that in the initial phases the lesion appears hyperfluorescent. Sharpening of the hyper-autofluorescent borders indicated healing of the lesions. Completely healed lesions showed hypo or absence of fluorescence (Figs 4.5A and B).
- ***Optical Coherence Tomography:*** OCT It helps in the assessment of macular complications like cystoid macular edema and inflammatory CNVM in these cases. Also, entities that may mimic tubercles like CSCR and choroidal tumors can be excluded.

  Enhanced-depth imaging-OCT (EDI) of active Tb-SLC lesions demonstrated infiltration of the choroid, elevation of the RPE-Bruch's membrane complex and focal increase of choroidal thickness.[10] These findings are not seen in non-infectious SC and can help in differentiating between the two entities.
- ***Ultrasound (USG):*** It is a helpful tool in diagnosis and follow-up of choroidal mass lesions like subretinal abscess, which characteristically show an anechoic space within the mass on A-scan. Tuberculomas can be

JAYPEE BROTHERS

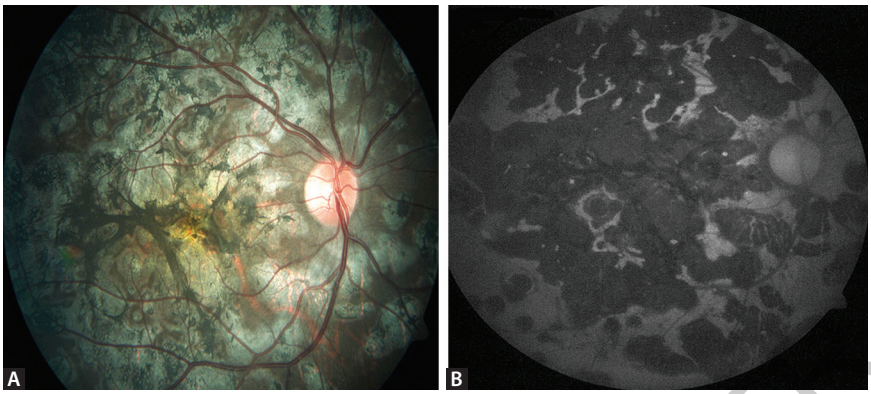

Figs 4.5A and B: A 22-year-old male patient with positve QuantiFERON TB- Gold test presented with features of (A) Healed multifocal choroiditis; (B) Fundus autofluorescence shows complete absence of autofluorescence indicating healed lesions

differentiated from malignancies like retinoblastomas, malignant melanomas and metastatic tumors.

- ***Ultrasound Biomicroscopy (UBM):*** It is a useful tool to study eyes with hypotony in patients with chronic uveitis and poor media clarity to assess the pars plana region. It can also pick up granulomas in this region.
- ***Fine Needle Aspiration Cytology (FNAC):*** Samples can be taken for histopathology or for techniques like PCR in cases, which present with diagnostic dilemmas.

Challenges in Diagnosis

The diagnosis of IOTB remains a challenging issue because each of the tests available has its strengths and weaknesses as discussed above and because TB infection can present with features of any type of extraocular or intraocular inflammation. Gupta A et al.[11] have proposed the classification of IOTB (Table 4.3) comprising of confirmed IOTB, probable IOTB and possible IOTB. These guidelines offer a greater degree of "certainty" of diagnosis as IOTB largely remains a presumptive diagnosis, as unequivocal evidence of infection is often not available. There are some signs which are consistent with intraocular tuberculosis; they are:

Presence of cells in anterior chamber or vitreous along with:

1. Broad posterior synechiae
2. Retinal perivasculitis with or without discrete choroiditis/scar
3. Multifocal serpiginoid choroiditis
4. Choroidal granuloma
5. Optic disc granuloma
6. Optic neuropathy.

Approach for the diagnosis of tuberculous uveitis in immunocompetent individuals[12] is shown in a flow chart below.

Showing diagnosis of tuberculous uveitis in immunocompetent individuals (Flowchart 4.1).[12]

JAYPEE BROTHERS

TABLE 4.3: The proposed classification of intraocular tuberculosis

Clinical diagnostic group	Case definition criteria
Confirmed IOTB (Both 1 and 2)	1. At least one clinical sign suggestive of IOTB 2. Microbiological confirmation of MTB from ocular fluids/tissues
Probable IOTB (1,2, and 3 together)	1. At least one clinical sign suggestive of IOTB (and other etiologies excluded) 2. Evidence of chest X-ray consistent with TB infection or clinical evidence of extraocular TB or microbiological confirmation from sputum or EO sites 3. At least one of the following: a. Documented exposure to TB b. Immunological evidence TB infection
Possible IOTB (1,2, and 3 together) OR (1 and 4)	1. At least one clinical sign suggestive of IOTB (and other etiologies excluded) 2. Chest X-ray not consistent with TB infection and no clinical evidence of EOTB 3. At least one of the following: a. Documented exposure to TB b. Immunological evidence TB infection 4. Evidence of chest X-ray consistent with TB infection or clinical evidence of EO TB but none of the characteristics given in 3

Flowchart 4.1: Uveitis in immunocompetent patient

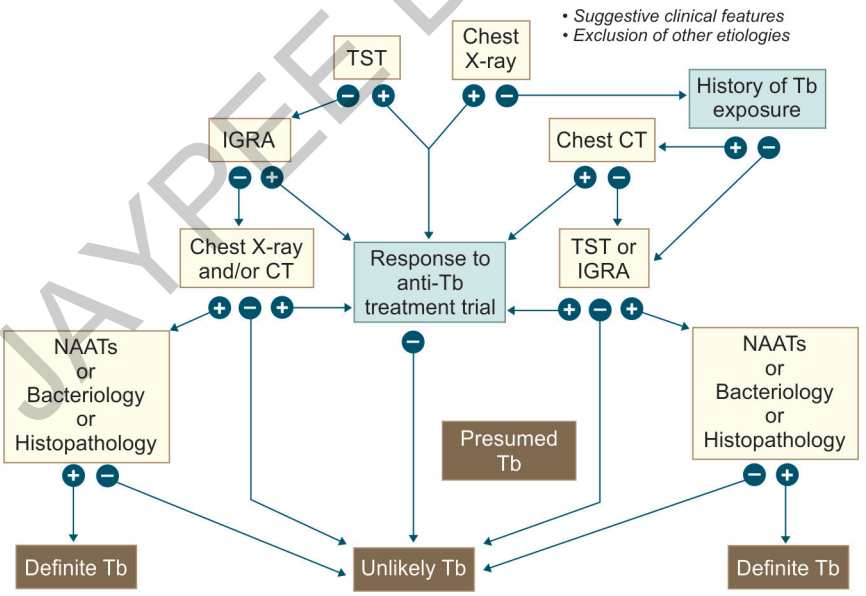

Abbreviations: TST, tuberculin skin test; IGRA, interferon-gamma release assay; CT, computer-assisted tomography; TB, tuberculosis. Anti-TB treatment for 8 weeks; presumed and definite TB require treatment for 6 months

Source: Ang, et al. Diagnosis of Ocular Tuberculosis. Ocular Immunol Inflamm. 2016;5:1-9.

JAYPEE BROTHER

MANAGEMENT

Tuberculosis is a readily curable disease with highly effective treatment. The management of ocular TB includes medical management of the disease on the same lines as other forms of extrapulmonary TB and surgical management to treat complications developing due to chronic ocular disease.

Medical Management

Anti-tubercular therapy has been known to eliminate latent TB and decreases a person's lifetime risk of developing active TB by 90%.[13]

Majority of patients with uveitis secondary to presumed Tb have underlying latent TB so treatment with timely ATT helps in reducing recurrences. In a study by Bansal et al.[14] the addition of ATT significantly improved the 5-year probability of no recurrence of inflammation in their cohort.

Treatment is instituted in two distinct phases—the first intensive phase involves the use of 4 drugs—isoniazid, rifampicin, pyrazinamide and ethambutol. After use for 2–3 months, only isoniazid and rifampicin are continued for another 6–9 months. The CDC recommends prolonged therapy for tuberculosis of any site that is slow to respond and thus, patients with intraocular TB may require prolonged therapy.[15]

Along with the initiation of ATT, low dose oral steroids are also commenced for a period of 4–6 weeks as they help in reducing the damage to ocular tissues, which can happen due to, delayed hypersensitivity.

Essential first-line anti-TB drugs:

1. **Isoniazid:** It is a prodrug; activation of isoniazid produces oxygen-derived free radicals (superoxide, hydrogen peroxide, and peroxynitrite) and organic free radicals that inhibit the formation of mycolic acids of the bacterial cell wall, causing DNA damage and, subsequently, the death of the bacillus. It has a bactericidal effect on rapidly growing bacilli, but has a limited effect on slow-growing (generally intracellular) and intermittently growing (generally extracellular) bacilli.
2. **Rifampicin:** It inhibits the gene transcription of mycobacteria by blocking the DNA-dependent RNA polymerase, which prevents the bacillus from synthesizing messenger RNA and protein, causing cell death. It is a bactericidal drug that kills growing, metabolically active bacilli, as well as bacilli in the stationary phase, during which metabolism is reduced.
3. **Pyrazinamide:** It is a prodrug; enters the bacillus passively, is converted into pyrazinoic acid by pyrazinamidase, and reaches high concentrations in the bacterial cytoplasm due to an inefficient efflux system. Pyrazinoic acid decreases the intracellular pH to levels that cause the inactivation of enzymes-such as fatty acid synthase I, which plays a fundamental role in synthesizing fatty acids-and, consequently, the impairment of mycolic acid biosynthesis. It is also bactericidal and is particularly potent in elimination of persistent bacilli in the sporadic multiplication phase which are responsible for bacteriological relapse.
4. **Ethambutol:** It interferes with the biosynthesis of arabinogalactan, the principal polysaccharide on the mycobacterial cell wall. It acts on intracellular and extracellular bacilli, principally on rapidly growing bacilli.

Side effects of anti-tubercular drugs are well documented. Dose associated hepatotoxicity can be prevented by regular monitoring of liver-function tests. Other commonly seen side effects include cutaneous reactions, gastrointestinal intolerance, hematological reactions and renal failure.

JAYPEE BROTHER

TABLE 4.4: Ocular side-effects of antitubercular drugs

Drug	Side-effect
Isoniazid	Optic neuritis, optic atrophy
Ethambutol	Optic neuritis, acquired red-green dyschromatopsia, central scotomas, disk edema, peripapillary splinter hemorrhages, optic atrophy, retinal edema pigmentary changes at fovea (rare)
Rifabutin	Severe acute anterior uveitis (hypopyon uveitis), corneal endothelial deposits, inflammatory vitreous exudates and opacities

Side effects caused by these drugs are listed in Table 4.4.

A baseline ophthalmic examination including visual acuity, visual fields and color vision should be documented for all patients before starting ethambutol. In case of any ocular side effect the drug should be stopped immediately. Vision improves spontaneously in many cases. Parenteral hydroxocobalamin can be considered for a 10–28 week period for those who do not improve spontaneously.

The emergence of MDR-TB (multidrug resistance) and XDR-TB (extremely drug resistant) entails the use of next generation drugs for extended periods. About 8–10 drugs have to be used for 18–24 months. Additional agents include ethionamide, kanamycin, cycloserine, rifabutin, fluoroquinolones, interferon-γ and linezolid.

Surgical Management

Complications may arise due to longstanding ocular disease leading to non-clearing vitreous hemorrhage, tractional retinal detachment, etc. Both the conditions need surgical intervention—vitrectomy.

Research and Development[2]

- A diagnostic platform called the GeneXpert Omni is in development. It is meant for testing for TB and rifampicin-resistant TB using XpertMTB/RIF cartridges. It is supposed to be smaller, lighter and less expensive than current platforms.
- A next generation cartridge called Xpert-Ultra is in development and intends to replace the XpertMTB/RIF cartridge. It could potentially replace culture as the primary diagnostic tool for TB.
- Eight new or re-purposed anti-TB drugs are in advanced phases of clinical development. For the first time in six years, an anti-TB drug (TBA-354) is in Phase I trials.
- Several new TB treatment resistant regimens are being tested for use in drug-susceptible and/or drug-TB in Phase II or Phase III trials.
- Fifteen vaccine candidates are in clinical trials; emphasis has shifted from children to adolescents and adults.

JAYPEE BROTHER

REFERENCES

1. TB India 2015-RNTCP-Annual status report; page 22.
2. WHO Global tuberculosis report 2015; page 8.
3. Basu S, Wakefield D, Biswas J, Rao NA. Pathogenesis and Pathology of Intraocular Tuberculosis. Ocul Immunol Inflamm. 2015;23(4):353-7.

4. Gupta V, Gupta A, Arora S, et al. Presumed tubercular serpiginous like choroiditis: clinical presentation and management. Ophthalmology. 2003;110,1744-9.
5. Majumder PD, Biswas J, Bansal N, Ghose A, Sharma H. Clinical Profile of Patients with Tubercular Subretinal Abscess in a Tertiary Eye Care Center in Southern India. Ocul Immunol Inflamm. 2016:1-5. [Epub ahead of print]
6. Biswas J, Sharma T, Gopal L, et al. Eales' disease—an update. Surv Ophthalmol. 2002;47:197-214.
7. Daniel V. Vasconcelos-Santos, Manfred Zierhut, Narsing A Rao. Strengths and Weaknesses of Diagnostic Tools for Tuberculous Uveitis, Ocular Immunology and Inflammation. 2009;17(5):351-5.
8. Herbort CP, LeHoang P, Guex-Crosier Y. Schematic interpretation of indocyanine green angiography in posterior uveitis using a standard angiographic protocol. Ophthalmology. 1998;105:432-40.
9. Gupta A, Biswas J. Fundus autofluorescence imaging to document evolution, progression and healing pattern of serpiginous choroiditis. Oman J Ophthalmol. 2014;7(2):100-101.
10. Rifkin LM, Munk MR, Baddar D, Goldstein DA. A new OCT finding in Tuberculous serpignous-like choroidopathy. Ocul Immunol Inflamm. 2015;23(1):53-8.
11. Gupta A, Sharma A, Bansal R, Sharma K. Classification of Intraocular Tuberculosis. Ocul Immunol Inflamm. 2015;23(1):7-13.
12. Ang M, Vasconcelos DV, Sharma K, et al. Diagnosis of Ocular Tuberculosis. Ocular Immunol Inflamm. 2016:1-9. [Epub ahead of print]
13. Centers for Disease Control and Prevention. Targeted tuberculin testing and treatment of latent tuberculosis infection. American Thoracic Society. MMWR Recomm Rep. 2000;49:1-51.
14. Bansal R, Gupta A, Gupta V, et al. Role of anti-tubercular therapy in uveitis with latent/manifest tuberculosis. Am J Ophthalmol. 2008;146:772-9.
15. Centers for Disease Control and Prevention (CDC): American Thoracic Society, MMWR Morb Mortal Wkly Rep. 2003;52(31):735-9.

JAYPEE BROTHER

for detailed information on ophthalmology books, visit our website **www.jaypeebrothers.com,** for detailed informa

Recent Advances in OPHTHALMOLOGY–13

Salient Features

- Contains two editorials and 19 chapters on selected topics in ophthalmology
- Focuses mainly on endophthalmitis, its differential diagnosis and control
- Includes an interesting subject of intravascular intervention in neuro-ophthalmic disorders
- Discusses the text with the help of numerous illustrations in diabetic macular edema
- Opens new avenues for the treatment and progression of glaucoma through imaging.



HV Nema MS has a distinguished academic career and is well-known for teaching, researches and publications. He has served as a Consultant Editor/Advisory Editor to Indian Journal of Ophthalmology, Afro–Asian Journal of Ophthalmology and Indian Journal of Optometry. He has published more than 6 dozen papers in the national and international journals. He is an established author in the field of ophthalmology. *Ophthalmic Syndromes* (Butterworth, London, UK, 1973) and *Textbook of Ophthalmology (*6th edn, 2012, Jaypee Brothers Medical Publishers, New Delhi, India) are some of his popular books. He has edited 13 volumes of *Recent Advances in Ophthalmology* and 3 editions of *Diagnostic Procedures in Ophthalmology*, which were well-received by readers and favorably reviewed in Indian and international journals. He has delivered guest-lectures in many universities.



Nitin Nema MS DNB is an experienced Phaco and Vitreoretinal Surgeon. He did his Fellowship from Aravind Eye Hospital, Madurai, Tamil Nadu, India. He gained clinical and research experience from the University of Illinois at Chicago, and the University of Wisconsin at Madison in the USA. He was awarded a Fellowship by the All India Ophthalmological Society to work on a Project on Uveitis at Sankara Nethralaya, Chennai, Tamil Nadu, India. He was awarded Dr Mohan Lal Gold Medal for the best paper. He had authored (in collaboration with Dr HV Nema) 2 textbooks: *Anatomy of the Eye and Adnexa* (3rd edition) and *Textbook of Ophthalmology* (6th edition), and edited 12 volumes of *Recent Advances in Ophthalmology*, and 3 editions of *Diagnostic Procedures in Ophthalmology.*

Available at all medical bookstores
or buy online at www.jaypeebrothers.com



JAYPEE BROTHERS
Medical Publishers (P) Ltd.
www.jaypeebrothers.com

Join us on facebook.com/JaypeeMedicalPublishers

Shelving Recommendation
OPHTHALMOLOGY

