information on pathology books, visit our website www.jaypeebrothers.com, for detailed information on pathology books, visit our website www.jaypeebrothers.com

Celebrating 50 Passion, Quality and Innovation in Healthcare Publishing

Fundamentals of SURGICAL PATHOLOGY

SECOND EDITION

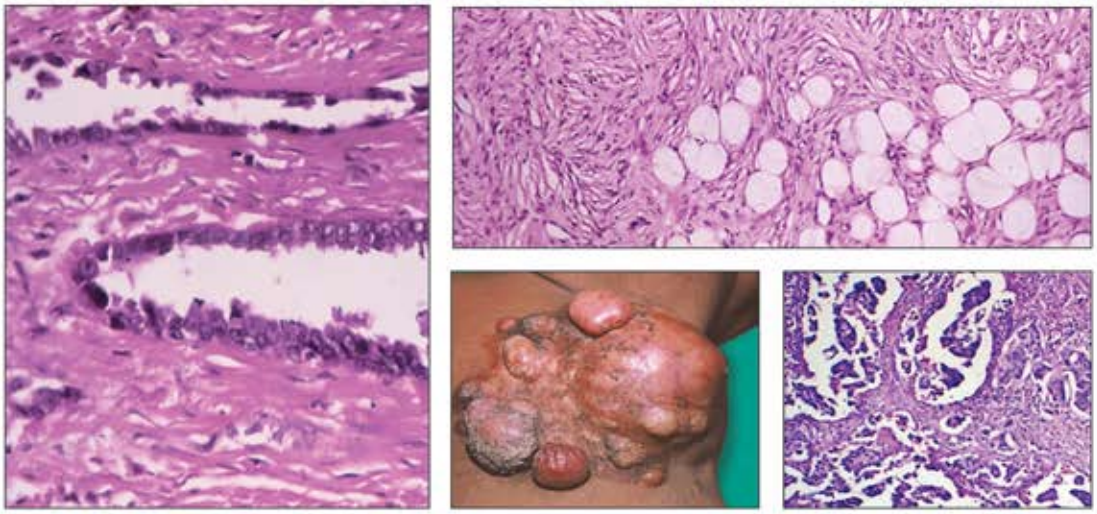

Shameem Shariff

JAYPEE

Fundamentals of
SURGICAL PATHOLOGY

Second Edition

- **Grossing Techniques: With Pictorial Line Diagrams**
- **Gross Pearls: Appearances of Lesions Based on Author's Extensive Experience**
- **Microscopy and Aids in Diagnosis: With Differential Diagnoses and Current Concepts**
- **Immunohistochemistry: Spectrum of Antibodies and their Applications in Surgical Pathology**
- **Synoptic Reporting and Minimum Datasets: Requirements for a Complete Biopsy Report**

Shameem Shariff
MBBS MD (Pathology) PhD (Pathology)
Formerly
Professor and Head
Department of Pathology
St John's Medical College and Hospital
and
MVJ Medical College and Research Hospital
Bengaluru, Karnataka, India

Foreword
Harsh Mohan

JAYPEE BROTHERS MEDICAL PUBLISHERS
The Health Sciences Publisher
New Delhi | London | Panama

JAYPEE BROTHERS

Contents

1. Female Genital Tract 1

Grossing Techniques *1*

- Cervix *1* ▪ Endometrium *3* ▪ Uterus, Cervix, Ovaries and Fallopian Tubes *3*
- Carcinoma Cervix *6* ▪ Carcinoma Endometrium *6* ▪ Ovarian Tumors *7*
- Tumors of the Fallopian Tube *7* ▪ Pelvic Exenteration *7* ▪ Vulva *8*
- Placenta *9* ▪ Fetus *13*

Gross Pearls *15*

- Cervix *15* ▪ Uterus *17* ▪ Ovary and Fallopian Tubes *17*

Microscopy Pearls: Aids in Diagnosis *18*

- Vulva *18* ▪ Cervix *20* ▪ Uterus *29*

Ovary *39*

- Non-neoplastic Conditions *39* ▪ WHO Classification of Ovarian Tumors *40*

Synoptic Reporting and Minimum Data Sets *54*

- Cervical Biopsy Histopathology Report (Tumor and Non-tumor) *54*
- Hysterectomy Specimen for Cervical Cancer *56*
- Endometrial Biopsy Histopathology Report (Tumor and Non-tumor) *58*
- Hysterectomy Specimen: Histopathology Report (Non-tumor) *58*
- Hysterectomy Specimen: Endometrial Cancer Histopathology Report *60*
- Ovary and Fallopian Tube: Non-neoplastic/Benign Tumors *63*
- Ovary: Malignant Surface Epithelial Tumor *64*
- Nonepithelial Tumors: Ovary *65* ▪ Fallopian Tube Carcinoma *67*

2. Male Genital System: Grossing Techniques 70

- Penis *70*

Synoptic Reporting and Minimum Data Sets *73*

- Small Biopsies *73* ▪ Resection Specimens *73*
- TNM Clinical Staging for Penile Carcinomas *74* ▪ Prostate *75*

Synoptic Reporting and Minimum Data Sets *82*

- Prostatic Needle Biopsies/TURP Chips *82* ▪ Resected Specimens for Prostatic Carcinoma *83*
- TNM Staging for Prostatic Carcinoma *84* ▪ Regional Lymph Nodes (N) *84*
- Distant Metastasis (M) *84* ▪ Testis *85* ▪ Gross Pearls *86*
- Microscopy Pearl: Aids in Diagnosis *86*

Synoptic Reporting and Minimum Data Sets *91*

- Testicular Biopsy *91* ▪ Resection Specimen for Testicular Cancer *91*
- pTNM Pathological Classification for Testicular Cancer *93*

JAYPEE BROTHERS

3. Urinary System 95

- Grossing of Kidney *95* ▪ Ureter *97* ▪ Gross Pearls *97*
- Microscopy Pearls: Aids in Diagnosis *99* ▪ Salient Anatomical Features *100*
- Renal Neoplasms *119*

Synoptic Reporting and Minimum Data Sets *125*

- Kidney Biopsy and Excision Histopathology Reporting Format *125*
- Urinary Bladder—Grossing Techniques *132* ▪ Gross Pearls *133*
- Microscopy Pearls: Aids in Diagnosis *134*

Synoptic Reporting and Minimum Data Sets *137*

- Urinary Bladder *137* ▪ Bladder Resection Specimens *138*
- TNM Classification of Urinary Bladder *140*

4A. Salivary Glands 142

- Normal Anatomy *142* ▪ Gross Pearls *143* ▪ Pearls for Microscopy: Aids in Diagnosis *144*
- Who Histological Classification of Tumors of the Salivary Glands, 2005 *145*

Synoptic Histopathology Reporting and Minimum Data Sets *153*

- Gross *153* ▪ Microscopy *153* ▪ Tumor *154* ▪ Lymph Nodes *154*
- TNM Staging of Salivary Gland Tumors *155*

4B. Oral Cavity and Oropharynx 156

- Oral Cavity *156* ▪ Grossing *156* ▪ Floor of Mouth and Gingiva *158*
- Hard Palate and Upper Alveolar Ridge *159* ▪ Pharynx *160* ▪ Grossing of Pharynx *162*
- Gross and Pearls for Microscopy: Aids in Diagnosis *166*

Synoptic Reporting and Minimum Data Set *169*

- Oral Cavity; Oropharynx—Resection for Malignancy *169*

5. Gastrointestinal Tract 171

- Esophagus *171* ▪ Stomach *176* ▪ Small and Large Intestine *185* ▪ Appendix *188*

Synoptic Reporting and Minimum Data Sets *208*

- Minimum Data Set *208* ▪ Esophageal Resection for Carcinoma Histopathology Report *208*
- Pathological Staging *209* ▪ Stomach Biopsy Histopathology Report *209*
- Stomach Carcinoma Resection Histopathology Report *210* ▪ Reporting of Small Intestinal Endoscopic Biopsies *210* ▪ Reporting of Resected Specimen of Small Intestine *211*
- Colorectal Biopsy Histopathology Report (Nontumor and Tumor) *212*
- Colorectal Cancer Resection Histopathology Report *212* ▪ Maximum Tumor Diameter *213*
- Distance of Tumor to Nearest Margin *213* ▪ Presence of Tumor Perforation *213*
- For Rectal Tumors *213*

JAYPEE BROTHERS

6. Liver and Gallbladder 215

- Liver *215* ▪ Gallbladder *217*

Gross Pearls *217*

- Liver *217* ▪ Gallbladder *218* ▪ Microscopy Pearls: Aids in Diagnosis *218*
- WHO Classification of Tumors of the Liver and Intrahepatic Bile Ducts 2010 *232*

Synoptic Reporting and Minimum Data Sets *234*

- Cholecystectomy *234* ▪ Liver: Needle Biopsy/Wedge Biopsy: Minimum Data Set *234*

7. Pancreas 237

- Pancreatic Biopsies *237* ▪ Gross Pearls *239* ▪ Microscopy Pearls: Aids in Diagnosis *239*

Synoptic Reporting and Minimum Data Sets *246*

- Pancreatic Biopsies/Resections *246* ▪ TNM Staging of Pancreatic Neoplasms *247*

8. Respiratory System 248

- Upper Respiratory Tract *248* ▪ Larynx *248* ▪ Grossing of Larynx *251*
- Lower Respiratory Tract: Lung *261* ▪ Pleura *262*
- 2015 WHO Classification of Lung Tumors *267*

Synoptic Reporting and Minimum Data Sets *276*

- Lung Biopsy/Resections *276* ▪ TNM Staging of Lung Tumors *277*

9. Lymphoreticular System 279

- Lymph Nodes *279* ▪ Spleen *280* ▪ Thymus *281* ▪ Gross Pearls *281*
- Microscopy: Aids in Diagnosis *282* ▪ Thymoma *305*

Synoptic Reporting and Minimum Data Sets *306*

- Lymphoreticular Histopathology Report *306*
- ANN Arbor Staging System for Hodgkin's and Non-Hodgkin's Lymphomas *307*

10. Breast 309

- Specimens Received *309* ▪ Lymph Nodes *311* ▪ Gross Pearls *312*
- Microscopy Pearls: Aids in Diagnosis *313* ▪ Carcinoma Breast *318*

Breast Histopathology Synoptic Report: Minimum Data Sets Excision/Mastectomy *331*

- Wide Bore Needle Biopsy Form (WBN) *332* ▪ Optional Further Information *333*
- TNM Clinical Classification *333*

JAYPEE BROTHERS

11. Thyroid and Parathyroid Glands 336

Grossing Techniques *336*

- Thyroid Gland *336*
- Parathyroid Gland *338*
- Gross Pearls *338*
- Microscopy Pearls: Aids in Diagnosis *339*

Synoptic Reporting and Minimum Data Sets *347*

- Thyroid Biopsy/Resection Specimens *347*
- TNM Staging of Thyroid Tumors *349*

12. Skin 350

- Grossing Techniques *350*
- Microscopy Pearls: Aids in Diagnosis *352*
- Keratinocytic Tumors (WHO Classification 2006) *357*
- Melanocytic Tumors (WHO 2006) *365*
- Appendageal Tumors (WHO 2006) *368*
- Soft Tissue Tumors *371*
- Neural Tumors (WHO 2016) *371*
- Inherited Tumor Syndromes (WHO 2016) *373*

Synoptic Reporting and Minimum Data Sets *373*

- Skin Melanoma *373*
- Nonmelanocytic Tumors of the Skin *374*

13. Bone 376

- Normal Anatomy *376*
- Grossing of Bone Lesions *377*
- Extremities *378*
- Gross Pearls *380*
- Microscopy Pearls: Aids in Diagnosis *381*
- WHO Classification of Bone Tumors, 2013 *383*
- Microscopy *384*
- Giant Cell Lesions of the Bone *393*

Synoptic Reporting Bone Lesions Minimum Data Sets *394*

- TNM Staging of Bone Tumors *394*

14. Soft Tissue 396

- Soft Tissue: Grossing *396*
- Gross Pearls *398*
- Microscopy Pearls: Aids in Diagnosis *399*

Synoptic Reporting and Minimum Data Sets *418*

- Non-neoplastic *418*
- TNM Staging of Soft Tissue Tumors *419*

15. Pediatric Neoplasms 420

- Grossing Techniques *420*
- Microscopy Pearls: Aids in Diagnosis *423*

Synoptic Reporting—Minimum Data Sets *429*

- Nephrectomy Specimen Reporting for Wilms' Tumor *429*
- Microscopy *430*
- Reporting on Neuroblastoma Resection Specimens *431*
- Staging of Neuroblastoma *431*
- Retinoblastoma Report on Resected Specimens *431*
- pTNM Staging *432*

JAYPEE BROTHERS

16. Cardiovascular System 433

- Normal Anatomy *433* ▪ Heart Valves: Gross *433*
- Microscopy Pearls Aids in Diagnosis *434* ▪ Endocarditis *434*

17. Brain and Meninges 441

- Brain *441* ▪ Vascular Disorders *446* ▪ Brain Tumors *448*
- Neurodegenerative Diseases *455* ▪ Alzheimer's Disease *455* ▪ Parkinsons' Disease *456*
- Huntingtons' Disease *456* ▪ Amyotrophic Lateral Sclerosis *456*

18. Eye and Orbit 458

- Eye and Orbit *458*
- Microscopy Pearls: Aids in Diagnosis *460*

Synoptic Reporting: Minimum Data Sets: Small Biopsies *463*

19. Immunohistochemistry in Surgical Pathology 465

- Applications *465*

Annexures 477

- **Annexure – I** *477*
- **Annexure – II** *478*
- **Annexure – III** *478*
- **Annexure – IV** *479*
- **Annexure – V** *479*

Index 481

JAYPEE BROTHERS

Chapter 15

Pediatric Neoplasms

JAYPEE BROTHERS

GROSSING TECHNIQUES[1]

The grossing of pediatric neoplasms needs special emphasis because of various factors. Solid neoplasms which occur in children are often embryonal with a capability for diverse differentiation, each differentiation indicating a varied prognosis. It becomes mandatory that the neoplasm be sampled generously for this reason. Besides this, due to gray zones occurring particularly in "small blue cell neoplasia", portions of tumor tissue have to be kept aside for chromosomal studies, electron microscopy, immunohistochemistry (IHC) and DNA studies. It is always preferable therefore that some "fresh tissue" wrapped separately in moist saline is sent along with the specimen in formalin. However, when such tissue is collected it should be representative of the neoplasm and taken from areas devoid of necrosis, hemorrhage, etc. Therefore, in order that appropriate tissue may be taken for these procedures in pediatric neoplasms it would be easier if the entire specimen is submitted to the surgical pathology laboratory in an intact fresh and unfixed state. The tissue may thereafter be taken immediately by the pathologist for the following:

- 2–3 mm slices of 1 g each wrapped in foil and snap frozen in liquid nitrogen for cytogenetic studies or DNA studies.
- 2 × 1 × 1 mm bits taken in 2% glutaraldehyde for electron microscopy
- 2 ×1 × 1 mm thick bits may be taken in APMI media with 10% fetal calf serum for cell culture.
- Fresh tissue sections may be cut for immuno-histochemistry.
- Touch preparations may also be made particularly from the bulged fresh cut surfaces.

The above sampling should not compromise in any way the study of resected margins.

The more important of the pediatric neoplasms will be dealt with here.

Wilms' Tumor

The specimen is to be handled, described and sectioned as per the specifications given in the chapter on urinary system. The chief differences are:

- The capsule should never be stripped in pediatric tumor, as:
  - This would distort any morphology relating to infiltration of the capsule which is a significant feature in the staging of the tumor.
  - Any nephrogenic rests normally situated in the subcapsular region may not be detected microscopically if they have been peeled away with the capsule.
- Generous sampling is advised in order to detect.
  - Anaplasia which would differentiate a neoplasm with favorable/unfavorable histology. The bare minimum of sampling advised therefore is one generous bit per centimeter of the greatest dimension of the tumor. The bits need not necessarily be contiguous, e.g. if a neoplasm is seen to measure 8 cm in the greatest dimension (after adequate sectioning), then 8 bits need to be given from representative morphologically variable areas of the tumor.

- Adequate sampling of uninvolved renal parenchyma is always advisable to detect blastema/nephrogenic rests. The detection of this becomes important for if this is present then there is a possibility that the uninvolved opposite kidney may also show these rests in which case the patient has to be monitored closely for any future neoplastic change occurring in these rests.
- Adequate sampling of the renal capsule. This can be ensured if the neoplasm is sampled at the periphery **(Fig. 15.1)**.
- Sampling of the hilar sinus—the hilar sinus is that concavity seen in the medial most portion of the kidney. It contains the renal blood vessels and ureter at the hilum with the surrounding fat. The surgical margin of this hilar sinus and the hilar contents need to be sampled both in Wilm's tumor and mesoblastic nephroma.
- Method of sampling the sinus—the bits taken should enable histological examination of the sinus and its resected soft tissue margin. Overnight fixing after the specimen is bisected enables adequate fixation for subsequent sectioning of the sinus as a horizontal slice which may be then divided and given in two or more bits with the soft tissue resected margin being inked. In the fresh state, however, the margin may be inked and taken separately, and the contents of the sinus may be scooped out in a separate capsule with portions of any adherent vessels or ureter.

Bits (Fig. 15.1)

- *A to D*: Neoplasm with renal capsule and adjacent parenchyma
- *E*: Neoplasm and portion of hilar sinus; tumour thrombus in renal vein with portion of vein (adjacent renal artery and ureter if necessary may be included)
- *F*: Soft tissue-hilar sinus (if not included in E)
- *G*: Soft tissue surgical margin at hilar sinus
- *H and J*: Uninvolved kidney to include nephrogenic rests;
- *K*: Renal artery and vein surgical margin
- *L*: Ureteric surgical margin
- *M and N*: Lymph nodes—perihilar, others.
(NWTS staging given after synoptic reporting)

Liver Tumors

The description and sectioning would be as similar to the protocol given in Chapter 6 (Liver and Gallbladder).

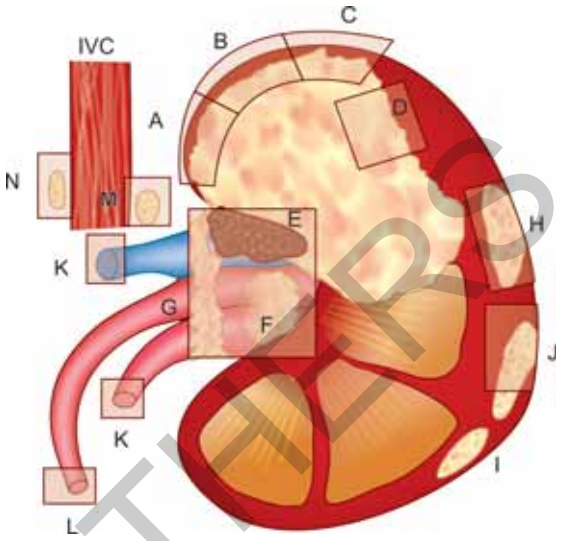

Figure 15.1

(IVC: inferior vena cava)

Photographs of the gross specimen should be taken if facilities are available. The important aspects to be considered during grossing are:

- Appropriate measures may be taken to identify blood vessels and bile duct.
- The resection margins should be inked and the inking allowed to dry thoroughly before sectioning. The resected margin is to be examined and sampled entirely. For this the sectioning should be made perpendicular to the resected margin at 1 cm intervals. A drawing of the specimen indicating the surgical surface and the location of sections taken for microscopic examination will aid in identifying and documenting the position of the neoplasm in relation to the resected margin.

The bits taken should be representative of the lesion under study, for example:

- Sections should be taken from any "large feeder vessels" at the junction of focal nodular hyperplasia with normal liver. These are thought to initiate development of the lesion.
- In hemangioendotheliomas that have been treated preoperatively with transarterial embolization or hepatic artery ligation, sampling, should be done at the very periphery of the tumor nodules as these alone may represent uninfarcted areas of the tumor.
- The possible sections that could be taken for a routine hepatic neoplasm are shown **(Fig. 15.2)**. The general rule followed should be one generous bit per 1 cm of the greatest tumor dimension.

JAYPEE BROTHERS

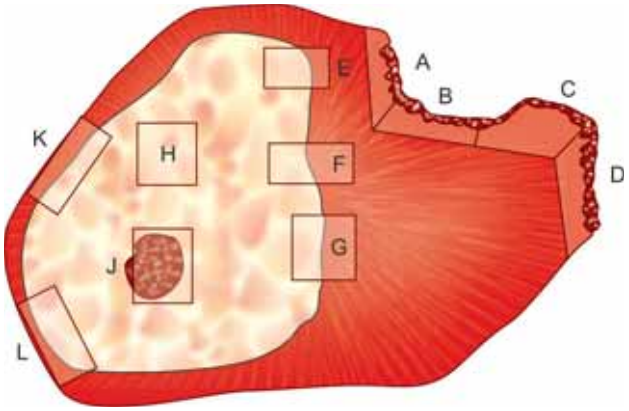

Figure 15.2

TABLE 15.1 Children's Cancer Study Group staging classification of liver tumors

Stage	*Criteria*
Stage I	Complete resection
Stage II	Microscopic residual, negative nodal involvement, no spilled tumor
Stage III	Gross residual or nodal involvement or spilled tumor. Primary completely resected, but nodes positive, tumor spill, or both. Primary not completely resected and nodes positive, tumor spill, or both
Stage IV	Metastatic disease: • Primary completely resected • Primary not completely resected

Bits

- *A to D*: Inked surgical margin to evaluate the completeness of the resection for staging purposes (**Table 15.1** outlines the staging of liver tumors in children)
- *E to G*: Sections of tumor with adjacent normal liver to ensure comparison of tumor morphology with normal liver
- *H, J, K and L*: Varied tumor areas representing necrosis, etc. and capsular study.

Germ Cell Tumors

- In a sacrococcygeal tumor the pathologist should determine whether the coccyx is received with the specimen. If this has not been surgically removed, the pathologist should notify the surgeon that coccygeal excision is part of the recommended surgical procedure for resection of such tumors. The soft tissue immediately adjacent to the coccyx needs to be sampled as this can be the site of an occult yolk sac tumor.
- Malignant extragonadal tumors frequently do not appear to have an intact capsule, therefore, it may not be possible to determine whether they have been completely resected.
- The tumor should be sampled from areas of differing appearances (one generous bit per 1 cm of tumor), as therapy is directed toward the most malignant element.
- Contrary to all tumors hemorrhagic areas in germ cell tumors should be sampled to detect choriocarcinomas which are often hemorrhagic.
- One or two sections from the adjacent testis should be taken for the presence of intratubular germ cell neoplasia which would place the child at an increased risk of developing a second primary in the opposite testis.
- In ovarian tumors, every nodule from the omentum and peritoneal surface and all lymph nodes should be sampled. If these nodules or nodes contain mature teratomatous elements (gliomatosis peritonei) the ovarian tumor stage is unchanged. If on the other hand, malignant elements are found in these tissues, the tumor becomes a stage II or III tumor and requires more aggressive therapy.

The staging of germ cell tumors as used by the Pediatric Oncology Group and the Children's Cancer Study Group:

Testis

Stage I: The tumor is limited to the testis (testes) and completely resected by high inguinal orchiectomy or transscrotal orchiectomy with no spillage. No clinical, radiographic, or histologic evidence of tumor is apparent outside the testis (testes). Tumor markers are normal after an appropriate half-life decline. Normal or markers unknown at the time of diagnosis of a malignant germ cell tumor require the patient to have negative ipsilateral retroperitoneal node sampling to confirm stage I. Bilaterality does not change the stage.

Stage II: The tumor is resected by trans-scrotal orchiectomy with gross spillage of tumor; microscopic disease is present in the scrotum or high in the spermatic cord (<5 cm from the proximal end); retroperitoneal lymph

JAYPEE BROTHERS

node involvement (<2 cm by pathologist's measurement) is found; and/or increased tumor markers after an appropriate half-life are noted.

Stage III: The retroperitoneal lymph nodes are involved (>2 cm by the pathologist's measurement), but no visceral or extra abdominal involvement is apparent.

Stage IV: Distant metastases, including liver metastases are present.

Ovary

Stage I: The tumor is limited to the ovary (ovaries), and peritoneal washings (or ascitic fluid) are negative for malignant cells. No clinical, radiographic, or histologic evidence of disease is found outside the ovary (ovaries). Tumor markers are normal after an appropriate half-life decline. Bilaterality does not change the stage.

Stage II: Microscopic residual or positive lymph nodes (≤2 cm by pathologist's measurement) are present. Peritoneal washings (or ascitic fluid) are negative for malignant cells, and tumor markers are positive or negative.

Stage III: Lymph nodes (or a metastatic nodule) are involved. (>2 cm by pathologist's measurement); there is gross residual or biopsy only; there is contiguous viscera involvement (omentum, intestine, bladder); and/or peritoneal washings (ascitic fluid) are positive for malignant cells. Tumor markers may be positive or negative.

Stage IV: Distant metastases, including liver metastases are present.

Extragonadal

Stage I: At any site complete resection must be performed (with coccygectomy performed for a sacrococcygeal site) and the tumor margins must be negative for tumor. Tumor markers are normal after an appropriate half-life decline.

Stage II: Microscope residual is present. Lymph nodes are negative, and tumor markers are positive or negative.

Stage III: There is gross residual or biopsy only. Lymph nodes and tumor markers are negative or positive.

Stage IV: Distant metastases, including liver metastases, are present.

MICROSCOPY PEARLS: AIDS IN DIAGNOSIS[2-4]

Classification of Kidney Tumors in Infants and Children

- Nephroblastoma (Wilms tumor)
  - Unfavorable histology
  - Favorable histology.
- Cystic partially differentiated nephroblastoma
- Mesoblastic nephroma
- Clear cell sarcoma
- Rhabdoid tumor
- Other tumors like neuroblastoma.

Wilms' Tumor

- Most common primary renal tumor of childhood (more than 80% of childhood renal tumors)
- Between 2 and 5 years.
- 5–10% involve both kidneys (synchronous/metachronous)
- 10% are associated with congenital syndromes:
  - WAGR syndrome—aniridia, genital abnormalities, mental retardation (30% chance of tumor)—*WT1* gene involved
  - Denys-Drash syndrome (90% risk)—gonadal dysgenesis (male pseudohermaphroditism), early onset nephropathy (diffuse mesangial sclerosis)—*WT1* germline abnormality
  - Beckwith-Weidemann syndrome—organomegaly, macroglossia, hemihypertrophy, omphalocele; WT2 locus involved.
- Familial predisposition to tumor is rare
- *Gross:* Large, solitary well circumscribed masses. C/S solid, soft and homogenous gray pink (resembling brain tissue) with occasional foci of hemorrhage and cyst formation.
  Tumor anaplasia has been defined by the National Wilm's Tumor Study (NWTS) system as: Combination of cells with very large hyperchromatic nuclei and multipolar mitotic figures. The enlarged nuclei should be atleast three times as large as the typical blastemal nuclei in both axes and the hyperchromasia should be obvious.
- Malignancies associated with Wilms' tumor—osteosarcoma; Botryoid variant of embryonal rhabdomyosarcoma; retinoblastoma; hepatocellular carcinoma; neuroblastoma.

JAYPEE BROTHERS

Immunohistochemistry:
- Blastemal area—focally +ve for vimentin
- Epithelial area—+ve for keratin, EMA, lectins and components of basement membrane
- Mesenchyme—skeletal muscle differentiation- +ve for myogenin
- Neural elements—+ve for NSE,GFAP, S-100
- Insulin like growth factor receptor +ve.

Cystic partially differentiated Wilms' tumor: Grossly resembles cystic nephroma, elements typical of Wilms' are contained in the septa; may be inconspicuous, therefore tumors should be sampled excessively.

Mesoblastic Nephroma

Comprises <3% of primary renal tumors in children.
- Occur in first 3 months of life and are uncommon in children.
- Associated with polyhydramnios and prematurity.
- Abdominal mass is the presenting symptom and vast majority are cured by surgical excision.
- Incomplete excision results in recurrences as the tumor is not well circumscribed.
- Grossly large with non-encapsulation.
- *Micros:* Moderately cellular proliferation of interlacing bundles of spindle shaped cells. Entrapment of glomeruli and tubules is common.
- "Cellular mesoblastic nephroma" with proliferation of polygonal cells with mitoses has been reported
- *DD:* Stromal predominant Wilms tumor
- *IHC:* Positive for vimentin, fibronectin and sometimes smooth muscle actin.

Clear Cell Sarcoma of the Kidney

- Originally called "bone metastasizing renal tumor of childhood" is a highly malignant neoplasm comprising 6% of pediatric renal tumors. It occurs in the same age range as Wilms' tumor.
- Gross: Well circumscribed, cut surface is variable-homogenous, grayish lobular, pink soft areas or firm and whorled. Occasionally, abundant mucin production is seen as well as cystic change.
- *Microscopy:* Monotonous array of cells with lightly staining or vacuolated cytoplasm and indistinct borders. Nuclei contain finely dispersed chromatin. In the classic pattern, the cells are arranged in sheets with intervening small blood vessels. An infiltrative border is seen. Other patterns include spindle, hyaline sclerosis, cystic change and palisading.
- The propensity for metastasis to bone is marked, atleast ten times more likely as compared to other pediatric tumors.
- *IHC:* Focal positivity for vimentin; also IGF-receptor.

Rhabdoid Tumor of Kidney

- Most malignant of the renal neoplasms of childhood, this tumor usually metastasizes widely and causes death within 12 months of diagnosis.
- The patients are very young at the time of diagnosis (rare after 3 years) and there is a 1.5: 1 male preponderance.
- *Gross*: Lack the appearance of encapsulation seen in Wilms' and clear cell sarcoma, they are located medially in the kidney with infiltration of the renal sinus and pelvis. They are typically yellow gray or light tan crumbly tumors with indistinct borders. Hemorrahge and necrosis are common.
- *Microscopy:* Diffuse and monotonous pattern of polygonal cells with abundant eosinophilic cytoplasm and spheroidal nuclei with thick nuclear membranes and prominent large nucleoli. Often the cytoplasm contains large eosinophilic globular inclusions which displaces the nucleus.
- *IHC:* Strong positivity for vimentin and usually for keratin also; negative for muscle and neural markers loss of INI1 expression is specific.

Neuroblastoma

- Common in young children. About 80% of cases are detected in those under 4 years
- May be familial and associated with Beckwith Wiedcmann syndrome, Hirschsprung's disease and other congenital abnormalities and in patients with neurofibromatosis.
- 70% of cases occur in the retroperitoneum and majority involve the adrenal gland
- Bilaterality is rare
- *Gross:* Large, soft gray and well circumscribed, areas of hemorrahge, necrosis and calcification are seen. Hemorrhage may be so extensive that it mimicks a hematoma. Cystic change is also seen.
- *Microscopy:* Vaguely nodular due to presence of delicate incomplete fibrous septa. Tumor cells are small and regular with round deeply staining nuclei slightly larger than lymphocytes. There is little cytoplasm and cytoplasmic outlines are poorly defined. Homer–Wright rosettes are present in 1/4th to 1/3rd cases—these are collections of tumor

JAYPEE BROTHERS

cells not related to blood vessels arranged around a central area filled with fibrillary material which is a tangled mass of neurites as shown by the silver stain. Rosettes do not show a central lumen (in contrast to those seen in retinoblastoma, ependydomas and carcinoid tumors). The lobular pattern may be prominent with a Zellballen like pattern. Hemorrhage is seen as also calcification which may occur as dust like or basophilic stippling. A pleomorphic variant of neuroblastoma has also been described and called the large cell variant.

IHC: NSE, neurofilaments, chromogranin, synaptophysin, secretogranin II, vasoactive intestinal peptide, cell surface ganglioside GD2 are all +ve.

Detail on Categories INPC, 1999 ***(Table 15.2)***

- Undifferentiated neuroblastoma:
  - Small to medium sized cells with a thin rim of cytoplasm and indistinct cytoplasmic borders
  - Nuclei round to oval, coarse granular chromatin (salt and pepper), indistinct nucleoli
  - Neuropil absent
  - No ganglion cell differentiation
  - No Schwannian stroma
  - Occasional immature ganglion cells (vesicular nucleus and prominent nucleolus) is a clue to differentiating these tumors from other small blue cell tumors.
- *Poorly differentiated neuroblastoma:*
  - Most cells similar to those described above
  - Neuropil: present
  - Ganglionic differentiation <5% of neoplastic cells (enlarged eccentric nucleus, vesicular chromatin, single prominent nucleolus and cytoplasm that is eosinophilic or amphophilic. (Cell diameter : Nucleus diameter is 2:1)
  - Nil or minimal ganglioneuromatous stroma, i.e. Schwannian stroma
- *Differentiating neuroblastoma:*
  - More than 5% of cells show ganglionic differentiation **(Fig. 15.3)**
  - More abundant neuropil than poorly differentiated neuroblastomas
  - Less than 50% of Schwannian stroma and <50% of ganglion cells
  - Ganglionic differentiation and Schwannian stroma seen at the periphery more often than in the center of the neoplasm
  - Transition zone between neuroblastoma and ganglioneuroblastoma component is poorly defined (as compared to nodular neuroblastoma)
- *Ganglioneuroblastoma, Nodular:* Characterized by gross presence of hemorrhagic neuroblastoma nodules that are present in a background which may resemble ganglioneuroblastoma, intermixed or the glistening tan pink whorled cut surface of ganglioneuroblatoma.

TABLE 15.2 Classification systems of Shimada, 1984 & INPC, 1999

Shimada 1984	International Neuroblastoma Pathologists' Committee (INPC) 1999
Stroma-poor neuroblastic tumor	*Neuroblastoma (Schwannian stroma-poor neuroblastic tumor)**
• Undifferentiated	• Undifferentiated
• Differentiating	• Poorly differentiated
	• Differentiating
Stroma-rich neuroblastoma	
• Nodular	*Ganglioneuroblastoma, nodular*
• Intermixed	*Ganglioneuroblastoma, intermixed*
Well-differentiated neuroblastic tumor	• *Ganglioneuroma*
Ganglioneuroma	• Maturing
	• Mature

* Main categories in each classification are given in italics

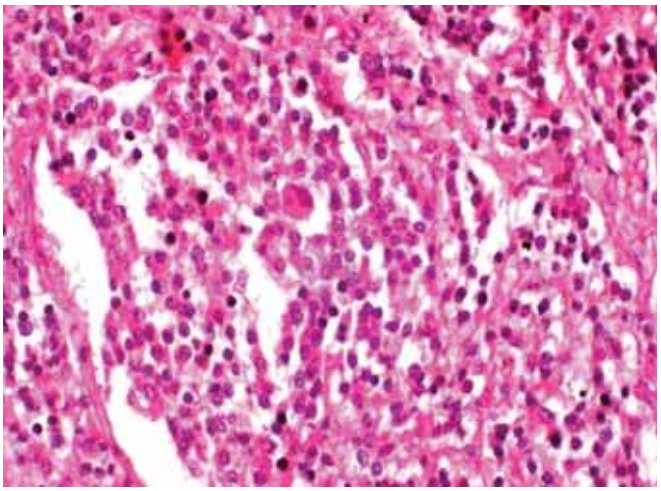

Figure 15.3 Sheets of uniform round cells of neuroblastoma with the center of the field showing differentiation into ganglion cell. (H&E x 400)

JAYPEE BROTHERS

The neuroblastoma nodules develop as result of evolution of one or more aggressive clones of cells within the tumor.
  - *Microscopy:* Abrupt demarcation of the neuroblastic (stroma poor) component from the ganglioneuroblastoma, intermixed (stroma-rich) or ganglioma neuroma (stroma dominant) component.
  - Nodules have a pushing border or may even have a fibrous pseudocapsule.
  - The stroma-rich/stroma dominant component is often located at the periphery but can appear as septa between tumor nodules.
  - Examination of the periphery is essential in identifying this tumor type.
- *Ganglioneuroblastoma, intermixed (Schwannian stroma-rich neuroblastic tumor):*
  - Random intermingling of neuroblastic nests within the stroma-rich (ganglioneuromatous) component.
  - Differs from ganglioneuroblastoma, nodular in lacking a macroscopic distinct hemorrhagic nodule; and microscopically lacks the distinct interface between the stroma-poor and stroma-rich components, i.e. edge is infiltrative and not pushing.
  - Ganglioneuroblastoma, intermixed unlike ganglioneuroblastoma, nodular, is classified as a favorable histology neuroblastic tumor.
  - Distinguished from differentiating neuroblastoma on the basis of the extent of ganglioneuromatous component which exceeds 50% of the total volume of the microscopic fields examined.
- *Ganglioneuroma (GN):* In the INPC classification GN is classified into GN maturing and GN mature.
  - The GN maturing subtype is composed predominantly of ganglioneuromatous stroma with a minor component of scattered evenly/unevenly distributed component of differentiating neuroblasts and/or maturing ganglion cells in addition to fully mature ganglion cells. Separation from GNB intermixed is based on the fact that neuroblastomatous foci do no form distinct microscopic nests, but instead individual neuroblastic cells merge into ganglioneuroblastic stroma.
  - The GN mature subtype can occur in adrenal and extra adrenal sites like retroperitoneum. They are sharply circumscribed but do not have a true capsule. Cut surface is gray to tan. Microscopically this subtype contains varying numbers of mature ganglion cells and Schwann cells with collagen. A few multinucleated ganglion cells may be seen. They lack a neuroblastoma component.

Immunohistochemistry

- Neuroblastoma component is +ve for 68 kd neurofilament protein, sometimes +ve for 150 and 200 kd neurofilament protein. GNBs and GNs are +ve for all three.
- NSE, chromogranin, secretogranins, synaptophysin +ve
- *Trk receptor protein:* Positivity denotes neuroblastoma with favorable histology
- NB 84 +ve (this is an antibody raised against NB cells. Also +ve in Ewing's Sarcoma, primitive neuroectodermal tumor (PNET) and desmoplastic small round cell tumors).

Genetics: Deletion of chromosome 1p is the most characteristic cytogenetic abnormality found in neuroblastomas.

Grading of neuroblastoma: Shimada classification: **(Fig. 15.4)** is based on the age of the patient and morphological factors like stroma-rich (schwannian) and stroma-poor (neuropil) nature of the lesion. Unfavorable stroma-rich and stroma-poor categories are separated out.

Features of the stroma-rich tumors that determine favorable and unfavorable histologic categories are:

Extensive schwannian spindle cell stroma imparting a neurofibroma or schwannoma-like pattern:

Favorable Histology

"Well-differentiated"—Immature cells uniformly distributed in isolated fashion.

"Intermixed"—Immature cells in isolated clusters throughout the tumor.

Unfavorable Histology

"Nodular"—One (or more) macroscopic area(s) of much less mature stoma-poor tumor (either one within the other grossly, or one in the primary tumor the other in metastatic site).

Histologic factors for the stroma-poor group of tumors, including the degree or 'grade' of differentiation and nuclear morphology.

Grade of Differentiation

Undifferentiated <5% differentiating elements

Differentiating >5% differentiating elements

Nuclear Morphology

Mitosis-Karyorrhexis index (MKI):*

- Low <100
- Intermediate <200
- High >200

*Based upon 5000 cell count in random fields

JAYPEE BROTHERS

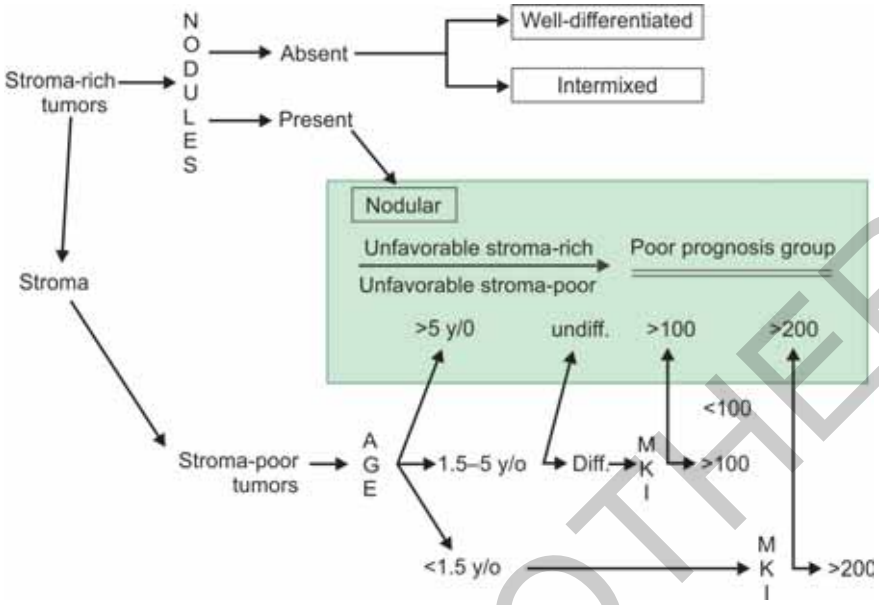

Figure 15.4 Prognostic factors in neuroblastic tumors
(Diff: differentiating; undiff: undifferentiated; MKI: Mitosis-Karyorrhexis index)
Courtesy: Fletcher CDM: Diagnostic histopathology of tumors, Shimada et al. JNCI. 1984;73:405-16.

Unfavorbale and favorable stroma-poor subgroups based upon differentiating elements, Mitosis–Karyorrhexis index (MKI), and age at diagnosis.

Unfavorable stroma-poor subgroups (4.5% survival)
- <1.5 years old, high Mitosis-Karyorrhexis index (MKI) regardless of histological maturity
- 1.5–5 years old with undifferentiated histology regardless of MKI
- 1.5–5 years old with differentiating histology and high or intermediate MKI
- All patients >5 years old

Favorable stroma-poor subgroups (84% survival)
- <1.5 years old with any maturation and low or intermediate MKI
- 1.5–5 years old with differentiating histology and low MKI

The MKI includes the number of cells with mitotic figures plus those with malformed, lobulated or pyknotic nucleic and individual cell necrosis. The MKI was used, hopefully to dampen interobserver variability in counting mitoses.

Retinoblastoma

- Most common intraocular neoplasm in children.
- Generally believed to be congenital and arises from the primitive neuroectodermal cells exhibiting retinal differentiation.
- Usually diagnosed between 16 months to 2 years.
- 60% are sporadic and 40% are familial. The gene responsible is the retinoblastoma (RB) gene and mutations in both alleles are necessary to produce inactivation of RB protein
- *Clinical features*: Presents as leukokoria (white papillary reflux). Rarely it presents with extraocular extension with formation of an orbital mass.
- Bilateral in 30% of all cases and in over 90% of familial cases.
- *Gross*: Flat diffuse or elevated forms are seen and show multicentric foci of origin especially in the hereditary type. It may protrude into the vitreous (endophytic type) or between retina and pigment epithelium (exophytic type). The tumors outgrow the blood supply so necrosis is often extensive and foci of calcification are seen which may be identified on X-ray.
- *Microscopy:* Dense sheets of small round cells with dark hyperchromatic nuclei and scanty cytoplasm. Trabecular and nesting formations are common. Well differentiated retinoblastoma cells show a bipolar appearance. Characteristic "Flexner-Wintersteiner rosettes" and fleurettes are seen. Hematoxyphilic deposits in and around blood vessels are seen in necrotic areas similar to "Azzopardi effect"
- *IHC:* IRBP (pho-receptor cell protein), S-antigen (S-Ag), opsin, neuron-specific enolase (NSE), glial fibrillary acidic protein (GFAP), laminin, and vimentin,

JAYPEE BROTHERS

synaptophysin, S100, Leu7, myelin basic protein and p53; high Ki-67, all +ve. CD99 : Negative.

- *Spread:* Invades the optic nerve; extends to the brain; can be carried by subarachnoid fluid ; can invade uveal tract.

Hepatoblastoma

- Accounts for 0.2–5.8% of all malignancies in childhood and 25–45% of all primary hepatic tumors.
- Vast majority occur in patients under 5 years and 66% are seen in the first 2 years of life, primarily in infants.
- One-third of patients have some form of congenital anomaly—hemihypertrophy, cleft palate, talipes, cardiacandrenalmalformations,Beckwith-Wiedemann and Down's syndromes and nephroblastomas. Trisomy of chromosomes 2 and 20 are common. Raised serum and urinary levels of human chorionic gonadotropin (hCG) are observed. Serum levels of α fetoprotein are often elevated.
- *Gross*: Single mass, often very large when detected and may weigh >1000 g, solid and well circumscribed. Cut surface is variegated according to the proportion of its histologic components—brown to green, fibrous or calcified. Often shows areas of necrosis, cystic change and hemorrahge.
- *Microscopy:* Most tumors are composed exclusively of immature hepatocytic elements with both epithelial and mesenchymal components.
  - Epithelial variant may show—embryonic subtype, fetal subtype, or mixtures of both. Fetal component consists of hepatocytes arranged in irregular laminae, two cell thick recapitulating those of fetal liver. Foci of extramedullary hemopoiesis is seen commonly with the fetal pattern. Fetal pattern is associated with a better prognosis.
  - The embryonal component is more immature with a solid pattern of growth but may also exhibit ribbons, rosettes, papillary formations, etc.
  - Others may be composed of small anaplastic cells and still others a cholangiolar pattern with tubules. Some tumors show cells resembling liver cell carcinoma, i.e. a macro-trabecular pattern.
  - Mixed epithelial and mesenchymal elements may be seen in 1/4th of hepatoblastomas.
  - The mesenchymal component is spindle celled or osteoid, rarely cartilage and neural tissue.
  - Rare variants are the teratoid, mucoid and rhabdoid types.

IHC: AFP, hCG, CEA, EMA, hepatic cytokeratins 8 and 18, biliary cytokeratins 7 and 19, α-1 antitrypsin, ferritin, S-100 protein, chromogranin A and NSE in varying proportions.

Cytogenetics: Trisomies 2, 8 and 20.

Spread: It occurs to regional lymph nodes, lung, brain and other organs.

Rhabdomyosarcomas[3,4]

Rhabdomyosarcomas (RMS) is a neoplasm commonly occurring in infants and children and somewhat less frequently in adolescents and young adults. About 2% of tumors are present at birth.

Each of the rhabdomyosarcoma subtypes occurs in a characteristic age group. Embryonal rhabdomyosarcomas (ERMS) and the botryoid and spindle cell subtypes affect mainly children between birth and 15 years of age. On the other hand, alveolar rhabdomyosarcoma tends to affect older patients, with a peak age of 10–25 years.

Males are affected more commonly than females by a ratio of approximately 1.3:1.0, but the male predominance is less pronounced during adolescence and young adulthood and for rhabdomyosarcomas of the alveolar type. Microscopically various histologic subtypes of RMS exist and these may be site specific. The commonest histologic subtype is embryonal and the least common is spindle cell.

The neoplasms occur predominantly in three regions: the head and neck; genitourinary tract; retroperitoneum; and upper and lower extremities. Approximately 5% of RMS arise in the urinary bladder or prostate. It is the most common bladder tumor in children under 10 years of age. Almost all tumors arising in this location are embryonal or botryoid RMS.

Embryonal rhabdomyosarcoma: It mostly affects children younger than 10 years of age (mean age: 7 years), but it also occurs in adolescents and young adults; it is uncommon in patients older than 40 years of age. The most common site of embryonal rhabdomyosarcoma is the head and neck, particularly the orbit and parameninges.

Histologically, varying degrees of cellularity with alternating densely packed, hypercellular areas and loosely textured myxoid areas. Round or spindle-shaped cells with hyperchromatic nuclei and a varying number of differentiated cells with eosinophilic cytoplasm characteristic of rhabdomyoblasts are seen.

JAYPEE BROTHERS

The rhabdomyoblasts range from slender spindle-shaped cells with a small number of peripherally placed myofibrils to large eosinophilic cells with a strap, ribbon, tadpole, or racquet shape and one or two centrally positioned nuclei and prominent nucleoli, with or without cross-striations. The stroma shows matrix containing minimal collagen and varying amounts of myxoid material. ERMS with a prominent degree of cellular pleomorphism ("anaplasia") are rare and, when seen, are difficult to distinguish from adult pleomorphic RMS.

Embryonal rhabdomyosarcoma, botryoid type: Most botryoid rhabdomyosarcomas are found in mucosa-lined hollow organs, such as the nasal cavity, nasopharynx, bile duct, urinary bladder, and vagina. They typically grow into the lumen of the hollow viscus, e.g. Urinary bladder as grape-like, richly mucoid, multinodular or polypoid masses with a broad base that not infrequently causes obstruction of the internal urethral orifice and prostatic urethra.

Microscopically show sparsity of cells and abundance of mucoid stroma, often resulting in a myxoma-like picture. According to the ICR criteria, a "cambium layer," characterized by a subepithelial condensation of tumor cells separated from an intact surface epithelium by a zone of loose stroma, must be present to recognize this variant. The cells range from primitive small cells to cells with clear-cut myoblastic differentiation. Cells with stellate cytoplasmic processes are often prominent. The surface epithelium may be hyperplastic or may undergo squamous changes, sometimes mimicking a carcinoma.

Alveolar rhabdomyosarcoma: It is the second most common subtype, tends to arise at a slightly older age than embryonal, botryoid, and spindle cell rhabdomyosarcomas, with a peak incidence at 10–25 years of age. It has a predilection for the deep soft tissues of the extremities, although the tumor may arise in many other sites, including the head and neck, trunk, perineum, pelvis, and retroperitoneum.

It is composed largely of ill-defined aggregates of poorly differentiated round or oval tumor cells that frequently show central loss of cellular cohesion and formation of irregular "alveolar" spaces. The individual cellular aggregates are separated and surrounded by a framework of dense, frequently hyalinized fibrous septa that surround dilated vascular channels. Characteristically, the cells at the periphery of the alveolar spaces are well preserved and adhere in a single layer to the fibrous septa in a manner somewhat reminiscent of an adenocarcinoma or papillary carcinoma. The cells in the center of the alveolar spaces tend to be more loosely arranged, or "freely floating"; they are often poorly preserved and show evidence of degeneration and necrosis.

Immunohistochemistry: Desmin, Smooth muscle actin, Sarcomeric α-actin, Myogenin and MyoD1 positive.

JAYPEE BROTHERS

SYNOPTIC REPORTING—MINIMUM DATA SETS[5]

NEPHRECTOMY SPECIMEN REPORTING FOR WILMS' TUMOR

Gross

Total nephrectomy ☐ Partial ☐ Portion of kidney ☐ Other ☐
Side: Right ☐ Left ☐ Not specified ☐ Bilateral ☐
Size of kidney with tumor: _____ (length) × _____ × _____ cm.
Location of tumor: Upper pole ☐ Lower pole ☐ Medulla ☐ Other ☐ Not specified ☐
Multicentric: Yes ☐ No ☐

Size of tumor: _____ ×_____×_____cm (largest if multifocal). Cannot be determined

Adrenal attached: Yes ☐ No ☐
Tumor infiltrates the renal capsule: Yes ☐ No ☐
Tumor infiltrates the perirenal tissue/fat ☐
Tumor infiltrates adrenal gland Yes ☐ No ☐
Tumor in the renal veins Yes ☐ No ☐

Cut surface: Variegated homogenous cystic

MICROSCOPY

Presence of tumor: Yes ☐ Benign ☐ Malignant ☐ No ☐

Histological subtype:
Wilm's favorable histology ☐
Wilm's unfavorable histology ☐
Nephrogenic rests present ☐
Nephrogenic rests do not show mitoses ☐
Nephrogenic rests show mitoses ☐

Tumor extent and margins:
- Confined to kidney ☐
- Infiltrates renal capsule ☐
- Infiltrates parenchymal cut margin (in partial nephrectomy): Yes ☐ No ☐
- Infiltrates perirenal fat: Yes ☐ No ☐
- Renal sinus fat: Yes ☐ No ☐
- Renal sinus veins and lymphatics: Yes ☐ No ☐
- Infiltarates Gerota's fascia: Yes ☐ No ☐
- Infiltrates Adrenal gland: Yes ☐ No ☐
- Infiltrates renal vascular cut margin: Yes ☐ No ☐
- Ureteric cut margin: Yes ☐ No ☐
- Peritoneal implants: Yes ☐ No ☐ cannot comment

Lymphovascular invasion: Present ☐ Absent ☐
Renal vein invasion: Yes ☐ No ☐
Other kidney (if sent): Follow same format

Regional lymph nodes:
- No. of nodes examined _____
- No. of nodes involved _____

Distant metastasis:
- Cannot be assessed
- Known, specify site _____

Comment _____
Signature _____ Date _____

National Wilm's tumor study system for staging pediatric renal tumors (NWTS system)

Stage	*Extent*
I	Tumor confined to kidney and completely resectable *Specific criteria:* – Renal capsule not penetrated by tumor - Renal sinus veins and lymphatics not invaded - No lymph nodes or hematogenous spread 11
II	Tumor extends locally outside the kidney but is completely resectable . *Specific criteria:* – Renal capsule is penetrated by tumor – Renal sinus veins or lymphatics invaded – Renal vein contains tumor – Local spillage or biopsy involves only the flank – Specimen margins are free of tumor and no residual tumor remains after surgery – No metastasis

JAYPEE BROTHERS

III There is residual tumor confined to the abdomen without hematogenous spread.
Specific criteria:
- Grossly visible residual tumor in abdomen
- There are tumor implants on the peritoneal surface
- Speminen margins contain tumor
- Abdominal lymph nodes contain tumor

IV There are blood borne metastasis or spread beyond abdomen

V Tumors are present in both kidneys.

REPORTING ON NEUROBLASTOMA RESECTION SPECIMENS

Site of biopsy:
Adrenal ☐ Extra adrenal specify ☐
Other tissue sent ☐ Specify ☐

Gross:
Measurement _____× _____×_____cm

Cut surface:
Variegated ☐
Hemorrhage ☐
Cystic ☐
Solid ☐

Microscopy: Histologic subtype
Undifferentiated neuroblastoma ☐
Poorly differentiated neuroblastoma ☐
Differentiating neuroblastoma ☐
Ganglioneuroblastoma, nodular ☐
Ganglioneuroblastoma, intermixed ☐
Ganglioneuroma maturing ☐
Ganglioneuroma mature ☐
Favorable histology ☐
Unfavorable histology ☐
MKI index _____
Surgical margin involvement : Yes ☐ No ☐
No. of lymph nodes sent _____
No. of lymph nodes involved_____
Comments_____
_____

STAGING OF NEUROBLASTOMA

- Tumor confined to structure or organ of origin.
- Tumor extends in continuity beyond the structure or organ of origin but does not cross the midline; ipsilateral lymph node involvement may or may not be present.
- Tumor extends in continuity beyond the midline with or without bilateral lymph node involvement
- Metastatic disease involves skeleton, viscera, soft tissue or distant lymph nodes.
- Patients who would be classified as stage I or II but have remote disease involving liver, skin or bone marrow (without radiologic evidence of bone involvement).

RETINOBLASTOMA REPORT ON RESECTED SPECIMENS

Specimen type:
- Enucleation ☐
- Limited exenteration ☐
- Complete exenteration
- Other specify _____
- *Laterality:* Right ☐ Left ☐ Both ☐
- Not specified ☐

Specimen size: For enucleation:
- Anterioposterior diameter.....cm
- Horizontal diameter ....cm
- Vertical diameter ....cm
- Length of optic nerve....cm
- Diameter of optic nerve...cm
- Cannot be determined ☐

For exenteration:
- Greatest diameter.....cm
- Additional diameter....cm
- Cannot be determined

Tumor site: Cannot be determined ☐
- Superotemporal quadrant of globe ☐
- Superonasal quadrant of globe ☐
- Inferotemporal quadrant of globe ☐
- Inferonasal quadrant of globe ☐

Tumor extent: Anterior chamber
- Extrascleral extension ☐
- Optic nerve ☐

Tumor diameter after sectioning:
- Cannot be determined ☐
- Base from the cut edge_____mm
- Height from the cut edge_____mm
- Maximum tumor height_____mm
- Distance from anterior edge of tumor to limbus at the cut edge_____mm

JAYPEE BROTHERS

- Distance of posterior margin of tumor base from edge of optic disc____mm

Histologis features: Cannot be determined
- Undifferentiated ☐
- Differentiated ☐
- Homer Wright rosettes ☐
  - Flexner-Wintersteiner rosettes ☐
  - Fleurettes ☐
- Necrotic ☐

Growth pattern: Endophytic ☐
- Exophytic ☐
- Both ☐

Tumor involvement of other ocular structures/other pathology

Cannot be determined ☐
Optic disc ☐
Choroid, minimal (Brush's membrane destroyed by three or more microscopic cell clusters without deeper penetration) ☐

Choroid, massive ☐	Vitreous ☐
Retinal detachment ☐	Vortex vein ☐
Ciliary body ☐	Iris ☐
Lens ☐	Anterior chamber ☐
Angle ☐	Sclera ☐
Cornea ☐	

Extent of optic nerve invasion: None
Not to end of nerve ☐
To cut end of optic nerve ☐

Surgical margins: Cannot be assessed ☐
- Free ☐ Distance from closest resection margin _____

Specify margin _____
Involved ☐ Specify margin_____

pTNM STAGING

pT—Primary Tumor

pTx : Primary tumor cannot be assessed
pT0 : No evidence of primary tumor
pT1 : Tumor confined to retina, vitreous, or subretinal space. No optic nerve or choroidal invasion
pT2 : Minimal invasion of the optic nerve and/or optic coats
pT3 : Significant invasion of the optic nerve and/or optic coats
pT4 : Extraocular tumor extension that includes any of the following: invasion of the optic nerve to the line of resection; invasion of orbit through the sclera; extension both anteriorly or posteriorly through the orbit; extension into brain extension to chiasma; extension into brain beyond the chiasma.

pN—Regional Lymph Nodes

pNX : Cannot be assessed
pN0 : No Regional lymph node metastasis
pN1 : Regional lymph node metastasis

pM—Distance metastasis

pMX : Distant metastasis cannot be assessed
pM0 : No distant metastasis
pM1a : Bone marrow
pM1b : Distant metastasis

Signature_____
Date_____

- *Reporting of hepatoblastoma:* As per section in liver.

REFERENCES

1. Shariff S. Laboratory techniques in Surgical Pathology. Prism Book Pvt. Ltd, Benguluru, Kolkata, Hyderabad, Mumbai; 1999.
2. Rosai JR. Ackerman's Surgical Pathology (1 & 2 Vols), 10th edn. New Delhi: Reed Elsevier India Private Limited; 2011.
3. Fletcher CDM. Diagnostic Histopathology of Tumors (Vol 1), 3rd edn. Elsevier. Philadelphia; 2007.
4. Weiss WS, Goldblum JR. Enzinger and Weiss's Soft tissue tumours (Chapter 21). Mosby Elsevier, Philadelphia, 5th edn; 2008.
5. Sobin LH, Gospodarowicz MK, Wittekind Ch. UICC International Union against cancer. TNM Classification of Malignant Tumors, 7th edn. Wiley-Blackwell, A John Wiley & sons Ltd Publication; 2009.

JAYPEE BROTHERS

for detailed information on pathology books, visit our website www.jaypeebrothers.com, for detailed information on pathology books, visit our website www.jaypeebrot

Fundamentals of SURGICAL PATHOLOGY

Objectives of Fundamentals of Surgical Pathology

- To give the reporting surgical pathologist a comprehensive knowledge of the anatomic pathology in disease, the salient microscopic features, immunohistochemistry as an aid in diagnostic pathology and essentials of delivering the format of reporting to the clinician
- To place before all surgical pathologists the practical difficulties in the reporting of lesions with the help of the author's vast experience in surgical pathology in dealing with "Hands on Bench Problems" encountered routinely.

Highlights

- Gross and lucid descriptions of lesions in pathology (both simple and complex)
- Diagnostic and salient microscopic features essential in arriving at a diagnosis
- Details on differential diagnosis in each lesion and ability to differentiate one from the other in the gray zone areas
- Importance of immunohistochemistry as an aid in diagnosis—it is correlation in the context of morphology and not at face value of a marker being positive or negative
- Synoptic reporting and the importance of a planned format in reporting—emphasis on point-wise completion, e.g. resection margin involvement, grade and stage of tumors in reports
- Caters to common and complex routine reporting in the Indian subcontinent.

Comparison with the First Edition

The first edition of this book has been very well received as a text and hands on manual by all surgical pathologists. The entire text has been updated with current new concepts, including all revised WHO classifications on all organ systems. New chapters have been added—cardiovascular, central nervous system and immunohistochemistry.

The entire book is of immense help not only to all postgraduates but also to all reporting surgical pathologists within and outside the country.

Shameem Shariff MBBS MD (Pathology) PhD (Pathology) was Formerly Professor and Head, Department of Pathology, St John's Medical College and Hospital and MVJ Medical College and Research Hospital, Bengaluru, Karnataka, India. She graduated from the Government Medical College, Bellary, Karnataka and postgraduation in Pathology from Bangalore Medical College, Bengaluru in the year 1981. In 1995, she was awarded PhD in Pathology. She served St. John's Medical College, Bengaluru for 20 years, from 1982 to 2002. She served as a Senior Consultant in the Ministry of Health, University Hospitals in Bahrain and Sultanate of Oman from 2002 to 2008. She has several awards to her credit—in 1984 the Khanolkar Award (young scientist award) by the Indian Association of Pathologists and Microbiologists (IAPM) for the best research paper of the year, at the Annual Conference of the IAPM; in 1996 the Excellence in Teaching Award, and in 1998 the Ernest Fernandez Award. She has presented papers at international conferences—the 15th International Conference of the International Academy of Pathologists held at Miami, Florida, USA in 1984 and the 11th International Conference of Tropical Medicine and Malaria, Alberta, Canada. In 1987, she trained at the prestigious Memorial Sloan Kettering Cancer Center, New York, USA and at the Memorial Medical Center, Long Beach, California, USA on an Endocurie Foundation Travel Fellowship. Her name featured among the cytologists of the country in the manual "Cytologists of repute in the Country" published at the Annual Cytology Conference in 2009. She was Ex-Chairman, Board of Studies for Paraclinical Subjects (postgraduates) at Rajiv Gandhi University of Health Sciences (RGUHS). She has more than 110 publications in national and international journals to her credit and has authored several textbooks and chapters in textbooks.

Available at all medical bookstores or buy online at www.jaypeebrothers.com



JAYPEE BROTHERS Medical Publishers (P) Ltd.
www.jaypeebrothers.com

Join us on facebook.com/JaypeeMedicalPublishers

Shelving Recommendation
PATHOLOGY

