visit our website **www.jaypeebrothers.com,** for detailed information on endocrinology books, visit our website **www.jaypeebrothers.com**

Celebrating 50 YEARS
Passion, Quality and Innovation in Healthcare Publishing

Case Studies in Diabetology & Endocrinology





Editors
Sanjay Chatterjee
Sudip Chatterjee

JAYPEE

CONTENTS

SECTION 1: ADRENAL

CASE 1: **Adrenal Histoplasmosis** 1
Tapas Chandra Das, Neeraj Sinha, Partha Sarathi Choudhury, Anirban Sinha, Animesh Maiti, Asish Kumar Basu

CASE 2: **Pheochromocytoma without Hypertension** 3
Saurav Shishir, Chhavi Agrawal, Partha Sarathi Choudhury, Partha Pratim Chakraborty, Anirban Sinha, Animesh Maiti, Asish Kumar Basu

CASE 3: **A 32-year-old Man with Hypertension** 5
JJ Mukherjee

CASE 4: **Giddiness and Near-syncope Post Pacemaker Implantation—Not Always Cardiac or Neurogenic** 10
Soumyabrata Roy Chaudhuri

CASE 5: **Triple A Syndrome** 13
Rana Bhattacharjee, Pradip Mukhopadhyay, Sujoy Ghosh

CASE 6: **Evolving Primary Adrenal Insufficiency** 14
Rana Bhattacharjee, Ajitesh Roy, Pradip Mukhopadhyay, Sujoy Ghosh

SECTION 2: BONES

CASE 1: **Pseudofracture (Looser's Zone) with Subsequent Low Trauma Fracture: Under-recognized but not Uncommon Presentation of Distal Renal Tubular Acidosis** 17
Subhankar Chowdhury, Partha Pratim Chakraborty

CASE 2: **Refractory Rickets due to Fanconi's Syndrome Secondary to Wilson's Disease** 20
Chitra Selvan, Rana Bhattacharjee, Pradip Mukhopadhyay, Sujoy Ghosh

SECTION 3: DEVELOPMENT

CASE 1: **A Short Girl with Delayed Puberty** 23
Anirban Mazumdar

SECTION 4: DIABETES

CASE 1: **A Young Ketosis Prone Diabetic** 27
Anirban Mazumdar

CASE 2: **Common Problem...Where Lies the Solution?** **30**
Biswajit Ghoshdastidar

CASE 3: **A Diabetic with Infected Hand** **33**
Anirban Mazumdar

CASE 4: **Advanced Diabetic Nephropathy without Diabetic Retinopathy** **35**
Debmalya Sanyal

CASE 5: **Diabetes Mellitus** **38**
Debasis Maji

CASE 6: **Diabetes and the Breast** **41**
Kalyan Kumar Gangopadhyay

CASE 7: **Cellulitis Mimic in Diabetes** **44**
Kalyan Kumar Gangopadhyay

CASE 8: **Heart Failure as a Presentation of Diabetes** **46**
Nilanjan Sengupta, Sajal Kamat

CASE 9: **Antihyperglycemic Agents and Hospitalization for Heart Failure: A Practical Issue** **50**
Samit Ghosal

CASE 10: **Modern Management of Type 2 Diabetes Mellitus: Making Sense of the Multiple Options** **54**
Samit Ghosal

CASE 11: **Approach to a Patient of Type 2 Diabetes Mellitus with Unexplained Hyperglycemic State** **57**
Sanjay Chatterjee

CASE 12: **Fibrocalculus Pancreatic Diabetes Presenting as Pancreatic Adenocarcinoma** **60**
Satinath Mukhopadhyay, Partha Pratim Chakraborty

CASE 13: **Myonecrosis: An Unusual Microvascular Complication of Diabetes** **63**
Satinath Mukhopadhyay, Partha Pratim Chakraborty

CASE 14: **Cystic Fibrosis-related Diabetes** **66**
Satinath Mukhopadhyay, Partha Pratim Chakraborty

CASE 15: **A Patient with Late Onset Diabetes in Adult** **67**
Satinath Mukhopadhyay, Partha Pratim Chakraborty

CASE 16: **Double Diabetes—But Differently Double** **69**
Soumyabrata Roy Chaudhuri

CASE 17: **Diabetes Mellitus as Presenting Manifestation of Acromegaly due to Growth Hormone-secreting Pituitary Macroadenoma** **72**
Subhankar Chowdhury, Partha Pratim Chakraborty

CASE 18: **Diabetic Truncal Radiculoneuropathy: A Completely Reversible Form of Diabetic Neuropathy** **75**
Subhankar Chowdhury, Partha Pratim Chakraborty

CASE 19: Acute Gastric Dilatation as Presenting Manifestation of Diabetic Ketoacidosis 77
Subhankar Chowdhury, Partha Pratim Chakraborty

CASE 20: A Patient where Continuous Glucose Monitoring System Helped 79
Sudip Chatterjee

CASE 21: A Patient with Interesting Problems 82
Sudip Chatterjee

SECTION 5: DIABETIC FOOT

CASE 1: A Case of Acute Charcot's Joint 84
Debmalya Sanyal

CASE 2: A Case of Charcot Foot 86
Ghanshyam Goyal

CASE 3: Ischemic Diabetic Foot 90
Ghanshyam Goyal

CASE 4: A Case of Diabetic Foot Infection 93
Ghanshyam Goyal

CASE 5: A Case of Neuropathic Diabetic Foot 96
Ghanshyam Goyal

SECTION 6: GENETICS

CASE 1: Turner Syndrome with Hyperthyroidism 100
Anirban Mazumdar

CASE 2: Hypogonadal Man with Leg Ulcers 102
Anirban Mazumdar

CASE 3: An Obese Hyperactive Child 104
Anirban Mazumdar

CASE 4: A Boy with Macroorchidism 107
Anirban Mazumdar

SECTION 7: METABOLISM

CASE 1: Central Venous Sinus Thrombosis in a Type 2 Diabetes Mellitus Patient with Marked Hypertriglyceridemia 110
Debmalya Sanyal

CASE 2: To be Taken with A Pinch of Salt 112
Kalyan Kumar Gangopadhyay

CASE 3: Familial Partial Lipodystrophy Masquerading as Polycystic Ovarian Syndrome: Rare or Overlooked? 115
Subhankar Chowdhury, Partha Pratim Chakraborty

SECTION 8: OVARIES

CASE 1: Polycystic Ovarian Syndrome: A Common Problem 120
Rahin Mahata, Chandan Mishra, Partha Sarathi Choudhury, Anirban Sinha, Animesh Maiti, Asish Kumar Basu

SECTION 9: PANCREAS

CASE 1: Hypoglycemia Workup 123
Binayak Sinha

SECTION 10: PARATHYROID

CASE 1: Brown Tumor of the Lower Jaw as the First Manifestation of Primary Hyperparathyroidism: A Case Report 127
Subir Ray

CASE 2: An Interesting Case of Acute Confusional State 129
Sujoy Majumdar

SECTION 11: PITUITARY

CASE 1: Uncontrolled Hyperglycemia–Think beyond Glycemia 134
Animesh Maiti, Anirban Sinha, Asish Kumar Basu, Partha Sarathi Choudhury, Saurav Shishir, Chhavi Agrawal

CASE 2: Hot Flashes in Men: Rare Presentation of a Rare Disorder 136
Biswajit Ghoshdastidar

CASE 3: Snake and the Pituitary 139
Kalyan Kumar Gangopadhyay

CASE 4: Prolactinoma: A Rare and Treatable Cause of Male Infertility 142
Nilanjan Sengupta, Rahul Valsaraj

CASE 5: Secondary Hypothyroidism: Easy to Miss 144
Sudip Chatterjee

SECTION 12: THYROID

CASE 1: Enlarged Pituitary in Primary Hypothyroidism 146
Ajitesh Roy

CASE 2: Thyroid Ophthalmopathy 149
Sayan Ghosh, Somnath Raghuvanshi, Partha Sarathi Choudhury, Anirban Sinha, Animesh Maiti, Asish Kumar Basu

CASE 3: Graves' Disease with Ocular Myasthenia Gravis 151
Anirban Mazumdar

CASE 4: Gestational Thyrotoxicosis 154
Binayak Sinha

CASE 5: **A Case of Thyrotoxic Periodic Paralysis due to Painless Thyroiditis** **156**
Debmalya Sanyal

CASE 6: **Myxedema Coma: Rare but Dangerous** **158**
Soumyabrata Roy Chaudhuri

CASE 7: **An Unusual Patient with Thyroiditis** **162**
Sudip Chatterjee

CASE 8: **A Hyperthyroid Child** **165**
Sudip Chatterjee

CASE 9: **Gynecomastia: An Unusual Initial Presentation of Thyrotoxicosis** **166**
Rana Bhattacharjee, Ajitesh Roy, Pradip Mukhopadhyay, Sujoy Ghosh

CASE 10: **Two Interesting Cases of Raised Thyroid-stimulating Hormone** **168**
Sujoy Majumdar

Index **171**

SECTION 4

Diabetes

CASE 1 A Young Ketosis Prone Diabetic

Anirban Mazumdar

CASE HISTORY

A 19-year-old girl presented to the outpatient clinic because of recent detection of high blood sugar. Her past medical history was unremarkable and her mother and maternal grandmother were diabetic. At the time of her diagnosis, she weighed 65 kg with a body mass index (BMI) of 29 kg/m^2. Physical examination showed acanthosis nigricans; rest of the examination was unremarkable.

Biochemical investigations are summarized in Table 1. Fasting C-peptide level was 3.6 ng/mL indicating adequate beta-cell functional reserve. All these tests supported the diagnosis of type 2 diabetes mellitus (T2DM). She was initially managed with diet, exercise and metformin and 4 months later, her blood sugar levels were consistently controlled with metformin only.

TABLE 1: Biochemical investigation.

Test	Value	Normal range
Fasting plasma glucose	180 mg/dL	70–99
Postprandial plasma glucose	256 mg/dL	70–139
Glycosylated hemoglobin	8.4%	4–5.6
Serum creatinine	0.76 mg/dL	0.6–1.2
Thyroid function	Normal	–
Fasting C-peptide level	3.6 ng/mL	0.51–2.72

She did well until 1 week ago, when she noted polyuria, polydipsia and rising finger-stick glucose values, higher than 300 mg/dL. She was presented in the emergency room of the hospital with vomiting, symptoms of dehydration and altered mental status. She denied any fever, chills, cough, abdominal pain or dysuria. Laboratory tests revealed severe hyperglycemia (random 567 mg/dL) with no evidence of acute infection, renal or liver dysfunction. The arterial pH was 7.1 (normal 7.35–7.45), anion gap was high, serum bicarbonate (8 mmol/L) was low, urine was positive for ketones (acetoacetate) and she was diagnosed with diabetic ketoacidosis (DKA) (Fig. 1). During her hospital stay, the fasting C-peptide level was rechecked and it was undetectable (less than 0.5 ng/mL). She received standard treatment for DKA with IV fluids and insulin and recovered uneventfully. She was discharged on the 5th hospital day on a basal-bolus

JAYPEE BROTHERS

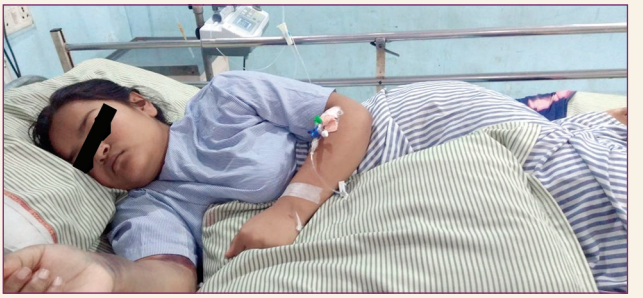

FIG. 1: Young and obese patient with diabetic ketoacidosis.

insulin regimen. She remained stable on basal-bolus regimen, but gained 3 kg weight in 4 months. Beta-cell functional reserve was reassessed and fasting C-peptide level had come up to 2.8 ng/mL. She was further evaluated for autoantibodies to glutamic acid decarboxylase (GAD) 65 and islet tyrosine phosphatase 2 antibodies (IA-A2) and both were absent. An attempt was made to switch her to oral antidiabetic agents in lieu of her repeat C-peptide level of 2.8 ng/mL. She was started on glimiperide 2 mg daily and metformin 1,000 mg twice daily and insulin was gradually discontinued. Over next 6 months glimiperide was also stopped. For the last 6 months she is on metformin 1,000 mg twice daily only without any further episode of DKA and her last HbA1c 1 month ago was 6.8%.

DISCUSSION

Diabetic ketoacidosis was once considered a hallmark feature of type 1 diabetes mellitus (T1DM) and was used in clinical practice to differentiate it from the more common T2DM. However, some patients present with DKA or unprovoked ketosis, despite lacking the classic autoimmune markers of T1DM. These ketosis prone individuals with negative autoantibodies are frequently associated with Human leukocyte antigen (HLA) class II DRB1*03 and/or DRB1*04 and this is commonly referred to as Flatbush diabetes mellitus.

This 19-year-old obese girl with positive family history of diabetes had no evidence of beta cell autoimmunity, had signs of insulin resistance (acanthosis nigricans). She was initially managed with oral hypoglycemic agents and presented with DKA. She did fine on an attempt to switch her to oral agents 4 months after recovery from DKA when beta cells had recovered from glucose toxicity. She was diagnosed with flatbush diabetes mellitus. However, we could not check HLA typing in our medical set-up.

Flatbush diabetes is a unique form of diabetes commonly described among African-American patients with DKA as the initial manifestation without any identifiable precipitating cause for DKA. This atypical presentation has also been reported in Asian countries including India and is being recognized increasingly worldwide. The pathophysiologic mechanisms involved are unknown. Severe impairment of both insulin secretion and insulin action are the most dominating pathophysiologies at presentation. The relation between this transient severe impairment of insulin secretion and HLA class II antigen is largely unknown. Aggressive diabetes management improve both beta-cell function and insulin sensitivity leading to discontinuation of insulin therapy within a few months as demonstrated in our case.

JAYPEE BROTHERS

TABLE 2: Classification of ketosis-prone diabetes.

GAD antibodies or IA-2 autoantibodies	β-cell functional reserve	HLA antigen	Diagnosis
A+	B–	HLA-DR3 and/or HLA-DR4	KPD type 1A: Autoimmune Type 1 diabetes
A–	B–	Nil	KPD type 1B: Nonautoimmune Type 1 diabetes
A+	B+	HLA-DR3	KPD type 2A: LADA
A–	B+	HLA-DR3 and HLA-DR4	KPD type 2B: Flatbush diabetes

(GAD: glutamic acid decarboxylase; HLA: human leukocyte antigen; IA-A2: islet tyrosine phosphatase 2 antibodies; KPD: ketosis-prone diabetes; LADA: late onset autoimmune diabetes in adults)

Ketosis-prone diabetes (KPD) is heterogeneous and Flatbush diabetes is one variety of KPD. They are classified into four groups (Table 2), based on the presence of GAD antibodies or IA-2 autoantibodies (A+ or A–) and β-cell functional reserve/C-peptide response (β+ or β–). KPD type 1A is the classic autoimmune T1DM accompanied by permanent and complete beta cell failure along with serologic markers of islets cell autoimmunity (A+, B–). KPD type 1B is the nonautoimmune variety T1DM with permanent and complete beta-cell failure, but lacking the serologic markers of islet cell autoimmunity (A–, B–). KPD type 2A is the late onset autoimmune diabetes in adults (LADA) with preserved beta-cell function at the time of diagnosis and has serologic markers of islet cell autoimmunity (A+, B+). KPD type 2B is flatbush diabetes where beta-cell function is preserved and serologic markers of islet cell autoimmunity are lacking (A–, B+). Hence, KPD comprises at least four etiologically distinct subtypes and is separable by GAD/IA-2 autoantibodies, HLA genotype and C-peptide response (β-cell reserve). The cause of β-cell dysfunction that leads to DKA among the flatbush diabetes and nonautoimmune T1DM is largely unknown and one or multiple novel, nonautoimmune mechanisms are likely to underlie the cause.

Take Home Message

- ***Evaluation of autoantibodies and C-peptide in young diabetic patients are often required to categorize the type of diabetes.***

SUGGESTED READING

1. Lebovitz HE, Banerji MA. Ketosis-Prone Diabetes (Flatbush Diabetes): an Emerging Worldwide Clinically Important Entity. Curr Diab Rep. 2018;18(11):120.
2. Maldonado M, Hampe CS, Gaur LK. Ketosis-prone diabetes: dissection of a heterogeneous syndrome using an immunogenetic and beta-cell functional classification, prospective analysis, and clinical outcomes. J Clin Endocrinol Metab. 2003;88:5090-8.

JAYPEE BROTHERS

CASE 2 Common Problem...Where Lies the Solution?

Biswajit Ghoshdastidar

CASE HISTORY

A 78-year-old female, known type 2 diabetes mellitus with past history NHL (non-Hodgkin's lymphoma-received chemotherapy and six cycles of radiotherapy), was admitted with sudden change in behavior associated with poor glycemic control.

General and systemic examination was unremarkable. However, she had profound hallucinatory and delusional symptoms and was difficult to manage in the ward. Routine hematological and biochemistry ruled out hyponatremia, hypercalcemia and sepsis or hepatic encephalopathy. Contrast-enhanced CT brain ruled out any NHL recurrence and revealed "age-related cerebral atrophy", which obviously does not explain her symptoms. Psychiatric assessment revealed acute psychosis in the background of severe depression and psychotropic medication was started. Response was dramatic and her orientation returned completely and went home with a reasonably clear state of mind.

Following is her inpatients glycemic profile with HbA1c as high as 16% (Tables 1 and 2).

She had been on glimepiride 2 mg and metformin 1,000 mg daily at home. Blood glucose values in-patients ranged from 300 mg/dL to 550 mg/dL requiring minimal dose of insulin during first 2 days, which was managed with supplemental insulin; however, her glycemic control rapidly returned to normal level requiring minimal dose of insulin in the controlled hospital environment. She went home after 1 week with a gliptin and metformin and advice of home monitoring of blood glucose. Her husband died 2 years

TABLE 1: Poor glycemic control (the only striking feature).

Test	Value	Normal range
SGOT (UV with P5P) V	24 U/L	14–36
SGPT (UV with P5P) V	26 U/L	9–52
Alkaline phosphatase (PNPP) V	134 U/L	38–126
Total bilirubin (DDS) V	0.6 mg/dL	0.2–1.3
Total protien (BEP) V	7.3 mg/dL	6.3–8.2
Albumin (BCG) V	4.2 mg/dL	3.5–6.0
Globulin (Calculated) V	3.1 mg/dL	2.8–3.2
Ratio (A:G) (Calculated) V	1.38	–
Gamma G T (GGPN) V	11 U/L	12–43
Urea (Urease) V	28.48 mg/dL	14.98–36.38
Creatinine (IFCC) V	0.92 mg/dL	0.52–1.04
Uric acid (Uricase) V	4.31 mg/dL	2.5–6.2
LDH total (L>P) V	175 µL	120–246
Glycosylated hemoglobin	16.0%	<6.0 nondiabetic <7.0 well controlled >8.0 poor controlled

JAYPEE BROTHERS

ago and she has been living alone since then. She has a daughter, living close by, but too tied up with her own family and visits her only occasionally. She reluctantly agreed to visit her mother once a week to check her blood sugar.

Now it is obvious that the high HbA1c is a reflection of her completely erratic lifestyle and withdrawal of antidiabetic medication for many months, which remained undetected because of very poor social support and perhaps inadequate awareness about mental health among healthcare providers and the caregivers. With a proper infrastructure, this unfortunate situation leading to unnecessary hospitalization could have been prevented.

TABLE 2: Rapid restoration of blood glucose level in hospital environment even without insulin at the end.

Date	Time	Capillary blood glucose (mg/dL)
24/01/19	2 PM	308
	5 PM	292
	7 PM	558
	10 PM	338
25/01/19	7 PM	125
	12 PM	80
	2 PM	110
	7 PM	120
	10 PM	140
26/01/19	12:30 AM	67
	2 AM	124
	5 AM	90
	7 PM	155
	12 PM	125
	7 PM	206
	10 PM	272
27/01/19	2 AM	152
	5 AM	142
	7 PM	179
	12 PM	198

DISCUSSION

Psychiatric illnesses among diabetic subjects are not uncommon and pose a special challenge to physicians, not only in resource-deprived countries but in developed world too, in community as well as hospital in-patient mainly due to lack of structured training in the diabetes team and poor linkage with psychiatry team.

British psychiatrists and diabetes societies have drawn up a joint guideline (Diabetes UK Position Statement) in 2018 for managing diabetes with psychiatrist

JAYPEE BROTHERS

disorder in in-patients settings (www.diabetes.org.uk/joint-british-diabetis-society and http://abcd.care/joint-british-diabetis-society-jbds-inpatient-care-group). This guideline, interestingly has incorporated a few community based preventive management as well. Some of the points are being highlighted here:

1. *Older people (>65 years)*: All with diabetes mellitus should be screened and be assessed for cognitive impairment, depression, psychosis and alcohol use, if there are concerns that such conditions may hinder diabetes self-management or may have contributed to the hospital admission
2. All psychiatric patients in community should be screened for diabetes
3. All psychiatric patients with known diabetes should have medicines to be reviewed to ensure use of antidiabetics with low risk of hypoglycemia. Those requiring insulin should have doses regularly reviewed
4. *Dementia care*:

Four-step approach			
Proactive screening for diabetes	Symptom alleviation + assessment of complication	Risk minimization	Palliative care approach in advance dementia

5. *Diabetes care*:

Four-step approach			
Increase awareness and screening for dementia	Managing cognitive deficit	Minimize therapy risk	Palliative care approach in advance dementia

6. All diabetic ketoacidosis should be screened for psychiatric disorder (using formal ICD-10) and also psychological distress
7. Training and educational needs of caregivers in the management of diabetes and dementia
8. *Inpatients in acute hospital setting*:

Three-step approach		
All DKA episodes	Any evidence of self-herm	Multiple comorbidities
↓	↓	↓
Screen for psychological factors	1. Screen for suicidal ideation 2. Supervise self-administration of insulin	Multidisciplinary team meeting to support self-management and care
↓		
Psychiatric referrals where cause not explained by medical factors		

9. *Substance misuse and learning disability*: They have higher risk of amputation and diabetes related complication

Three-step approach		
Create a registry	Monitor glycosylated hemoglobin, blood pressure, dyslipidemia	Weigh benefit of psychotropic medication against the risk of obesity

10. Eating disorder and type 1 diabetes mellitus—A very complex problem.

JAYPEE BROTHERS

Research and piloting of innovations in models of care are needed to improve care for this group.

Take Home Message

- ***An integrated mind–body approach to diabetes (both inpatients and outpatients) within the constraints of economic and manpower resource is a need of the hour in our country. A special task force should be employed to generate a country (India) specific guideline and raise awareness among the healthcare providers.***

SUGGESTED READING

1. Schmidt CB, Potter van Loon BJ, Vergouwen ACM, et al. Systematic review and meta-analysis of psychological interventions in people with diabetes and elevated diabetes-distress. Diabet Med. 2018;35:1157-72.
2. Price HC, Ismail K. Royal College of Psychiatrists Liaison Faculty & Joint British Diabetes Societies (JBDS): guidelines for the management of diabetes in adults and children with psychiatric disorders in inpatient settings. Diabet Med. 2018;35:997-1004.

CASE 3 A Diabetic with Infected Hand

Anirban Mazumdar

CASE HISTORY

A 46-year-old man with recently detected diabetes, presented with painful gangrene in his left thumb (Figs. 1 and 2). A needle had pricked his thumb 7 days ago. He had no history suggestive of peripheral neuropathy and all modalities of sensation in both upper and lower limbs were intact. He had no intermittent claudication or ulcers in feet. He was a nonsmoker and not an intravenous drug abuser. He was an occasional drinker for past 5 years. On presentation at our hospital, he was normotensive and hemodynamically stable with normal radial pulse on both sides. He had very high (580 mg/dL) capillary plasma glucose during presentation.

The following evaluations were done at the time of presentation (Table 1).



FIG. 1: Ulceration and gangrene in left thumb.

JAYPEE BROTHERS

He underwent aggressive debridement and surgical amputation of the thumb under cover of intravenous antibiotics (ceftriaxone 1 g 12 hourly and metronidazole 500 mg 8 hourly) and insulin. Culture of debrided tissue revealed *Staphylococcus aureus*, *Klebsiella pneumonia* and *Pseudomonas aeruginosa* strain. The wound healed gradually over 2 weeks time with proper sensitive antibiotics and insulin therapy.



FIG. 2: Gangrene in left thumb with spreading inflammation proximally and unaffected right hand.

TABLE 1: Laboratory parameters at the time of presentation.

Investigations	Results	Normal range
Hemoglobin	11.7 g/dL	12–16
Total leukocyte count	21,700/cumm	3,500–11,000
Platelet	320,000/cumm	150,000–450,000
Erythrocyte sedimentation rate	63 mm/h	0–22
C-reactive protein	38 mg/L	Below 3.0
Fasting plasma glucose	267 mg/dL	70–99
Postprandial plasma glucose	549 mg/dL	70–139
Glycosylated hemoglobin	11.7%	3.6–5.6
Serum creatinine	0.8 mg/dL	0.6–1.2
Liver function test	Normal	
Immunofluorescent antinuclear antibody	Negative	Less than or equal to 1:40
Rheumatoid factor	6.5 IU/mL	Less than 15
Arterial doppler study (both upper and lower limbs)	Normal	
Urine routine	Glucose: present RBC: absent	
X-ray	No bony abnormality	

JAYPEE BROTHERS

DISCUSSION

Infection and gangrene in diabetics commonly involve lower limbs and hand infection is less recognized than foot infections. Hand involvement may be due to associated systemic sclerosis, trauma, connective tissue disorders, vasculitic disorders, as a part of tropical diabetes hand syndrome (TDHS) but rarely from upper limb arterio-occlusive

disease as a macrovascular complication of diabetes. Normal renal function with absent red blood cells in urine, normal liver function test and normal platelet count are indicative of lack of systemic involvement in our case. Absent rheumatoid factor and negative immunofluorescent antinuclear antibody (FANA) are suggestive of absence of connective tissue disorders. Arterial Doppler study was done to evaluate any upper limb arterio-occulsive disease. The hand infection and gangrene in this diabetic subject was without any evidence of upper limb arterio-occulsive disease, systemic sclerosis, connective tissue disorders or vasculitic disorders. This presentation of diabetic hand is a rare clinical presentation and known as TDHS.

The TDHS is a specific acute symptom complex found in diabetic patients in tropics. It usually follows minor trauma to the hand and leads to a fulminant hand sepsis with gangrene, as seen in our case. The antecedent minor trauma is often as trivial as scratches or insect bites and presentation to the hospital is often delayed due to the unawareness of the potential seriousness. The severe consequences of TDHS are amputation, permanent disability and death. Immediate appropriate antimicrobial therapy is the key to success. The swab cultures yield polymicrobial flora in the majority (probably because of contamination) whereas culture of tissue biopsy specimens mostly yield a single bacterial species and thus is a better approach. However, even culture of tissue biopsy yielded polymicrobial flora in our case and required combined antibiotic therapy. The infection is often more extensive than suspected and prompt aggressive wound management with incision, debridement and drainage of the wound is required. Observation, local wound care and oral antibiotic therapy are not acceptable approach in TDHS. Through the majority of reported cases have been from various parts of the African continent, TDHS has been reported among patients in India also. Early recognition by patients, prompt medical attention and proper glycemic control might reduce the disability and death from this condition.

Take Home Message

- ***A minor trauma to the hand of a diabetic may lead to a progressive fulminant hand sepsis with gangrene.***

SUGGESTED READING

1. Abbas ZG, Archibald LK. Tropical diabetic hand syndrome. Epidemiology, pathogenesis, and management. Am J Clin Dermatol. 2005;6(1):21-8.
2. Nthumba P, Cavadas PC, Landin L. The tropical diabetic hand syndrome: a surgical perspective. Ann Plast Surg. 2013;70(1):42-6.

CASE 4 Advanced Diabetic Nephropathy without Diabetic Retinopathy

Debmalya Sanyal

CASE HISTORY

A 40-year-old male from Bangladesh with hypertension (HTN) and end-stage renal disease (ESRD) due to chronic glomerulonephritis underwent renal allograft

JAYPEE BROTHERS

transplantation. The patient developed new onset diabetes after transplantation (NODAT). He had hypertension and was on multiple antihypertensive drugs. He had diabetic peripheral neuropathy (DPN). The patient had a poor follow-up, 7 years later his eGFR dropped to 38 with ACR of 178. Renal biopsy of transplanted kidney showed classic nodular glomerulosclerosis (KW lesion) indicating diabetic nephropathy. Diabetes was poorly controlled with HbA1c of 10.2; uncontrolled HTN—176/100, FBS—200, PPBS—289, eGFR—11, ACR—2534, TC—300, LDL—140, 1 year later—ESRD—he had repeat renal allograft transplantation. He had no evidence of diabetic retinopathy (up to two microaneurysms in each side) on direct and indirect ophthalmoscopic examination. Immediate preoperative fundal photograph (Figs. 1 and 2) showed no evidence of diabetic retinopathy (DR). The patient's father died of chronic kidney disease due to diabetes without any retinopathy.

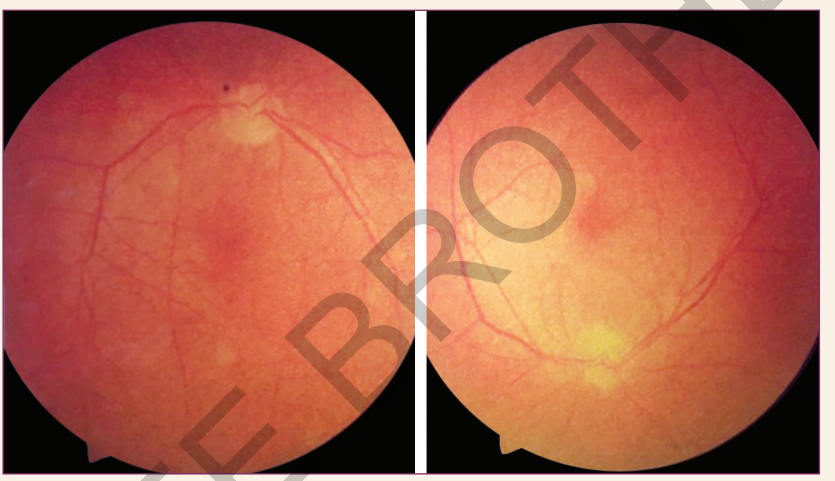

FIG. 1: Fundal photograph showing no evidence of diabetic retinopathy.

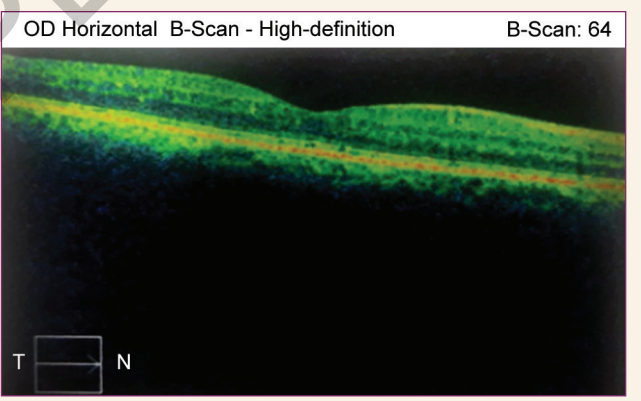

FIG. 2: OCT: no abnormality.

JAYPEE BROTHERS

DISCUSSION

There is generally a concordance between eye and renal complications in patients with DM. Though some studies have demonstrated the presence of severe retinopathy without nephropathy, the reverse, i.e. overt nephropathy without retinopathy is rare. Renal retinal relationship in type 2 diabetes mellitus (T2DM) may not be helpful for clinical diagnosis of DN. One-third of T2DM patients with renal biopsy—demonstrated diabetic glomerulopathy do not have retinopathy. DN found in 50% of patients without DR and lack of retinopathy is a poor predictor of nondiabetic kidney disease. In a study, advanced nephropathy was present in 5 of the 122 (4.1%) patients without retinopathy and no special clinical features distinguished the patients who were regarded as having possible advanced nephropathy without retinopathy. For patients with only DR, incidence increased as DM duration increased, for DR and overt nephropathy incidence appeared to be closely related to levels of HbA1c. The Atherosclerosis Risk in Communities (ARIC) Study showed that poor glycemic control in diabetes increase risk of incident CKD even in absence of albuminuria and retinopathy. Visit-to-visit systolic blood pressure variability is an independent predictor of development and progression of DN, but not retinopathy, in T2DM patients. Recent studies demonstrate that an insertion/deletion of polymorphism of different genes is associated with diabetic complications. Genotype II of the angiotensin-converting enzyme gene is a marker for a decreased risk of DN but not for DR. In Chinese subjects, XbaI (2) allele of *GLUT1* gene might be a genetic marker of noninsulin-dependent diabetes mellitus with DN, and this genetic susceptibility is independent of retinopathy.

Take Home Message

- ***There is well-recognized association between retinopathy and nephropathy, in which nephropathy without retinopathy is rare but retinopathy without nephropathy is common. The standard medical opinion is that DN in the absence of DR should trigger a search for nondiabetic renal disease. It is generally recognized that DR can exist in the absence of DN, but DN, especially ESRD is almost always associated with DR. The fact that microvascular complications in retina and kidney can occur in isolation suggest the existence of specific organ-related pathogenetic factors. Microvascular complications of the kidney do not always spillover to the retina. This suggests that the etiopathogenesis of the two complications are distinct from each other. It is also possible that some individuals with DN and ESRD are genetically protected from DR. Thus, there can be discordance between retinopathy and nephropathy may be present independent of each other and all clinicians should be actively vigilant about independent existence of each complications of diabetes.***

SUGGESTED READING

1. Kanauchi M, Kawano T, Uyama H, Shiiki H, Dohi K. Discordance between retinopathy and nephropathy in type 2 diabetes. Nephron. 1998;80:171-4.
2. Marre M, Bernadet P, Gallois Y, et al. Relationships between angiotensin I converting enzyme gene polymorphism, plasma levels, and diabetic retinal and renal complications. Diabetes. 1994;43(3):384-8.
3. Sanyal D, Chatterjee S. Advanced diabetic nephropathy with "Clean" eyes: An extreme phenotype. Indian J Endocr Metab. 2018;22:274-6.

JAYPEE BROTHERS

CASE 5 Diabetes Mellitus

Debasis Maji

CASE HISTORY

Patient A

A 10-year-old boy of Class IV was brought to the emergency of a subdivisional hospital in the evening from a nearby village of South 24 Parganas, West Bengal. He was complaining of drowsiness for 2 days and passage of roundworm through mouth as well as in stool for last 1 week. There was nausea, but no vomiting or diarrhea.

He was afebrile, pulse rate: 110 beats/min, BP: 90/60 mm Hg, abdomen: irregular palpable ill-defined, nontender, movable swelling noticed, liver/spleen not palpable, there was no ascites. CVS—no abnormality, CNS—the boy was drowsy but responding to verbal questions and no neurodeficit was noticed. A diagnosis of roundworm toxicity was made. He was admitted under a pediatrician. IV dextrose saline drip started and a tablet of albendazole was given by Ryle's tube. All attention was given to the roundworm infestation and his clinical condition was thought to be due to roundworm infestation.

Next morning he became more drowsy, the detailed history was taken from the mother and it was revealed that for last 2 months he felt weak after coming from school in the afternoon and was becoming thin in spite of good appetite.

On examination, apart from the findings of the previous evening, he was found to have gross dehydration (sunken eyes and loss of elasticity of skin).

Laboratory reports are summarized in Table 1. Urine R/E–sugar ++++, acetone+++: No pus cells, no RBC.

A diagnosis of diabetic ketoacidosis (DKA) was considered and he was put on standard regimen of management of DKA with adequate IV fluid, IV KCl, IV insulin injection, antibiotic, hourly measurement of blood sugar and vital signs. Over the next 3 days, the boy gradually recovered from DKA and blood sugar came down to the normal range. He was given oral feed and put on basal-bolus regimen (i.e. rapid acting insulin before breakfast, lunch and dinner, injection glargine at bedtime. Over the next 4 days the parents were educated on insulin injection, dietary regulation, monitoring of

TABLE 1: Laboratory reports.

Test	Value
Hemoglobin	14 g%
Total leukocyte count	14,000/mm^3
Polymorphonuclear leukocyte	70%
Fasting blood glucose	610 mg/dL
Urea	48 mg/dL
Serum creatinine	1.15 mg/dL
Serum bicarbonate	10 mEq/L
Serum sodium	136 mEq/L
Serum potassium	4.3 mEq/L

JAYPEE BROTHERS

for detailed information on endocrinology books, visit our website **www.jaypeebrothers.com,** for detailed information on endocrinolo

Case Studies in Diabetology & Endocrinology

Every practising physician comes across at least once in his lifetime one patient on whom he can make an original scientific contribution. This is something one of my teachers told me many years ago, and it holds true even today. The problem is that most of us do not have the time or resources to document the scientific problems that pass through our hands, nor do we possess the patience to write it up as an article and then see it through to publication. This is a pity as much valuable information is lost forever. Once in a while there are exceptions and some patients do get their cases written up and published. This casebook is a compilation of cases seen by the respective authors and documented. Each patient tells a story. In some cases the patient comes with an uncommon diagnosis, while in others the diagnosis is not rare, but important management issues are discussed. Each case report is informative, entertaining and would make you think.

The cases in this book are arranged subject wise, starting from adrenals. The largest number of cases pertain to diabetes, which is as it should be. Each case is meant to be read independently. In one or two instances, similar patients have been seen by different authors. They have been included to show the similarities and differences in approach amongst colleagues. The cases can be read in any order, as each is stand alone and complete in itself. The suggested reading at the end of each case will further enrich your experience.

Some of the problems described may have been seen by you personally and have been managed similarly or differently. Please do share your feedback with us at *office.idea2011@gmail.com*. We would love to hear from each of our readers. Your unbiased opinions will guide us in our future endeavors and our labor would be truly rewarded if the end product is of use to you.

Sanjay Chatterjee Dip. BMSc MD Certificate in Diabetes Care
Honorary Consultant Diabetologist
Apollo Hospital
Kolkata, West Bengal, India

Sudip Chatterjee MD MNAMS FRCP FACP
Honorary Professor
Vivekananda Institute of Medical Sciences
Honorary Secretary
Park Clinic
Kolkata, West Bengal, India

Available at all medical bookstores
or buy online at www.jaypeebrothers.com



JAYPEE BROTHERS
Medical Publishers (P) Ltd.
www.jaypeebrothers.com

Join us on facebook.com/JaypeeMedicalPublishers

Shelving Recommendations
DIABETOLOGY
ENDOCRINOLOGY

