tailed information on dermatology books, visit our website **www.jaypeebrothers.com,** for detailed information on dermatology books, visit our website **www.jaypeebrothers.com**



Celebrating 50
Passion, Quality and Innovation in Healthcare Publishing

Cosmetic Injectables in Practice-Dermal Fillers and Botulinum Toxin

Editors
Rashmi Sarkar
Vivek Nair

Associate Editor
Gillian Ruth Britto

JAYPEE

Contents

Introduction and History of Dermal Fillers and Botulinum Toxin xix
Pallavi Ailawadi, Rashmi Sarkar

SECTION 1: DERMAL FILLERS

1. **Classification of Fillers** 3
   Rashmi Sarkar, Gillian Ruth Britto
2. **Science and Properties of Hyaluronic Acid Fillers** 9
   Maya Vedamurthy, Deepak Vedamurthy
3. **Guide for Selection and Use of Fillers** 16
   Richa Ojha Sharma, Rashmi Sarkar
4. **Facial Anatomy for Dermal Fillers** 23
   Kuldeep Singh
5. **Facial Assessment** 50
   Malavika Kohli, Banani Choudhury
6. **Patient Selection and Esthetic Consult** 66
   Latika Arya
7. **Pre-requisites for Filler Treatment** 70
   Rashmi Sarkar, Vivek Nair
8. **Anesthesia** 72
   Tanvi Gupta Arora
9. **Filler Injection Techniques** 75
   Richa Ojha Sharma
10. **Fillers for Upper Face—Forehead and Temporal Region** 79
    Vanravi Vachatimanont, Rungsima Wanitphakdeedecha
11. **Fillers for Upper Face—Temples** 85
    Gulhima Arora, Sandeep Arora
12. **Fillers for Upper Face—Eyebrow** 90
    MK Shetty
13. **Fillers for Upper Face—Upper Eyelid** 94
    Indu Ballani

JAYPEE BROTHERS

14. Fillers for Midface—Tear Trough and Infraorbital Areas 98
Rajat Kandhari, Deepak Jhakar

15. Fillers for Midface—Cheeks 107
Madhuri Agarwal

16. Fillers for Midface—Tear-Trough and Nose 112
Vanravi Vachatimanont, Rungsima Wanitphakdeedecha

17. Fillers for Midface—Nasolabial Folds 118
Vivek Nair

18. Fillers for Lower Face—Marionette Lines 123
Richa Ojha Sharma

19. Fillers for Lower Face—Chin 128
Gillian Ruth Britto, Rashmi Sarkar

20. Fillers for Lower Face—Jawline 133
Hema Pant, Gillian Ruth Britto, Vivek Nair

21. Fillers for Lower Face—Lip Augmentation 137
Gillian Ruth Britto

22. Fillers for Nonfacial Areas and Scars 149
Madhuri Agarwal

23. Complications of Fillers and their Treatment 154
Mukta Sachdeva, Ayushi Khandelwal

24. Combination Therapies with Fillers 160
Ishad Aggarwal

25. Fractional Laser-assisted Botulinum Toxin Delivery 171
Weeranut Phothong, Woraphong Manuskiatti

SECTION 2: BOTULINUM TOXIN

26. Neurotoxin Preparations 179
Abhay Talathi

27. Frown Lines 182
Varsha Vaidyanathan, Shilpa Garg, Rashmi Sarkar

28. Forehead Lines 186
Richa Ojha Sharma, Rashmi Sarkar

29. Crow's Feet and Lower Eyelid 191
Nidhi Sharma

30. Brow Lift with Botulinum Toxin 197
Jaishree Sharad

JAYPEE BROTHERS

31. Bunny Lines 202
Sonali Langar

32. Nose 208
Indu Ballani

33. Smoker's Lines (Lip Lines) 213
Gulhima Arora, Sandeep Arora

34. Gummy Smile—Botulinum Toxin 218
Malavika Kohli, Swati Mutha

35. Botulinum Toxin for Marionette Lines 225
Ishad Aggarwal

36. Dimpled Chin 229
Rajat Kandhari, Kritu Bhandari

37. Botulinum Toxin in Platysmal Bands 234
Sudha Vani Damarla, Manogna Vellala

38. Nefertiti Lift 237
Bhavesh K Swarnkar

39. Botulinum Toxin in Masseteric Hypertrophy 241
Sudha Vani Damarla, Manogna Vellala

40. Complications of Botulinum Toxin and their Management 245
Sheilly Kapoor, Komal Sharma

41. Botulinum Toxin in Men 253
Rajat Kandhari

42. Microdosing in Botulinum Toxin 259
Rajat Kandhari, Ishmeet Kaur

43. Neurotoxin Resistance 267
Vivek Nair, Rashmi Sarkar

Index 273

JAYPEE BROTHERS

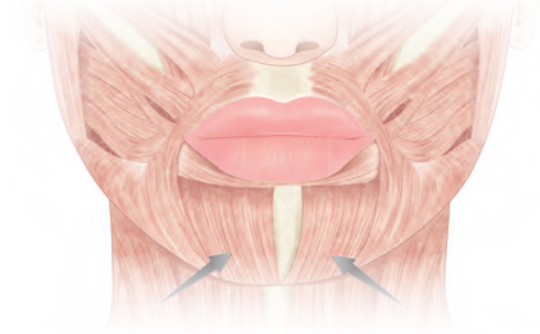

CHAPTER 4

Facial Anatomy for Dermal Fillers

Kuldeep Singh

JAYPEE BROTHERS

INTRODUCTION

Knowledge of anatomy of the face is absolutely essential to enable safe and effective injection of fillers which has been evolving over the last three decades. As knowledge has evolved, the techniques of injection have also evolved and have become more predictable, effective, and safer. Anatomy has become clearer because of efforts by researchers through live and cadaver dissections, and also the imaging and staining techniques.[1]

Aging changes in the face include skin texture changes, volume changes in the fat compartments, sagging of the soft tissues, bony resorption, and hyperactive muscles. Whether we want to lift the tissues or restore volume, an accurate knowledge of the structures in the face and the changes in anatomy which happen with time, will help us to be more effective and also safe.

In this chapter, we will be discussing relevant injection anatomy of the face area-wise. The objective is to facilitate a complete understanding of the area to be injected. Each area will be discussed layer-wise so as to understand different planes, tissues, and spaces. Subsequently, the surface landmarks and their relationship to underlying important structures will also be delineated.

FOREHEAD INCLUDING THE BROW

The area of the forehead extends from the frontal hairline to the root of the nose, and sideways from one temporal crest to the other. The layers of the forehead consist of skin, subcutaneous tissue, muscles, galea, the subgaleal space, the periosteum, and bone **(Fig. 1)**.

The skin of the forehead is glabrous and is attached to underlying muscle with fibrous septa.[2] This ensures that the skin remains fairly fixed to underlying muscles and therefore conveys expressions caused by movement

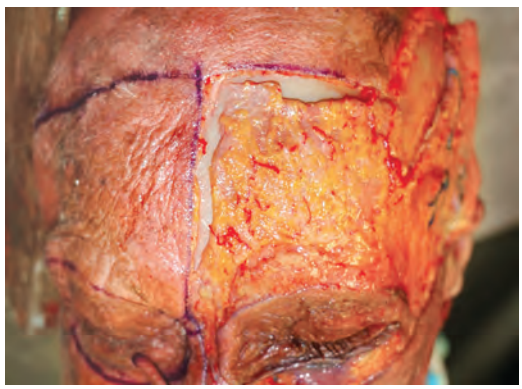

Fig. 1: Layers of soft tissues in the forehead region. Skin has been removed on the left side, and a thin layer of superficial fat overlying the frontalis muscle is seen.

of the muscles to the surface of the skin. In youth, the skin is smooth and rarely shows any lines. But with age, and regular repetitive movements of the forehead muscles strong lines emerge. The pattern of these lines varies in different individuals depending on the pattern of the adherence of the skin via the septa. These lines initially are present during movement (dynamic), but gradually remain present at rest too. The transverse lines on the forehead are due to the underlying frontalis muscle, and the vertical lines in between the eyebrows are due to the underlying corrugator supercilii muscle.

The subcutaneous tissue in the forehead is a thin layer lying on the frontalis muscle. There are two superficial fat compartments in the forehead, the central compartment and the middle fat compartment **(Fig. 1)**. The nerves of the forehead namely the supratrochlear and the supraorbital run on the surface of the frontalis muscle underneath the subcutaneous fat along with the blood vessels. Initially, it was thought that there is no deep fat compartment in the forehead. However, a fat pad exists deep to the frontalis at the level of the eyebrows called the galeal fat pad, which extends upwards for 2–2.5 cm above the supraorbital rim.[3,4] It is covered on its deep surface by the posterior layer of the galea, which invests the frontalis muscle **(Fig. 2)**.

In the region of the eyebrow, another deep fat compartment exists, which lies deep to the orbicularis oculi muscle (orbital part), and is called the retro-orbicularis oculi fat (ROOF) **(Fig. 2)**.

In younger people, most of the brow volume is made up of muscle, whereas in older people most of the brow volume is fat, mostly in the ROOF.

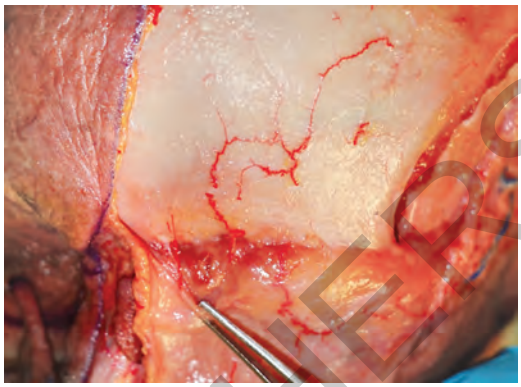

Fig. 2: The frontalis muscle along with galea removed from the forehead showing the supraorbital notch, supratrochlear and supraorbital vessels, the corrugator supercilii muscle. The galea invests the frontalis muscle, and there is a trace of fat on the deep surface of the galea (described by some as the galeal fat pad). The lateral fat seen is the ROOF.

Muscles of the Forehead and Eyebrow Region

Frontalis Muscle

This muscle originates from the galea at the hairline and inserts into the skin in the eyebrow region. The fibers also interlace with the orbicularis and the corrugator supercilii. The two bellies of the frontalis usually do not meet in the midline; however, in some males, they decussate in the midline. The upper part of the muscle pulls the hairline down, while the lower part elevates the eyebrows. It is to be noted that the frontalis muscle is the only elevator of the eyebrows. It is innervated by the temporal branch of the facial nerve **(Figs. 1 and 7)**.

Corrugator Supercilii

This muscle originates from the superomedial part of the orbital rim, and courses transversely to be attached to the skin of the middle of the eyebrow. The corrugator has two bellies,

JAYPEE BROTHERS

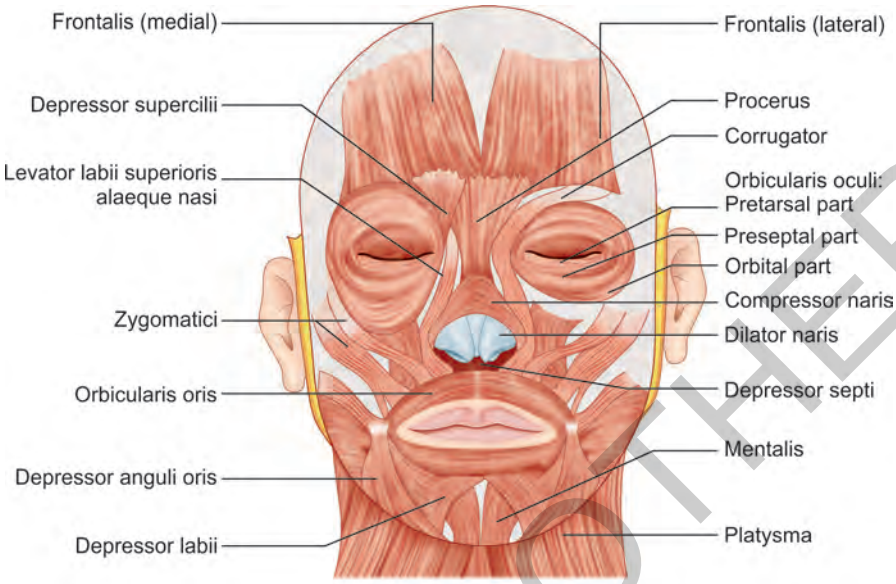

Fig. 3: Muscles of the face.

a transverse belly and an oblique belly. Medially, near its origin, the corrugator is situated deeply close to the bone whereas laterally, near the tail, it is very superficial and subdermal.

The medial part of the corrugator receives its nerve supply from the zygomatic branch and the lateral part from the temporal branch of the facial nerve. Contraction of the corrugator muscle brings the medial ends of the eyebrows together and also depresses the eyebrows. The corrugator crease in the glabellar region is formed over the supratrochlear neurovascular bundle. The supraorbital neurovascular bundle pierces the medial end of the corrugator supercilii before becoming superficial as it ascends into the forehead **(Fig. 3)**.

Depressor Supercilii

It is a thin muscle which blends in with the medial fibers of the orbicularis oculi. It arises from the frontal process of the maxilla 2–5 mm below the frontozygomatic suture and inserts into the dermis of the medial brow, and acts as a depressor of the medial brow.

Procerus Muscle

It arises from the lower end of the nasal bones and the upper lateral cartilage. It travels upward and inserts into the skin of the glabella in between the eyebrows. It pulls the nose skin up and the glabellar skin downward, and is responsible for the horizontal crease at the root of the nose. It is believed evolution wise that the procerus is a downward extension of the frontalis muscle **(Fig. 3)**. The temporal branch of the facial nerve supplies the procerus.

The scalp in the forehead glides over the underlying pericranium. At the lateral ends these layers are attached to the superior temporal crest and inferiorly at the supraorbital margin with the orbicularis retaining ligament (ORL). These attachments

JAYPEE BROTHERS

protect the neurovascular structures lying adjacent.

The bony skeleton of the forehead comprises the frontal bone. It is smoothly convex uniformly across its extent in women, but in men has a prominent supraorbital ridge with a more vertical frontal bone above.

Applied Anatomy

Loss of volume in the ROOF contributes to deflation and descent of the tail of the eyebrow.[5] Also, it deepens the upper eyelid sulcus causing the A frame deformity. Injection is placed deep to the orbicularis, and lateral to the supraorbital bundle.[6]

VESSELS AND NERVES OF THE FOREHEAD

The vessels are the paired supratrochlear vessels with the supratrochlear nerve, the supraorbital vessels and nerve, and the anterior (frontal) branch of the superficial temporal arteries.

Supratrochlear artery (branch of the ophthalmic artery) exits the orbit through the supratrochlear foramen at the medial end of the roof of the orbit, on an average of 14 mm from the midline. The medial glabellar fold typically overlies the origin of the vessels.

Supraorbital artery exits the orbit through the foramen of the same name (rarely a notch), which is palpable, and lies about 10 mm lateral to the supratrochlear vessels, or along a line drawn vertically touching the medial limbus. Twenty percent of the time, it is a notch on one side and a foramen on the other.[7]

1 cm after exiting the orbit both the supratrochlear (ST) and supraorbital (SO) vessels pierce the galea and become superficial. They at first pass through the



Fig. 4: Supratrochlear and supraorbital neurovascular bundles emerging from their respective foramina, and travelling about 1.5 cm before piercing the galea to become superficial. Frontalis muscle with galea has been reflected

corrugator muscle and then come to lie on the surface of the frontalis muscle, and ascend to the hairline. The vessel diameter ranges from 1 mm to 1.5 mm at the foramen **(Fig. 4)**.

The supraorbital nerve gives off a deep branch which travels laterally and ascends in a supraperiosteal plane about 1.5 cm medial and parallel to the superior temporal crest. It is accompanied by an artery.

Applied Anatomy

Filler injections in the glabellar and brow region should be placed in the dermal or immediate subdermal plane. Deep injections in this region within 2 cm of the supraorbital rim are at a higher risk for intravascular injection, antegrade if slow, and retrograde if injected under pressure. As the viscous filler cannot go distally in a smaller lumen size, it travels proximally till the injection pressure is kept up. Once the pressure is discontinued, it flows distally.

As the glabellar arterial branches are terminal, the entire glabella is a high risk for injection. The SO and ST arteries communicate

JAYPEE BROTHERS

with branches of the internal carotid artery through the ophthalmic artery and therefore filler material can travel retrograde to the ophthalmic artery and then distally into the central artery of the retina.

Injections into the lateral forehead in the supraperiosteal plane can impinge upon the deep branch of the SO nerve or even embolize the accompanying artery.

Injections in the brow region can be done using a cannula 25 G or greater in the suborbicularis plane, using a lateral to medial approach. Filler injections for contouring the forehead in the upper part are done in the supraperiosteal plane.

TEMPORAL REGION

The temporal region is bound superiorly by the superior temporal septum and inferiorly by the zygomatic arch. The layers of this region from superficial to deep are the skin, subcutaneous tissue, superficial temporal fascia-consisting of two layers, the outer layer and the deep layer, together called the temporoparietal fascia. This is followed by the deep temporal fascia, the temporalis muscle, and the periosteum **(Figs. 6A to C)**. The superficial temporal artery and the frontal branch of the facial nerve travel within the temporoparietal fascia. The frontal branch (or branches) crosses over the zygomatic arch at its midpoint **(Fig. 7)**.

The temporoparietal fascia is separated from the deep temporal fascia by loose areolar tissue. The latter is thickened in the region of the temporal crest and is called the *superior temporal septum*. Also, there is the condensation of the areolar tissue in the middle of the temporal fossa, called the *inferior temporal septum*. Both septum fuse at the anterior end and form the *temporal adhesion* in the region of the tail of the eyebrow **(Fig. 5)**. The temporal ligamentous adhesion (TLA) measures about 20 mm in height and 15 mm in width, and begins 10 mm cephalad to the superior orbital rim.[8]

About 2–3 cm above the zygomatic arch, the deep temporal fascia divides into an outer layer which attaches to the outer surface of the zygomatic arch, and a deeper layer which attaches to the inside edge. In between these

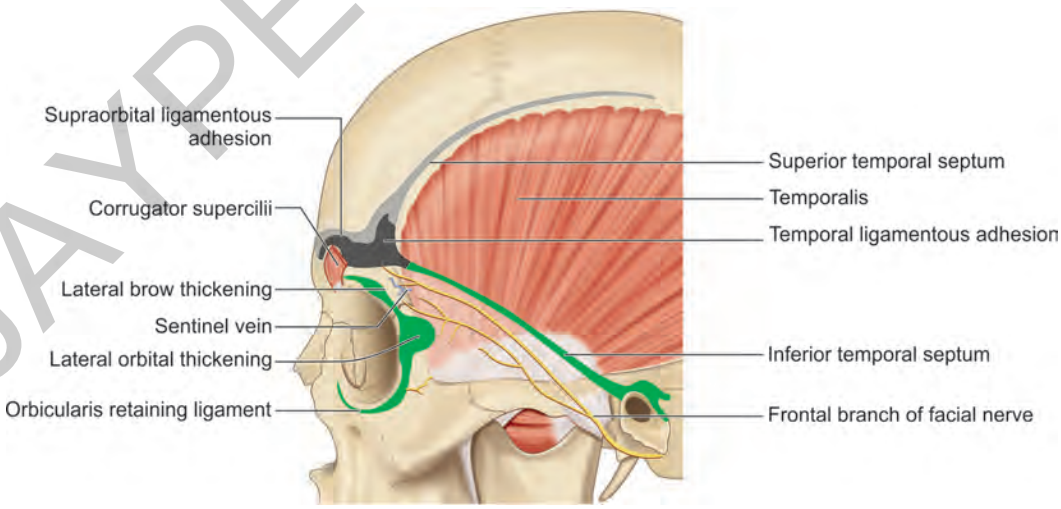

Fig. 5: Ligaments in the periorbital area and the temporal region.

JAYPEE BROTHERS

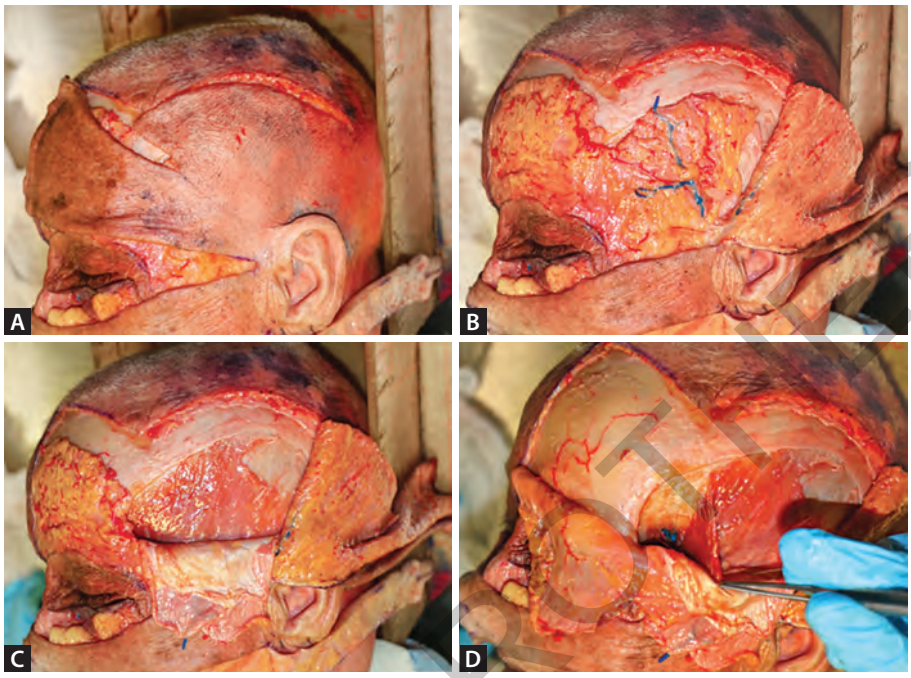

Figs. 6A to D: (A) The temporal region with skin flaps elevated; (B) Exposed temporoparietal fascia showing the superficial temporal artery dividing into its anterior and posterior branches about 5 cm from the tragus, with accompanying veins; (C) Shows reflected deep temporal fascia exposing the temporalis muscle arising from the superior temporal crest and temporal fossa; (D) The reflected anterior edge of the temporalis muscle showing the anterior deep temporal vessels about 2 cm behind the junction of the lateral orbital rim and the superior temporal crest (Swift point is 1 cm above and lateral to avoid the vessels in a temple filler injection).

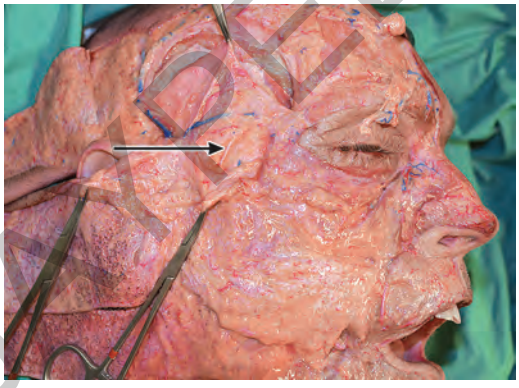

Fig. 7: Showing the temporal branch of the facial nerve crossing over the zygomatic arch at its midpoint, lying in the deep part of the temporoparietal fascia enveloped with fat (black arrow).

two layers, lies a fat pad called the superficial temporal fat pad (also called the supra zygomatic fat pad).[6] Also, in this space the medial zygomaticotemporal (sentinel) vein can be found.

Deep to the deep temporal fascia is a space which is continuous with the infratemporal fossa. Some fat is present in this space and is called the deep temporal fat pad (subzygomatic fat), which is the temporal extension of the buccal pad of fat.

The *temporalis muscle* originates from the periosteum of the temporal fossa, the superior temporal crest and the deep surface

JAYPEE BROTHERS

of the deep temporal fascia **(Fig. 6C)**, and is inserted into the coronoid process and the anterior surface of the ascending ramus of the mandible. The middle temporal vessels and the deep temporal vessels provide blood supply the muscle. Motor innervation is from the mandibular nerve.

The *superficial temporal artery* is a branch of the external carotid artery, emerges 1 cm anterior and 1 cm superior to the tragus. About 5 cm later, it branches into the anterior (frontal) branch and the posterior (parietal) branch **(Fig. 6B)**. It lies within the temporoparietal fascia.

The frontal branch of the facial nerve runs obliquely from the tragus to the lateral border of the frontalis muscle in the forehead. It crosses the zygomatic arch obliquely at its midpoint, lying under the deeper part of the temporoparietal fascia, just supraperiosteal **(Fig. 7)**. Its surface marking is the Pitanguy line, which runs from point 0.5 cm below the tragus to a point 1.5 cm lateral to the supraorbital rim.

The anterior deep temporal vessels run vertically in the deep part of the temporalis muscle on an average about 1.8 cm posterior to the lateral orbital rim **(Fig. 6D)**.

The anterior and the posterior deep temporal arteries supplying the muscle are branches from the second part of the maxillary artery. They lie between the temporalis muscle and the pericranium **(Fig. 6D)**.

The middle temporal artery arises from the superficial temporal artery immediately above the zygomatic arch and perforates the deep temporal fascia, gives branches to the temporalis muscle, and anastomoses with the deep temporal vessels.

Applied Anatomy

The bone in the temporal region is of varying thickness. One site is particularly thin and is called the *pterion*. This is located 3 cm posterior and 3 cm superior from the lateral canthus. It can also be localized 3 cm posterior to the frontozygomatic suture and 4 cm above the zygomatic arch. Forceful deep injections against the bone in this region can possibly enter the cranial cavity in the region of the pterion.

Injections in the temporal region are usually made deep in the muscle, or in the interface between the muscle and the periosteum. The bony landmarks including the temporal crest, the lateral orbital rim, and the upper border of the zygomatic arch are defined and located before starting injection. Injections are usually made in the anterosuperior quadrant of the temporal region outside the hairline. A point within 1 cm of the lateral orbital rim is considered safe with respect to avoiding the anterior deep temporal vessels.

Swift, DeLorenzi, and Kapoor (2019) have described a safe point 1 cm superior and 1 cm lateral to the tail of the eyebrow **(Fig. 6D)**.[9]

Intravascular injection in this area can enter the anterior deep temporal artery and travel retrograde to the external carotid artery and on releasing pressure embolize into the superficial temporal artery, or any closest branch. Direct injection in the anterior branch of the superficial temporal artery may occur, if one does not look for it and mark it.

Injections in the inferior part of the temporal fossa, just above the zygomatic arch, are avoided as the filler may reach the infratemporal fossa through the space between the deep temporal fascia and the temporalis muscle.

JAYPEE BROTHERS

EYELIDS AND ORBIT

This region is also called the periorbital region. It includes the eyebrow, supraorbital rim, infrabrow area, lateral canthal area, the upper and lower eyelids, and the infraorbital area.

The *orbicularis oculi* muscle originates from the nasal part of the frontal bone, the frontal process of maxilla, and the medial canthal tendon and, inserts into the lateral raphe and lateral canthal tendon. It consists of circular fibers extending from the eyelids outward, to cover the orbital septum and then extend across the orbital rim. The infraorbital part extends much farther in the inferolateral part to cover the upper cheek **(Fig. 8)**.[10]

The orbicularis oculi muscle is divided into three parts:

1. The *pretarsal* part which overlies the upper and lower tarsal plates, and is involved in the closure of the eyelids and blinking
2. The *preseptal* part overlies the orbital septum, and
3. The *orbital* part extends over the bony orbit. The orbital fibers in the inferolateral part have been described to have multiple fenestrations by Michaud.[11] Muscle fibers from the medial part extend to cover the lacrimal sac, and are involved in the function of pumping lacrimal fluid downward.

The orbicularis oculi muscle action is to close the eyelids. The superior part is also a depressor of the eyebrow. It is the only cheek elevator.

The infraorbital part of the orbicularis lies between the superficial fat of the cheek viz. the infraorbital fat (IOF) (the malar fat pad), and the deep fat namely the suborbicularis oculi fat (SOOF). In the supraorbital part, the fat of the forehead overlies the orbicularis oculi, and deep to the orbicularis lies the ROOF.

The eyelids have no fat and the orbicularis oculi muscle is intimately adherent to the skin in most areas.

At the orbital rim, the deep surface of the *orbicularis* muscle is attached to the periosteum by a ligament called the ORL. This ligament exists in the upper orbital rim, the lateral orbital rim, and the inferior orbital rim dividing the orbicularis into the septal and orbital parts. In the infraorbital region, the ORL (it is about 2 mm away from the rim

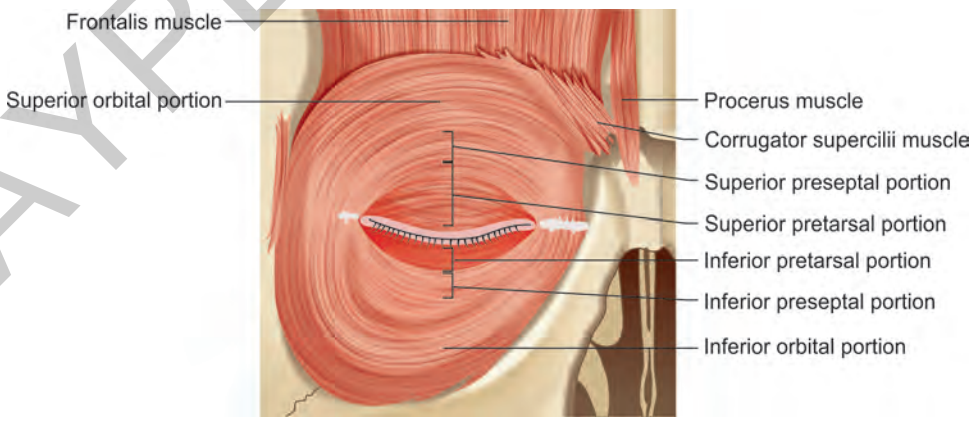

Fig. 8: Orbicularis oculi muscle showing the pretarsal, preseptal and preorbital parts, and its relationship with the corrugator supercilii and frontalis muscles.

JAYPEE BROTHERS

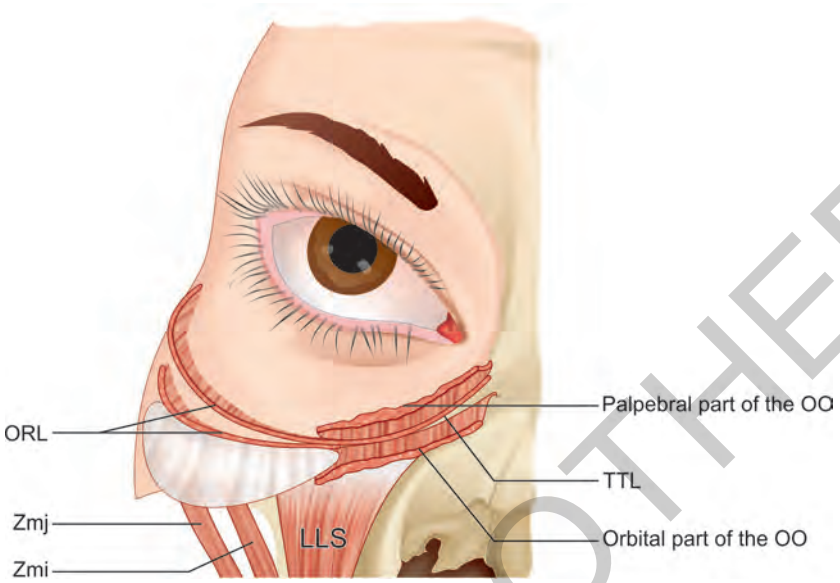

Fig. 9: Orbicularis retaining ligament (ORL) showing 2 lamellae in the lateral infraorbital part and medially single tightly adherent structure. Also showing relationship with prezygomatic space.

(ORL: orbicularis retaining ligament; TTL: tear trough ligament; LLS: levator labii superioris; OO: orbicularis oculi)

here) is split into two lamelli in the lateral part, whereas as it travels medially it fuses, gets more and more tightly adherent to the periosteum, and in the medial most part is called the tear trough ligament (TTL). The orbicularis muscle is also tightly adherent to the periosteum in the medial part **(Figs. 5 and 9)**.

The nerve supply to the orbicularis oculi comes from the frontal branch of the facial nerve in the superolateral part and the zygomatic branch in the inferomedial part.

The corrugator supercilii and the depressor supercilii muscles have been discussed in the section on the forehead.

The SOOF consists of a medial part and a lateral part. The medial part extends from the medial limbus to the lateral canthus, and the lateral part from the lateral canthus to the temporal fat pad. Deep to the SOOF lies the prezygomatic space, and deep to that lies the origin of the zygomaticus major muscle and adjacent periosteum.

The prezygomatic space is bound anteriorly by the SOOF, posteriorly by the body of the zygoma and maxilla, superiorly by the ORL, and inferiorly as well as laterally by the zygomatic ligament. Access to this space (other than by direct puncture) is via a point on the front of the zygoma body in the lateral and upper part **(Fig. 11)**. This gives access (using a cannula) to the SOOF up to the medial canthus, as well as the deep medial cheek fat compartment.

The malar septum is a funnel-like structure which exists in the infraorbital and the lateral orbital region, inferiorly ending on the orbital rim, whereas laterally it is 5 mm away from the rim **(Figs. 12A and B)**. It divides the SOOF into a superficial part and a deep part.[12] The lymphatic drainage of superficial SOOF is already compromised in patients with malar

JAYPEE BROTHERS

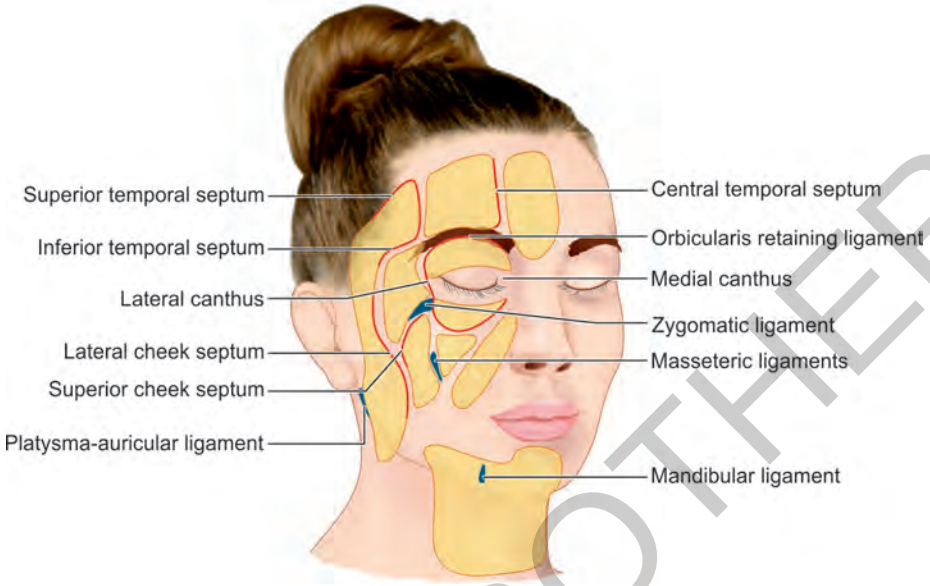

Fig. 10: Fat compartments of the face—showing ligaments and septae demarcating various fat compartments
(*Source*: Prendergast PM. Anatomy of the face and neck. Cosmetic Surgery. Schiffman and Guiseppe (Eds). Springer Verlag 2012)

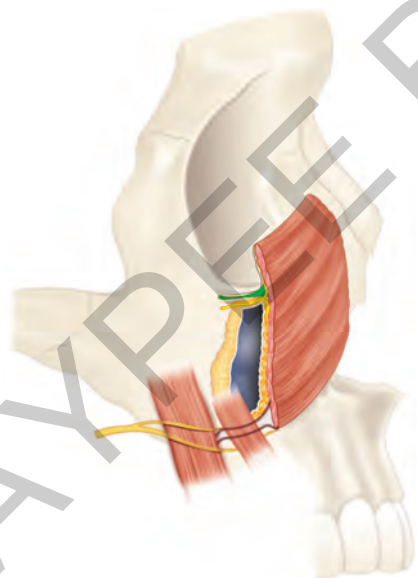

Fig. 11: Prezygomatic space—situated in front of the body of zygoma, superiorly. Bordered by ORL, roof by Preorbital part of the orbicularis oculi muscle, floor by SOOF. The zygomatic ligament forms the lateral part of its floor. Gives access to the SOOF and deep medial cheek fat compartment.

(*Source:* Mendelson B and Wong, C. Anatomy of the ageing face. Aesthetic Surgery of the face. Plastic Suregry. Elsevier 2013)

bags, and any high-volume injection in the deep SOOF will increase edema (malar bags) in the region. Also, superficial injection in a patient with malar bags will worsen them.

Vascular Anatomy

Almost all around the orbit, there is a confluence of arteries and veins between the external carotid and the internal carotid systems. The supratrochlear, supraorbital, lacrimal, infratrochlear, and the dorsal nasal (branches of the ophthalmic artery) arteries anastomose freely with the superficial temporal artery, the transverse facial artery, the infraorbital artery, and the angular artery **(Fig. 13)**.

The superficial temporal artery anastomoses with the supraorbital artery and/or supratrochlear artery. The transverse facial artery and the deep temporal arteries anastomose with the zygomatic branch of the lacrimal artery.

JAYPEE BROTHERS

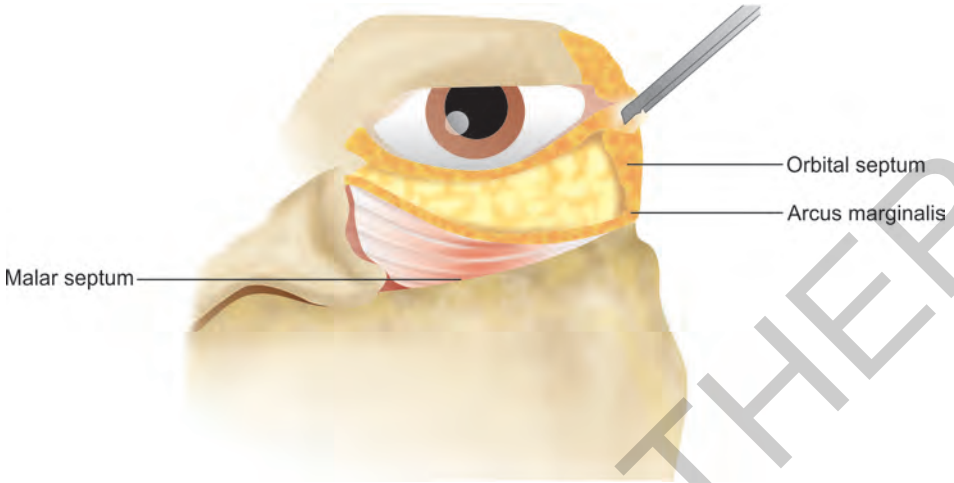

Figs. 12: Structure of the malar septum—(A) cadaver dissection; and (B) diagrammatic representation.

(*Source*: Pessa JE, Garza JR: The malar septum: the anatomical basis of malar mounds and malar edema. Aesthet Plast J . 1997;17(1):11-17)

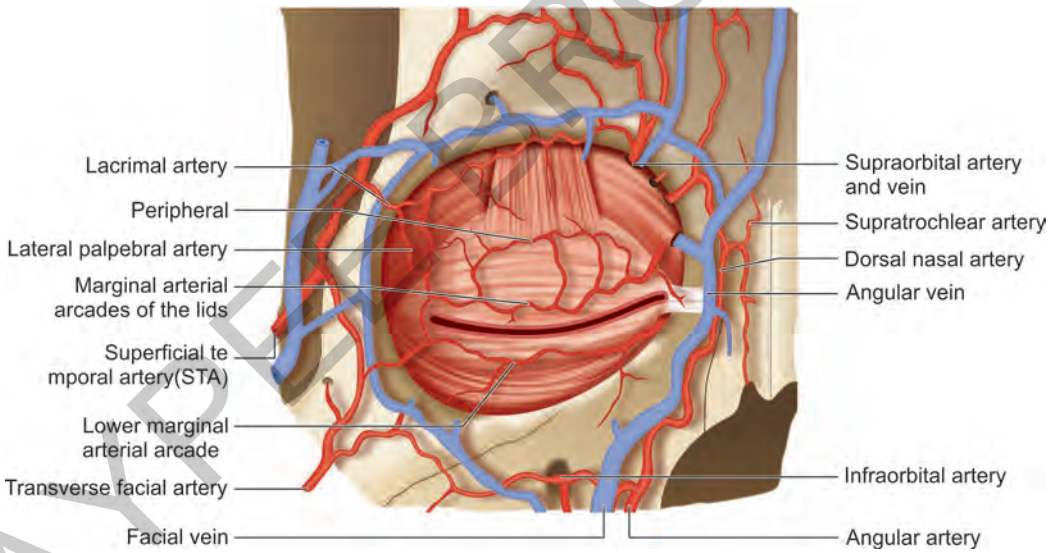

Fig. 13: Periorbital arteries and veins—showing connections between the ECA and the ICA systems, viz. the infraorbital, angular, transverse facial, superficial temporal, supraorbital, supratrochlear, and dorsal nasal arteries.

(ECA: external carotid artery; ICA: internal carotid artery)

Applied Anatomy

The ROOF is the deep fat compartment in the supraorbital region. Here the deep fat is continuous and flows into the preseptal area reaching the levator palpebrae superioris (LPS) muscle unlike the SOOF in the lower eyelid, which is limited by the ORL from communicating with the lower eyelid preseptal space.[13]

JAYPEE BROTHERS

Volume loss in the ROOF causes the tail of the eyebrow to descend and contributes to deepening of the superior sulcus of the upper eyelid, called the "a frame deformity". The plane of injection of fillers obviously is deep to the OO muscle, in the suprapericranial plane, lateral to the supraorbital notch. To improve the superior sulcus of the upper eyelid, injection is performed just inferior to the rim, deep to the orbicularis, and superficial to the LPS and the orbital septum. Care should be taken to avoid the septum, the LPS and the upper eyelid fat pads.

The infraorbital area has very confusing anatomical nomenclature. The "tear trough" extends from the medial canthus to the mid-pupillary line, and from the mid-pupillary line to the lateral canthus, it is called the "nasojugal groove". Lateral to the lateral canthus, it is called the "mid-cheek groove". The mid-cheek groove corresponds to the attachment of the zygomatic ligament **(Fig. 14)**.

The fullness/volume of the infraorbital region arises from the underlying muscles, the IOF, the deep fat compartment (SOOF), and the underlying bone. All of these structures show changes with age along with changes in the overlying skin. The lower eyelid fat pads herniate because of attenuation of the orbital septum and the stretched orbicularis muscle. The lateral SOOF also undergoes atrophy leading to a prominent palpebromalar groove.

In youth, the infraorbital region is a smooth convexity transitioning from the lower eyelid to the cheek. As aging progresses, the orbital fat pads herniate causing convexity in the preseptal part of the lower eyelid. Ptosis of the deep cheek fat compartment further exposes the SOOF creating a double convexity. Rohrich, Pessa, and Ristow[14,15] demonstrated that in cadaveric specimens injection of saline in the deep medial cheek fat compartment caused the double convexity to disappear, thereby inferring that the primary determinant

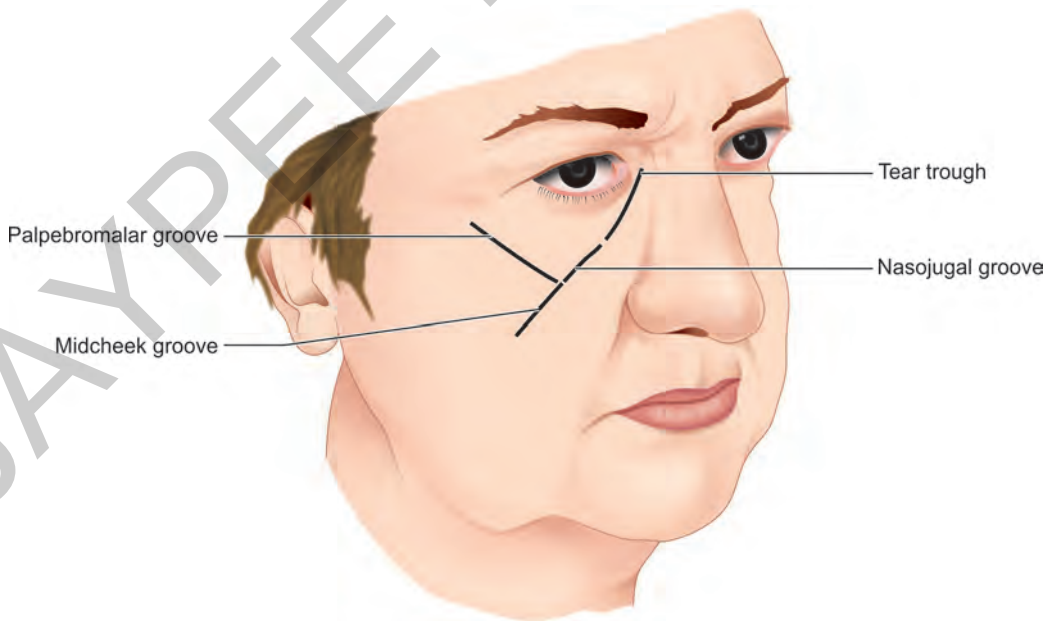

Fig. 14: Face showing 1. Palpebromalar groove, 2. Tear trough 3. Nasojugal groove and 4. The midcheek groove.

JAYPEE BROTHERS

r detailed information on dermatology books, visit our website **www.jaypeebrothers.com,** for detailed information on dermatology books, visit our website **www.jaypeebroth**

Cosmetic Injectables in Practice-Dermal Fillers and Botulinum Toxin

Salient Features

- Offers an excellent and comprehensive overview on the clinical use of fillers and Botulinum Toxin
- Opens with an introduction, followed by history of fillers, injection techniques, complications and safety parameters
- Updated evidence-based data on cosmetic applications of dermal filler agents
- An ideal chapter on patient selection and esthetic consult for cosmetic injectable, including the contraindications, pre-treatment precautions, patient counseling and other important considerations during esthetic consultation is described in brief
- Mechanisms of action of Botulinum Toxin and esthetic indications are described in a separate chapter
- Neurotoxin preparations, complications and their management is emphasized in a separate chapter
- The text is supplemented with line arts, tables, clinical images, wherever appropriate
- Authoritatively written by experts with immense knowledge and clinical experience
- A valuable source for dermatologists, cosmetologists, and postgraduate students.

Rashmi Sarkar MD MNAMS is a Professor, Department of Dermatology, Maulana Azad Medical College and Associated Lok Nayak Jai Prakash Narayan Hospital, New Delhi, India. She has done her MD (Dermatology) from Postgraduate Institute of Medical Education and Research, Chandigarh, India. She is Editor-in-Chief, Pigment International and World Clinics in Dermatology; was the Founder Editor of Asian Pigment Bulletin (APB); was Associate Editor of Journal of Cutaneous and Aesthetic Surgery (JCAS) (2011–14); on the Editorial Board of Indian Journal of Dermatology, Venereology and Leprology (IJDVL), Indian Journal of Pediatric Dermatology (IJPD), Indian Journal of Dermatology (IJD) and International Journal of Dermatology (2014–17), International Journal of Women's Dermatology (IJWD) and Journal of Clinical and Aesthetic Dermatology (JCAD); besides being a reviewer for 20 Journals. She has edited 12 books, has 175 publications in peer-reviewed international and national journals and 75 chapters in textbooks of dermatology and pediatrics. She was the National Secretary General of Indian Association of Dermatologists, Venereologists, and Leprologists (2014–15); President IADVL Delhi State Branch (2018); Chief Founder and President of Pigmentary Disorders Society (PDS); and Founding President of Joint Women's Dermatologic Society-Indian Women's Dermatologic Society. She is also a recipient of several prestigious awards and honors including Maria Duran Fellowship from International Society of Dermatology (ISD), Member Making a Difference Award from American Academy of Dermatology (AAD), Career and Community Development Award from Women's Dermatologic Society, and other International Travel Awards from ISD, World Congress of Dermatology (WCD), and AAD. She has been an invited speaker in many international and national conferences, including the prestigious Annual AAD Meetings since 2006. She has received the prestigious IADVL's Dr BM Ambady Oration (2019), IADVL South Zone's Dr BV Sathyanarayanan Oration (2015), IADVL Delhi State Branch Oration (2019), Economic Times "Inspiring Dermatologist" Award (2019), Dr Madhusudan Das Oration from Nalanda Medical College (2019), Dr VN Sehgal Award from IADVL for Excellence in Dermatology in 2020.

She is Vice President, ISD; Secretary General of Asian Society of Pigment Cell Research (ASPCR) (2014–17); International Representative, Board of Directors in Women's Dermatologic Society (WDS) (2011–14; 2017–18); former Board of Directors in Skin of Color Society (SOCS); Chair of International Mentorship Committee of ISD; and Chair of Women's Committee of International Federation of Pigment Cell Societies (IFPCS) and International Affairs Committee of WDS (2014–17), Member of International Affairs Committee of AAD. She is the Chair, National and International Committee of SOCS.

Vivek Nair MD FAAD (USA) FISD (USA) is a Consultant Dermatologist and Dermatosurgeon, Dr Nair's Skin Clinic (DNSC) and Hair Transplant Center, Gurugram, Haryana, India. He is vastly experienced in the use of Botulinum Toxin and Dermal Fillers and has been injecting since 2010. A dermatology gold medalist from Maulana Azad Medical College. He received the 'Best Young Dermatologist Award Paper' (IADVL, DSB) in 2007 for his work on the surgical treatment of acne scarring. He has honed his cosmetic dermatology and dermatosurgical skills through fellowships in Miami, London, Singapore, and Israel. His special interest areas are lasers, injectables, teledermatology, and hair transplantation. He has been active in teaching injectables at various regional and national conferences through workshops and hands on demonstrations. He is a reviewer for four journals and has published numerous articles in national and international journals. He has contributed eight book chapters in textbooks including 'Treatments for Skin of Color' (Taylor et al, Elsevier), 'Lasers in Dermatological Practice' (Sardana et al, Jaypee), and the 'ACSI Textbook on Cutaneous & Aesthetic Surgery' (Mysore, Jaypee).

Available at all medical bookstores or buy online at www.jaypeebrothers.com



JAYPEE BROTHERS
Medical Publishers (P) Ltd.
www.jaypeebrothers.com

Join us on facebook.com/JaypeeMedicalPublishers

Shelvin Recommendation
DERMATOLOGY

