bsite www.jaypeebrothers.com, for detailed information on dermatology books, visit our website www.jaypeebrothers.com

Celebrating 50 Passion, Quality and Innovation in Healthcare Publishing

Color Atlas of Dermatophytoses

Focus on Superficial Fungal Infections





Editor
Jayakar Thomas

Co-editor
Parimalam Kumar

Foreword
UR Dhanalakshmi

JAYPEE

CONTENTS

1. Scalp Infections 1
2. Face Infections 11
3. Trunk and Limbs Infection 26
4. Axillary Infections 85
5. Hand Infections 89
6. Groin Infections 98
7. Gluteal Area Infections 127
8. Feet Infections 147
9. Nail Infections 152
10. Steroid-modified Disease 157
11. Infections in Pregnancy 176
12. Infections in Children 184
13. Infections in Adolescent 209
14. Infections in the Immunocompromised 227
15. Mimickers of Dermatophytoses 245

JAYPEE BROTHERS

2 CHAPTER Face Infections



FIG. 1: Tinea faciei around the left eye. This might involve the eye lashes and needs prolonged treatment.



FIG. 2: Single patch involving the beard area.

JAYPEE BROTHERS



FIG. 3: Involvement of pinna with excoriation.



FIG. 4: Same patient as in figure 3 indicating autoinfection.

JAYPEE BROTHERS



FIG. 5: Retroauricular involvement.



FIG. 6: Noninflammatory type of tinea faciei.

JAYPEE BROTHERS



FIG. 7: Extensive tinea faciei extending on to the bald scalp.



FIG. 8: Tinea faciei with very mild scaling.

JAYPEE BROTHERS



FIG. 9: Involvement of midface. Note the well-defined border.



FIG. 10: Involvement of periorbital area will need systemic antifungal therapy.

JAYPEE BROTHERS



FIG. 11: Tinea faciei unilateral involvement of the ear, a diagnostic clue.

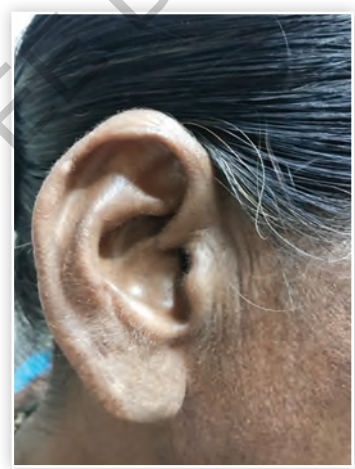

FIG. 12: Same patient as in figure 11. Note there is no involvement of the right side.

JAYPEE BROTHERS



FIG. 13: Tinea faciei treated with topical steroid, note herpes simplex.



FIG. 14: Same patient as in figure 13. Note the well-defined border over the right cheek.

JAYPEE BROTHERS



FIG. 15: Same patient as in figures 13 and 14 involvement of left side of face.



FIG. 16: Very faint scaling in a patient with tinea faciei.

JAYPEE BROTHERS



FIG. 17: Same patient as in figure 16. Note border in the preauricular area.



FIG. 18: Tinea faciei in a patient with psoriasis.

JAYPEE BROTHERS



FIG. 19: Ill-defined scaly patch.



FIG. 20: Same patient as in figure 19 showing patches over the neck as well.

JAYPEE BROTHERS



FIG. 21: Tinea faciei in a boy whose father also had tinea faciei.



FIG. 22: Involvement of the vermilion border in tinea faciei.

JAYPEE BROTHERS



FIG. 23: The active border without much scaling in a man with tinea faciei.



FIG. 24: Patch within patch affecting the perioral area.

JAYPEE BROTHERS



FIG. 25: Single coin shaped tinea faciei; centre showing inflammation.



FIG. 26: Small patch within a big patch of tinea faciei.

JAYPEE BROTHERS



FIG. 27: Classical annular scaly patch involving the neck.



FIG. 28: Extensive scaling yet asymptomatic in a noninflammatory type.

JAYPEE BROTHERS



FIG. 29: Ill-defined border difficulty in diagnosis in dark individuals.



FIG. 30: Tinea faciei worsened with topical steroid.

JAYPEE BROTHERS

for detailed information on dermatology books, visit our website www.jaypeebrothers.com, for detailed information on derma

Color Atlas of
Dermatophytoses

Focus on Superficial Fungal Infections

Key Features

- The book is an image bank presenting the clinical features of fungal infectious diseases
- Contains more than 500 high resolution clinical images in an agile format for easy interpretation
- Images accompany a brief caption which provides an appropriate understanding of the disease in question
- Compiled in a chapter wise format including the fungal infections of different body parts with emphasis on steroid-modified disease and mimickers of fungal infections
- Includes infections in special conditions such as pregnancy and immunocompromised states
- Separate chapter on infections in adolescents and children
- The atlas presents a panorama of knowledge not only to dermatologists, but also to physicians, general practitioners and medical students.

Jayakar Thomas
MD DD MNAMS FRCP FRCPCH PhD DSc
Professor and Head
Department of Dermatology
Sree Balaji Medical College and Hospital
Chennai, Tamil Nadu, India

Parimalam Kumar
MD DD MNAMS FRCP
Professor and Head
Department of Dermatology
Stanley Medical College and Hospital
Chennai, Tamil Nadu, India

Available at all medical bookstores
or buy online at www.jaypeebrothers.com



JAYPEE BROTHERS
Medical Publishers (P) Ltd.
www.jaypeebrothers.com
Join us on facebook.com/JaypeeMedicalPublishers

Shelving Recommendation
DERMATOLOGY

