eebrothers.com, for detailed information on obstetrics & gynecology books, visit our website www.jaypeebrothers.com, for detailed information on obstetrics & gynecology books

FEDERATION OF OBSTETRIC AND GYNAECOLOGICAL SOCIETIES OF INDIA
FOGSI™

WE FOR स्त्री
Safer • Stronger • Smarter

Celebrating 50 Years
Passion, Quality and Innovation in Healthcare Publishing

FOGSI FOCUS

ENDOMETRIOSIS
Current Trends



Editor-in-Chief
Nandita Palshetkar

Editor
Kuldeep Jain

Co-Editors
Sudha Prasad
T Ramani Devi
Fessy Louis T

JAYPEE

Contents

1. **Newer Insights in Etiopathogenesis of Endometriosis** 1
   Saumya Prasad, Sudha Prasad
2. **Endometriosis in Adolescent: Clinical Challenges** 6
   M Preethi, Damodar R Rao, Asha R Rao
3. **Imaging in Endometriosis** 13
   Bharti Jain, Maansi Jain
4. **Medical Management of Endometriosis and Adenomyosis—What's New** 17
   Sonia Malik, Meenakshi Dua
5. **Adenomyosis and Assisted Reproductive Technology** 24
   Kuldeep Jain, Maansi Jain, Bharti Jain
6. **Müllerian Anomalies and Endometriosis** 29
   T Ramani Devi, Dhivya Sethuraman
7. **Stimulation in Endometriosis and Adenomyosis: Is It Different?** 37
   Abha Majumdar, Neeti Tiwari
8. **Tips of Surgery in Endometriosis** 42
   Nutan Jain
9. **Rectosigmoid Endometriosis/Deep Infiltrative Endometriosis** 48
   Parul Kotdawala, Santwan B Mehta
10. **Fertility Prevention and Endometriosis: What is the Status?** 58
    Surveen Ghumman
11. **Scar Endometriosis—Preservation Strategies and Management** 62
    Pratik Tambe, Riddhi Desai
12. **Endometriosis and Infertility** 66
    Rohan Palshetkar, Nandita Palshetkar
13. **Surgery before In Vitro Fertilization: What is the Evidence and Recommendations?** 73
    Fessy Louis T, Parvathy T

Index 79

CHAPTER 2

Endometriosis in Adolescent: Clinical Challenges

M Preethi, Damodar R Rao, Asha R Rao

JAYPEE BROTHERS

INTRODUCTION

Endometriosis was frequently described as an enigmatic condition due to many unanswered questions and controversies in its pathogenesis, diagnosis, and management. Endometriosis was once believed to occur in teenagers rarely and was thought to affect women in later reproductive years. With increasing awareness of both healthcare professionals and general population, it is now well revealed that endometriosis affects significant teenagers.

After introduction of keyhole surgery since 1980s, endometriosis is recognized as a disease that affects adolescent and young women, whereas in the beginning it was believed that it was rare in younger age group.

Endometriosis prevalence in adolescents undergoing keyhole surgery for chronic pelvic pain is reported to be between 19% and 73%. To our surprise rarely, endometriosis has also been notified in premenarchal girls with some breast development. Diagnosis of adolescent endometriosis is often delayed in the adolescent girls for more than 6–8 years if high index of suspicion is not there.

Several factors have been described for endometriosis, whereas no single theory can explain the cause of symptoms. Genetic factors may play a role, whereas lifestyle characteristics and environmental factors can also be related to the development of the disease.

The raising concern on this topic is because this diagnosis of condition is quite challenging.

- Presenting symptoms of adolescent endometriosis is persistent chronic pelvic pain, in spite of treatment with medical management like either hormonal contraceptives or pain killers.
- In almost 60–70% of adults with endometriosis, symptoms started even before the women reached 20s.
- In spite of using an oral contraceptive or pain killers, these girls tend to have more school absentees during their menses and also take leave more for a longer period of time to treat severe primary dysmenorrhea.
- Several symptoms, which are associated with gastrointestinal tract, are seen with these adolescent girls like constipation, diarrhea, nausea, and vomiting.
- Appearance of adolescent endometriosis may be different from adult endometriosis and also deeper lesions seem to be rare.
- There is no evidence whether the treatment for adolescent endometriosis may prevent disease progression in their later life.

RISK FACTORS

Most commonly obstructive type Müllerian anomalies are known to be associated with increased risk of endometriosis in teenagers. It may be due to increased retrograde menstruation. After surgical correction of obstruction, spontaneous resolution of such endometriosis has been reported. There is a familial association in adolescent endometriosis similar to adult endometriosis.[1,2]

SYMPTOMS

Major presenting symptoms of endometriosis in adolescence are chronic pelvic pain (27–96%) and dysmenorrhea (18–100%). Severe acyclic pain tends to be more common in these teens than in adults. Other symptoms are urinary symptoms, gastrointestinal symptoms, pelvic mass, irregular menses, dyspareunia, subfertility, migraine, and depression or anxiety. Adolescents should be offered a pain diary in order to document frequency and pain characters.[2,3]

HISTORY

Past medical history, family history, and physical examination are necessary for evaluation and management of adolescents with a possible endometriosis. Several other pathologies, such as appendicitis, pelvic inflammatory disease, bowel disease, Müllerian anomalies or outflow obstruction, musculoskeletal disorders, hernias and psychosocial complaints should be excluded prior to diagnose adolescent endometriosis.[3,4]

EXAMINATION

Inspection of the girl should be done for possible estrogen-dependent body configuration with peripheral fat distribution and also for breast and pubic hair development according to the Tanner system.

A patent outflow tract should be evaluated in these teen adolescents by placing a Q-tip into the vaginal canal. This is very helpful to exclude a possible transverse vaginal septum, vaginal agenesis or agenesis of the lower vagina. For virgo adolescents pelvic examination cannot be performed; hence, rectal-abdominal examination is done. Importance should be given for diagnosis of both diffuse and focal pelvic tenderness.[3,5]

Investigations

Imaging is very helpful in these girls. Ultrasonography and magnetic resonance imaging (MRI) will perform anatomical evaluation, but are not specific for diagnosing endometriosis.

Transvaginal Ultrasound

In case of suspected endometriosis, transvaginal ultrasound is necessary to investigate even if the pelvic and/or abdominal examination is normal so as to identify endometriomas and deep endometriosis involving the bowel, bladder or ureter. In virgins where transvaginal scan is not appropriate, consider for a transabdominal ultrasound imaging of the pelvis.[6]

Magnetic Resonance Imaging

According to some studies, *MRI* can detect endometrial implants with a sensitivity as high as 60% but due to its high cost, it is better not to use pelvic MRI as the primary investigation to diagnose endometriosis in women with symptoms and signs of endometriosis. It is better to consider pelvic MRI only to assess the extent of deep endometriosis involving the bowel, bladder or ureter.[6]

CA 125

Cancer antigen (CA 125) is very sensitive, but they are not specific, thus, is not so helpful in the diagnosis of adolescent endometriosis. If in case of coincidentally reported increased serum CA 125 level is available, then a raised serum CA 125 (that is, 35 IU/mL or more) may be consistent with endometriosis. Despite endometriosis may be present even with a normal serum CA 125 (less than 35 IU/mL).[1,6]

ROLE OF DIAGNOSTIC LAPAROSCOPY

Adolescents with severe symptoms should be appropriately evaluated by *diagnostic laparoscopy* where standard treatment for pelvic pain or dysmenorrhea is not effective. Endometriosis should be staged by using the revised criteria of the American Society of Reproductive Medicine-based classification system. Thus, during a diagnostic laparoscopy, it is always better to take a biopsy of suspected endometriosis, in order to confirm the diagnosis of endometriosis (but be aware that a negative histological result does not exclude endometriosis).[6,7]

Large numbers of lesions in adolescent populations with endometriosis are atypical red lesions and majority of these lesions were correlated with severe dysmenorrhea and abdominal pain, nausea, constipation and diarrhea due to increased production of prostaglandins (Figs. 1A and B).

Some study had reported peculiar atypical red vascular lesions in 60% of adolescents teens compared to only 20% of nonadolescents. Clear lesions are common in adolescent endometriosis but often it is difficult to visualize and evaluate these lesions. Peritoneal defects or windows are common manifestations of adolescent endometriosis (Fig. 2).[7,8]

NATURAL COURSE OF ENDOMETRIOSIS IN TEENAGERS

The natural course of endometriosis in adolescents has always been a matter of debate. In adults spontaneous resolution, particularly of superficial lesions, has been reported, but in teenagers, some authors reported progression of endometriosis lesions in few patients who underwent a second-look laparoscopy after ablative therapy of endometriosis. Due to this reason, some authors have a belief that teenage endometriosis is a progressive disease.[3,9]

MEDICAL TREATMENT

Nonsteroidal Anti-inflammatory Drugs

Due to high prevalence of severe dysmenorrhea in teenagers, it is always better to treat these young girls with

JAYPEE BROTHERS

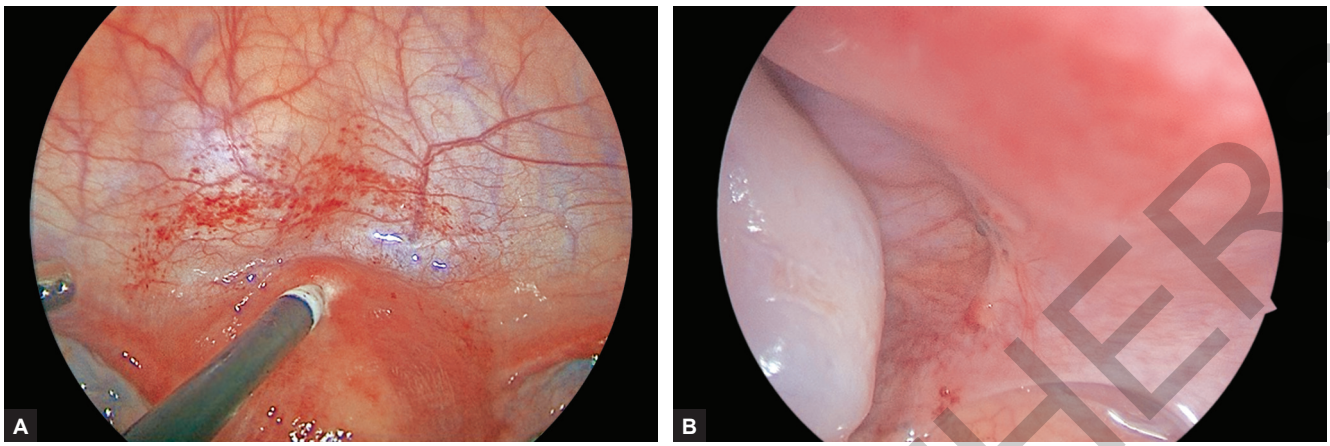

Figs. 1A and B: Peculiar atypical red vascular lesions.
Courtesy: Rao Hospital, Coimbatore.

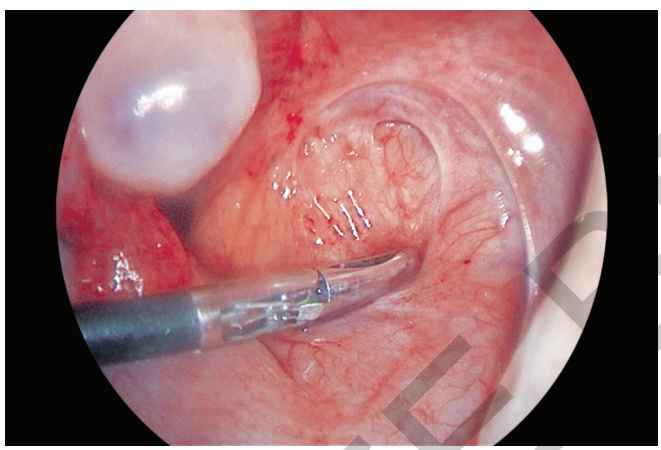

Fig. 2: Peritoneal windows in endometriosis.
Courtesy: Rao Hospital, Coimbatore.

the classical approach of nonsteroidal anti-inflammatory drugs (NSAIDs), oral contraceptive pills, and/or paracetamol.[2,5] Thus, it has to be remembered that both primary dysmenorrhea and endometriosis-associated pain will respond to these kinds of therapies whereas symptomatic improvement does not rule out endometriosis. Hence, it is always better to communicate this message to both the teenager and her parents/caregivers. In this sort of approach it is expected that the symptoms will improve and avoid a significant number of further unnecessary investigations including gonadotropin-releasing hormone agonist (GnRHa) or laparoscopy. But it is also better to explain to parents or caregivers that the symptoms of endometriosis may be masked due to NSAIDs, thus allowing the condition to progress further.

Hormonal Treatment

In those women with suspected or confirmed endometriosis, hormonal treatment may reduce pain, but it has no permanent negative effect on subsequent fertility. Thus, it is better to offer hormonal treatment [e.g., the combined oral contraceptive (COC) pill or a progestogen] to women with recurrent endometriosis. If the pain is not responding to the COC or NSAIDs treatment, then there is a high likelihood of endometriosis. Hence, before starting options of medical management like GnRH analogs or dienogest (DNG) diagnosis with diagnostic laparoscopy may be considered as an option.

Levonorgestrel Intrauterine System

In adolescents who are sexually active, levonorgestrel intrauterine system (LNG-IUS) may be effective alternative for those who have endometriosis-associated pain. Due to lack of evidence in its use among teenagers, it may not be considered as an acceptable option among teenagers. Thus, it may not be used as a first-line empirical treatment option.[1,4]

GnRHa

Those teenagers who have surgically confirmed disease, treatment with GnRHa may be considered as an option. However, overuse of GnRHa in teenagers who are at the critical stage of achieving the peak bone density is of concern. In spite of this, some studies suggest that GnRHa can be an alternate option for treatment of endometriosis-associated pain in teenagers. Hence, patients should be given options in selecting patients for either medical or surgical modality of treatment. Thus, GnRHa may be

JAYPEE BROTHERS

an effective alternative for those teenagers who have completed their bone formation.[10,11]

Progestins

Due to lack of data, usage of progestins in teenagers is of debate. This may be probably due to long-term use of progestins on bone mineral density (BMD). Some studies have shown that women who used depomedroxyprogesterone acetate (DMPA) on long term have lower BMD. Due to this reason The National Institute for Health and Care Excellence, UK (UK NICE) has recommended that care should be taken before recommending DPMA as a treatment option for adolescents. Thus, it may be an alternative option only if other methods are not suitable or not acceptable.[6]

Dienogest

Dienogest 2 mg can be started at any day of the menstrual cycle once a day, and it appears to be safe and effective when taken up to 2 years. Though, current treatments are limited to shorter treatment intervals. DNG is effective in treating symptomatic women with rectovaginal endometriosis even in a particular endometriotic subpopulation of norethisterone acetate (NETA) "resistant" patients. DNG can be a novel alternative for extragenital endometriosis.

Treatment of adolescent endometriosis with DNG is not inferior as compared to that of GnRHa. DNG was found to be successful in those patients with deep infiltrating endometriosis with or without visceral involvement; a slight reduction in BMD is noted only after 24–52 weeks of treatment (Flowchart 1).[12]

Surgery

Surgery is often indicated in those adolescent teens who have:

- Pain (failed medical management)
- Endometrioma (which damages ovary)
- Moderate or severe disease distorting anatomy
- Infertility.

Surgical options in adolescent teens will include laparoscopy rather than laparotomy. Surgery should be timed ideally in the follicular phase of her menstrual cycle, in order to prevent future possibility of recurrences and adhesions. The goal of surgical treatment is the possible removal of visible areas of endometriosis and restores their normal anatomy by adhesiolysis (Fig. 3).[13,14]

The advantages of laparoscopy are:

- Magnification
- Better visualization of subtle lesions

Flowchart 1: The American College of Obstetricians and Gynecologists has put forth a stepwise treatment algorithm for treatment of adolescent endometriosis.

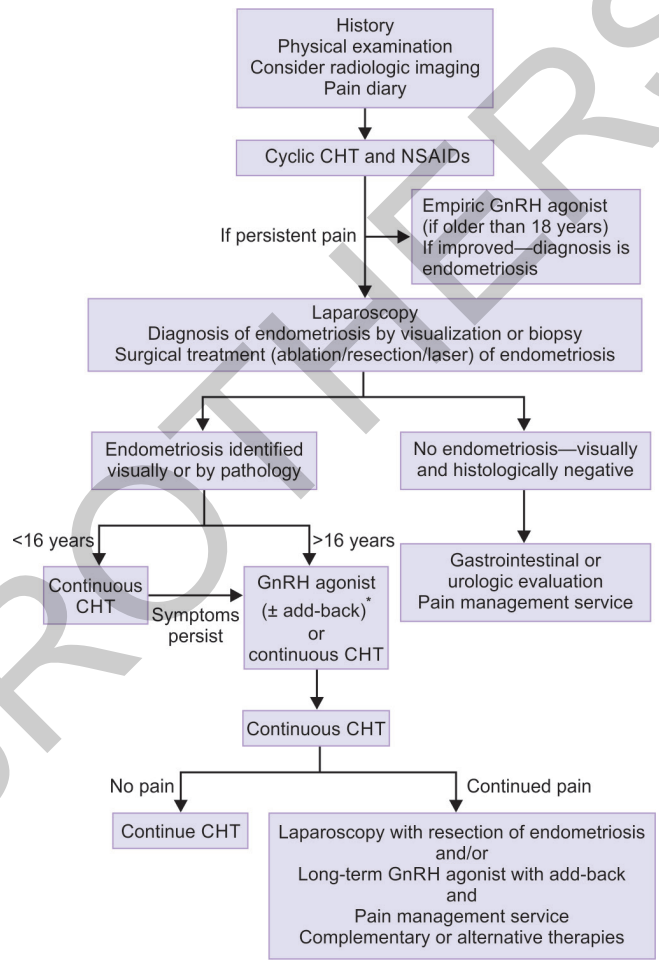

(NSAIDs: nonsteroidal anti-inflammatory drugs; CHT: combination hormone therapy; GnRH: gonadotropin releasing hormone)
*Add-back indicates use of estrogen and progestin or norethindrone acetate alone.

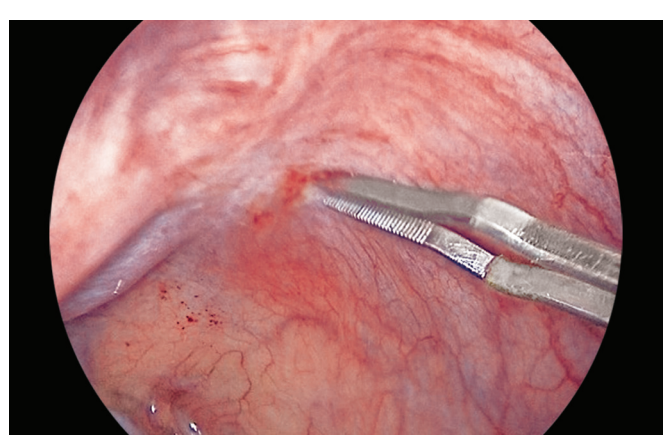

Fig. 3: Surface endometriosis electrocoagulation.
Courtesy: Rao Hospital, Coimbatore.

JAYPEE BROTHERS

- Less tissue trauma and desiccation
- Smaller incisions
- Speedy postoperative recovery
- Less postoperative adhesions.

The procedure seems to improve the endometriotic symptoms in 38–100% of adolescents. Laser vaporization and monopolar or bipolar coagulation are the methods used, with no single technique shown to be superior than the other. In some studies it is reported that complete laparoscopic excision by experts can significantly reduce the recurrence rates of endometriosis in adolescents, while Yang et al. found a zero rate of recurrence of the disease (diagnosed visually or histologically) after complete laparoscopic excision of the disease in teenagers at a repeat laparoscopy for pain. Even though frequency of adolescents who undergo laparoscopy for persistent recurrent pain is 47.1%, the rate of endometriosis found at surgery was almost insignificant.[11]

ENDOMETRIAL CYSTS MANAGEMENT

Endometrioma of ovary is the most common symptomatic presentation of advanced endometriosis in adolescents. Recent publications have reported large number of cases of adolescents with stage III and IV endometriosis. Even though adolescents may present with advanced stages of endometriosis, these numbers are fewer as comparing with adults. Red lesions are the most usual lesions seen in adolescents, with some atypical lesions being common among these teens.

Ovarian endometriomas are usually correlated with more advance stage of the disease. Therefore, it is easily understood that these girls will present with more frequent pain. A retrospective study of 63 adolescents with endometrioma found bilateral disease in 22.22%, while endometrioma in the right ovary seems to be more frequent than a left endometrioma (65% vs. 57%).[13] In these cases the preferable surgery is a combined technique of cystectomy and cauterization of the capsule. Interestingly, in a review by Gordts et al. it was found that early ablative surgery can contribute to a lower morbidity, relief of symptoms, and a better quality of life, while in another recently published study have reported recurrence rates of endometrioma per patient at 24, 36, 60, and 96 months after laparoscopic cyst enucleation for ovarian endometrioma being 6.4%, 10%, 19.9%, and 30.9%, respectively. All these adolescents had stage III or IV of the disease (Figs. 4 and 5).[14]

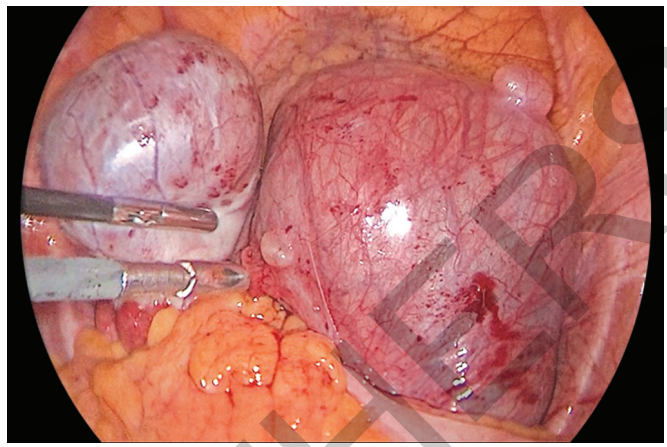

Fig. 4: Ovarian endometrioma in a 16-year-old adolescent and drainage of endometriotic cyst.
Courtesy: Rao Hospital, Coimbatore.

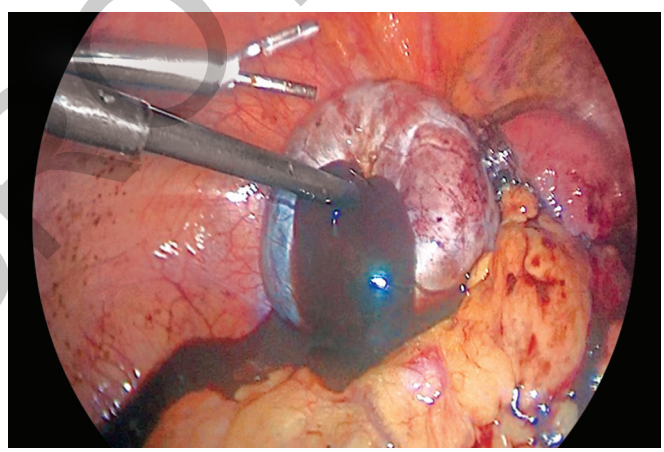

Fig. 5: Ovarian endometrioma in a 16-year-old adolescent and drainage of endometriotic cyst.
Courtesy: Rao Hospital, Coimbatore.

ROLE OF POSTOPERATIVE HORMONAL SUPPRESSION

On the other hand, postoperative hormonal suppression should be offered to adolescents in order to treat symptoms and to prevent disease progression and/or recurrence of the disease, while the role of postoperative medical therapy in addition with surgery in improving future fertility of adolescents with endometriosis has not been well documented.

However, the conjunction of surgery with postoperative medical therapy does not seem to slow disease progression and/or recurrence. The recurrence rate of endometriosis

JAYPEE BROTHERS

in these young women appears to be higher than in older women. In a retrospective cohort study of 57 women, aged ≤21 years, who were treated initially by excisional surgery, it was shown that the rate of recurrence of symptoms during a follow-up period of 5 years was 56%. The study also showed that the postoperative medical therapy did not influence the recurrence rates.[15]

As reported above, a variety of medical therapies have been used in treating endometriosis during adolescence. Even though further studies are needed, in order to conclude which medical therapy is superior than the other, GnRHas seem to be more effective as compared with COCs and progestins to prevent disease recurrence.

Conjugated equine estrogens as add-back therapy in combination with norethindrone acetate will be more effective for increasing total bone mineral content, BMD, and lean mass than using the usual norethindrone acetate monotherapy. LNG-IUS is accepted for use in the adolescent population for contraception and menorrhagia in sexually active women, but there are not enough data regarding its effectiveness in the treatment of adolescent endometriosis.[16]

In those studies of adults with endometriosis, *DNG* has shown limited effects on BMD. In a 24-week trial, Strowitzki et al. observed a 0.25% increase in mean lumbar spine BMD with DNG 2 mg vs. a decrease of 4.04% with leupride acetate (LA).[12]

RECURRENCE FOLLOWING SURGERY

Tandoi et al. reported that recurrence of endometrioma following surgery seems to be high during a 5-year follow-up, 56% recurrence rate has been reported among 57 young women aged ≤21 years. In that only 34% of these recurrences were confirmed laparoscopically and remaining 66% diagnosis of recurrence was based on either symptoms or ultrasound findings.[10] In contrast, Yeung et al. found no visual or histological evidence of recurrence in 8 of 17 teenagers (47%) who underwent repeat laparoscopy within 66 months following laparoscopic treatment of endometriosis.[17]

Majority of the studies have supported for postoperative use of medical management in order to prevent recurrence. Most of studies have reported the use of either COC pill or LNG-IUS. Now, recent studies have advocated the use of either GnRHa or DNG as an effective alternative. DNG 2 mg is equivalent in efficacy to LA for reducing endometriosis-associated pelvic pain. It is the most effective in reducing the recurrence of endometrioma, and therefore the necessity of reoperation may be avoided.[12]

There is currently no consensus whether surgery should be avoided or should be considered at an early stage. Some authors advocate conservative approach due to high recurrence rates whereas others recommend an early intervention before developing more severe lesions. Hence, further future research is required for better patient compliance.

FUTURE TRENDS

Selective estrogen receptor modulators and selective progesterone receptor modulators are the newer treatment options available for adolescent endometriosis. Both of these drugs will act by suppressing estrogen-dependent endometrial growth without any adverse systemic effects like vasomotor symptoms and loss of BMD. Another treatment options are aromatase inhibitors which are the key enzyme in estrogen biosynthesis as it appears to be overexpressed in areas of endometriosis. These drugs act by reducing ovarian and as well as local production of estrogens, and hence it can be used in treatment of adolescent endometriosis. Autoimmune modulators with antitumor necrosis factor therapies may be an effective option for disease treatment to reduce endometriotic growth in animal models, being a promising prospective future treatment model.

FOLLOW-UP

A careful follow-up of adolescents with history and symptoms of endometriosis is mandatory as it can be a life-long disease. Patients should be examined every 3–6 months for disease progression. Thus, pain calendar should be monitored, while concerns regarding future fertility and quality of life should be enrolled in the diary. Unless contraindicated, most of those patients should be put on COCs after surgery. In case if the patient has recurrence of symptoms in spite of either medical or surgical management, other treatment modalities should be considered. A multidisciplinary approach should be usually considered, including a gynecologist along with surgeon, gastroenterologist, psychologist, and urologist.

ISSUES OF INTEREST FOR FUTURE CONSIDERATION

Future studies should be ideally focused on the role of early diagnosis of endometriosis and treatment in progression and advancement of the disease process. There is a need

JAYPEE BROTHERS

to evaluate the course of endometriosis in teenagers, as this may improve our understanding for the development of deep endometriosis.

CONCLUSION

Due to increasing awareness of endometriosis in teenagers, increasing prevalence of the disease is being documented. Clinicians should take more proactive approach in the diagnosis and treatment of endometriosis in the teenage group. Both medical and surgical treatment options should be better utilized for them to prevent recurrence. However, a number of debatable questions are unanswered and the importance of prospective data collection/international collaboration is mandatory in order to give a better quality of care for these teens.

REFERENCES

1. ACOG Committee Opinion. Obstet Gynecol. 2018;132(6).
2. Kaur KK, Allahbadia G, Singh M. An update on diagnosis and management of adolescent endometriosis: A short communication. Acta Sci Paediat. 2019;2:48-50.
3. Deligeoroglou E, Karountzos V, Tsimaris P, et al. Endometriosis in adolescence: Challenges and opportunities for managing future infertility. Int J Gynecol Clin Pract. 2018;5:IJGCP-145.
4. ESHRE Guideline of the European Society of Human Reproduction and Embryology. 2018.
5. Brosens I, Gordts S, Benagiano G. Endometriosis in adolescents is a hidden, progressive and severe disease that deserves attention, not just compassion. Hum Reprod. 2013;28(8):2026-31.
6. Endometriosis: Diagnosis and management, NICE Guideline, 2017.
7. Miller JA, Missmer SA, Vitonis AF, et al. Prevalence of migraines in adolescents with endometriosis. Fertil Steril. 2018; 109(4):685-90.
8. Hugh S, Taylor G, Adamson D, et al. An evidence-based approach to assessing surgical versus clinical diagnosis of symptomatic endometriosis. Int J Gynecol Obstet. 2018;142:131-42.
9. Giuseppe G, Guo SW, Puttemans P, et al. Progress in the diagnosis and management of adolescent endometriosis: An opinion. Reprod Biomed Online. 2018;36(1):102-14.
10. Tandoi I, Somigliana E, Riparini J, et al. High rate of endometriosis recurrence in young women. J Pediatr Adolesc Gynecol. 2011;24(6):376-9.
11. Yang Y, Wang Y, Yang J, et al. Adolescent endometriosis in China: a retrospective analysis of 63 cases. J Pediatr Adolesc Gynecol. 2012;25:295-9.
12. Ebert AD, Dong L, Merz M, et al. Dienogest 2 mg daily in the treatment of adolescents with clinically suspected endometriosis: The VISanne Study to Assess Safety in ADOlescents. J Pediatr Adolesc Gynecol. 2017;30:560-7.
13. Gordts S, Puttemans P, Gordts S, et al. Ovarian endometrioma in the adolescent: a plea for early-stage diagnosis and full surgical treatment. Gynecol Surg. 2015;12:21-30.
14. Vitonis AF, Baer HJ, Hankinson SE, et al. A prospective study of body size during childhood and early adulthood and the incidence of endometriosis. Hum Reprod. 2010;25:1325-34.
15. Sadler GJ, Feldman HA, Stokes NA, et al. The effects of gonadotropin-releasing hormone agonist combined with add-back therapy on quality of life for adolescents with endometriosis: A randomized controlled Trial. J Pediatr Adolesc Gynecol. 2017;30:215-22.
16. Özyer S, Uzunlar Ö, Özcan N, et al. Endometriomas in adolescents and young women. J Pediatr Adolesc Gynecol. 2013;26:176-9.
17. Yeung P Jr, Sinervo K, Winer W, et al. Complete laparoscopic excision of endometriosis in teenagers: is postoperative hormonal suppression necessary? Fertil Steril. 2011; 95(6):1909-17.

JAYPEE BROTHERS

for detailed information on obstetrics & gynecology books, visit our website www.jaypeebrothers.com, for detailed information on obstetrics & gynecology books, visit our website

FOGSI FOCUS

ENDOMETRIOSIS: Current Trends

Endometriosis is an enigmatic disease, full of controversies and debates in diagnosis, management as well as follow-up and always remains clinicians' nightmare. "FOGSI FOCUS Endometriosis: Current Trends" is a comprehensive book covering almost all aspects ranging from adolescent Endometriosis to complications of surgery and long-term follow-up and fertility preservation keeping current recommendations in mind. The aim of the book is to provide practical guidelines, do's and don'ts, current trends and recommendations for clinicians to be applied in daily practices. All contributors are well-known academicians, having vast knowledge and experience in the field.

The book will be highly useful for all clinicians and will be used as Reference book for Endometriosis.

Nandita Palshetkar MD FCPS FICOG FRCOG (UK) is a Professor of Obstetrics and Gynecology, Dr DY Patil Medical College, Hospital and Research Center, Navi Mumbai. She is the current President of the Federation of Obstetric and Gynaecological Societies of India (FOGSI) and has been the Past President of the Mumbai Obstetrics and Gynecological Society (MOGS), Indian Association of Gynaecological Endoscopists (IAGE) and Maharashtra Chapter of ISAR (MSR). She is the President Elect for the All Maharashtra Association of Obstetric and Gynaecological Societies (AMOGS) and heads the IVF unit at Lilavati and Bhatia Hospitals, Mumbai, DY Patil Medical College, Navi Mumbai, Fortis Hospitals, New Delhi, Gurugram and Chandigarh. Widely considered as a pioneer in ART and responsible for offering the latest laboratory advances in the field to Indian patients, her passion for medicine in general and assisted reproduction in particular is well known. She has written over 100 textbook chapters, edited several books and has been the recipient of 18 national and international awards including the Bharat Gaurav Award at the House of Commons in the UK. Most recently, Dr Palshetkar has been conferred the Fellowship of the Royal College of Obstetricians and Gynecologists (UK) ad eundem.

Kuldeep Jain MD Fellow ART (Singapore) is a senior IVF Consultant and Gynae laparoscopic surgeon and currently Director of KJIVF and Laparoscopy Center, Delhi. He was formerly Reader at UCMS at GTB Hospital, Delhi and Professor at Muzaffarnagar Medical College and having more than 30 years of teaching and clinical experience. He is trained in ART and Embryology and completed his fellowship in ART at KKIVF Singapore. He is one of the pioneer for establishing the teaching and training courses in Reproductive Medicine and Embryology in India and was instrumental in starting the prestigious Embryology preparatory course for ESHRE examinations and IFS certification for embryologists. He is also the founder Secretary and past President of Indian Fertility Society and Editor-in-Chief, Fertility Science and Research. He has established one year diploma in Clinical Embryology run by Indian Fertility Society in collaboration with Amity University. He is currently member of Scientific Committee of International Federation of Fertility Societies and Chairperson of Endometriosis Committee, FOGSI. He has written multiple chapters in books on Reproductive Medicine and author of *IVF Techniques for Beginners* and *Embryology for Beginners*.

Available at all medical bookstores
or buy online at www.jaypeebrothers.com

JAYPEE BROTHERS
Medical Publishers (P) Ltd.
www.jaypeebrothers.com

Join us on facebook.com/JaypeeMedicalPublishers

Shelving Recommendation
OBSTETRICS & GYNECOLOGY

ISBN 978-93-89188-84-4