bsite www.jaypeebrothers.com, for detailed information on pediatrics books, visit our website www.jaypeebrothers.com

INDIAN ACADEMY OF PEDIATRICS

Celebrating 50 YEARS
Passion, Quality and Innovation in Healthcare Publishing

IAP Textbook of Pediatric Radiology

Editors-in-Chief
TM Ananda Kesavan
S Venkateswaran

Editors
Mona D Shastri
G Vijayalakshmi
Anoop Verma
M Zulfikar Ahamed
Anand S Vasudev
TK Nandakumaran
Manish Kumar
Kavita Menghani
Pulak Parag

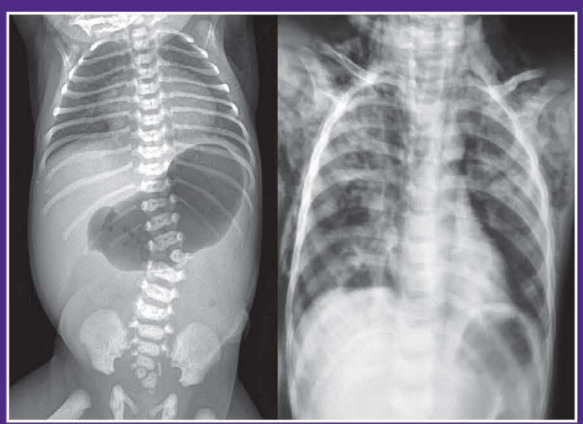

Executive Editors
TU Sukumaran
Digant D Shastri

SECOND EDITION

JAYPEE

Contents

1. **X-ray Imaging in Children** **1**
   Mona D Shastri
2. **Respiratory System** **5**
   S Venkateswaran
3. **Cardiovascular System** **70**
   M Zulfikar Ahamed
4. **Bone and Metabolic Diseases** **97**
   G Vijayalakshmi
5. **Gastrointestinal System** **143**
   TK Nandakumaran
6. **Genitourinary System** **155**
   Anand S Vasudev, Manish Kumar
7. **Neonatology** **173**
   Anoop Verma, Kavita Menghani, Pulak Parag
8. **Interesting Case Scenarios** **187**
   TM Ananda Kesavan, TU Sukumaran

Bibliography *209*

Index *211*

CHAPTER
4

Bone and Metabolic Diseases

G Vijayalakshmi

INTRODUCTION

The first X-ray ever taken was that of bones. Next to the chest, the largest number of X-ray taken now is that of bones. In spite of so many advancements in the field of imaging, X-ray is and will remain the mainstay in diagnosis of skeletal pathology. There are certain features in bone peculiar to children. After fusion of epiphysis, the mature adult bone is a continuous mass. However, there are five radiologically distinct parts in a growing bone. They are the epiphysis, metaphysis and diaphysis, physis, and zone of provisional calcification. An epiphysis is present at each end of the long limb bones, but is found at only one end of the metacarpals (at proximal end in first and distal end in second to fifth metacarpals), metatarsals (proximal in first and distal in second to fifth metatarsals), phalanges (proximal ends), clavicles, and ribs. In contrast to long bones, flat or membranous bones do not have a single growth plate, but many epiphyses are placed at intervals circumferentially. The slightly expanded portion at the end of the diaphysis is the metaphysis. In between the epiphysis and the metaphysis is a lucent layer, the physis, or growth plate (Fig. 4.1). In between the physis and the metaphysis is a white line, which is the zone of provisional cartilage. The physis is composed of innumerable cartilage cells that have an amazing potential for multiplication. The cartilage cells near the epiphysis proliferate, undergo hypertrophy, and move to the metaphyseal side. Here they die and get calcified. This is the zone of provisional calcification, consisting of dead and calcified cartilage cells. It is then invaded by osteoclasts, which resorb the calcified cartilage. Osteoclasts are followed by osteoblasts. Osteoblasts lay down osteoid, which is then mineralized. Both calcification of cartilage and mineralization of osteoid are affected in vitamin D deficiency. Between the ages of 18 years and 25 years, the cartilage cells gradually cease to proliferate, the epiphyseal plates close, fade, and leave a thin



Fig. 4.1: Note the thin lucent physis in between the epiphysis and metaphysis in this 9-year-old child.

JAYPEE BROTHERS

white line. This signifies that bone growth has stopped. It has been found that the fastest growing bone ends are the distal femur, proximal tibia, distal radius, and proximal humerus. The clavicle is the last bone to stop growing. The aforementioned sequence results in linear growth of bone. Thickness of bone is achieved by osteoblasts derived from the periosteum. Increase in thickness goes on even after linear growth ceases. Long bones have a tubular shaft composed of solid bone tissue enclosing a cavity. The medullary cavity is filled with fat and marrow and is the relatively lucent portion in the X-ray, while the cortex of bone is seen as a white outline. The periosteum covers bone and is not seen in the X-ray. Some long bones, for example, femur, have a nonarticulating apophysis at the end of a protrusion of bone (greater trochanter). It is like an epiphysis, grows and fuses with the shaft, but does not contribute to linear growth of the bone.

ACCESSORY OSSICLES

These are accessory ossification centers. They are not always bilateral. Common accessory ossicles are the accessory navicular on the medial aspect of the foot near the navicular bone and os trigonum just behind the talus. Sesamoid bones are also accessory ossicles and are so named because they are shaped like sesame seeds. They are formed at the insertion of tendons and articulate with the adjacent bone. They help in reducing wear and tear of joints, tendons, and ligaments by reducing the tension on the tendons. The largest sesamoid bone in the body is the patella. Other sesamoids commonly seen in the knee are fabella (in the lateral head of the gastrocnemius muscle) and cyamella (in the head of the popliteus). In the foot, they are seen near the head of the first metatarsal.

SOME PECULIAR FEATURES IN THE GROWING SKELETON

It is essential to remember that bone X-ray of children, though largely similar to that of the adult, have some peculiarities arising out of its continuous growth. Many ossification centers are continuously appearing and fusing. These may appear fragmented as they ossify in a multicentric fashion and may thus simulate fractures. Likewise, certain epiphyses like that of the calcaneum appear fragmented and sclerotic and should not be mistaken for osteochondritis. The growth plate is a structure that should be preserved. Insults to the metaphysis-physis-epiphysis complex due to infection, trauma, or tumor are more damaging in the child as the growth plate is disturbed and linear growth of the child is altered. Salter Harris fractures are peculiar to children. These involve the growth plate. Since the child's capsular and ligamentous structures are five times stronger than the weakest part of the growth plate, the growth plate fractures first, and dislocations are less frequent. The zone of provisional calcification is the weakest part of the growth plate. Growing bones are "softer" and tend to bend before they fracture. The greenstick fracture consists of bending of bone, where there is a break on the convex surface while the concave surface is intact. In the torus fracture, there is buckling of one side of the cortex (Fig. 4.2).

In children, the periosteum is constantly growing so that it is loosely attached to the underlying cortex. Therefore, subperiosteal hematoma due to twisting injury or scurvy is more likely in children. For the same reason, the periosteum is easily lifted with accumulation of pus in osteomyelitis. The periosteum reacts by laying down new bone so that involucrum is exuberant in children.

JAYPEE BROTHERS



Fig. 4.2: Torus fracture—buckling of the lateral cortex of radius is seen.



Fig. 4.3: Depressed fracture

The periosteum at the ends of bones is firmly adherent. So, twisting injuries here cause avulsion of a piece of bone from the metaphysis. Another difference between the adult and child is the ability to estimate bone maturation by studying the appearance and growth of epiphyses.

Depressed fracture (Fig. 4.3) of skull bones is common in children. Similarly, dural tear and growing fracture occur more readily in the child due to malleability of the growing skull and rapidly growing brain and skull causing close adherence of the dura to the bone. The arachnoid with the CSF bulges through the tear in the dura. This soft tissue interposition prevents dural and fracture healing. The pulsating pressure of the CSF erodes the edges of the fracture causing it to widen with time. An initial width of fracture more than 4 mm should alert the pediatrician to the possibility of a dural tear requiring follow-up. The growing fracture is seen as a wide gap with overlying soft tissue swelling representing the leptomeningeal cyst (Fig. 4.4).

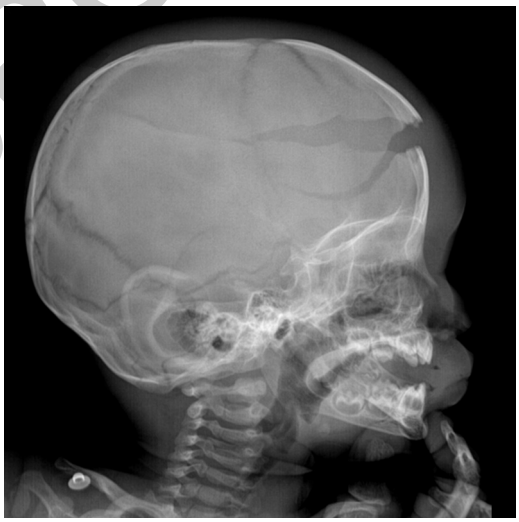

Fig. 4.4: Growing fracture and leptomeningeal cyst.

Estimation of Bone Age

There are two methods of evaluating precise bone age as reflected in specific X-rays. The Greulich and Pyle method uses the X-ray of the hand. It assesses the appearance of the various epiphyseal centers and changes in the shape of the bones as they grow. These

JAYPEE BROTHERS

have been standardized and documented and are available as an atlas. X-rays have to be matched with the standardized pictures. The other method is the Tanner and Whitehouse TW1 and TW2 (modified TW1) methods where numerical values have been assigned to growing bone patterns. This is considered to be more accurate but time consuming. The method that is being considered in this section is the oldest method that uses only the age of appearance of epiphyseal centers. This is what is used in forensic medicine and is generally familiar among students and clinicians. It can quickly separate those with growth disorders from the others. Further precise measurements can be done with either the Greulich and Pyle method or the TW method. These two methods are likely to be easier when computer-assisted techniques get more popular and available. Based on a large study in the Institute of Child Health and Hospital for Children, Chennai (Dr G Vijayalakshmi—unpublished data), the following pattern may be used. Depending on the chronological age of the child, specific X-rays are taken. Both hands with wrists, both knees anterior-posterior (AP) and lateral, and both elbows AP and lateral are taken. Knee X-rays can be excluded in children over 6 years of age. Elbows are taken if children are over 5 years of age. At birth, there are two centers in the hand—capitate and hamate. A preterm child may not have any centers in the hand. The knee X-ray will show the lower femur epiphysis that appears at the 36th week and the upper tibial epiphysis that appears at the 38th week. So, at birth, the X-ray of the knees is useful to evaluate hypothyroidism. The upper femur begins to ossify at about the 10th month and is seen as a well-defined round center by the age of 1 year. The carpal bones, with the exception of the pisiform, are very variable in their appearance. The pisiform appears by the age of 10 in girls and 11 in boys (Fig. 4.5). By 1 year 6 months, the distal radius is present. Though there is variability, it is definitely seen at 2 years. In contrast, the distal ulna is widely variable. All metacarpals appear by 2–3 years, but the second metacarpal is earlier by a few months. The base of the first metacarpal shows great constancy and can be used as a marker for 2 years 6 months.

In the elbow, the medial epicondyle appears by 7–8 years, the lateral epicondyle by 11 years. The olecranon is seen at about 10–10 years 6 months (Fig. 4.6). The radial head is definitely seen by 7 years and may appear at 6 years (Fig. 4.7).

There is a lack of indicators between the age groups of 3 years (seen in the hand) and 7 years (seen in the elbow). For this, the patella center can be used. A lateral X-ray of knees should be evaluated for the presence of the center for the patella. This shows great constancy and is seen by the age of four in both boys and girls. It should be remembered that epiphyseal centers in



Fig. 4.5: Hand PA view. The pisiform has appeared.

JAYPEE BROTHERS



Fig. 4.6: Elbow lateral. Note the olecranon center.



Fig. 4.7: The anteroposterior elbow shows the presence of radial head, medial, and lateral epicondyles.

general appear a little earlier in girls. But, the aforementioned centers do not show any remarkable difference between boys and girls (Fig. 4.8).

The triradiate cartilage fuses by 15 years (range 13–15 years) and the entire iliac crest appears by 16 years. In female children, it fuses soon after while in boys it may fuse only at 18 years (range 18–20 years). In general, ossification centers of long bones fuse by about 17 years.

Skeletal maturity is known to vary as much as 2 years on either side of chronological age in normal healthy children between ages 5 years and 14 years. So a discrepancy of more than 2 years is required to diagnose problems in maturation. After making an initial diagnosis using the aforementioned method, further accurate determination of bone age can be done when necessary by the other methods.



Fig. 4.8: Knees lateral for patella center.

CHROMOSOMAL DISEASES

Turner's Syndrome

The genetic defect is a single X chromosome (45XO), partial deletion of X chromosome or mosaicism. The characteristic radiological sign is short fourth metacarpal giving rise to the metacarpal sign (Fig. 4.9). When a line drawn tangential to the heads of the fourth and fifth metacarpals is extended, it normally passes distal to the head of third

JAYPEE BROTHERS



Fig. 4.9: Turner's syndrome. Note the short fourth and fifth metacarpals.



Fig. 4.10: Down's syndrome. Note the overhanging anterior superior iliac spine.

metacarpal. If it transects the head of the third metacarpal, the sign is positive as in Turner's syndrome. The fifth metacarpal can also be short. In older children, skeletal age is delayed.

NOONAN'S SYNDROME

This is the male phenotype of Turner's without chromosomal anomaly. There are short metacarpals and osteoporosis.

DOWN'S SYNDROME

The genetic defect is an extra 21 chromosome. The iliac wings are flared with horizontal acetabular roofs (Fig. 4.10). Sometimes there are 11 pairs of ribs. There may be maldevelopment of the dens with atlantoaxial instability. The skull is brachycephalic.

Trisomy 13, 18, and Cri Du Chat Syndrome

All these have microcephaly and micrognathia. The pelvic bones are hypoplastic.

SKELETAL DYSPLASIAS

Skeletal dysplasias are a large group of disorders characterized by defective growth of bone and cartilage, which results in abnormality of the shape, size, and proportions of the skeleton. They are classified according to the skeletal abnormalities and more recently according to the underlying molecular genetic cause. The number of dysplasias is enormous and beyond the scope of this book. Some common dysplasias will be examined here. The first step is a clinical suspicion of a dysplasia. Short stature is a feature of most dysplasias. So, anthropometric measurements are necessary to decide whether proportionate or disproportionate shortening is present. Proportionate shortening is usually due to constitutional delay, familial short stature, endocrine disorders like growth hormone deficiency or hypothyroidism, as well as some congenital malformation syndromes. For this, skeletal maturation and bone age determination with X-ray is all that is required. When it is disproportionate

JAYPEE BROTHERS

shortening, radiological studies are called for. All the bones starting from the pelvis and axial skeleton to the limbs are studied. Essential X-rays are X-ray AP of the pelvis with both lower limbs, dorsolumbar spine AP and lateral, both hands PA and sometimes the skull. These X-rays help in coming to a conclusion in most cases. Further reference from specialty books can then be done.

Achondroplasia

Inheritance

- Autosomal dominant inheritance
- Common nonlethal dysplasia.

Radiological Features (Fig. 4.11)

Pelvis: The iliac wings are small and square. Acetabular roofs are horizontal. The sacrosciatic notches are narrow. Champagne glass appearance of pelvic brim.

Spine: The spinal canal is narrow. The interpedicular distance will taper downward toward L5 or will remain parallel. This is the hallmark of achondroplasia. Normally the interpedicular distance widens from L1 to L5.



Fig. 4.11: Achondroplasia and square ilium. Thick short bones.

Long bones: Rhizomelic shortening, i.e. shortened proximal segments (humerus and femur). Bones are also thick. The upper femoral metaphysis is bulbous while the lower femoral metaphysis slants obliquely.

Hands: Metacarpals and phalanges are short and stubby.

Skull: The vault is large and base of skull is short.

Hypochondroplasia

Inheritance

- Autosomal dominant
- Genetically distinct from achondroplasia
- Clinically like mild form of achondroplasia, but skull and face are normal.

Radiological Features

Pelvis, spine, and bones similar to achondroplasia, but appears less severe. Skull is normal.

Thanatophoric Dysplasia

Inheritance

- Not certain
- The most common lethal dysplasia in newborns
- Severe short-limbed dwarfism.

Radiological Features

Pelvis: Pelvis as in achondroplasia (Fig. 4.12).

Spine: Flattened vertebral bodies. Narrow interpedicular distance like achondroplasia.

Long bones: Severe rhizomelic shortening. There is flaring at the metaphyses and bent shafts—telephone handle appearance.

JAYPEE BROTHERS



Fig. 4.12: Thanatophoric dysplasia. Flattened vertebrae and short bones with bent shafts.

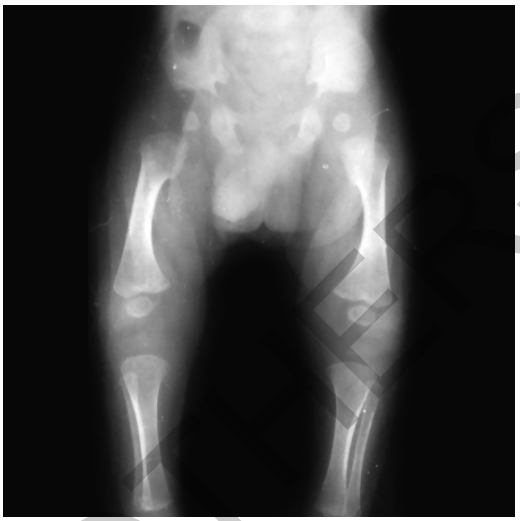

Fig. 4.13: Asphyxiating thoracic dysplasia—square ilium. Note the rounded upper femoral epiphysis.

Hands: Extremely shortened metacarpals and phalanges.

Skull: Skull base is short and vault is large with frontal bossing and cloverleaf appearance of the skull.

Asphyxiating Thoracic Dysplasia (Jeune's Disease)

Inheritance

- Autosomal recessive

Radiological Features

Pelvis: Iliac wings are squared as in achondroplasia (Fig. 4.13). Acetabular roofs show inferomedial projections at the sacrosciatic notches. Early appearance of the upper femoral epiphyses—a useful diagnostic feature.

Skull and spine: Normal.

Thorax: The ribs are extremely short causing respiratory embarrassment, the reason for the name (Fig. 4.14).

Long bones: Mild shortening. Hands: There may be polydactyly.



Fig. 4.14: Asphyxiating thoracic dysplasia. Very short ribs.

Chondroectodermal Dysplasia (Ellis-van Creveld Syndrome)

Inheritance

- Autosomal recessive

JAYPEE BROTHERS

Radiological Features

Pelvis: Iliac wings are mildly squared. Acetabular roofs show inferomedial projections at the sacrosciatic notches as in asphyxiating thoracic dysplasia.

Skull and spine: Normal.

Thorax: Short and horizontal ribs giving a bell shape to the chest (Fig. 4.15).

Long bones: Mesomelic shortening. The proximal tibial epiphysis shows a medial slope (Fig. 4.16).

Hands: Short bones. Polydactyly, usually postaxial. Carpal fusions especially capitate and hamate. Delayed maturation of the carpal bones compared to the phalanges. In addition, dental abnormalities, hypoplastic nails, or sparse hair may be present.

Short Rib Polydactyly Syndromes

There are three distinct syndromes, but the common features are short ribs and preaxial polydactyly (Fig. 4.17). The additional features are as follows:

Type 1: Saldino-Noonan syndrome: Small iliac bones and short tubular bones.

Type 2: Majewski syndrome: Pelvis is normal, but femoral heads ossify early. Mesomelic shortening. Tibia is ovoid in shape (Fig. 4.18).

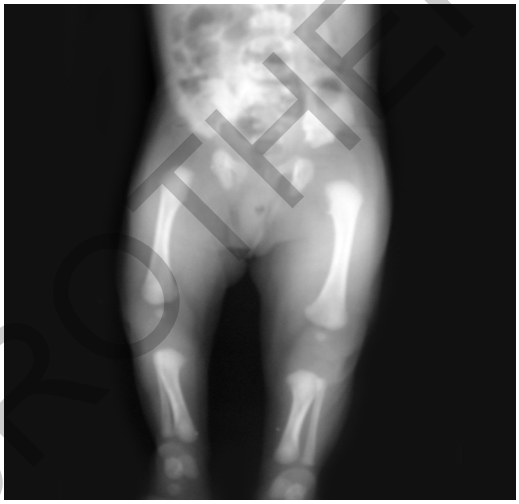

Fig. 4.16: Ellis-van Creveld syndrome—pelvis. Note the medially sloping metaphyses.

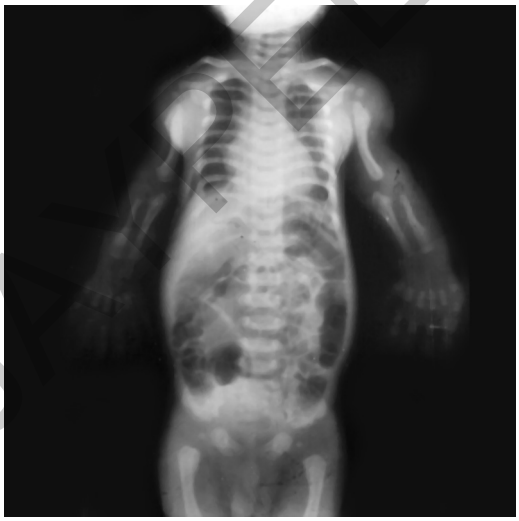

Fig. 4.15: Ellis-van Creveld syndrome. Bell-shaped chest and sloping metaphysis.

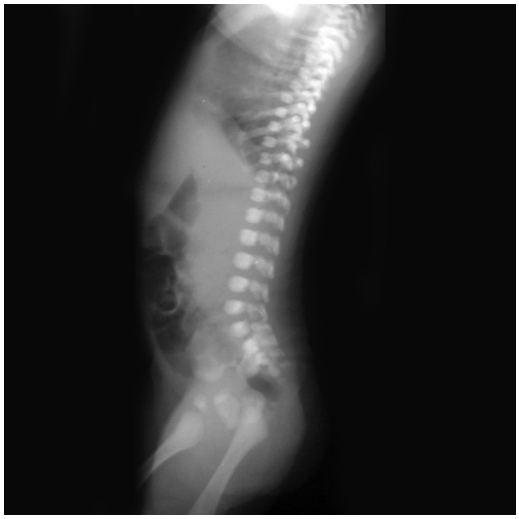

Fig. 4.17: Short rib polydactyly syndrome. Very short ribs.

JAYPEE BROTHERS



Fig. 4.18: Majewski type short rib polydactyly syndrome. Mesomelic shortening. Ovoid tibiae.

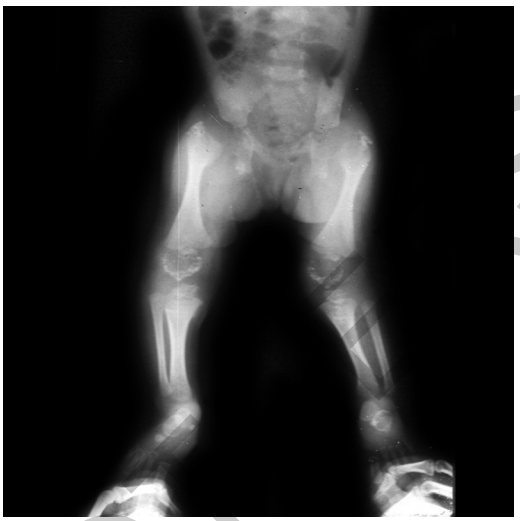

Fig. 4.19: Chondrodysplasia punctata. Stippled epiphysis.

Type 3: Verma-Naumoff syndrome: Short tubular bones, vertebral flattening.

Chondrodysplasia Punctata

Inheritance

There are three types:
1. Conradi-Hunermann—autosomal dominant
2. Rhizomelic form—autosomal dominant
3. X-linked form.

Radiological Features

Pelvis: Bones are normal. But multiple discrete punctate calcifications in the unossified epiphyses are seen (Fig. 4.19).

These may coalesce to form epiphysis or disappear by 3 years of age. Such stippling can be seen in other cartilaginous areas like trachea (Fig. 4.20).

Long bones: Rhizomelic shortening.

Hands: Stippling around the carpus.



Fig. 4.20: Chondrodysplasia punctata. Stippling seen in the tracheal and bronchial cartilages.

Spine: Coronal cleft in vertebrae. Wedge-shaped vertebrae.

Skull: Normal

Metatropic Dysplasia

The name is due to the changing pattern of disease. At first dwarfism is due to short

JAYPEE BROTHERS



Fig. 4.21: Metatropic dysplasia—pelvis.

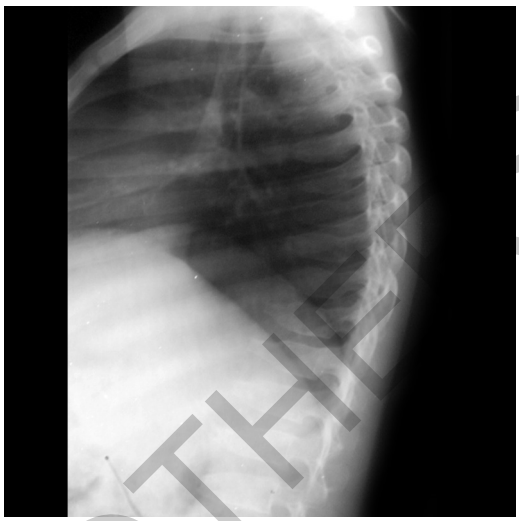

Fig. 4.22: Metatropic dysplasia—platyspondyly.

limbs. Later flattening of the vertebrae and kyphoscoliosis makes the trunk also short.

Radiological Features

Pelvis: The lower parts of the iliac bones are hypoplastic. Roof of acetabulum is horizontal and ischial and pubic bones are thick (Fig. 4.21).

Spine: Progressive platyspondyly. The anterior edges are more flattened or wedged (Fig. 4.22).

Long bones: Short with pronounced metaphyseal flaring.

Hands: Short with metaphyseal flaring (Fig. 4.23).

Thorax: Slightly narrow.

Skull: Normal.

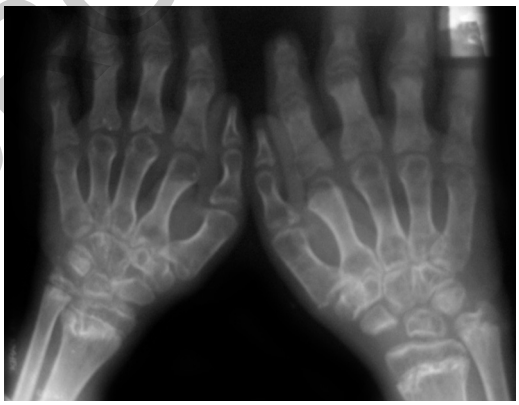

Fig. 4.23: Metatropic dysplasia—hands. Note widened metaphyseal ends.

Cleidocranial Dysplasia

Inheritance

- Mostly autosomal dominant, sometimes mutation

Radiological Features

Pelvis: Symphyses apparently widened because the pubic bones show delayed ossification (Fig. 4.24).

Spine: Likewise, there is a persistence of the synchondroses between the neural arches and the vertebral bodies.

Thorax: Clavicles are hypoplastic or even absent. The ribs are a little short and scapulae are small (Fig. 4.25).

JAYPEE BROTHERS



Fig. 4.24: Cleidocranial dysplasia. Pubic bones not ossified.

Long bones: Normal.

Hands: The terminal phalanges are short. The second metacarpal is long. Accessory ossicles are present.

Skull: Delayed closure of anterior fontanelle. Many Wormian bones. Persistent metopic suture.

Metaphyseal Chondrodysplasia

This is a group of dysplasias characterized by abnormal metaphyses.

Radiological Features

Pelvis: Normal.

Spine: Normal. In lateral view, the vertebral bodies may be ovoid.

Thorax: Normal.

Long bones: Flaring and irregularity of the metaphyses. The epiphyseal growth plate is apparently wide due to the dysplastic metaphyses (Fig. 4.26).

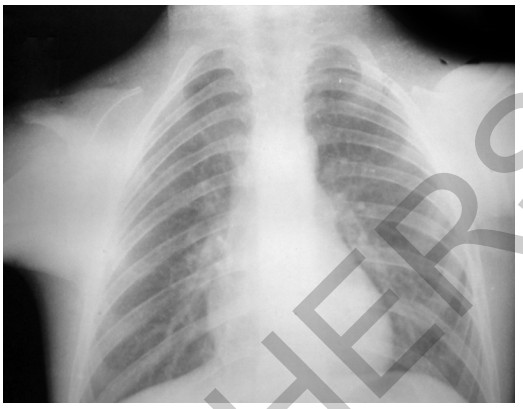

Fig. 4.25: Cleidocranial dysplasia. Absent clavicles.

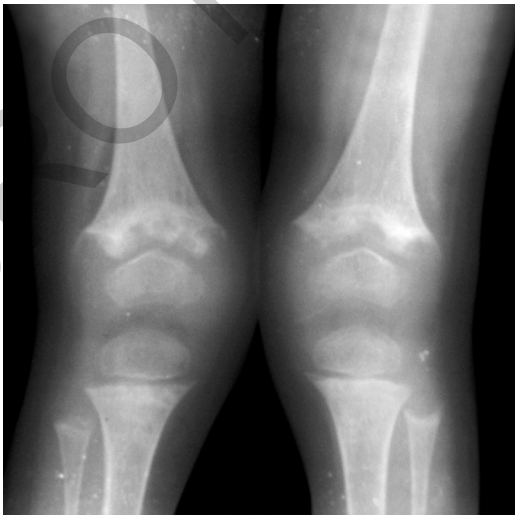

Fig. 4.26: Metaphyseal chondrodysplasia. Both femora and fibulae are involved. DD rickets in which all bones are involved.

Hands: Likewise flaring and irregularity of metaphyses.

Skull: Normal. Schmidt type—aforementioned features, Jansen type—severe such features with skull base sclerosis, McKusick type (cartilage/hair hypoplasia)—additional feature is sparse hair. Pena type—longitudinal striations in the expanded metaphyses.

JAYPEE BROTHERS

for detailed information on pediatrics books, visit our website www.jaypeebrothers.com, for detailed information on pedia

IAP Textbook of
PEDIATRIC RADIOLOGY

The Editorial team of IAP Textbook of Pediatric Radiology, after sincere and hardworking effort is bringing out this book which have a lot of useful information on conventional radiology which will help the pediatricians in their day-to-day office practice as a ready to refer guide in pediatric radiological investigations. This book also contains information on many of the emergency radiological investigation. Despite the advent of various Electronic Radiological Gadgets the conventional plain X-ray, remains to be one of the most celebrated investigation in every nook and corner across the globe.

In this Second edition, there are few value added additions such as Digital Radiography and case scenarios of clinical importance almost in all essential chapters. The value of this book is further enhanced as all the authors are pediatric veterans who are also renowned teachers in various medical colleges in India. No doubt, that this book will be of immense help for UG and PG students, practicing pediatricians and teaching faculties alike.

Available at all medical bookstores
or buy online at www.jaypeebrothers.com



JAYPEE BROTHERS
Medical Publishers (P) Ltd.
www.jaypeebrothers.com
Join us on facebook.com/JaypeeMedicalPublishers

Shelving Recommendation
PEDIATRICS

ISBN 978-93-89188-97-4

