ers.com, for detailed information on pediatrics books, visit our website www.jaypeebrothers.com, for detailed information on pediatrics books



Practical Pediatrics

HIGHLIGHTS

The book contains:

- Various nutritional aspects of food items, proper feeding of children and disorders caused by nutritional deficiency
- Indications, contraindications, adverse effects of various drugs and vaccines
- Methods of using various medical devices and instruments
- Radiological features of various disorders

Aruchamy Lakshmanaswamy

JAYPEE

Contents

1. Nutrition **1**
- ❑ Nutritive Values of Food Items 11
- ❑ Recommended Daily Allowance 39
- ❑ Nutritional Disorders 40

2. Instruments and Procedures **48**
- ❑ Antropometry 48
- ❑ Skinfold Caliper 52
- ❑ Instruments to Record Vital Signs 53
- ❑ Blood Pressure 55
- ❑ Needles 56
- ❑ Biopsy Needles 67
- ❑ Syringes 73
- ❑ Tubes 74
- ❑ Catheters 87
- ❑ Bags 91
- ❑ Infusion Sets 92
- ❑ Oxygen Delivery Systems 93
- ❑ Pediatric Breathing Circuit 96
- ❑ Newborn Resuscitation 97
- ❑ Asthma Devices 108
- ❑ Airways 113
- ❑ Miscellaneous 115

3. Radiology—X-rays **119**
- ❑ General Considerations 119
- ❑ X-rays Chest 125
- ❑ Cardiovascular System 138
- ❑ Respiratory System 151
- ❑ Abdomen 186
- ❑ Endocrine System 192
- ❑ Chromosomal Disorders 194
- ❑ Genitourinary System 196
- ❑ Hematology 198

Musculoskeletal System **201**
- ❑ General 201
- ❑ Skeleton 203
- ❑ Skull 218
- ❑ Neck 219
- ❑ Pelvis 219
- ❑ Newborn 221

Pediatric Surgery **234**
- ❑ Cardiovascular System 234
- ❑ Respiratory System 237
- ❑ Gastrointestinal System 245
- ❑ Miscellaneous 275

4. Drugs **278**
- ❑ Antibiotics 279
- ❑ Antivirals 308
- ❑ Antifungals 312
- ❑ Antiprotozoal 315
- ❑ Anthelmintics 319
- ❑ Antihistaminics 322
- ❑ Cholinergic Drugs 324
- ❑ Sympathomimetic/ Inotropic Drugs 329
- ❑ Antihypertensives 339
- ❑ Antiasthmatics 349
- ❑ Sedatives Hypnotics 358
- ❑ Opioids 363
- ❑ Anticonvulsants 368
- ❑ Corticosteroids (Glucocorticoids) 384
- ❑ Hormones 390
- ❑ Diuretics 396
- ❑ Cardiac Glycosides 401
- ❑ Chelating Agents 407
- ❑ H2-receptor Blockers 408
- ❑ Miscellaneous 411

5. Vitamins **449**
- ❑ Vitamin A 449
- ❑ Vitamin B_{12} (Cyanocobalamin) 453
- ❑ Vitamin D 455
- ❑ Vitamin E 458
- ❑ Vitamin K 459

6. Intravenous Fluids **464**
- ❑ Intravenous Fluid Requirements 465
- ❑ Crystalloids 467
- ❑ Colloids 475
- ❑ Blood Products 482

7. Vaccines **483**
- ❑ Vaccines for General use 485
- ❑ Vaccines used on Special Occasions 515
- ❑ Combination of Vaccines 534
- ❑ Duration of Protection Offered by Vaccines 537
- ❑ Contradictions Precautions for Immunization 537
- ❑ Vaccination Failure 538
- ❑ Vaccine Storage 538
- ❑ Adverse Events following Vaccination 545
- ❑ National Vaccine Injury Compensation Program 552

8. Supplement on Vaccines—2019 ..... **554**
- ❑ Immunization Schedule of Vaccines 554
- ❑ High-risk Group 560
- ❑ Immunization Schedules 560
- ❑ Catch-up Vaccination 560
- ❑ Vaccine Schedule for an Unimmunized Child 560

Annexure *563*

Index *565*

3 CHAPTER

Radiology—X-rays

CHAPTER OUTLINE

- General Considerations
- X-rays Chest
- Cardiovascular System
- Respiratory System
- Abdomen
- Endocrine System
- Chromosomal Disorders
- Genitourinary System
- Hematology
- **Musculoskeletal System**
- General
- Skeleton
- Skull
- Neck
- Pelvis
- Newborn
- **Pediatric Surgery**
- Cardiovascular System
- Respiratory System
- Gastrointestinal System
- Miscellaneous

INTRODUCTION

Reading X-rays is an important aspect of medicine. This chapter gives you the details of X-ray finding in various clinical conditions.

GENERAL CONSIDERATIONS

Radiology Basics—Plain, Contrast

Q1. How X-rays are produced?

X-rays are produced when electron beam produced from cathode (tungsten filament) strikes the anode (thermionic emission) made of tungsten.

Q2. What are the effects of radiation on the fetus?

Dose of 0.1 Gy (10 rad) to the embryo or fetus is recommended as a threshold dose. Radiation of 500 millirads (mrad) (limit) may lead to microcephaly, mental retardation. Now the units Sievert/Gray is followed instead of rads.

Q3. When is therapeutic abortion recommended in radiation?

Therapeutic abortion recommended when the radiation 0.1 Gy (10 rad) to the embryo or fetus.

Large doses of radiation are harmful to the central nervous system. There is increased incidence of leukemia and cancer in the children, when there is a history of exposure of irradiation in the antenatal period. Exposure to irradiation should be avoided in the first trimester of pregnancy.

Q4. What is Rule of 10 for radiological exposure of any female in the reproductive age group?

JAYPEE BROTHERS

The ovulation takes place by about 14 days prior to the first day of next menstrual cycle. There is possibility that the ovum can get fertilized by a sperm that is present in the female genital tract 3–4 days before this day. Hence any exposure to radiation after this time can result in exposure of the fertilized ovum. To avoid this, the exposure to radiation should be restricted to first 10 days of the menstrual cycle.

Q5. Where should be the X-ray film kept in posteroanterior (PA) view?
The film should be placed against the front of the patient's chest.

Q6. What should be the distance between the patient and the X-ray tube?
The X-ray tube should be 2 m away from the patient.

Proper immobilization is essential.

Q7. What are the best positions/views to diagnose various conditions?
Best positions to diagnose various conditions are:

Conditions	Best positions/views
Left pleural effusion	Left lateral decubitus
Right pleural effusion	Right lateral decubitus
For mitral valve	Right anterior oblique
Left atrial enlargement	Barium swallow
Tracheal bifurcation	Left anterior oblique
Renal scan	Prone position
Barium meal in hiatal disorders	Trendelenburg position

Best views to diagnose various conditions are:

Conditions	Best views
Pneumothorax—foreign body	Expiratory film
Chest X-ray for cardiac and other respiratory problems	Inspiratory film

Q8. Which is the investigation of choice for sequestration of lung?
Angiography is the investigation of choice for sequestration of lung.

Q9. Which is the investigation of choice for minimal pericardial effusion, mitral stenosis?
ECHO is the investigation of choice for minimal pericardial effusion, mitral stenosis.

Q10. Which is the investigation of choice for minimal ascites?
Ultrasonogram abdomen is the investigation of choice for minimal ascites.

Q11. What are the views taken in children?
a. Anteroposterior (AP) view is taken for children below 3 years with child lying in supine position.
b. X-ray lateral view with child lying in supine position
c. Erect PA view is taken for children above 3 years of age.

Q12. What are the important views in which X-rays are taken?

Views	Part best viewed
Towne view	Paranasal sinuses, mastoid air cells, petrous sinus, internal acoustic meatus
Water view	Maxillary sinus, floor of orbit
Caldwell's view	Frontal sinus, ethmoidal sinus
Lateral view	For sphenoidal sinus
Lordotic	For apex lingual lobe of lung
Reverse lordotic	Interlobar effusion
Oblique	Spondylolisthesis
Von Rosen	Congenital dislocation of the hip (CDH)
Skyline	Fracture patella
Stryker's view	Recurrent subluxation/ dislocation of shoulder
Lateral skull view	Sella turcica

Q13. What is the difference between consolidation and ground glass opacity?
Consolidation is increase in lung attenuation with obscuring the underlying vasculature.

Ground glass opacity is increased in lung attenuation without obscuring the underlying vasculature.

Radiological Findings—Head to Foot

General

X-ray bones: Dense bones—osteopetrosis.

JAYPEE BROTHERS

Skull

- Skull X-ray:
  - Hair on end appearance—thalassemia
  - Widening of sutures—increased intracranial tension.
- X-ray changes (in the skull) in increased intracranial tension:
  - Sutures—widened
  - Erosion of posterior glenoids
  - Silver beaten appearance
  - Deep sella turcica.

Neck

X-ray neck lateral view:

- Prevertebral space—when X-ray neck is taken with neck extended, the shadow should be more than one-half of the width of the adjacent vertebral body
- Retropharyngeal abscess
- Subcutaneous air in the neck, axilla, supraclavicular region—subcutaneous emphysema.

Chest

X-ray chest:

- Steeple sign—hyperinflated lung with narrowing of trachea will be seen in acute laryngotracheal bronchitis. This is known as steeple sign.
- Thumb sign—observed in X-ray neck lateral views and is seen in swollen epiglottis.
- Silhouette sign—right middle lobe pneumonia homogeneous opacity in the middle and lower zone obliterating the medial border of the heart on that side.

a. Lungs:

X-ray findings	Diagnosis	Points
Homogeneous opacity in the right upper lobe	Upper lobe pneumonia	Air bronchogram will be seen
Haziness over the entire lung in children with lying down posture	Pleural effusion	Cardiophrenic and costophrenic angle will be obliterated

Contd...

Contd...

X-ray findings	Diagnosis	Points
Fluid level in erect posture	Pleural effusion, hydropneumothorax	Mediastinal shift to opposite side
Homogeneous opacity	Empyema	Cardiophrenic and costophrenic angle will be obliterated Mediastinal shift to opposite side
Dilated bronchioles, linear streaking	Bronchiectasis	Honeycomb appearance
Air shadow between lung and pleura, hyperlucency without lung markings	Pneumothorax	Mediastinum will be shifted to opposite side ICD should be done at second intercostal space
Patchy shadow	Consolidation	
Thick walled cavity with air fluid level	Lung abscess	
Miliary mottling	Miliary tuberculosis, eosinophilia	Diffuse mottling shadows
Hilar adenopathy	Tuberculosis, lymphomas	
Bilateral hyperventilation	Bronchial asthma, bronchiolitis	
Diffuse, fluffy infiltrate in perihilar region	Pulmonary edema	Batwing appearance, butterfly distribution
Kerley B lines—enlarged lymphatics in the intralobular septum	Pulmonary edema	Will be associated with cardiomegaly
Elevation of diaphragm	Diaphragmatic hernia, eventration of diaphragm	Congenital pulmonary adenomatoid malformation may resemble these conditions

Features of oligemic lung fields:
The vascular markings will cover less than one third of the lung field

JAYPEE BROTHERS

Features of plethoric lung fields:
The vascular markings will cover more than two third of the lung field.

b. Heart:

X-ray findings	Condition
Jug-handle appearance	Atrial septal defect (ASD)
Boot shaped heart	Tetralogy of Fallot (TOF)
Cardiomegaly—cardiothoracic ratio >60 (in adults 50 is significant)	• Cardiac failure • Cardiomyopathy (dilated) • Pleural effusion
Peripheral pruning of pulmonary vessels	Pulmonary hypertension
Money bag appearance, water bottle appearance	Pericardial effusion
Snowman appearance—Figure of 8 appearance	Total anomalous pulmonary venous drainage (TAPVD)
Egg on side appearance	Transposition of the great vessels (TGV)
Air around the heart	Pneumopericardium

c. Mediastinum:

- Causes of mediastinal widening:
  - Tuberculous hilar adenopathy
  - Tumors
  - Tumors of thymus—thymoma
  - Teratoma
  - Hodgkin's lymphoma
  - Neuroblastoma
  - Aberrant thyroid.
- Dextrocardia:
  - Dextrocardia with situs solitus: Apex will be on the right side with normally related abdominal organs
  - Dextrocardia with situs inversus: Apex will be on the right side with transposition of abdominal organs (liver and stomach).

d. Diaphragm:

- Diaphragmatic hernia
- Eventration of diaphragm.

Abdomen—X-ray abdomen:

- Multiple fluid levels—intestinal obstruction
- Air under diaphragm—Intestinal perforation
- Intravenous pyelogram (IVP)
- Micturating (MCU) cystourethrogram—vesicoureteral reflux.

Upper limbs/hands:

- Phalanx—middle constriction maintained in Morquio's, mucopolysaccharidoses
- Bullet-shaped—Hurler's syndrome

X-ray wrist:

Bone age—look for number of epiphysis

- Decreased bone age—bone age will be decreased in hypothyroidism, rickets, osteogenesis imperfecta
  - Rickets—widening of epiphysis, cupping, widening and fraying of metaphysis the distal end of long bones like radius.
  - Increased height of the physeal plate.

Lower limbs:

X-ray lower end of femur and upper end of tibia:

- Absent epiphysis—hypothyroidism

Vertebral column:

X-ray vertebral column: Bamboo spine in Ankylosing spondylitis due to syndesmophytes (Calcified intervertebral ligaments).

X-ray pelvis:

Flaring of iliac crest—Down syndrome.

Contrast studies:

- *Barium enema*: Apple core appearance of the sigmoid colon—carcinoma colon.
- Intravenous pyelography
  - Spider leg appearance—polycystic kidney
  - Thimble bladder—tuberculosis (TB) of bladder.
- Intravenous urography (IVU)
  - Flower vase appearance of ureters—horseshoe kidney
  - Golf hole ureter—TB urinary bladder
  - Cobra head deformity—in IVP—ureterocele.

JAYPEE BROTHERS

QUESTIONS

Q1. What are the criteria for cardiomegaly in X-ray chest?
The cardiothoracic ratio will be more than 60% in newborn babies and >50% in adults.

Q2. What is the condition associated with box-shaped cardiomegaly?
Ebstein anomaly.

Q3. What are the conditions associated with decreased bone age?
Bone age will be decreased in hypothyroidism, rickets, and osteogenesis imperfecta.

Increased Intracranial Tension

- Separation of sutures
- Silver beaten appearance
- Erosion of glenoids
- Deepening of sella turcica

Clinical Examination

- Fundus examination will show papilledema
- Blood pressure will be elevated
- Heart rate decreased

Clinical Features

- Headache
- Vomiting.

Invertogram

A plain X-ray is taken with the child held upside down about 12–24 hours after birth (Fig. 3.1).

Lateral Radiograph of Abdomen

Lateral radiograph of abdomen (Fig. 3.2) helps to differentiate abnormal gas-filled/fluid levels containing structures such as:

- Stomach on lateral radiograph anterior transverse fluid level under left dome of diaphragm
- Duodenum is seen near colon, posterior
- Air in the bladder is seen in anterior retropubic region
- Portal vein gas shadow which is centripetally placed seen in advanced necrotizing enterocolitis (NEC).

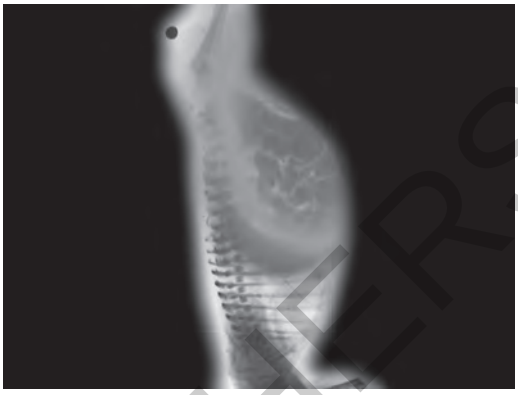

Fig. 3.1: X-ray—invertogram for anorectal anomalies.

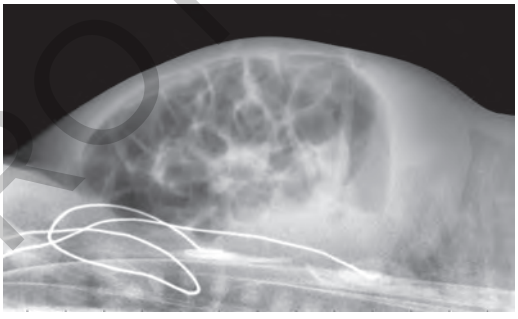

Fig. 3.2: X-ray lateral radiograph of abdomen.

Prone Cross Table Lateral View (Fig. 3.3)

- It helps to differentiate mechanical from functional obstruction for ileus.
- It also serves an alternative to invertogram in anorectal malformations.
- Absent air indicates mechanical obstruction. Rectal gas suggests paralytic ileus.

QUESTIONS

Q1. How will you read a normal X-ray?

- See for the symmetry of clavicles
- Look for bones
- Look for ventilation of lungs
- Look for the location of liver and stomach gas bubble

JAYPEE BROTHERS

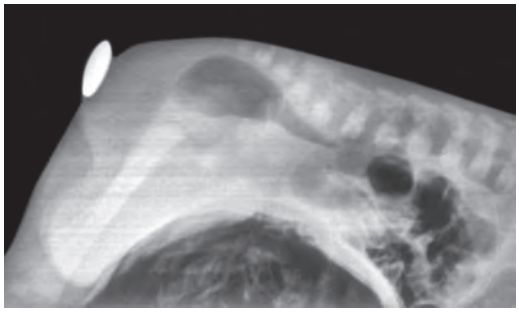

Fig. 3.3: X-ray—prone cross-table lateral view for anorectal anomalies.

- ❑ Identification of aorta
- ❑ Upper mediastinum
- ❑ Pulmonary parenchyma

See for the symmetry of clavicles—if the X-ray is taken in proper position, the clavicles will be symmetrical on both sides.

Pectus excavatum will result in compression of heart in the AP dimension and result in compensatory increase in transverse diameter.

Look for ventilation of lungs and assess the bilateral symmetry.

Aeration or volume of lungs can be assessed by noting the level of diaphragm in adequate inspiration, the diaphragm should be at the level of 6th rib anteriorly or 8th rib posteriorly.

Motion artifacts—if the exposure is not short enough, there may be patient or respiratory movements causing blurring of the diaphragmatic contour and pulmonary vascular markings.

Evaluate each anatomic portion of the lung thoroughly.

Identification of aorta—descending aorta along the left margin of the spine will indicate a left aortic arch, descending aorta along the right margin of the spine will indicate a right aortic arch.

Q2. What is the distance between the X-ray source and the film?
Six feet.

Q3. In which phase of respiration will you take normal chest X ray (PA View)?
Deep inspiration.

Q4. What are the zones in X-ray chest?
There are three zones:

1. *Zone I*: Upper border—apex; lower border—line joining the lower borders of the anterior ends of the second costal cartilage.
2. *Zone II*: Upper border—line joining the lower borders of the anterior ends of the second costal cartilage; lower border—4th costal cartilage.
3. *Zone III*: Upper border—below the 4th costal cartilage; lower border—lower end of the lungs.

Q5. Do the zones represent the lobes?
No, the zones do not represent the lobes.

Q6. What are the differential diagnoses of an enlarged shadow at the right cardiac border?

- ❑ Hilar node enlargement
- ❑ Right-sided aortic arch
- ❑ Manubrium sterni

End on views of the blood vessels may be misinterpreted as enlarged hilar nodes.

Q7. How will you differentiate the hilar node from a right-sided aortic arch?
Right-sided aortic arch will indent the right wall of trachea but the hilar node irrespective of its size will not indent the trachea.

Q8. How will you differentiate the hilar node from a manubrium sterni?
Medial ends of the clavicle will be away from midline in manubrium sterni.

Q9. How will differentiate if unilateral increased translucency of lungs is due to air in the alveoli or pleural space?
If the air is in alveoli as in emphysema, the lung markings will be seen, in pneumothorax where the air is in the pleural space, the alveolar markings will not be seen.

Hilar lymph node enlargement. This will be seen as a convex outer margin.

JAYPEE BROTHERS

Q10. What is the feature of an overpenetrated postero anterior view of X ray chest film?
The lower thoracic vertebra will be seen clearly.

Q11. How will you differentiate between thymus shadow and mediastinal node?
Thymus shadow will be more diffuse whereas mediastinal node will be more globular.

Collapse and consolidation will confirm the shape and the site of a segment or lobe of the lung.

Q12. How will you differentiate between thymus shadow and cardiac shadow?
In thymus enlargement, the base of the heart will be normal.

Q13. What are the features of enlarged left atrial appendage?
- ❑ Prominent left atrial appendage at the left border of the heart
- ❑ Double shadow seen through the left atrium
- ❑ Upward displacement of the left main bronchus
- ❑ Compression of the esophagus will be evident in barium swallow study.

X-RAYS CHEST

Digital X-rays

Should be marked as R or L to indicate which part of the X-ray is right or left.

Q1. How to read a normal chest X-ray?
- ❑ A systematic approach to the X-ray interpretation is essential
- ❑ Also a good understanding of the basic pathology which causes structural changes is needed to a good X-ray interpretation.

Various Positions of X-ray Chest

- ❖ Supine
- ❖ Erect
- ❖ Lateral
- ❖ Decubitus (right or left lateral)
- ❖ Inversion
- ❖ Prone translateral (Fig. 3.4).



Fig. 3.4: Prone cross-table translateral position for anorectal anomalies and intestinal obstruction.

Various Projections of X-ray Chest

1. *Standard projections/views of X-ray chest*:
   - ❖ Posteroanterior view taken on full inspiration to examine the lungs, bony thoracic cage, mediastinum, great vessels
   - ❖ Lateral for retrosternal, retrocardiac and lung lesions.
2. *Additional projections*:
   - ❖ Anteroposterior view for vertebra, posterior mediastinal mass
   - ❖ Supine for patients under critical care
   - ❖ Lateral decubitus for pleural effusion
   - ❖ Expiratory view for pneumothorax
   - ❖ Lordotic view for apex of lung
   - ❖ Frontal view
   - ❖ Right anterior oblique (RAO) view/left anterior oblique (LAO) view for fractures and intrathoracic lesions.

Following of Technical and Clinical Aspects

- ❖ Technical aspects
- ❖ Clinical aspects.

Technical aspects:

- ❖ Technical points to be considered in X-ray evaluation

JAYPEE BROTHERS

- ❖ First evaluate the technical factors of the X-ray film
- ❖ Locate the right and left markers
- ❖ Centering—medial end of the clavicles should be equidistant from the spinous process.

1. *Position of the patient*: Is the patient straight or rotated? If the patient is straight the inner end of clavicles will be symmetrical with reference to the vertebral columns *Patient rotation*:
   - Quality of exposure or film
     - ♦ Under exposure
     - ♦ Over exposure
   - Is the film penetrated adequately?
2. *Quality of the film*: Readable quality or not, adequate inspiration, normal penetration, centered on mid chest. It should not be too white or too black in color.

   A quality of the film should have the following:
   - Adequate inspiration
   - Normal penetration
   - Centered on mid chest
   - Rotation—should not be rotated
   - Appropriate exposure.
3. *Penetration*: Adequate penetration should be enough to bring out the pulmonary details which are essentially the pulmonary markings. The penetration can be normal, under- or overpenetrated

   In normal penetration, the vertebral bodies and the disk spaces should be just visible at T8 and T9 level.

   The following points will indicate good penetration:
   - Pulmonary vascular markings are well brought out. Is it adequately penetrated or else the pulmonary details will not be brought out which are essentially the vascular markings.
   - Intervertebral disk spaces and vessels posterior to the heart are seen well. When the penetration is adequate, the intervertebral disk spaces and the vessels posterior to the heart are seen well. It should be adequately penetrated. Adequately penetrated films will bring out the details of pulmonary vascular markings.
4. *Degree of rotation*: Note the distance between the center of the vertebral bodies and the lateral aspect of ribs. See if the medial end of clavicle is equidistant from the midline.
   - Medial ends of the clavicle should be equidistant from each other.
   - Aeration of the lungs can be assessed by noting the level of the diaphragm.
   - In adequate respiration, the diaphragm will be at the level of the 6th rib interiorly and 8th rib posteriorly.
   - Two-thirds of the heart will lie on the left side of the chest and one-third on the right.
   - The left side of the heart will be made of left atrium and left ventricle.
   - Superior vena cava (SVC) will lie above right heart border.
   - Expiratory or inspiratory film—see if the area of interest is covered.

Clinical aspects:

Read the film from out to in or from in to out. The anatomic parts should be thoroughly evaluated. Look at the position of clavicles. The medial ends of the clavicles should be equidistant from the midline. Look at the soft tissues and the bony cage.

Note the Following Structures

- ❖ Bones (ribs, clavicle, scapula, spine, shoulder joint) and soft tissues (cutaneous tissue, muscles, breast)
- ❖ Bony cage
- ❖ Cardiac shadow
- ❖ Lung shadow
- ❖ Diaphragm and subdiaphragmatic area
- ❖ Mediastinum (superior mediastinum, hilum, etc.)
- ❖ Bronchial—normal/inverted/ambiguous
- ❖ Aortic arch side—left or right

JAYPEE BROTHERS

- Upper abdomen: Abdominal situs—normal/inverted/ambiguous.

Note the Following Areas

- Cardiophrenic angle
- Costophrenic angle
- Trachea
- Mediastinal shift.

Systematic approach—should be followed so that no part is missed. The X-ray can be evaluated in the following order:

- Extrathoracic
  - Abdomen
  - Neck
  - Soft tissues
  - Bones
- Thorax
- Mediastinum—mediastinal silhouette on each side
  - Position, size and density of each hilum
  - Thymus
  - Trachea and bronchi/tracheal position look at the trachea especially right wall
- Position and shape of diaphragm
- Costophrenic angles
- Great vessels
- Bronchial situs—normal/inverted/ambiguous
- Aortic arch left sided or right sided
- Heart—side, apex, size, contour and shape
  - Side—right/left
  - Direction of apex
  - Size—CT ratio 55–60%
  - Gross cardiac anatomy
  - Contour.

Lung fields—pathological conditions like consolidation, pneumonia. The minor interlobar fissure will be separating the right upper and middle lobes and will be seen running horizontally in the third and fourth right intercostal spaces.

Lung vasculature—plethora, oligemia, pulmonary venous engorgement.

Diaphragm—the level of the diaphragm will be lower on the side of the apex.

Upper abdomen—look for abdominal situs—normal/inverted/ambiguous. Look for free air under the diaphragm.

Musculoskeletal—vertebra, rib abnormalities.

Tubes and catheters—always compare each part with the corresponding opposite side.

- Retrocardiac space
- Abdominal situs—normal/inverted/ambiguous
- Bronchial—normal/inverted/ambiguous
- Aortic arch side—left or right.

Look for the location of liver and stomach gas bubble—the cardiac apex will be on the same side of the stomach and opposite side of the liver shadow. In heterotaxia, the apex will be on the right and the stomach on the left side. Midline liver will be associated with asplenia—Ivemark syndrome or polysplenia syndrome. Carefully look in a sequence the parts like soft tissues, bones, aeration of each lung in the upper, middle and lower thirds as well as medial, mid and outer thirds by comparing with the opposite sides.

Look for the vascularity in each of these zones

Look for tracheal position. The trachea should be in central position.

Bones and soft tissues:

- Bony cage and soft tissue of thoracic wall
- Bony skeleton—look at the position of clavicles. Is the chest symmetrical? Is there any scoliosis?
- Are the ribs crowded or widely spaced? If so note the areas in which the abnormalities are noted. Look for the presence of cervical ribs. Look for erosion of ribs. Look for chest abnormalities like scoliosis.

Bony cage:

- Look for bones
- Rib notching will be seen in older children with coarctation of aorta.

JAYPEE BROTHERS

Cardiac shadow:

- Two-thirds of the heart will lie on the left side of the chest and one-third on the right.
- The left side of the heat will be made of left atrium and left ventricle.
- Superior vena cava will lie above right heart border.
- Heart—side—right/left
  - Direction of apex
  - Size—CT ratio 55–60%
  - Gross cardiac anatomy
  - Contour.
- Increased cardiac shadow will be seen:
  - Congestive cardiac failure (CCF)
  - Cardiomyopathy
  - Pericardial effusion.
- Dextrocardia is a condition in which heart is placed on the right side of the chest with the apex of the heart is pointing towards the right instead of normal heart pointing towards left. In isolated dextrocardia only the heart is placed on the right side with no other defects (Fig. 3.5). Dextrocardia is often associated with abdominal situs solitus or situs inversus. In this condition the right hemidiaphragm will be placed at a lower lever as compared to the left side. The apex of the heart will push down the diaphragm.
- Dextroposition is a form of dextrocardia with apex still directed to the left side (Fig. 3.6). This is a condition in which the heart is shifted to right either due to push by, diaphragmatic hernia, pleural effusion, etc. or pull due to fibrosis, collapse, etc.

Localization of the chambers:

Localization of the atria:

- The atrial situs will be the same as visceral situs. Localize the liver shadow and the stomach bubble
- Right-sided liver shadow and left-sided stomach bubble will indicate situs solitus. Situs solitus of atria will indicate that the right atria are on the right of the left atria. Situs inversus indicates liver is on the left side and the stomach bubble is on the right side (Fig. 3.7). Midline liver with variable

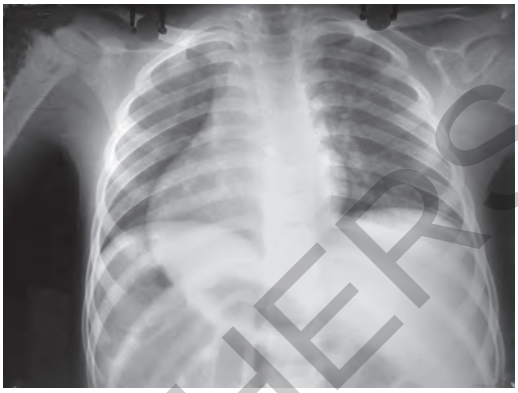

Fig. 3.5: Dextrocardia with situs inversus heart on the right side of the chest and apex facing right side. Note the diaphragm lies at lower level on the side of the apex.



Fig. 3.6: X-ray dextroposition with the cardiac shadow shifted to right with apex still facing to the left side.

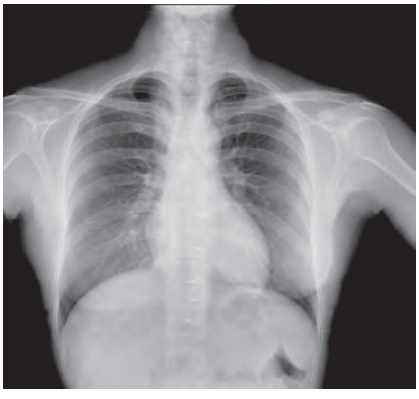

Fig. 3.7: Normal chest X-ray.

JAYPEE BROTHERS

position of stomach will indicate—situs ambiguous—two right atria or two left atria.

Localization of the ventricles:
Localization of the great arteries can be determined by angiocardiography.

Pulmonary vascular markings:

- Increased pulmonary blood flow: When the pulmonary blood flow is increased the pulmonary arteries will be enlarged and appear to extend into the lateral third of the lung field, where they are not usually present.
  - Increased vascularity to the lung apices where the vessels are normally collapsed.
  - The external diameter of the right pulmonary artery visible in the right hilum will be wider than the internal diameter.
- Decreased pulmonary blood flow—hilum appears small, remaining lung field appears black, vessels appear small and thin.
- Normal pulmonary blood flow.

Heart:

- Look at the cardiac size and shape. Two-thirds of the heart lies on the left side of the chest, with one-third on the right.
- Right heart border is formed by
  - SVC
  - Right atrium
  - IVC
- Left border is formed by
  - Aortic knuckle
  - Pulmonary artery (Main pulmonary trunk)
  - Left atrial appendage
  - Left ventricle
- On both sides trace the pulmonary artery branches which are seen fanning out through the lungs.

Hilum: Position, size and density of each hilum.

Position of the heart:

- The heart will be displaced as a whole in pleural effusion, pneumothorax, fibrosis, collapse of lung.
- In scoliosis, the heart will be displaced.
- In obesity, the heart will be lifted a upward and the apex will be tilted upward
- In adults, one-third of the heart will be lying on the right and two-thirds on the left side. In infancy, the heart is of transverse or globular and right side is equal to left side. By 5–7 years the heart will resemble the adult type.

Shape of the heart:

- In infancy and up to 5–7 years, the heart can be globular
- Globular shaped in pericardial effusion
  - Saber en boot or boot shaped heart in tetralogy of Fallot
  - Figure of 8 sign or snowman sign or dumbbell sign—in total anomalous pulmonary venous drainage (TAPVD)—supracardiac type
- Money bag appearance in pericardial effusion
- Scimitar-shaped in Scimitar syndrome
- Box-shaped heart in Ebstein anomaly.

Contours of cardiomediastinum:

- *Contours of right cardiomediastinum*:
  The following structures will form the right cardiomediastinal contour from superior to inferior:
  - Right paratracheal stripe is made up of right brachiocephalic vein and SVC
  - Arch of azygos vein
  - Ascending aorta
  - Lateral border of right atrium
  - Inferior vena cava (IVC).
- *Contours of left cardiomediastinum*:
  The following structures will form the left cardiomediastinal contour from superior to inferior:
  - Left paratracheal stripe is made up of common carotid artery, left subclavian artery and left jugular vein
  - Uppermost rounded or convex part—posterior part of transverse aortic arch (aortic knuckle or knob)
  - Below this flat or concave pulmonary conus—trunk of pulmonary artery

JAYPEE BROTHERS

- Below pulmonary conus—auricle of left atrium
- Lower, largest segment—left ventricle.

❖ *Contours of anterior cardiomediastinum (lateral view)*:
The anterior border is formed by the following structures from above downward:
- Superior mediastinum—great vessels, thymus
- Transverse part or arch or aorta
- Ascending aorta
- Right ventricular outflow tract
- Pulmonary trunk
- Right ventricle
- Left ventricle.

❖ *Contours of posterior cardiomediastinum*:
- Above—left atrium and pulmonary veins
- Below—right atrium
- Diaphragmatic surface is formed by IVC, right atrium, right ventricle.

Size of the heart:
❖ Normal sized heart
❖ Cardiomegaly—cardiothoracic ratio will be more than 50
❖ Small heart—cardiothoracic ratio will be less than 50.

Chamber enlargement:
❖ In left ventricular hypertrophy, here is a prominent convexity and the heart will form an obtuse angle with the diaphragm. In right ventricular hypertrophy, the apex will be lifted up and the heart will form an acute angle with the diaphragm.
❖ Increased cardiac shadow will be seen:
- Congestive cardiac failure
- Cardiomyopathy
- Pericardial effusion.

❖ Right atrium enlargement—right border will be more convex.
❖ Left atrium enlargement—will show double contoured right border with both right and left atrial shadow.
❖ Right ventricular hypertrophy—the apex will be shifted outward and tilted up
❖ Left ventricular hypertrophy—the apex will be shifted downward and outward.

Shape and size of aorta:
❖ Dilatation
❖ Poststenotic dilatation
❖ Identification of aorta—descending aorta along the left margin of the spine will indicate a left aortic arch. Descending aorta along the right margin of the spine will indicate a right aortic arch.

Pulmonary artery:
❖ Pulmonary bay on the left border of heart will be obliterated and concave in pulmonary stenosis. For example: in tetralogy of Fallot.
❖ In pulmonary artery, dilatation the pulmonary bay on the left side will be full and convex.

Lung shadow:
❖ *Lungs*: View the lung on both sides starting from the apex. Both lungs will appear dark due to air in the lungs. Scan both the lungs above downward starting from the apices. Compare both sides at the same level. See if both right and left sides are equal in volume and aeration. When there is more air on one side that side will be more black and more volume.
❖ *Pulmonary parenchyma*: Look for pneumonia.
❖ Bronchopulmonary sequestration is common in right lower lung field. In this condition, a segment of the lung will be supplied by an artery arising from the descending aorta.
❖ *Ventilation of lungs*: Note the volume and aeration of both lungs. The right and left lungs will be equal in aeration and volume. Look at the volume and the degree of the aeration of the hemithorax.
- On full inspiration, anterior end of the 6th rib should cut the diaphragm.
- Posterior end of the 10th rib.
- If the expansion is more than the lung is considered as hyperinflated.

❖ *Bilateral hyperventilation*: Generalized increased translucency of the thorax with low-flattened diaphragms.

JAYPEE BROTHERS

for detailed information on pediatrics books, visit our website www.jaypeebrothers.com, for detailed information on pediatrics books, visit our

Practical Pediatrics

Salient Features

- Designed for medical students which will help them to understand various facts in nutrition such as positive and negative aspects of nutrition, feeding and various other nutritional factors
- Basics of X-rays and radiological features of various clinical conditions are discussed in detail
- Indications, contraindications and adverse effects of various medicines and vaccines are discussed in detail
- Mnemonics for easy remembrance and recollection.

Aruchamy Lakshmanaswamy MBBS MD (Pediatrics) DCH is working as Associate Professor, Department of Pediatrics, Coimbatore Medical College, Coimbatore, Tamil Nadu, India. He completed his MBBS at Stanley Medical College, Chennai and Diploma in Child Health from the same college. He completed his MD Pediatrics from Madras Medical College, Chennai. He has been working in the Department of Pediatrics and involved in teaching students for the past 29 years. He is an examiner for MBBS and postgraduate students. His exemplary services in the field of pediatrics had won him an award for "Excellent Services in the Field of Medicine" at the Government Mohan Kumaramangalam Medical College, Salem 2008 and "Best Doctor Award" 2012. He has written many books for the medical students which have overwhelming response from the medical students and pediatricians. The book *Clinical Pediatrics—History Taking and Case Discussion* is very popular among medical students and pediatricians.

Available at all medical bookstores
or buy online at www.jaypeebrothers.com



JAYPEE BROTHERS
Medical Publishers (P) Ltd.
www.jaypeebrothers.com
Join us on facebook.com/JaypeeMedicalPublishers

Shelving Recommendation
PEDIATRICS

