website www.jaypeebrothers.com, for detailed information on radiology books, visit our website www.jaypeebrothers.com

Celebrating 50

Passion, Quality and Innovation in Healthcare Publishing

Clinico Radiological Series

IMAGING OF CHEST TUMORS

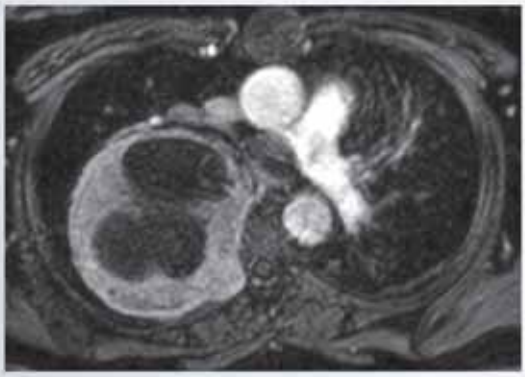

Editors
Ashu Seith Bhalla
Manisha Jana

Clinical Contents Edited by
Randeep Guleria
Anant Mohan

Co-Editor
Priyanka Naranje

JAYPEE

Contents

SECTION 1: IMAGING MODALITIES

1. **Imaging Modalities in Chest Tumors: Role and Techniques** 3
   Devasenathipathy Kandasamy, Gh Mohammad Wani
2. **Role of PET-CT in Chest Tumors** 12
   Rakesh Kumar, Ravikant Gupta
3. **Artificial Intelligence and Radiomics: Basics and Applications** 20
   Abhishek Mahajan, Pooja Pande

SECTION 2: LUNG TUMORS

PART A

4. **Lung Cancer: Risk Factors, Presentation and Evaluation** 31
   Pawan Tiwari, Randeep Guleria, Vijay Hadda
5. **Pathology, Immunohistochemistry and Driver Mutations of Lung Carcinoma** 37
   Deepali Jain, Sudheer K Arava
6. **Imaging of Carcinoma Lung** 45
   Ashu Seith Bhalla, Richa Yadav, Manisha Jana
7. **Carcinoma Lung: Staging** 59
   Smita Manchanda, Imtiyaz Ahmad Khan
8. **Lung Cancer Screening** 83
   Manisha Jana, Ashu Seith Bhalla, Sudhakar Pipavath

PART B

9. **Evaluation of Pulmonary Nodules** 94
   Ashu Seith Bhalla, Tahleel Altaf Shera, Manisha Jana
10. **Tumors of Airway and Other Lung Tumors** 119
    Priyanka Naranje, Richa Yadav
11. **Neuroendocrine Tumors of Thorax** 139
    Manisha Jana, Anuradha Dawani, Smita Manchanda

JAYPEE BROTHERS

SECTION 3: PLEURAL AND CHEST WALL TUMORS

12. Pleural Tumors: Imaging **159**
Surabhi Vyas, Madhuri Kumari

13. Chest Wall Tumors: Imaging **174**
Surabhi Vyas, Madhuri Kumari

SECTION 4: MEDIASTINAL TUMORS

14. Imaging of Thymic Epithelial Tumors **193**
Smita Manchanda, Raju Sharma, Gh Mohammad Wani

15. Imaging of Thoracic Germ Cell Tumors **210**
Manisha Jana, Imtiyaz Ahmad Khan

16. Neurogenic Tumors of Thorax **224**
Priyanka Naranje, Tahleel Altaf Shera, Ashu Seith Bhalla

17. Imaging in Thoracic Lymphoma **241**
Aparna Irodi

SECTION 5: SPECIAL SITUATIONS

18. Imaging of Thoracic Metastases **265**
Abanti Das

19. Thoracic Involvement in Hematologic Malignancies **276**
Priyanka Naranje, Mukesh Yadav

20. Pediatric Chest Tumors: Imaging **289**
Ashu Seith Bhalla, Priyanka Naranje, Anuradha Dawani

21. Thoracic Malignancies in Special Situations **309**
Smita Manchanda, Ashu Seith Bhalla

SECTION 6: MANAGEMENT OF LUNG CARCINOMA

PART A

22. Personalized Medicine: Chemotherapy, Targeted Therapy and Immunotherapy in Lung Cancer **327**
Prabhat S Malik

23. Radiation Therapy in Lung Cancer **334**
Dodul Mondal

24. Carcinoma Lung: Surgical Perspective **342**
Rajinder Parshad, Shashikiran NJ, Manjunath Bale

JAYPEE BROTHERS

PART B

25. Interventional Pulmonology in Chest Tumors **349**
Saurabh Mittal, Karan Madan, Anant Mohan

26. Interventional Radiology in Chest Tumors **356**
Ankur Goyal, Ashu Seith Bhalla, Amit Kumar Janu

27. Response Assessment in Chest Tumors **370**
Abanti Das

28. Imaging of Pulmonary Complications of Oncologic Therapies **384**
Abhishek Mahajan, Pooja Pande

SECTION 7: APPROACH

29. Approach to Thoracic Masses **395**
Smita Manchanda, Ashu Seith Bhalla

30. Approach to Mediastinal Masses **411**
Ashu Seith Bhalla, Manisha Jana

31. Approach to Pulmonary Neoplasms **428**
Priyanka Naranje, Ashu Seith Bhalla

SECTION 8: REPORTING/EXAMINATION SECTION

32. Structured Reporting Templates for Thoracic Tumors **443**
Abanti Das, Priyanka Naranje

33. Subjective Assessment and Multiple Choice Questions **452**
Anuradha Singh

34. Spotters **468**
Manisha Jana

Index *475*

JAYPEE BROTHERS

12
CHAPTER

Pleural Tumors: Imaging

Surabhi Vyas, Madhuri Kumari

- Anatomy
- Classification of Pleural Tumors
- Mesothelial Tumors
  - Pleural Mesothelioma
- Mesenchymal Tumors
  - Solitary Fibrous Tumor
  - Synovial Sarcoma
  - Calcifying Tumor of the Pleura
- Lymphoproliferative Disorders
  - Primary Effusion Lymphoma
  - Diffuse Large B-cell Lymphoma Associated with Chronic Inflammation
- Metastases
- MRI in Pleural Mass Evaluation

ANATOMY

- The pleura is a thin (2–5 mm) serous membrane composed of a single layer of mesothelial cells on a supporting matrix of collagen and elastin fibers with their vasculature, lymphatics, and nerves.
- There are two layers of the pleura, visceral and parietal, the former envelopes the lungs on all sides except where the hilar structures are connected; the latter, on the other hand, covers the insides of the thoracic wall and the superior surface of the diaphragm (Figs. 1A and B). The parietal pleura can thus be divided into costal, mediastinal, and diaphragmatic parts.
- Small amount (2–5 mL) of pleural fluid is present normally which allows the dynamic motion of the two layers of pleura with respiration.

CLASSIFICATION OF PLEURAL TUMORS

The tumors of pleura can be primary or secondary (metastatic), the secondary being more common than primary lesions. The 2015 WHO classification of primary pleural tumors broadly categorizes them in three groups based on the cell of origin with the major entities as follows:[1]

Mesothelial tumors:

- *Diffuse malignant mesothelioma (MM)*: Epithelioid, sarcomatoid (desmoplastic), or biphasic variety
- Localized MM with similar subcategories as diffuse variety.

JAYPEE BROTHERS

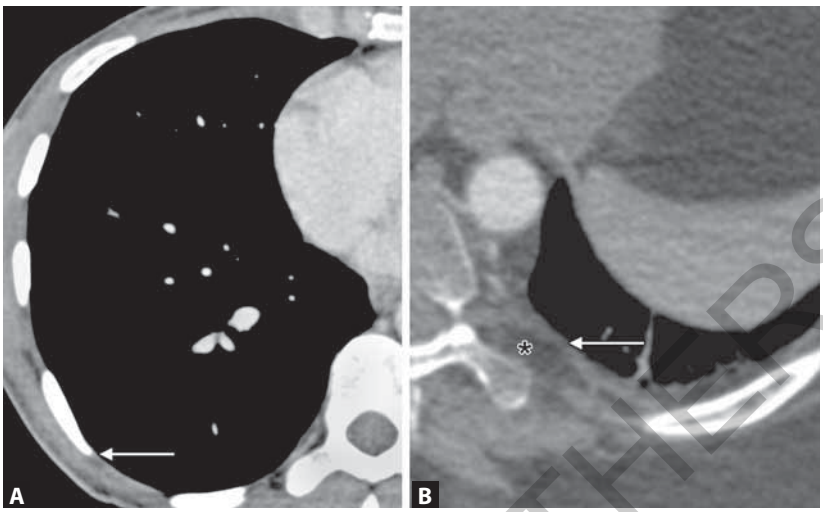

Figs. 1A and B: Normal pleura CT appearance. Normal pleura (arrows in A and B) has imperceptible thickness, with no calcification or nodularity. (*) marks the extrapleural space.

Mesenchymal tumors:

- Solitary fibrous tumor
- Synovial sarcoma
- Calcifying fibrous tumor
- Epithelioid hemangioendothelioma
- Desmoid-type fibromatosis
- Desmoplastic round cell tumor.

Lymphoproliferative disorders:

- Primary effusion lymphoma
- Diffuse large B-cell lymphoma associated with chronic inflammation.

MESOTHELIAL TUMORS

Pleural Mesothelioma

Introduction and Risk Factors

- Pleural mesothelioma (PM) is the most common primary pleural malignancy and the second most common malignancy involving pleura after metastasis.
- It can occur in the diffuse and localized forms, the former being more common.
- *Risk factors* include asbestos exposure, radiation therapy for other malignancies, and simian virus-40 infection.
- Asbestos exposure is seen in up to 80% of patients with a latent period between exposure and development of mesothelioma ranging from 20 years to 50 years.

JAYPEE BROTHERS

- There are two types of asbestos fibers chrysotile (curly and flexible serpentine fibers), and crocidolite (stiff and straight fiber), the latter being more carcinogenic.

Clinical Presentation

- Age group affected is 50–70 years and male:female ratio is 4:1.
- Cough, fatigue, nonpleuritic chest pain, and weight loss are the common symptoms.
- Rarely, spontaneous pneumothorax, superior vena cava (SVC) obstruction, and laryngeal nerve palsy may also occur.

Laboratory Investigations

- Raised serum soluble mesothelin-related protein (SMRP)
- Elevated carcinoembryonic antigen (CEA).

Imaging Features

Chest radiograph:

- Chest X-ray (CXR) is used for surveillance of those patients with asbestos exposure and also is the first investigation in symptomatic patients.
- Unilateral pleural effusion followed by diffuse pleural thickening is common feature; pleural mass may also be seen (Fig. 2A). The pleural thickening and masses are seen along the fissures and may simulate an intraparenchymal mass, in which case a lateral chest radiograph helps.[2]
- Volume loss is often present due to encasement of lung which manifests as tracheomediastinal shift, elevated hilum, elevated diaphragm, and reduced intercostal spaces (Fig. 2B).
- When mediastinal or diaphragmatic pleura is involved, there may be shaggy mediastinal/heart or diaphragmatic contours.
- Punctate calcifications may be seen due to osseous and cartilaginous differentiation.
- Mediastinal or hilar lymphadenopathy may be seen.

Computed tomography:

- Computed tomography (CT) is the imaging modality of choice for the extent of primary disease and locoregional extent of disease.
- Nodular or diffuse pleural thickening is the most common manifestation, seen in up to 90% of cases (Figs. 3A and B).
- A pleural thickening of more than 1 cm is highly suggestive of malignant disease. A mesothelioma with pleural thickening of less than 1 cm may be indistinguishable from benign causes (Figs. 4A to D).
- Cartilaginous calcification and ossification are better appreciated on CT. Other manifestations of asbestos exposure, i.e. calcified pleural plaques, appear linear or angular in contrast to the punctate foci of calcification

JAYPEE BROTHERS

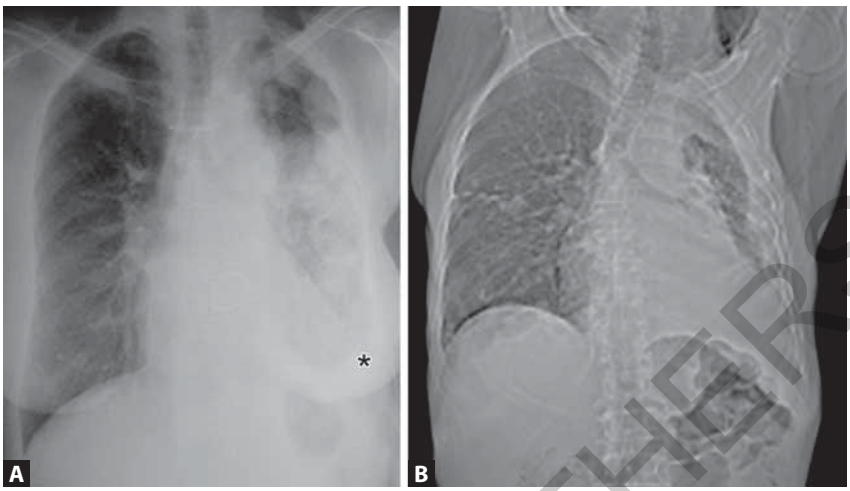

Figs. 2A and B: Pleural mesothelioma: CXR (A) shows nodular left pleural thickening, blunting of CP angle (*) and volume loss. Note made of sternotomy sutures and prosthetic aortic valve. Different patient (B) showing left pleural thickening similar to (A) with reticular opacities in both lungs due to asbestos related lung disease.

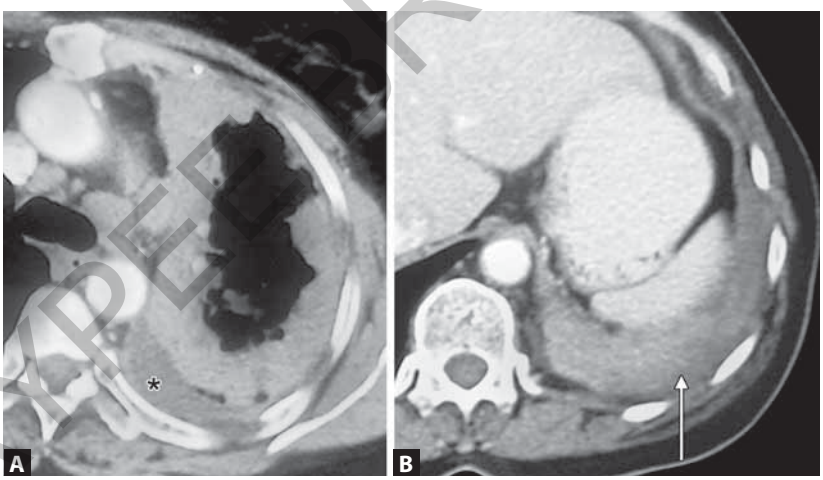

Figs. 3A and B: Mesothelioma—CT appearance. Axial images showing thick nodular pleural thickening (A) encasing the lung with heterogeneous enhancement, and pleural effusion (*). The thickening is seen to also involve the diaphragmatic pleura (arrow) (B).

due to osteocartilaginous differentiation in PM (Figs. 5A and B). Pleural effusion, mediastinal pleural involvement, and interlobar pleural involvement are seen more frequently in mesothelioma.[3]

- *Mediastinal invasion:* It is present when there is loss of the interface with the mediastinal fat, or greater than 50% circumferential invasion of the trachea or esophagus (Fig. 6A).

JAYPEE BROTHERS

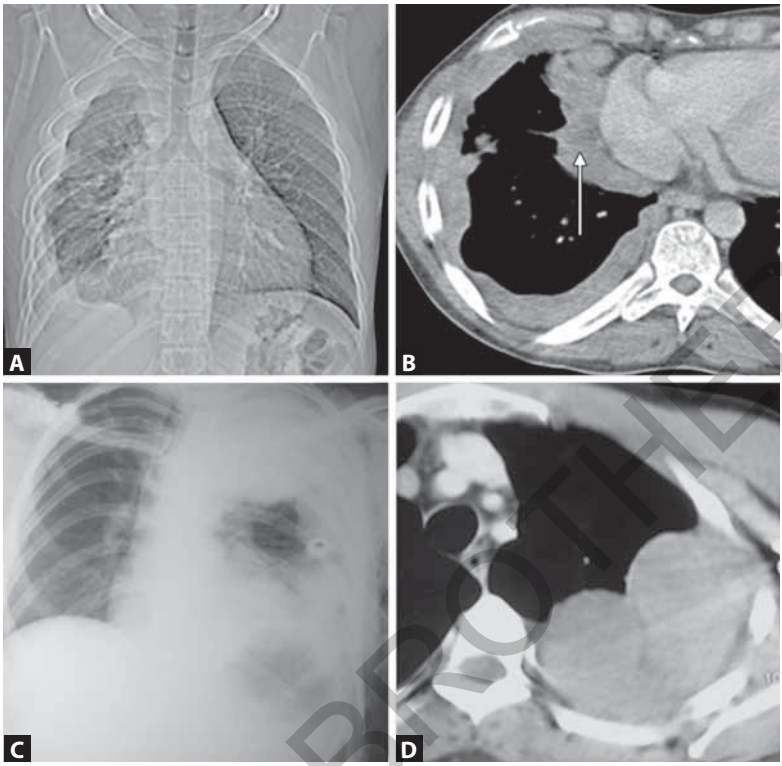

Figs. 4A to D: Tubercular (TB) vs mesothelioma pleural involvement. Known case of TB (A and B) with thin regular right pleural thickening and minimal volume loss. There are necrotic areas along the mediastinal pleura (arrow). In a case of mesothelioma (C and D), exuberant nodular pleural thickening with homogeneous enhancement.

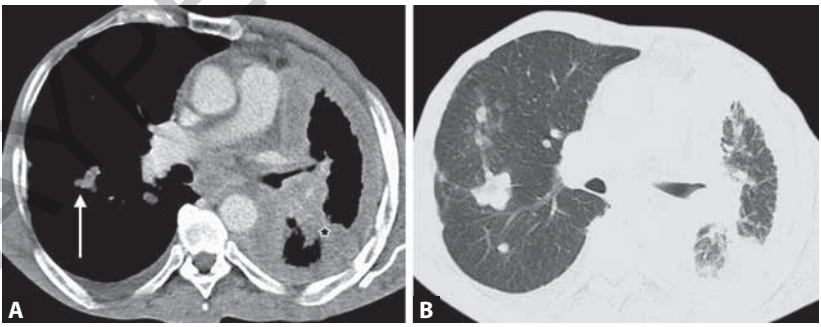

Figs. 5A and B: Mesothelioma with asbestosis. (A) Rind-like left pleural thickening extending along the oblique fissure (arrow in A) with left pleural effusion. Noncalcified right pleural plaque along the fissure (arrow in A) with pleural effusion; (B) Shows asbestos related bilateral subpleural fibrotic changes with pleural tags.

- *Pericardial invasion:* It results in pericardial thickening, effusion, nodularity, or soft tissue. As transmural invasion of the pericardium results in the staging of tumor as T4, it is imperative to distinguish it

JAYPEE BROTHERS

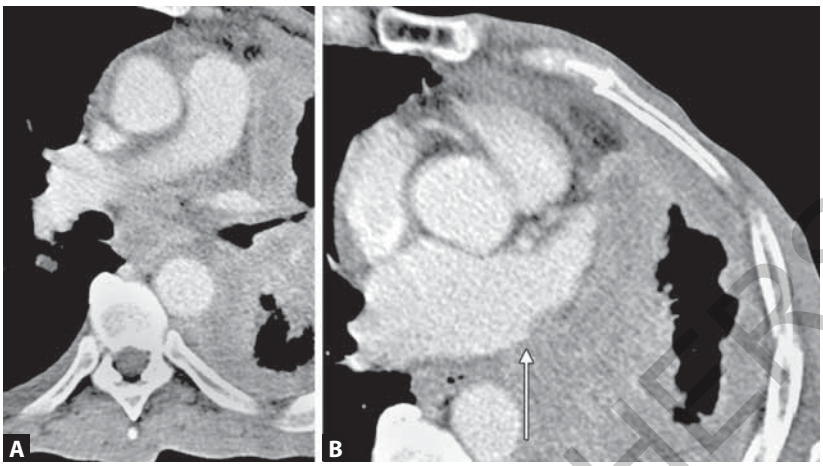

Figs. 6A and B: Mesothelioma with mediastinal/myocardial involvement. (A) Encasement of the esophagus with nodes and soft tissue around the aorta suggesting mediastinal involvement. Different patient (B) shows myocardial invasion of the left atrium (arrow).

from nontransmural pericardial involvement. Transmural pericardial invasion is present when there is involvement of the inner surface of pericardium by the tumor or there is myocardial involvement (Fig. 6B).

- *Chest wall involvement:* It is said to be present when there is loss of normal extrapleural fat lining or when there is invasion of the intercostal muscles or bony destruction (Figs. 7A and B).
- *Diaphragmatic extension:* It is less reliably diagnosed on CT; however, loss of fat plane with diaphragm and subdiaphragmatic structures; and indistinct margins may indicate the same.
- CT parameters of unresectability of the disease are:
  - Multifocal or diffuse invasion of the chest wall
  - Invasion of the mediastinal structures or spine
  - Transmural invasion of the pericardium
  - Involvement of the contralateral pleura
  - Transdiaphragmatic extension
  - Metastatic disease
- *Mediastinal, hilar, and paraesophageal lymph nodal involvement:* It is seen and is said to be present if lymph node is >10 mm in short axis (SA) diameter (Figs. 8A and B). Visualization of the internal mammary, retrocrural, and extrapleural nodes is considered abnormal irrespective of the size.
- *Pulmonary metastasis:* It can be in the form of parenchymal nodules, masses or lymphangitis carcinomatosis.

JAYPEE BROTHERS

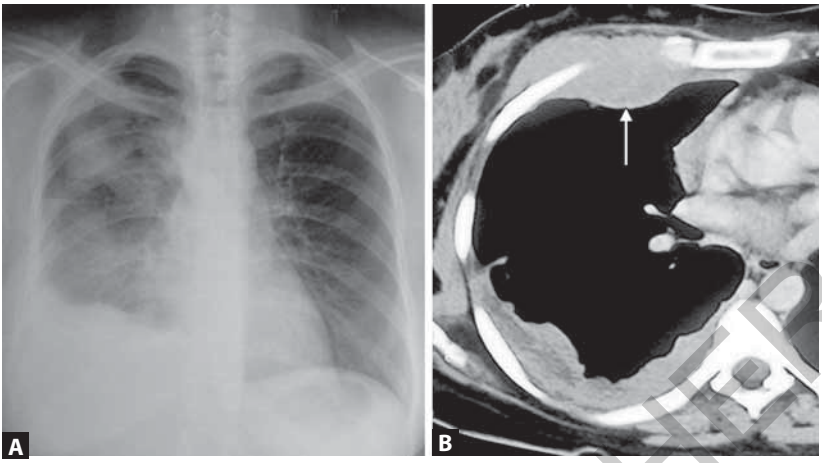

Figs. 7A and B: Mesothelioma: Chest wall invasion. CXR (A) shows opacities in right upper and mid zone and in right paracardiac location and pleural effusion. CT (B) shows enhancing right costal pleural based mass (arrow) with invasion of anterior chest wall muscles.

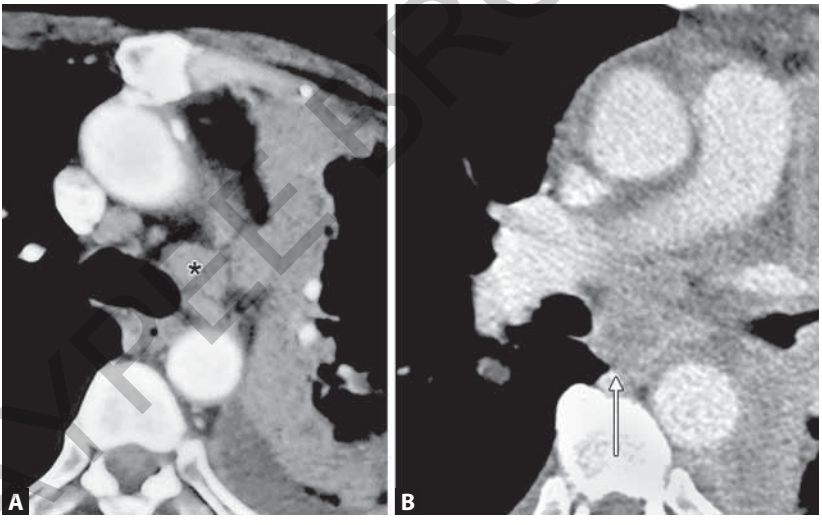

Figs. 8A and B: Mesothelioma—Nodal spread. CT images of different patients showing homogeneous pretracheal and prevascular enlarged lymph nodes (* in A); (B) Showing necrotic subcarinal lymph node (arrow), with heterogeneously enhancing soft tissue around the descending thoracic aorta.

Magnetic resonance imaging:

- Magnetic resonance imaging (MRI) has limited indications and is not routinely used in evaluation of mesothelioma.

JAYPEE BROTHERS

- MRI has a definitive role in detecting chest wall, mediastinal and diaphragmatic invasion where it shows better sensitivity as compared to CT.
- The pleural thickening of mesothelioma appears iso- to mildly hyperintense to muscles on T1 and moderately hyperintense on T2W images with diffuse enhancement on contrast-enhanced MRI. The associated pleural effusion appears bright on T2W images and hypointense on T1W images.
- Direct invasion of surrounding structures may be seen best on postcontrast images.
- Information obtained from MRI may serve as guide for sampling procedures as enhancing areas as well as those that show restricted diffusion as most suited for biopsy and cytology.

Ultrasound: The role of ultrasonography (USG) is limited to guiding biopsy and pleural fluid aspiration.

Fluorodeoxyglucose positron emission tomography-computed tomography (FDG PET–CT):

- FDG PET provides functional information and thus plays a complementary role in the assessment of disease.
- Cut-off values of standardized uptake value (SUV) of 2–2.2 have been described to differentiate between benign and malignant pleural disease with sensitivities and specificities ranging from 90% to 100% and 80% to 100%, respectively.
- PET/CT is increasingly used in staging, follow-up, and monitoring of PM (Figs. 9A and B).

Staging

The TNM staging remains the most widely used staging system of MM. Currently the eighth edition is in use with salient features as follows.

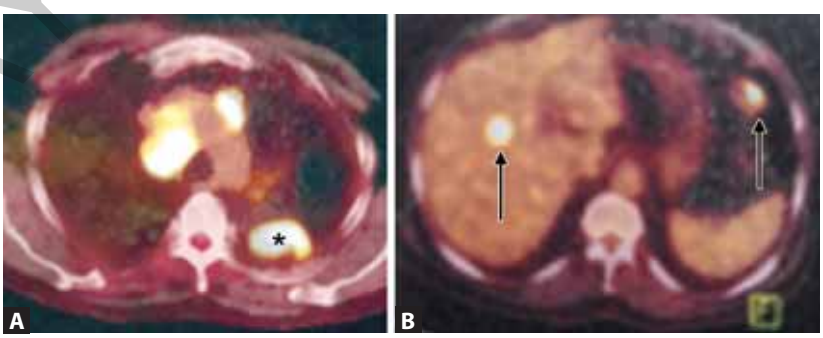

Figs. 9A and B: Mesothelioma: Utility of FDG PET/CT. Left pleural primary mass (* in A) with multiple mediastinal lymph nodes showing FDG uptake seen. A metastatic lesion showing similar uptake in the liver and omentum (arrows in B).

JAYPEE BROTHERS

for detailed information on radiology books, visit our website www.jaypeebrothers.com, for detailed information on radiolog

Clinico Radiological Series
IMAGING OF CHEST TUMORS

Salient Features

- Focuses on core imaging and management issues in chest tumors
- Chest tumors have been discussed based on anatomic localization as well as on the basis of pathology
- Complex topic presented in a simple and lucid manner
- Extensive coverage of newer classification, staging systems and management. Management-related complications and response assessment also covered
- Unique arrangement of sections having a combined clinical and radiological perspective of the disease
- Chapters contributed by reputed experts from Radiology, Pathology, Pulmonary Medicine, Medical Oncology, Surgery and Radiation Oncology
- High quality images and illustrations with detailed description of the disease entities
- Templates and Examination section: a unique feature of this book which will act as a ready guide to the radiologists in practice on how to approach and report in a specific situation
- Comprehensive coverage of the key radiological abnormalities not only to reach a diagnosis, but to plan and guide treatment
- Attempts to provide tables of close radiological differentials
- Aims to become a 'ready reference' for all the radiologists and surgeons involved in this field.

Ashu Seith Bhalla MD MAMS FICR is Professor of Radiodiagnosis at All India Institute of Medical Sciences (AIIMS), New Delhi, India. She is a reputed radiologist with special interest in Thoracic, and Head & Neck Radiology with over 20 years experience in the field. She has over 200 publications, has authored numerous chapters in books and is on the editorial boards of several journals. She has a passion for teaching and is extensively involved in teaching programs all over the country.

Manisha Jana MD DNB FRCR is Additional Professor of Radiodiagnosis at All India Institute of Medical Sciences (AIIMS), New Delhi, India. She has special interest in Pediatric and General Radiology and nurtures a love for teaching. She has published over 100 articles in reputed journals; written many book chapters and is actively involved in teaching and research activities in the institute.

Available at all medical bookstores
or buy online at www.jaypeebrothers.com



JAYPEE BROTHERS
Medical Publishers (P) Ltd.
www.jaypeebrothers.com

Join us on facebook.com/JaypeeMedicalPublishers

Shelving Recommendation
RADIOLOGY

ISBN 978-93-89587-17-3