our website www.jaypeebrothers.com, for detailed information on obstetrics & gynecology books, visit our website www.jaypeebrothers.com

THIRD EDITION

Celebrating 50 Years
Passion, Quality and Innovation in Healthcare Publishing

OBSTETRIC EMERGENCIES

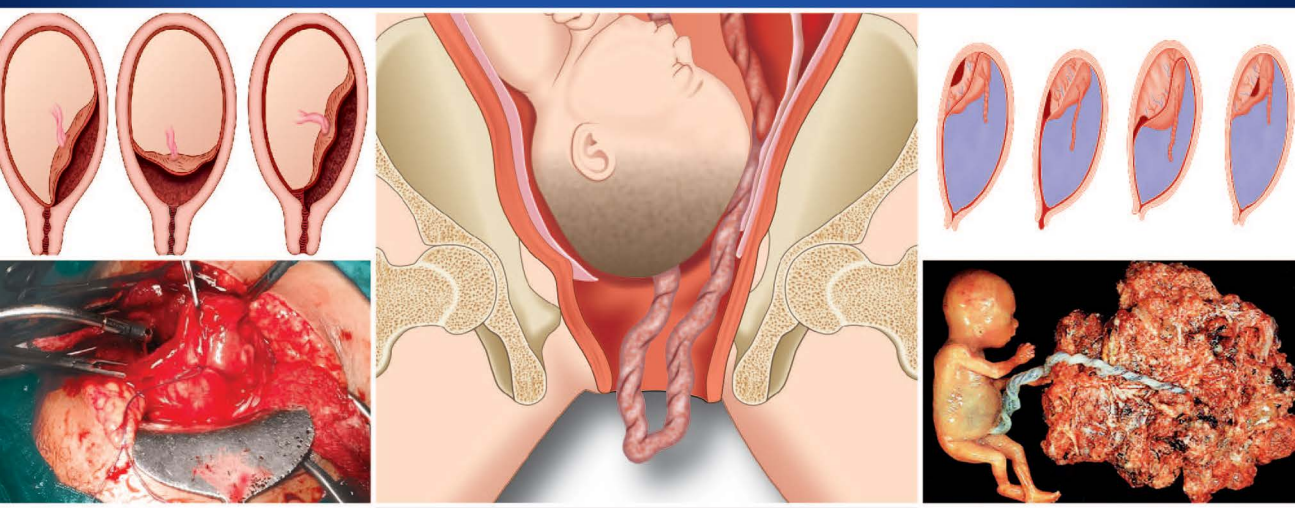

Editor
Kamini A Rao

Co-Editor
Vyshnavi A Rao

JAYPEE

CONTENTS

1. **Antenatal Care** 1
   Aparna Jha
2. **Miscarriages** 4
   Vyshnavi A Rao
3. **Hyperemesis Gravidarum** 14
   Vyshnavi A Rao
4. **Ectopic Pregnancies: Diagnosis and Management** 19
   Deepa Nambiar
5. **Retroverted Gravid Uterus** 51
   CS Sushma Madhuprakash
6. **Hydatidiform Mole** 55
   Nisha Singh
7. **Trauma in Pregnancy** 71
   Haritha Mannem
8. **Shoulder Dystocia** 86
   BS Susheela Rani
9. **Hypertensive Emergencies in Pregnancy and Labor** 95
   Sunitha B
10. **Cardiac Failure in Pregnancy** 108
    Shalini MA
11. **Acute Fatty Liver and Jaundice in Pregnancy** 114
    Chandana C
12. **Infections in Pregnancy** 119
    Deepa Patil, Shravya Tallapureddy
13. **Deep Vein Thrombosis in Pregnancy** 129
    Rinke S Tiwari
14. **Preterm Labor** 141
    Shravya Tallapureddy
15. **Antepartum Hemorrhage** 155
    Chandana C, Srividhya GK
16. **Retained Placenta** 168
    Sowparnika SN

17. Intrauterine Growth Restriction 173
Rekha Viswanath

18. Management of Amniotic Fluid Emergencies 181
Arya Rajendran

19. Intrauterine Fetal Death 189
Mahesh Koregol, Soumya Mahesh Koregol

20. Amniotic Fluid Embolism 193
Thejaswini J

21. Breech Presentation and its Complications 198
Ravishankar P

22. Abnormal Fetal Heart Trace on Cardiotocography 208
Revathi S Rajan

23. Anesthetic Complications in Pregnancy and Labor 216
Swetha, Ravi Kumar IR

24. Cesarean Delivery 229
Aishwarya Yerram

25. Perimortem Cesarean Delivery 239
Aishwarya Yerram

26. Postpartum Hemorrhage 243
Meghana V Nyapathi

27. Perineal Tears 253
Nilofer

28. Vaginal Birth after Cesarean Section 258
Sonal Agarwal

29. Drug Therapy in Pregnancy 269
Vignata N

30. Peripartum Cardiomyopathy 278
Shalini MA

31. Uterine Inversion 288
Priyadharsini S

32. Peripartum Collapse 293
Smitha Avula

33. Acute Abdomen in Pregnancy 297
Smitha Avula

34. Umbilical Cord Prolapse 303
Taswin Kaur Reddy

35. Epilepsy in Pregnancy 311
Surbhi Gupta

36. Diabetic Ketoacidosis in Pregnancy 322
Sunil Gupta

37. Laparoscopy in Pregnancy 327
Arathi Sreedhara

38. Pregnancy as a Result of Rape 331
Rahul Wani

39. Obstetric Emergencies: Medicolegal Issues and Implications 339
SV Joga Rao

40. Puerperal Sepsis 358
Sudeepti Mummadi

41. Obstructed Labor 365
Rajitha Yarlagadda

42. Retained Mop in Abdomen/Gossypiboma in Abdomen 372
Shashikala KT

43. Malpresentations 379
Sneha

44. Acute Asthma in Pregnancy 385
A Shilpa Reddy

45. Scar Dehiscence 393
Sumi Maria

46. Disseminated Intravascular Coagulation in Obstetrics 398
Vinay Kumar, Harleen Kour, Anju Dogra

47. In Utero Transfer 407
Vinay Kumar, Anju Dogra, Harleen Kour

48. Delivery in Emergency Department 417
Sowmya Davuluri

49. Induction of Labor 423
Karthigayeni Rathinam

50. Abnormal Progress of Labor 436
Komal Unadkat

51. Transfusion Reactions 441
Rekha Viswanath

52. Anaphylaxis 444
Neha Tyagi

53. Sickle Cell Crisis 454
Priyanka Yadav

54. Severe Anemia in Pregnancy and Labor 459
Jyothirmayi Kunam

55. Role of Imaging Modalities in Obstetric Emergencies 472
Roopa PS, Akhila Vasudeva

56. Uterine Rupture 486
Sudeepti Mummadi

Index 491

CHAPTER

4 Ectopic Pregnancies: Diagnosis and Management

Deepa Nambiar

DEFINITION

An ectopic pregnancy is one in which the blastocyst implants itself anywhere else, other than the endometrium of the uterine cavity. It is derived from the Greek word *ektopos* which implies being "out of place".[1]

The ectopic pregnancy has an insidious and potentially cataclysmic nature which has made it one of the most dangerous conditions to occur in the reproductive age group of women, this has been proven historically. Heterotopic pregnancy is a rare phenomenon and it is a unique dual presentation of pregnancy, one is a normal intrauterine gestation (Fig. 1) and other is an ectopic pregnancy (incidence: 1:17,000–30,000).

EPIDEMIOLOGY[1,2]

- *Incidence*: 2% in 1st trimester pregnancies
- *Fatality rate*: 10% in pregnancy-related mortality.

CLASSIFICATION[3]

The most common site of implantation in ectopic pregnancies accounting for 95% is in the fallopian tube, which are mostly ampullary implantations.[1] Bilateral ectopic pregnancies are extremely rare, and their estimated prevalence is 1 of every 200,000 pregnancies.[3]

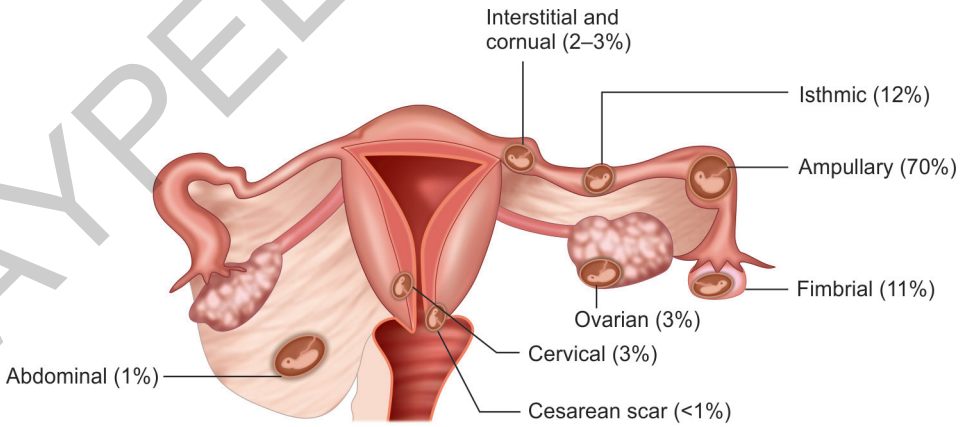

Fig. 1: Various frequencies and sites of ectopic pregnancy.

JAYPEE BROTHERS

ETIOLOGY[4,5]

Factors that are responsible for the fertilized ovum to remain in the fallopian tube	*Factors that facilitate nidation of the fertilized ovum into the tubal mucosa*
• *Pelvic inflammatory disease*: Causes impairment of the muscular peristalsis, loss of cilia lining, and narrowing of the tubal lumen, peritubal adhesions resulting in kinking and angulation of the tube, and formation of pockets of adhesion between mucosal folds. • *Iatrogenic*: Contraception devices (Cu-T), tubal sterilization, tubal recannulation, and pelvic surgery • Previous ectopic pregnancy, previous abortion , and previous cesarean section • Assisted reproductive technology (ART) • Transperitoneal migration of the ovum. • Developmental defects of the tube.	• Increased decidual reaction • Tubal endometriosis • Premature degeneration of zona pellucida causing early resumption of trophoblastic activity.

RISK FACTORS FOR ECTOPIC PREGNANCY[1]

Factor	*Relative risk (%)*
Prior ectopic pregnancy	3–13
Prior tubal surgery	4
Tubal sterilization	9
Tubal pathology	3.8–21
Prior medical or surgical abortion	0.6–3
Assisted reproductive technology	2–8
Prior cesarean delivery	1–2.1
Infertility >1 year	2.5–3
Lifelong sexual partners >5	1.6–3.5
Prior IUD use	1–4.2
Smoking >20 cigarettes per day	1.7–4
Pelvic inflammatory disease (PID) confirmed by laparoscopy or positive test for *Chlamydia trachomatis*	2–4

PATHOPHYSIOLOGY[3]

In an ectopic pregnancy, changes occur in the tube as well as in the uterus. The corpus luteum produces progesterone and estrogen which changes the secretory endometrium into decidua (the endometrium may produce a mixed proliferative and secretory pattern called as Arias-Stellar reaction. Uterus enlarges to 8 weeks size).

- Tubal pregnancy does not usually prolong beyond 8–10 weeks due to:
  - The inadequacy of tubal lumen to accommodate the pregnancy
  - Lack of decidual reaction in the fallopian tube
  - Bleeding in the site of implantation as the trophoblast invades into the tubal musculature.
  - The thin wall of the fallopian tube.
- Acute inflammation has been indicated in the tubal damage that predisposes to ectopic pregnancies. Salpingitis isthmica nodosa and chronic salpingitis also contribute to such tubal damage.
- Embryo progress is arrested due to inflammation within the fallopian tube and this provides a premature preimplantation signal. Primarily, oviduct interstitial cells of Cajal are specialized pacemaker cells responsible for egg transport and oviduct motility.

JAYPEE BROTHERS

- Cannabinoid receptor (CB1) is yet another factor involved with oviductal transport of embryos; it is mediated by endocannabinoid signaling. Endocannabinoid levels are elevated in smokers, where there is a chronic exposure to nicotine which causes fallopian tube dysfunction.
- In artificial reproductive techniques, the mechanism for ectopic pregnancy in women has been a dilemma as the fallopian tube is bypassed. Only in women who underwent in vitro fertilization (IVF), E-cadherin, an adhesion molecule, was evidently localized to the tubal embryo implantation site. This implies a biological factor that accounts for the ectopic pregnancies in IVF.
- The absence of a submucosal layer beneath its epithelium in a fallopian tube plays an important role in the tubal pregnancy genesis after the disruption of the normal tubal transport, so the embryo effortlessly burrows through the epithelium and implantation occurs within tube's muscularis layer (Figs. 2A and B), which leads to hemorrhaging into the trophoblastic space/adjacent tissues.
- The extent of damage can be predicted by the site of ectopic pregnancy. Implantations that take place in the isthmic or ampullary portion of the fallopian tubes rupture earlier than the interstitial portion. Rupture is unpredictable and spontaneous, but it can also be caused by a coitus or bimanual pelvic examination.
- Ectopic pregnancy development that happens after implantation explains the typically divergent clinical manifestations between acute and chronic ectopic pregnancies.

JAYPEE BROTHERS

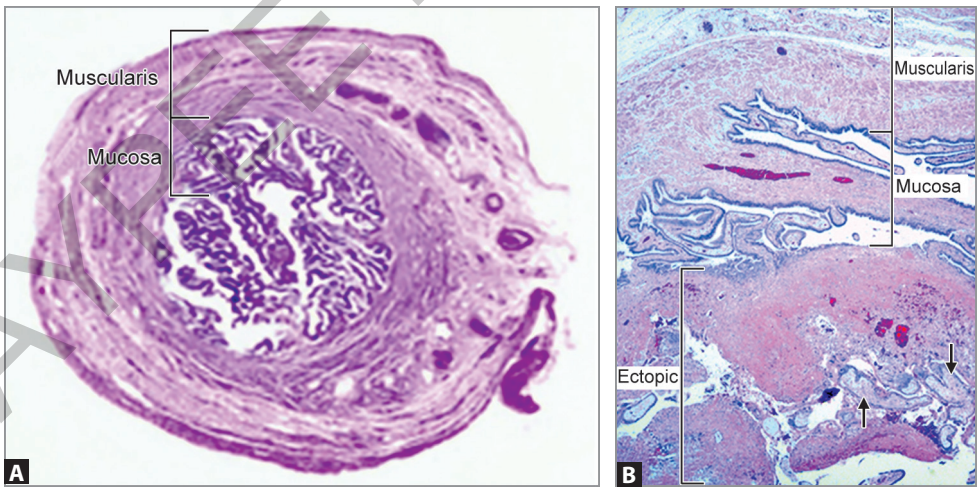

Figs. 2A and B: (A) Fallopian tube with normal ampullary lumen; (B) Ectopic tubal pregnancy—chorionic villi (arrows) within the lumen.
Source: Hoffman BL, O Schorge J, Bradshaw KD et al. Ectopic pregnancy. Williams gynecology, 3rd edition. New York: McGraw-Hill Education; 2016.
https://obgynkey.com/wp-content/uploads/2016/06/m_p9780071849081-ch007_f002.png

Acute ectopic pregnancies[2]	*Chronic ectopic pregnancy*
• High serum beta-human chorionic gonadotropin (β-hCG) level at presentation corresponds with the depth of trophoblastic invasion into the tubal wall. • Greater invasion promotes associated severe ischemic changes and eventually tubal wall rupture. • Rapid pregnancy growth leads to painful tubal distention or rupture and aids immediate diagnosis.	• An inflammatory response caused due to minor repeated ruptures or tubal abortion leads to formation of a pelvic mass. • Negative or lower, serum β-hCG levels are found as the abnormal trophoblasts die early. • Chronic ectopic commonly forms a complex pelvic mass and typically ruptures late.

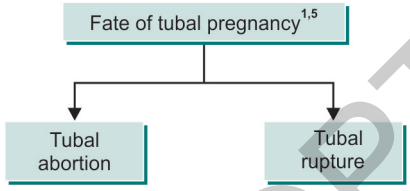

• Common in ampullary pregnancies • Chorio decidual hemorrhage causes placental separation and results in: – *Complete tubal abortion*: Through the fimbrial end into the peritoneal cavity – *Incomplete tubal abortion*: Hematosalpinx is formed in cases of blocked tubes – Complete tubal absorption – *Missed tubal abortion*: Products of conception are retained in the tubal lumen and repeated chorio decidual hemorrhages converts it into a carneous/tubal mole, that partly gets absorbed resulting in a small symptomless hydrosalpinx. In rare cases, calcification of the fetus occurs, which is called lithopedion.	• Common in isthmic pregnancies • Signs of hypovolemia are common • Rupture that occurs in the antimesenteric border of the fallopian tube results in profused intraperitoneal hemorrhage. • Rupture that occurs in the mesenteric boundary of the tube causes a broad ligament hematoma that progresses slowly and ultimately ruptures into the peritoneal cavity. • Rupture is impetuous and impulsive, but may occur following trauma caused by coitus/ bimanual examination.

CLINICAL MANIFESTATIONS

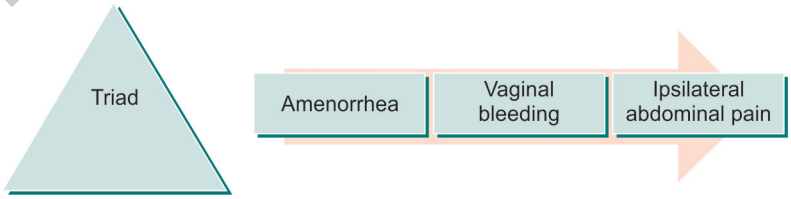

The classic symptom triad of ectopic pregnancy is amenorrhea followed by vaginal bleeding and ipsilateral abdominal pain. Unfortunately, only about 50% of patients

JAYPEE BROTHERS

present with all three symptoms. However, as women nowadays seek care earlier, the ability to diagnose ectopic pregnancy before rupture—even before the onset of symptoms is not unusual.

Early pregnancy discomforts such as breast tenderness, nausea, and urinary frequency may accompany more ominous findings.

Symptoms and signs of ectopic pregnancy are often subtle or even absent.

ACUTE ECTOPIC PREGNANCY: AN OBSTETRIC EMERGENCY[1]

Rupture of a tubal ectopic pregnancy, which results in a massive intraperitoneal hemorrhage leads to an acute presentation.

Pain	*Abnormal bleeding*	*Abdominal and pelvic tenderness*	*Uterine changes*	*Vital signs*
• 95% report with pelvic and abdominal pain. • Shoulder pain worsened by inspiration, which is caused by phrenic nerve irritation from sub-diaphragmatic blood • Acute retention of urine caused due to upward displacement of the uterus by the mass causing obstruction can cause severe suprapubic pain.	• Amenorrhea with some degree of vaginal bleeding/ spotting is seen in 60–80% patients	• With unruptured ectopic tenderness is uncommon. • Three-fourth women with ruptured ectopic pregnancies have exquisite tenderness on abdominal and pelvic examination, especially with cervical motion. • Patients have symptoms of painful defecation.	• In later stages, the uterus can be pushed to one side by the ectopic mass. • Uterus is enlarged to 8 weeks due to hormonal stimulation .	• It is generally normal before rupture. • Responses in moderate hemorrhage include no change in vital signs; a slight rise in systolic BP or a vasovagal response with hypotension and bradycardia, which manifests as a syncope/shock. • In eminent rupture: Blood pressure will fall and the pulse rate will only rise.

Signs[4,5]

General examination: Signs of shock.

Extreme pallor, restlessness, air hunger, thready pulse with marked tachycardia, hypotension, subnormal temperature, and cold extremities.

Shock index (heart rate/systolic BP) is greater than 0.85.

Breast signs of pregnancy usually are not present.

Per abdominal (PA) examination: Mild abdominal distension (distension is not always due to intraperitoneal blood, but due to localized ileus of the gut caused by blood).

Periumbilical bluish discoloration (Cullen's sign is a late sign) due to absorption of intraperitoneal blood into the lymphatics.

On palpation: Extreme tenderness in the lower abdomen and slight rigidity.

Local examination: Vagina is pale and tender.

Per speculum (P/S) examination: Cervix has a bluish discoloration (rarely seen in early pregnancy), bleeding may/may not be seen through os.

Per vaginal (P/V) examination: Cervix is soft and tender.

Due to the severe abdominal pain, a bimanual examination may not be accurate,

JAYPEE BROTHERS

but if possible uterus is bulky and soft. A tender bulge or fullness in the pouch of Douglas (POD) is suggestive of a pelvic hematocele.

Very gentle forniceal examination may reveal soft tender mass, but it is discouraged to prevent the possibility of rupture.

Differential Diagnosis in Cases of Acute Abdomen[2]

A woman who belongs to the reproductive age group and presenting with complaints of abdominal pain, should be investigated as a whole keeping the mind alert for other conditions also, such as:

Conditions within the reproductive system	*Conditions involving other organs*
• Incomplete abortion in retroverted uterus • Pyosalpinx • Ovarian torsion • Rupture of an ovarian cyst (endometrial/corpus luteal cyst) • Salpingitis • Septic abortion • Pelvic abscess • Uterine fibroid.	• Acute appendicitis • Urinary tract infections • Diverticulitis • Intestinal intussusception.

CHRONIC ECTOPIC PREGNANCY[4]

It is the most common variety, which occurs due to small recurrent intraperitoneal bleeding that results from a tubal abortion.

Symptoms: Amenorrhea + vaginal bleeding + pain.

Pain may manifest as the following:
Constant dull pain: Due to distension and tearing of the fallopian tube.

Cramping pain: Due to peristalsis and dilatation of the fimbrial end of the fallopian tube.

Sharp pain: Due to cervical movement on the uterine body.

Gross abdominal pain: Due to peritoneal irritation by the blood.

Signs: Findings may be normal.

A chronic leaking ectopic may rupture and produce acute symptoms.

Diagnosis and Management

Ectopic pregnancy is a potentially life-threatening condition. Patients with abnormal bleeding, pelvic pain, or both, who are found to have ectopic pregnancy or those who are strongly suspected of having ectopic pregnancy require establishment of a diagnostic and management plan and close follow-up to avoid the potentially catastrophic complication of tubal rupture with massive hemorrhage and shock that with delay increases the chances of morbidity and mortality.

Multimodality Diagnosis[1]

Clinical findings + serum analyte testing + transvaginal ultrasonography (TVS) + laparoscopic diagnosis.

- *Laboratory tests*:
  - Beta-Human Chorionic Gonadotropin:[1,6]

Accurate and rapid determination of pregnancy is essential, current blood serum analytical tests that use ELISA for β-hCG is sensitive to levels as low as 10–20 mIU/mL.

Kadar Principle: Doubling time.
In an intrauterine pregnancy, the β-hCG doubles with every 48 hours during the 1st

JAYPEE BROTHERS

42 days' period of gestation; but in an ectopic pregnancy, there is less than 66% increase in β-hCG levels within 48 hours.

This alone cannot be taken in diagnosing an ectopic pregnancy as it is not specific only to ectopic pregnancies since similar fall in β-hCG levels are seen in failing intrauterine pregnancies also.

- *Serum progesterone*: Value >25 ng/mL excludes an ectopic pregnancy with a 92.5% sensitivity. Values <5 ng/mL are suggestive of a failing intrauterine pregnancy/ectopic pregnancy.
- *Culdocentesis*: Presence of microclots in the blood aspirated from the POD justifies laparotomy.
- *Hemogram*: After hemorrhage, the depleted blood volume is restored by hemodilution over a period of 24 hours/longer; thus even after a substantive hemorrhage, the hematocrit value may be within normal, hence after an acute hemorrhage, a drastic decrease in the values of hemoglobin and hematocrit over several hours is a more valuable index of blood loss than compared to the initial level. Leukocytosis varying up to 30,000/μL may be documented.
- *Novel serum markers (ongoing trials)*: Vascular endothelial growth factor (VEGF), cancer antigen 125 (CA 125), insulin-like growth factor (IGF), pregnancy-associated plasma protein A (PAPP-A), creatine kinase, fetal fibronectin, and mass spectrometry-based proteomics.

• *Sonography*:[2,3]
  - *Transabdominal sonography*:
    - *Discriminatory zone*: 6,000 mIU/mL. Discriminatory zone1 is the value of serum β-hCG level above which failure to visualize an intrauterine pregnancy indicates with high reliability that the pregnancy either is ectopic or is not viable.
    - *Ectopic pregnancy is certain*: Where a sonographic absence of a uterine pregnancy, positive assay for β-hCG, free fluid in the POD, and an abnormal pelvic mass (Fig. 3). Transabdominal scan helps to image other neighboring organs and the extent of the hemoperitoneum. Blood (seen as fluid with altered hyperechogenicity) is seen in the Morison's pouch.
  - *Transvaginal sonography*:
    - *Discriminatory zone*: 2,000 mIU/mL
    - *Ultimate diagnostic tool*:
      - *Endometrial cavity*: Trilaminar pattern is unique for diagnosis.
      - *Anechoic fluid collections*: Pseudogestational sac is formed due to decidual reaction and sloughing, and lies in the mid-line and is contiguous with the endometrial stripe, unlike a normal gestational sac that is eccentrically located. Decidual cyst is formed due to decidual breakdown and predates formation of a decidual cast. It lies in the endometrial cavity at endo-myometrial border (Fig. 4).
      - *Adnexa*: An ectopic pregnancy is established when the fallopian tubes and the ovaries are visualized along with the products of conception as an extrauterine yolk sac or embryo, but such findings are seen in only 15–30% of such cases.
      - *Bagel sign*: Characteristic ring pattern.
      - *Tubal ring*: Halo—surrounded by a thin hypoechoic area which is accounted for due to subserosal edema. *Differentiation of an ectopic pregnancy from a*

JAYPEE BROTHERS

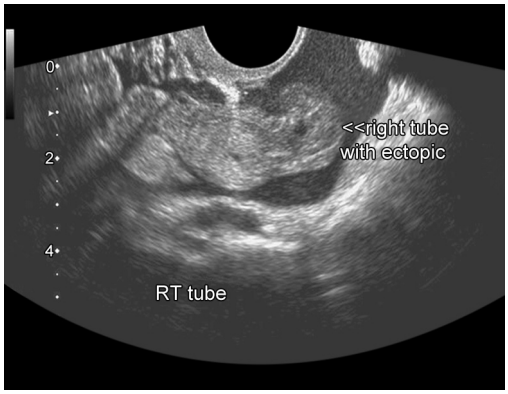

Fig. 3: Ultrasound picture of the right tube showing a ruptured ectopic pregnancy with free fluid in POD.
Source: https://3.imimg.com/data3/PO/KI/MY-12206051/sonography-of-ruptured-ectopic-500x500.jpg

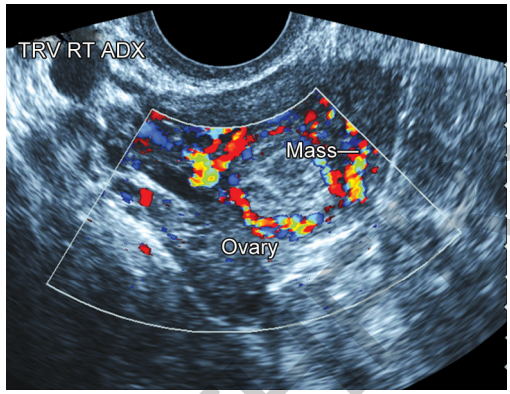

Fig. 5: Ring of fire—ectopic pregnancy.
Source: Hoffman BL, O Schorge J, Bradshaw KD et al. Ectopic pregnancy. Williams gynecology, 3rd edition. New York: McGraw-Hill Education; 2016.
*https://*obgynkey.com/wp-content/uploads/ 2016/06/m_p9780071849081-ch007_f005.png

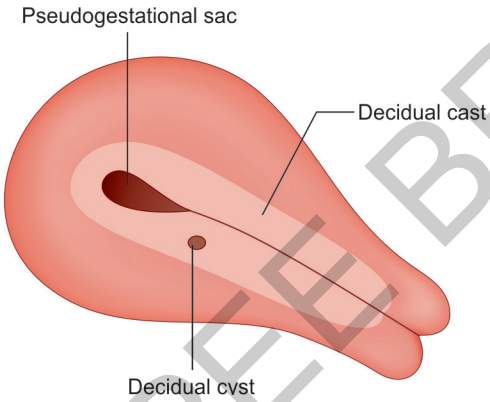

Fig. 4: Trilaminar pattern of endometrium with a centrally located pseudocyst.

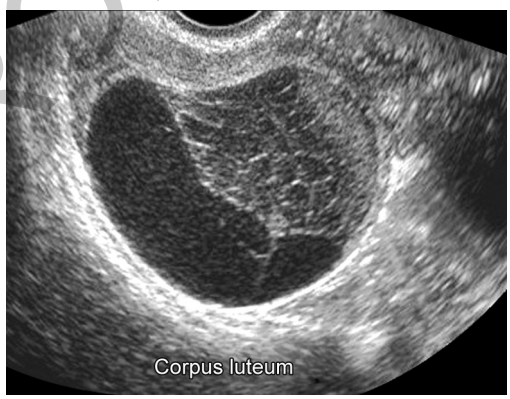

Fig. 6: Cobweb appearance (due to fibrin strands)—corpus luteum.
Source: https://i.pinimg.com/originals/30/bf/bf/30bfbf304c579e90597f17e30f400c55.jpg

corpus luteum is challenging. With TVS Doppler imaging, placental blood flow within the periphery of the complex adnexal mass (ring of fire) can be seen (Figs. 5 to 7).

Classical appearance of a CL cyst: Spongiform and lace-like/reticular pattern.

- *Diagnostic laparoscopy*: In cases where an ectopic pregnancy is suspected and ultrasound is inconclusive, a diagnostic laparoscopy is required. This is believed to be the "gold standard" investigation in ectopic pregnancy. Indeed delay or reluctance in performing a diagnostic laparoscopy has been highlighted as a factor in fatal cases. An alternative to diagnostic laparoscopy may involve serial repeat ultrasound examinations,

JAYPEE BROTHERS

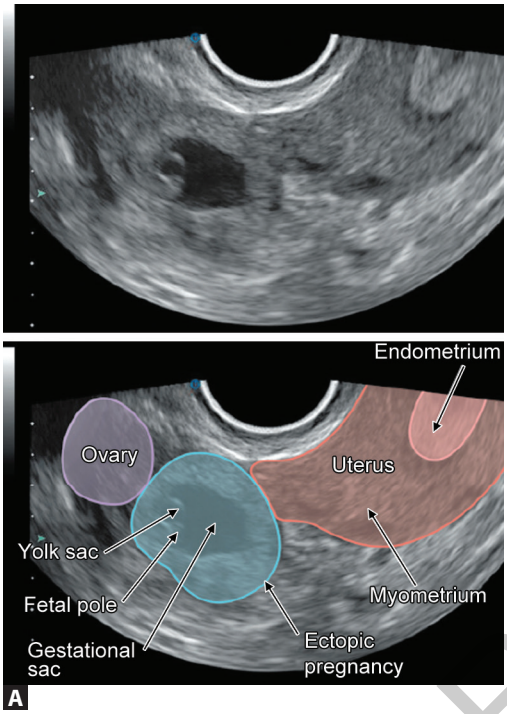

Figs. 7A and B: Picture of uterus without a fetal pole and a complex adnexal mass consistent with ectopic pregnancy.
Source: Simel DL, Rennie D. The Rational Clinical Examination: Evidence-based Clinical Diagnosis. Mayo Clin Proc. 2009;84(11):1045

particularly when β-hCG concentrations are close to 1,500 IU/L.

- *Endometrial biopsy*: In selected cases of pregnancy of unknown location (PUL), an endometrial biopsy may be taken and analyzed for the presence or absence of chorionic villi.

The absence of chorionic villi in the presence of a positive serum β-hCG is suggestive of an ectopic pregnancy. Dilatation and curettage is useful when performed in association with a "negative" diagnostic laparoscopy for a suspected ectopic pregnancy.

Heterotopic Pregnancy[1,3]

Heterotopic pregnancy, a rare phenomenon in the past, is now becoming more common because of assisted reproductive technique (Fig. 8).

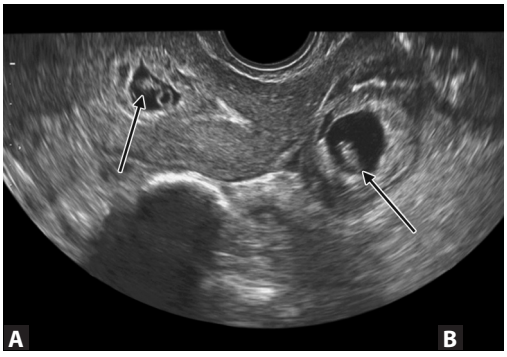

Figs. 8A and B: (A) Intrauterine gestation seen along with a (B) right tubal ectopic gestation.
Source: http://www.ultrasound-images.com/s/cc_images/cache_4215718788.jpg?t=1450776546

JAYPEE BROTHERS

The most important aid in the diagnosis of heterotopic pregnancy is the utilization of high-resolution TVS. The management of heterotopic pregnancy still remains controversial. Operative management is still a mainstay, but it involves surgical and anesthetic risk to both the mother and fetus.

Laparoscopy is preferred in the diagnosis and treatment. Methotrexate with its potential adverse effects on the intrauterine gestation and RU486, a prostaglandin, with their potential effect on uterine contractility, are not options in the treatment of ongoing heterotopic pregnancy. The injection of potassium chloride to selectively reduce multiple intrauterine gestations has been widely used.

Adequate counseling and judicious follow-up of the patient are the essential components of expectant management. The use of more stringent selection criteria results in increase in the efficacy of expectant management to approximately 70%.

Evaluation Algorithm[1]

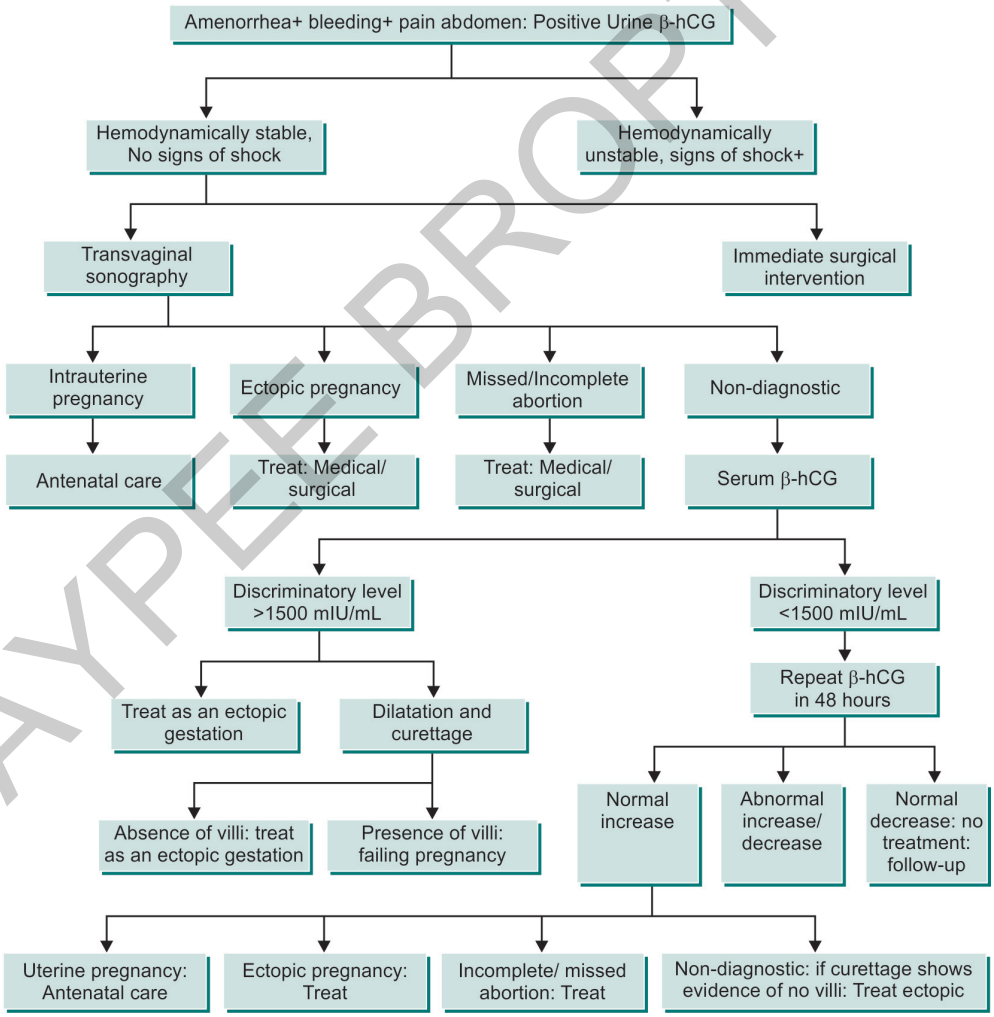

JAYPEE BROTHERS

MANAGEMENT

After a conclusive diagnosis has been made, treatment options comprise:

- Medical management
- Expectant management
- Surgical management

- Acute ruptured ectopic pregnancy is an obstetric emergency requiring immediate surgical management.
- *Postoperatively*: In an Rh-negative woman—not yet sensitized to the Rh antigen. Anti-D gamma-globulin of 50 μg should be given intramuscularly (IM) (deltoid), if gestation <12weeks and a 300 μg dose should be given if the gestation >12 weeks.

Indications for active surgical intervention in ectopic pregnancy are as follows:

- The patient is hemodynamically unstable.
- The patient is diagnosed with a heterotopic pregnancy—containing a viable intrauterine gestation.
- Failed medical therapy
- The patient does not meet the criteria for medical therapy.

Preparation[7-9]

Preoperative orders to be followed:

- Relevant investigations
- Secure a large-bore venous cannula and establish fluid resuscitation
- Ascertain the availability of cross-matched blood
- There should be no delay in the operation, if the patient has an active bleeding site/is in evident shock
- Under aseptic precautions, catheterize the patient before starting the procedure
- In case of unavailability of blood, make arrangements required for autotransfusion.

Take informed consent from the patient after counseling (chances of conversion of a laparoscopy into a laparotomy, unilateral/bilateral salpingectomy if required, chances of bowel and bladder injuries in the presence of adhesions).

Technique

As early diagnosis is aimed for and often achieved in these cases in today's era with the help of faster and accurate laboratory results and technology, it is followed up with a prompt treatment plan.

A multidisciplinary mode of management involving conservative microsurgery has replaced the once-standard laparotomy hence minimalizing tubal damage and maintaining its function.

Laparotomy is only indicated for patients with complicated ectopic pregnancies and patients who present with features of hemorrhagic shock.

Advantages of laparoscopic approach over laparotomy	*Risk factors for converting laparoscopy to laparotomy*
• Laparoscopic surgery is associated with significantly less blood loss • It results in fewer postoperative adhesions • Laparoscopy is more economical for the patient as the period of hospitalization is reduced • Reduced need for analgesia and fast recovery	• Dense pelvic adhesions • Surgical experience and skill of the team • Convenient obtainability of the equipment • Deteriorating condition of the patient • History of multiple abdominal surgeries

JAYPEE BROTHERS

Conservative laparoscopic surgery, usually salpingotomy is opted procedure for in the absence of the below indications. Since salpingectomy is a radical procedure, adequate counseling and informed consent must be obtained prior to the surgery.

Conditions in which salpingectomy is indicated in:

- Patient has completed her family and sterilization is requested and given consent for
- Ruptured ectopic pregnancy
- Ectopic pregnancy after a failure of sterilization or also after a prior partial salpingectomy
- Ectopic pregnancy in a previously reconstructed fallopian tube
- Hemostasis is not achieved after a salpingotomy
- In case of findings conclusive of a chronic tubal pregnancy.

In case the ectopic pregnancy is at the fimbrial end, then gentle evacuation from the fimbria is opted for. Partial salpingectomy is suggested if the pregnancy has implanted in mid portion of the fallopian tube and she is cooperative and is a willing candidate for later tubal reanastomosis (if required).

Aim: Active resuscitation and surgical intervention, as time is of the essence in these cases.

Emergency laparotomy: Abdomen is opened in layers.

Findings: Peritoneum appears bluish in color—blood and clots are suctioned out [it may be collected in acid citrate dextrose (ACD) bottles in 1:5 ratios for autotransfusion if required].

Primary aim is to stop the bleeding, inspect the uterus, and adnexa for the site of rupture. Apply two clamps on ectopic side with the tips meeting the center of the mesosalpinx, examine the area well and rule out (R/O) a broad ligament hematoma. Always inspect the opposite tube and ovary. Carefully cut and remove the section of the tube containing the ectopic pregnancy and ligate the ends. Attain good hemostasis.

Milking out of the sac from the *tube should never be done* as it lacerates the endosalpinx and causes further damage. Intra-abdominal drain should be kept and monitored closely postoperatively. The effected tube and products of conception should be sent for histopathological examination to rule out tuberculous salpingitis for medicolegal reasons.

Procedures:[2,3,10,11]

- *Linear salpingotomy/salpingostomy*: It is the surgery opted for in unruptured (ampullary) ectopic pregnancies (Fig. 9).

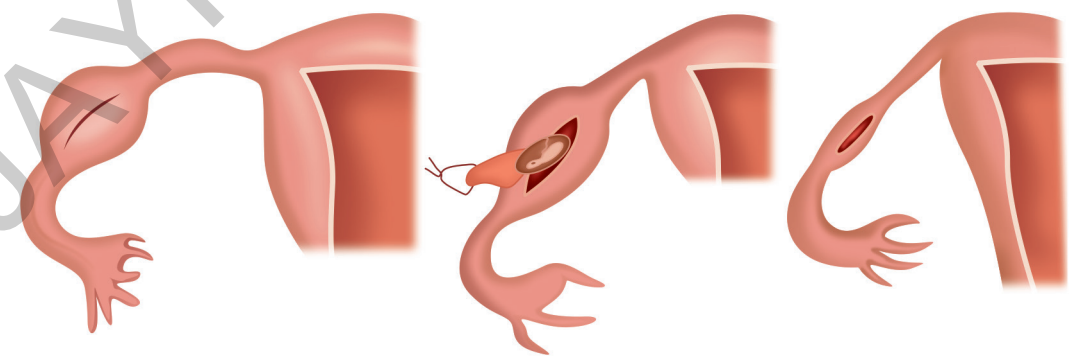

Fig. 9: Technique of salpingostomy.

JAYPEE BROTHERS

for detailed information on obstetrics & gynecology books, visit our website www.jaypeebrothers.com, for detailed information on obstetrics

OBSTETRIC EMERGENCIES

Salient Features

- Obstetric Emergencies is a systematic stepwise approach in managing different situations requiring immediate intervention for busy practitioners and aspiring young Obstetrics and Gynecology students to optimize their practice of managing a variety of obstetric emergencies
- Many chapters like Pregnancy as a Result of Rape, Medicolegal Issues in Obstetrics, Role of Imaging Modalities in Obstetric Emergencies, Diabetic Ketoacidosis in Pregnancy and Labor, etc. have been carefully written by experts to make an easy understanding of the subject
- The book also incorporates latest evidence-based guidelines
- The third edition of this book has current updated scientific evidence with algorithms
- This book will be an invaluable reference to all practitioners.

Kamini A Rao DGO DORCP DCh FRCOG (UK) MCh (UK) FRCOG PGDMLE (Law) FNAMS a pioneer of the assisted reproduction fraternity in India is the Medical Director of Milann—The Fertility Center, Bengaluru, Karnataka, India and a recipient of the Padma Shree. Her vision for developing the reproductive medicine talent in the country led to the setting up of a strong education vertical which is affiliated to Milann (A unit of BACC Healthcare), and is considered to be amongst the country's premier institutions for education and training in reproductive medicine. Being academically oriented, she has authored nearly 50 medical textbooks and a large number of journals and chapter publications. She served as the President of the Federation of Obstetric and Gynaecological Societies of India (FOGSI) in the year 2000 as well as the President of the Indian Society for Assisted Reproduction (ISAR) between 2006 and 2008. She is the Member of the Central Supervisory Board, Government of India, for implementation of the Prenatal Diagnostic Techniques (PNDT) Act, the National Apex Committee for Stem Cell Research and Therapy, and the Drafting Committee for formulating national guidelines for "Accreditation, Supervision and Regulation of ART Clinics in India".

Vyshnavi A Rao MBBS MS (OBG) FRM (Reproductive Medicine) is Consultant IVF Specialist at Milann (A Unit of BACC Healthcare), Bengaluru, Karnataka, India. She has completed her MBBS and MS from Vydehi Institute of Medical Sciences and Research Center, Bengaluru, and FRM from Dr Patil's Fertility and Endoscopy Center, Bengaluru. She is the Joint Secretary to Karnataka chapter of IFS. She has participated as Faculty in various National Conferences. She has received Nav Shakti Award at 11th National Women Excellence Award at New Delhi, 2018 organized by Yog Confederation of India, North Eastern Council, Government of India and Vaidya Ratna Young Achiever award in Feb 2019, from Akhila Karnataka Vipra Vanitha Seva Prathishthana. She has contributed extensively to the curriculum and chapters for nationally recognized textbooks in Reproductive Medicine.

Available at all medical bookstores
or buy online at www.jaypeebrothers.com



JAYPEE BROTHERS
Medical Publishers (P) Ltd.
www.jaypeebrothers.com

Join us on facebook.com/JaypeeMedicalPublishers

Shelving Recommendation
OBSTETRICS & GYNECOLOGY

