mation on ophthalmology books, visit our website www.jaypeebrothers.com, for detailed information on ophthalmology books, visit our website www.jaypeebrothers.com

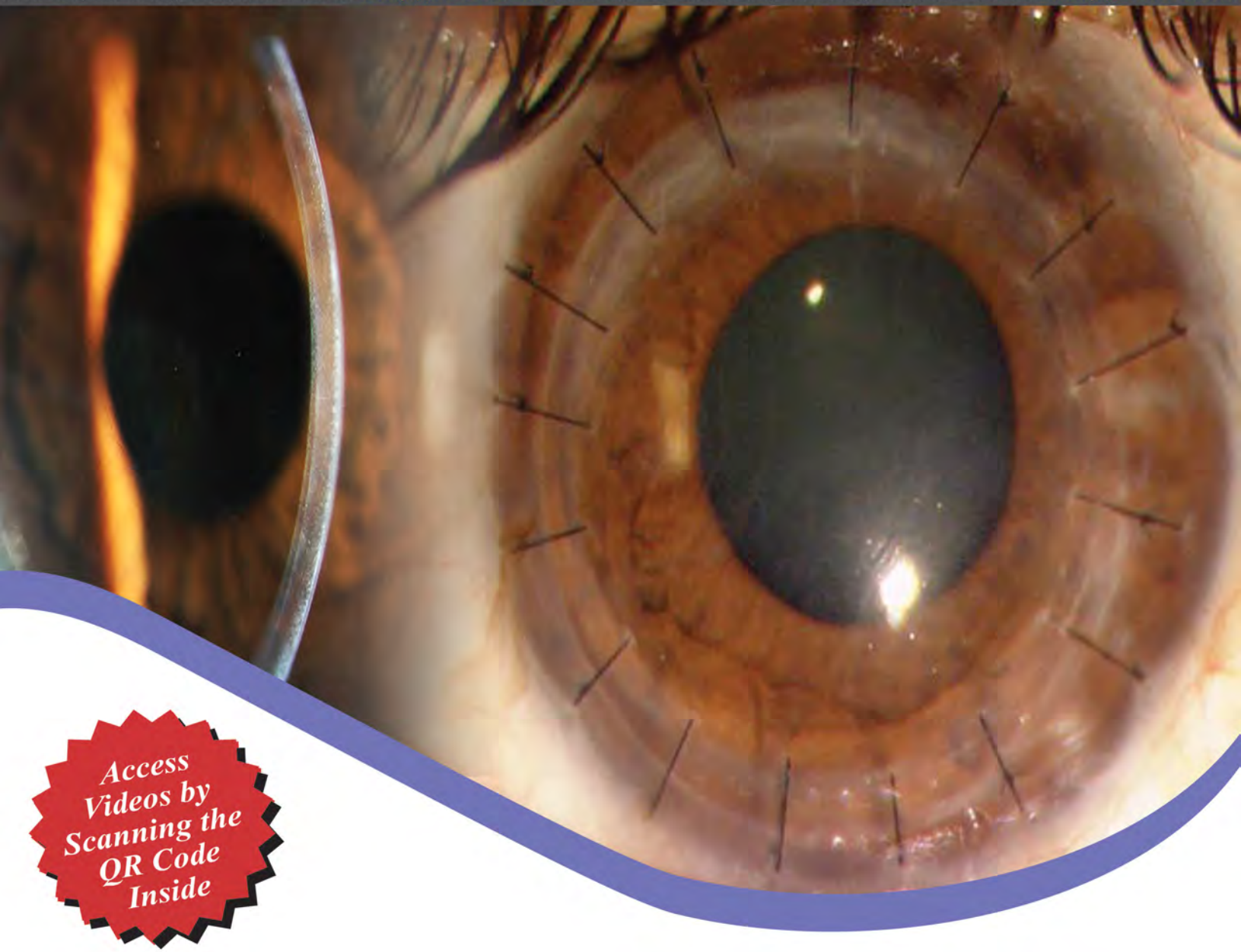

Access Videos by Scanning the QR Code Inside

CORNEAL TRANSPLANTATION

with Videos

3rd Edition

Editors
Namrata Sharma
Ritu Nagpal
Rasik B Vajpayee

Forewords
Hugh R Taylor
Mark J Mannis
Jorge L Alió

JAYPEE

Contents

SECTION 1: Evolution, Preoperative Considerations, and Eye Banking

1. **Evolution of Corneal Grafting Surgery** 3
   Namrata Sharma, Prabhakar Singh, Chandrashekhar Kumar
2. **Indications and Outcomes of Penetrating Keratoplasty** 7
   Urmimala Ghatak, Sridevi Nair, Ritu Nagpal, Namrata Sharma
3. **Preoperative Evaluation** 15
   Namrata Sharma, Sridevi Nair, Ritika Sachdev, Manotosh Ray
4. **Eye Banking for Corneal Transplantation** 24
   Graeme A Pollock
5. **Medicolegal Aspects of Eye Banking** 40
   M Vanathi, Rakhi Nathawat, Gurnarinder Singh, Rakesh Ahuja
6. **Setting Up Corneal Transplant Center** 47
   Rakhi Nathawat, Namrata Sharma, Rasik B Vajpayee
7. **Setting Up an Eye Bank** 53
   Mukesh Taneja, Rakhi Nathawat, Prashant Garg, Usha Gopinathan
8. **Accessing Human Corneal Tissue** 58
   Heather Machin, Collin Ross

SECTION 2: Penetrating Keratoplasty

9. **Surgical Instruments for Penetrating Keratoplasty** 67
   Prakash Chand Agarwal, Rinky Agarwal, Namrata Sharma, Vishal Gupta
10. **Suture Materials and Needles** 77
    Mohamed Ibrahime Asif, Suman Lata, Namrata Sharma
11. **Technique of Penetrating Keratoplasty** 80
    Nicholas York, Nagib Du Toit, Rasik B Vajpayee
12. **Suturing Techniques in Penetrating Keratoplasty** 94
    C Banu Cosar, Peter R Laibson
13. **Postoperative Care after Penetrating Keratoplasty** 99
    Raj Maini, Rinky Agarwal, Urmimala Ghatak, Hugh R Taylor
14. **Postkeratoplasty Contact Lens Fitting** 108
    Rajesh Sinha, Suman Lata, Jeewan S Titiyal

SECTION 3: Penetrating Keratoplasty: Management of Complications

15. **Complications of Penetrating Keratoplasty** 119
    Mohamed Ibrahime Asif, Ritu Nagpal, Sarath S, Namrata Sharma
16. **Post-penetrating Keratoplasty Glaucoma** 140
    Viney Gupta, Shikha Gupta, Jonathan G Crowston
17. **Corneal Graft Rejection** 146
    Robin G Abell, Ben Connell, Michael S Loughnan
18. **Surgical Management of Refractive Errors Following Corneal Transplantation** 152
    Haitham Al-Mahrouqi, Shokufeh Tavassoli, Mohammed Ziaei

SECTION 4: Lamellar Keratoplasty

A: Anterior Lamellar Keratoplasty Techniques

19. **Surgical Instruments for Lamellar Keratoplasty** 163
Namrata Sharma, Sohini Mandal, Prakash Chand Agarwal, Rasik B Vajpayee

20. **"Dry" Manual Technique for Deep Anterior Lamellar Keratoplasty** 172
Paolo Rama, Karl Anders Knutsson

21. **Automated Lamellar Therapeutic Keratoplasty** 177
Namrata Sharma, Sohini Mandal, Ritu Nagpal, Sameer Kaushal

22. **Superficial Anterior Lamellar Keratoplasty** 184
Giuseppe Giannaccare, Angeli Christy Yu, Massimo Busin

23. **Deep Anterior Lamellar Keratoplasty: The Melles Technique** 186
Keamela Vasanthananthan, C Maya Tong, Gerrit RJ Melles

24. **Deep Anterior Lamellar Keratoplasty: Big Bubble Technique** 194
Luigi Fontana, Antonio Moramarco

25. **Deep Anterior Lamellar Keratoplasty: Double Bubble Technique** 198
Vishal Jhanji, Ritu Nagpal, Sarath S, Namrata Sharma, Rasik B Vajpayee

26. **Large-diameter Deep Anterior Lamellar Keratoplasty** 203
Angeli Christy Yu, Asaf Friehmann, Massimo Busin

27. **Cannula-assisted Big Bubble Deep Anterior Lamellar Keratoplasty** 209
Rajesh Fogla

28. **"Groove and Peel" Deep Anterior Lamellar Keratoplasty** 213
Rishi Swarup

29. **Diamond Knife-assisted Deep Anterior Lamellar Keratoplasty** 217
Sri Vatsa Sehra, Prafulla K Maharana, Elsie Chan, Namrata Sharma, Rasik B Vajpayee

30. **"Tuck in" Lamellar Keratoplasty** 223
Namrata Sharma, Vishal Jhanji, Sohini Mandal, Rahul Kumar Bafna, Rasik B Vajpayee

B: Endothelial Keratoplasty Techniques

31. **Surgical Instruments for Endothelial Keratoplasty** 228
Priyadarshini K, Ritu Nagpal, Namrata Sharma, Rasik B Vajpayee

32. **Descemet's Stripping Automated Endothelial Keratoplasty** 234
Marianne O Price, Sohini Mandal, Francis W Price Jr

33. **Thin Lenticule Descemet's Stripping Automated Endothelial Keratoplasty** 247
Prabhakar Singh, Sohini Mandal, Namrata Sharma

34. **Ultrathin Descemet Stripping Automated Endothelial Keratoplasty** 250
Angeli Christy Yu, Asaf Friehmann, Massimo Busin

35. **Manual DSEK: "Manual Dissection" Technique of Descemet Stripping Endothelial Keratoplasty** 256
Samar K Basak, Soham Basak

36. **Pre-Descemet's Endothelial Keratoplasty** 262
Amar Agarwal

37. **Tectonic Descemet Stripping Automated Endothelial Keratoplasty** 277
Vincenzo Scorcia, Angeli Christy Yu, Massimo Busin

38. Descemet's Stripping Automated Endothelial Keratoplasty: Triple Procedure 280
Vishal Jhanji, Sarath S, Ritu Nagpal, Rasik B Vajpayee

39. Descemet's Membrane Endothelial Keratoplasty 286
Denisse Pinkus, Marianne O Price, Francis W Price Jr

SECTION 5: Specific Techniques in Corneal Transplantation

40. Keratoplasty and Cataract Extraction: Triple Procedure 303
Mohamed Ibrahime Asif, Namrata Sharma

41. Penetrating Keratoplasty for Aphakic and Pseudophakic Bullous Keratopathy 312
Sujata Das, Smrutirekha Priyadarshini, Vishal Gupta

42. Pediatric Corneal Transplants 321
Gerald W Zaidman

43. Therapeutic Keratoplasty 331
Eric Donnenfeld, Nandyala Sushma, Ritu Nagpal

44. Shaped Penetrating Keratoplasty 343
Priyadarshini K, Bhavana Sharma, Namrata Sharma, Rasik B Vajpayee

45. Noncircular Corneal Transplantation 348
Rashmi Deshmukh, Louis J Stevenson, Rasik B Vajpayee

46. Crescentic Tuck in Lamellar Keratoplasty 355
Ritu Arora, Shipra Sarda

47. Hemi-automated Lamellar Keratoplasty 360
Hassan Mansoor, Jodhbir S Mehta

48. Compressive C-shaped Lamellar Keratoplasty 371
Namrata Sharma, Prakhyat Roop, Ritu Nagpal

49. Femtosecond Laser-assisted Keratoplasty 374
Nir Sorkin, David S Rootman

50. Femtosecond Laser-assisted Deep Lamellar Endothelial Keratoplasty 382
Jorge L Alió del Barrio, Verónica Vargas, Bruce D Allan

51. Bowman's Layer Transplantation 386
Bhavana Sharma, Harsha Saxena, Rasik B Vajpayee

52. Tectonic Patch Grafts 389
Nikhil S Gokhale

53. Autokeratoplasty 395
Tushar Agarwal, Sohini Mandal, Namrata Sharma, Rasik B Vajpayee

54. Autorotational Keratoplasty 400
Namrata Sharma, Sohini Mandal, Nandyala Sushma, Rasik B Vajpayee

55. Limbal Stem Cell Transplantation 407
Swapna S Shanbhag, Anahita Kate, Sayan Basu

56. Large-diameter Anterior Lamellar Keratoplasty 419
Sohini Mandal, Namrata Sharma, Rasik B Vajpayee

57. Femtosecond Laser-assisted Tuck-in Penetrating Keratoplasty 423
Jorge L Alió del Barrio, Olena Al-Shymali, Jorge L Alió

58. Microscope-integrated Intraoperative Optical Coherence Tomography-guided Keratoplasty 427
Namrata Sharma, Priyadarshini K, Pranita Sahay, Rahul Kumar Bafna, Ritu Nagpal

59. Amniotic Membrane Transplantation 435
Ahmad Kheirkhah, Sean Tighe, Olivia Mead, Scheffer CG Tseng

SECTION 6: Indication Specific Techniques of Corneal Transplantation

60. Pellucid Marginal Degeneration 453
Sohini Mandal, Somasheila I Murthy

61. Terrien's Marginal Degeneration 466
Sohini Mandal, Somasheila I Murthy

62. Keratoglobus 474
Priyadarshini K, Ritu Nagpal, Namrata Sharma, Rasik B Vajpayee

63. Severe Corneoiridic Scars 480
Priyadarshini K, Ritu Nagpal, Namrata Sharma

64. Anterior Staphyloma 484
Priyadarshini K, Ritu Nagpal, Namrata Sharma

65. Descemetocele 488
Rinky Agarwal, Prerna Agarwal, Ritu Nagpal, Namrata Sharma

66. Sclerokeratoplasty 496
Shreya Thatte, Ankita B Dube, Trupti Dubey

SECTION 7: Alternatives to Corneal Transplantation

67. Keratoprosthesis: A Broad Overview 505
Hiren Matai, Shweta Agarwal, Bhaskar Srinivasan, Geetha Iyer

68. The Boston Type II Keratoprosthesis 513
Shaunak K Bakshi, James Chodosh

69. Phototherapeutic Keratectomy 519
Ritu Nagpal, Somasheila I Murthy, Christopher J Rapuano, Namrata Sharma

70. Optical Sector Iridectomy 531
M Vanathi, Sarath S, Rasik B Vajpayee, Namrata Sharma

71. Corneal Tattooing 534
Nikhil S Gokhale

72. Prosthetic Contact Lenses 539
Monica Chaudhry

73. Gundersen Flap 544
Prakash Chand Agarwal, Sarath S, Ritu Nagpal, Namrata Sharma, Rasik B Vajpayee

74. Future Developments 547
Vishal Jhanji, Karl David Brown, Ritu Nagpal, Sarath S, Hugh R Taylor

Index 553

4 Eye Banking for Corneal Transplantation

Graeme A Pollock

INTRODUCTION

The process of corneal transplantation begins with eye donation. Corneal transplantation is not possible without the provision of a viable, disease-free donor cornea. Eye banks and effective eye banking practices are central to providing this essential service.

Since the establishment of the Eye-Bank for Sight Restoration in New York in 1944, eye banking has evolved in both professional practice and scope and moved far beyond the concept of a simple storage and supply unit for the purposes of full-thickness penetrating keratoplasty (PK). The professional practice of eye banking can be defined as encompassing two interdependent processes: (1) the coordination, identification, consent, and surgical donation of eyes from recently deceased persons (eye donation) and (2) the evaluation, processing, preservation, and equitable allocation of safe and efficacious allograft tissue for transplantation (eye banking in the technical sense). In the past decade and a half, these services have extended into customized tissue preparations to accommodate the different forms of corneal transplantation.

While the scope of activity undertaken by an individual eye bank may be determined by jurisdiction, regulation, nation, or health system in which it operates, the cornerstone of eye banking and corneal transplantation is the availability and donation of eyes from recently deceased persons. While this chapter does not deal directly with this issue, it is incumbent that any eye bank recognizes the importance of advocacy for eye donation within their health system to ensure policy, regulation, legislation, and ethical practice provide for sustainability and growth in eye donation as the demand for transplantation increases. In this respect, eye banks need to engage with, or directly provide hospital development and professional in-service programs designed to maximize the appropriate identification of suitable donors and referral to the eye bank.

The continued development, complexity, professionalism, and evolution of the services provided by eye banks has been accompanied by the development of robust quality management systems. These incorporate peer reviewed evidence-based standards with an emphasis on risk assessment and mitigation. In many nations, government regulations have mandated such standards within a framework of current of good tissue practice (cGTP) or good manufacturing practice (cGMP). As such, eye banking now not only includes the classical areas of donor selection/eligibility, retrieval/recovery, preservation and storage, and tissue evaluation, but importantly must now also address quality in traceability, personnel and training, documentation, facilities and equipment, materials, packaging and labeling, and notification and recall systems.

Increasing globalization of eye banking, transnational movement of corneas between sovereign states and new business practices employed by some organizations, has highlighted that all aspects of eye banking needs to be conducted within an acceptable ethical framework. Importantly, this now not only includes issues relevant to the donation of human ocular tissue, but also to its allocation and use. Guidance is provided by the Barcelona Principles[1] and the World Health Organization (WHO).[2]

DONOR SELECTION

While the technical aspects of eye banking must be robust to ensure the provision of safe tissue, it is in the careful selection or exclusion of potential donors that is of utmost importance in preventing the transmission of disease to the recipient. In addition, donor selection must also consider matters regarding the quality, or potential efficacy for purpose, of the tissue.

Many of the standards that have been adopted by eye banks worldwide were initially developed by the Eye Bank Association of America (EBAA)[3] who produced their first set of medical standards in 1980. A rigorous review process has ensured that these medical standards continue to evolve as new knowledge, insights, and challenges develop. These standards are supported by the EBAA procedures manual which provides valuable guidelines and rationale toward implementing the standards. Other eye banking

JAYPEE BROTHERS

organizations, such as the European Eye Bank Association,[4] have also developed minimum standards that are reviewed each year. The European Directorate for the Quality of Medicines and Healthcare publish a comprehensive guide to the quality and safety of tissues and cells for human application which covers general principles involved in the quality management of the technical aspects of eye and tissue banking, as well as a specific chapter on ocular tissue requirements and ocular tissue monologues.[5]

It is important however when developing medical standards that each jurisdiction analyses their own unique situation to ensure assessment of potential risk in the donor is balanced against benefit of the transplant. The balance will vary by disease prevalence in the local donor pool, the consequences of transmission of disease, available local resources available in pathology and testing, and other risk mitigation strategies. The degree of acceptable risk will therefore vary by jurisdiction. Each eye bank jurisdiction should consider their contraindications accordingly.

Contraindications for the Use of Donor Tissue

The Eye Bank Association of Australia and New Zealand (EBAANZ) contraindications for the use of donor tissue are available at www.ebaanz.org/medical-standards-and-quality.[6] These contraindications are designed to reduce the potential for (1) viral transmission of disease; (2) transmission of bacterial or fungal infections; (3) transmission of malignant disease; (4) transplantation of corneal disorders, or of those corneas which pose a risk to the success of the surgery. These standards are supported by EBAANZ guidelines for the selection of ocular tissue donors.[7]

To successfully implement these standards eye banks must have consistent policies for the examination and documentation of a prospective donor's available medical records, medical history or investigation of cause of death. Donor history gathering should be to an extent to which it is possible to make an acceptable judgment on donor risk. Sources of information may include but not be limited to:

- Medical record or hospital charts
- Donor risk assessment interview with the donor's family member or friend who can answer questions about the donor's medical and lifestyle history.
- Physical assessment of the donor to identify risk factors for potential infection with transmissible diseases (the extent of which is in keeping with the overall risk profile of the donor).
- Death certificate
- Coroner or pathologist's report on the physical assessment of death
- Treating physician or general practitioner interview/report.

In deciding on donor eligibility, all evidence should be examined together within the circumstances of the donor rather than in isolation, considering objective and subjective evidence and the validity of each piece of evidence. An individual who is qualified either by profession, education, or training to perform all the above tasks, and familiar with the potential surgical uses of the tissue should perform donor screening.

Disease Transmission from Donor Corneas

Fortunately, iatrogenic transmission of serious or fatal systemic disease from corneal transplantation is a rare event. A review of the world literature reveals only 13 reports of disease transmission since 1939 (excepting bacterial and fungal contamination and transmission).

Diseases that could potentially be transmitted by corneal transplantation fall into three categories:

1. Prion disease [Creutzfeldt–Jakob disease (CJD) and associated variants]
2. Infections (bacterial, fungal, and viral)
3. Malignancies

A good understanding of these cases and an understanding of the underlying pathogens is instructive when considering the degree of risk of transmission that each of these diseases pose.

Prion Disease

Duffy et al.[8] reported the possible transmission of CJD in 1974 and during the 1990s two further possible cases were reported.[9,10] However, the evidence for transmission in these later two cases is limited. In 1999, Hogan et al.[11] reviewed known cases of transmission of CJD by tissues and concluded that the risk of transmission was very low. In addition, they suggested that the review of a potential donor's available medical information for any evidence of a diagnosis or family history of CJD or evidence that human pituitary hormone had been administered was enough to guard against the extremely low potential risk of disease transmission.

Initial concern about the presence of variant CJD (vCJD) in the United Kingdom and the theoretical possibility of human-to-human transmission has tempered in recent years. Those nations that have excluded from donation those people who have visited or resided in the United Kingdom for a cumulative period of 6 months (some 3 months) or more between 1980 and 1996, based on increased risk of vCJD transmission from such donors, are now reviewing these policies. In 2010, Garske and Ghani[12] predicted a peak global annual incidence of vCJD around 11 cases, but with a 95% credibility interval between one and 65 cases. Notably, UK surveillance data after the 2010 modeling records a total of 10 cases from 2010 to November 2020, with no cases since 2016.[13] Variant CJD has a very different epidemiology and presentation than sporadic (classical) CJD (sCJD), and

JAYPEE BROTHERS

vCJD has behaved differently from sCJD with respect to transmission. Unlike blood transfusion, ocular tissues have not been implicated in any case of vCJD transmission.[14]

Interestingly, data on CJD and vCJD suggests the disease-related prion protein (PrP^{Sc}) may not be widely distributed in human eye tissue. In three cases of sporadic (or classical) CJD, no PrP^{Sc} was detected in proximal optic nerve, sclera, retina, vitreous humor, lens, aqueous humor, iris or cornea. In the one case of vCJD, investigated PrP^{Sc} in the eye was restricted to the optic nerve and retina.[15] In addition, in a widely reported case of transplantation of ocular tissues from a donor subsequently determined to have sporadic CJD (where subsequently tissues were explanted with no known transmission) there was no evidence of PrP^{Sc} in the cornea.[16] These findings, together with only one case of CJD being plausibly attributed to corneal transplants among millions of recipients, have led to cornea now being categorized as a lower-risk tissue by the WHO and the Australian Government Department of Health.[17,18]

Infections—Viral

During the history of eye banking corneas have transmitted three types of virus that have the potential for harm to the recipient or the outcome of the transplant—hepatitis B, herpes simplex, and rabies.

Nine cases of rabies transmission from six donors resulting in eight deaths have been documented between 1979 and 1996.[19-24] In all cases, rabies was not identified in the donor until transmission had occurred. In only one case, rabies in the donor was detected promptly and subsequent intensive immunotherapy for the recipient prevented their death.[25] The problem arises that diagnosis in a potential donor can be difficult if the rabies does not present with its classical picture of hydrophobia and hyperesthesia (furious rabies). In the Iran case, the donor is described as presenting only the prodromal symptoms of fever, malaise, headache, and gastrointestinal infections prior to death. However, even in the less common paralytic or dumb rabies, flaccid paralysis develops and the exclusion criteria of "death from central nervous system disease of unestablished diagnosis" would today exclude such potential donors from becoming actual donors.

The possibility of iatrogenic transmission of hepatitis B virus (HBV) has long been recognized. Two cases of transmission from 1984 and 1985 were reported by Hoft et al.[25] Both these cases took place before routine serological screening of donors for hepatitis B surface antigen (HBsAg). There have been no further reports of transmission since.

Hepatitis C virus has been detected in corneas[26] and in the media of organ-cultured corneas of seropositive donors[27] although at the very low concentration of virus detected, it remains arguable whether transmission via corneal transplantation is likely. In one case of a donor being anti-HCV-negative but HCV ribonucleic acid (RNA)-positive, HCV infection occurred in eight of 30 recipients of organ and tissues but not in the single recipient of a corneal transplant.[28] These negative reports suggest that the transmission of HCV through corneal transplantation is highly unlikely, and of course has not been reported.

Similarly, the human immunodeficiency virus (HIV) has been shown to be present in a human cornea[29] but such a presence may not lead to transmission of the disease by corneal transplantation. There are three reports in the literature of HIV-infected donors where the corneal recipients have not seroconverted.[30-32] Again, all these negative reports suggest that the transmission of HIV through corneal transplantation is highly unlikely, and of course has not been reported.

The recent corona virus SARS-CoV-2 global pandemic has created great concern about the possibility of transmission through corneal transplantation, and indeed the transmissibility of many other virus-types that may potentially be the causative agent of an epidemic. In one publication, the authors demonstrated a small but noteworthy prevalence of SARS-CoV-2 viral RNA and antigens in the corneas from coronavirus disease 2019 (COVID-19) donors, although they indicated further studies were necessary to explore the possibility of transmission via ocular tissues.[33] Fortunately, there is no evidence to suggest that any coronavirus [including severe acute respiratory syndrome (SARS-CoV) and Middle East respiratory syndrome coronavirus (MERS-CoV)], nor any influenza virus, has been transmitted by cell, tissue or organ transplantation or by blood. However, the degree of risk that a pathogen presents to eye banking is not only a factor of the likelihood of transmission via transplantation but also the degree of consequence to the recipient if a transmission should take place. The degree and type of risk mitigation measures must then consider the prevalence of the causative agent in the donor population, the consequences of transmission, the availability of validated testing for the agent, and any interventions that may inactivate the agent. This has been the approach to COVID-19 as a contraindication. Donors suspect of having coronavirus are excluded from donation while povidone-iodine readily inactivates coronavirus (SARS-CoV and MERS-CoV) infectivity.[34] The need for postmortem COVID-19 testing has been debated due to the high false positive rate, the nonvalidated nature of the test, availability of the test and its cost-effectiveness in areas of low prevalence. All of these are precautionary measures considering the low risk of transmission.

There is also a group of diseases listed as contraindications that are diseases of possible but unproved viral etiology. This includes subacute sclerosing panencephalitis, progressive multifocal leukoencephalopathy, Reyes syndrome, acute leukemia, and active disseminated lymphomas such as Hodgkin's disease. Hematological malignancies,

JAYPEE BROTHERS

with decreased immunological defense mechanisms, may also mask opportunistic viral or bacterial infections.

Infections—Bacterial and Fungal

Septicemia is a contraindication in a prospective corneal donor because of the risk of pathogenic organisms being harbored in the conjunctiva, surviving the antibiotics used throughout the retrieval and buttoning process, and eventually leading to an endophthalmitis in the recipient's eye. The only exception to this is if the corneas are to be placed in organ culture for preservation. The microbiological surveillance during organ culture allows the exclusion prior to transplantation of those corneas that may be harboring organisms and therefore reduces the risk of transmission to the recipient.

A search of the Project Notify library, the global vigilance, and surveillance database for medical products of human origin[35] list 25 case reports of harm to a recipient due to transmission of bacteria or fungus from the donor tissue where the imputability level has been assessed as possible, probable or certain. Several publications have also reported the incidence of endophthalmitis following PK ranging from 0.11 to 1.05% but whether donor tissue contamination was considered as causative is not defined.[36-39] A systemic review published in 2005 estimated an overall post-PK endophthalmitis rate of 0.382%.[40] All these reports are prior to widespread endothelial keratoplasty (EK) being adopted.

Importantly regarding EK, the EBAA medical review subcommittee on adverse reactions reported an increasing trend in the rate of endophthalmitis and keratitis from 2007 to 2014. This was disproportionately associated with EK and Candida species.[41] The surge in fungal infections [associated primarily with hypothermic storage and Descemet's stripping automated endothelial keratoplasty (DSAEK)] has somewhat abated since a peak in 2017 (7.6/10,000) to 5.0 and 2.3/10,000 in 2018 and 2019. This may be attributed to more efficient decontamination protocols at the time of recovery, combined with reducing warming times during donor tissue EK preparation. The role of supplementation of hypothermic media with antifungal preparations is less clear.[42]

Of note is that all reports, where the cause of infection may be attributable to donor tissue contamination, suggest that the contamination originated with the donor and was not introduced during any processing undertaken within the eye bank. This emphasizes the importance of effective epithelial donor tissue decontamination prior to corneal storage in reducing the (uncommon) instances of post-transplant keratitis or endophthalmitis.

Malignancies

There are two cases reported where a malignancy has been transmitted through corneal transplantation. In the first case, a retinoblastoma was transplanted from the donor eye to the recipient eye.[43] There is also a report of transmission of a disseminated adenocarcinoma from donor to the recipient's iris with confirmation of tumor markers with polymerase chain reaction (PCR).[44] It would be incorrect however to consider malignancies in the donor as being high risk for transmission of disease. Nonhematological malignancy is not an exclusion for donation, and a substantial percentage of the hundreds of thousands of corneal transplants performed have used corneas from donors with malignancies without any evidence of transmission. However, the two isolated cases reported above, both relating to malignancies in the donor eye, demonstrate the importance of a careful examination, including the posterior pole of the eye, to exclude the possibility of malignancy or other pathology in the donated eye.

A third report is that of patient who developed an ocular melanoma after she had limbal stem cell transplantation from a donor with history of melanoma.[45] Following this report, the EBAA amended its medical standards to exclude for transplantation, corneas from donors with known metastatic melanoma.

Although leukemia and lymphoproliferative disorders pose the greatest theoretical risk of transmission, due to a possible viral etiology, no cases of transmission have been reported. However, these latter disorders remain as a contraindication.

Intrinsic Eye Disease or Anterior Segment Surgery

Local corneal disorders or surgery may pose a risk to the success of corneal transplant surgery. Keratoconus in its early stages or corneal dystrophies may go undetected. Incisional surgery to correct myopia is detected through the appearance of radial and arcuate lines upon slit-lamp examination but detecting past photorefractive surgery in a donor cornea is difficult and can easily go undetected, particularly in organ-cultured corneas.[46] This type of surgery is best detected through interview with the donors next of kin although multiple modalities such as topography, pachymetry, specular microscopy, and optical coherence tomography have demonstrated some effectiveness in identifying these eyes.[47] Modern cataract extraction by phacoemulsification and the replacement of the host lens by an intraocular lens is not an absolute contraindication to donation. However, in these cases, microscopy of the endothelium is required to exclude those corneas showing low cell density or abnormal morphology.

Donor corneas with prior refractive surgery are unsuitable for PK, anterior lamellar keratoplasty, epikeratoplasty, or tectonic corneal grafting surgeries. However, donor tissue with a history of keratorefractive surgery retains endothelial integrity and has been used with good outcomes in DSAEK and Descemet's membrane endothelial keratoplasty (DMEK).[47]

JAYPEE BROTHERS

Donor Age and Endothelial Cell Density

Evidence from the multicenter outcome registries of the United Kingdom[48] and Australia[49] and the controlled clinical trial of the Cornea Donor Study[50] shows that there is no influence of donor age on corneal transplant outcome after PK. Graft survival is equivalent across all donor age groups at all-time intervals post-transplant. Similarly, these outcome registries,[48,49] Cornea Donor Study[50] and its ancillary Specular Microscopy Ancillary Study,[51] have shown no association between preoperative endothelial cell density (ECD) (which decline with donor age) and graft survival (preoperative ECDs being above the lower limits acceptable by eye banks—generally between 1,800 and 2,200 cells/mm^2).

The influence of donor age on graft survival following DSAEK surgery is less clear and appears to have as confounding variable the experience of the operating surgeon in the relevant procedure. Data from the 2018 Report of Australian Corneal Graft Registry (ACGR) indicated a significant difference across groups with survival for grafts performed with tissue from donors aged under 40 years being better than those aged 40–69 years, and 70 years or older. Similarly, corneas with cell counts under 2,500 cells/mm^2 had significantly poorer survival than donor corneas with higher ECD. However, the Registry notes that differences in rates of follow-up across subgroups was likely to have affected survival calculations for these factors.[49] In contrast, the Swedish Cornea Transplant Registry reported that higher age or low ECD was not detrimental to graft survival following DSAEK.[52]

For DMEK the situation is more nuanced. The ACGR reports that DMEK with survival for grafts performed with tissue from donors aged *under* 50 years significantly poorer than those aged 60–69 years and 70–79 years.[49] This result is thought to be associated with the surgical difficulties and complications of handling a "tighter scroll" of DMEK tissue in donors below 50 years.[53] Price[54] has recommended that new surgeons use older donor tissue, particularly that between 60 and 75 years old. Others have reported that with surgeon experience donor characteristics such as younger donor age, higher donor age, lower preoperative ECD (<2,500) and donor diabetes did not affect outcome at 1 year.[55,56]

Lower Donor Age

There is no clearly defined lower age limit for corneal donation. The Eye Bank Association of Australia and New Zealand list the minimum age as 2 years. Problems relate to both the technical difficulties in using infant tissue and the complication of postoperative myopia. The extreme thinness of the infant cornea means that it is likely to fold upon itself during handling. This, combined with the small diameter of the cornea, creates problems during the donation surgery, trephining, and during placement and suturing in the host bed. Koenig provides a review of these problems.[57] The myopic shift after keratoplasty with infant donor corneas has been related to the steep curvature of these corneas.[58]

Key Points—Donor Selection

- Careful selection or exclusion of donors is of prime importance in preventing transmission of disease to the recipient and ensuring suitability for transplantation.
- Medical standards are available from eye banking associations but should be reviewed by local jurisdictions for their own risk versus benefit balance. Transmission of disease through corneal transplantation is rare. Corneas have transmitted rabies, hepatitis B, and possibly classical CJD.
- The risk of transmission of bacteria or fungi from donor to recipient can be mitigated by effective epithelial donor decontamination at the time of retrieval.
- Nonhematological malignancy is not an exclusion to donation.
- There is no influence of donor age on graft outcome for PK or DSAEK. In experienced surgical hands, there is no influence on graft outcome for DMEK, but over 50 years of age donors are preferred.

DONATION OF EYE TISSUE

Eye Donor Coordination

Arguably, an Eye Bank's most important work is done during consent, the interaction with bereaved family members and with the process of gathering of accurate medical histories. All of this involves multiple interactions with a variety of sources such as relatives, medical and nursing staff, pathologists, and general practitioners. The skill is in the collection, assimilation, and analysis of all this information while ensuring that the donor family is cared for and is fully informed of their choices and the processes that donation entails. All of this must be done within an ethical and professional framework to reduce the risk of harm to the donor family and to the prospective recipients of donated tissue.

The form of the consent, or authority to proceed with the donation, will of course vary depending on the jurisdiction's legislation and social culture, but regardless of this the donor coordinator should ensure that all parties that need to be fully informed are fully informed. The extent of the donation (whole globe or just cornea, transplant and research purposes) needs to be identified and recorded. The investigations about assessing medical risk or donor suitability must be conducted in a thorough and professional and considered manner that is relative to the risk being assessed. These responsibilities extend to those instances where workplace partners have been primarily involved in the consent and donor screening process (e.g., multiple tissue or organ donation); the eye donor coordinator must still cross-check and ensure that these processes have been suitably performed.

JAYPEE BROTHERS

Medical and Social History Review

It is important to review all available records on each donor to an extent to which it is possible to make an acceptable judgment on donor risk (in relation to donor contraindications and safety, and likely efficacy of the tissue for purpose). This should be performed by an individual(s) who is qualified by profession, education, or training to do so. Final review of the relevant donor history should also be undertaken by individuals (the medical director of the eye bank or their delegates) who are both familiar with the intended use of the tissue and deemed competent to undertake the review.

Depending on the circumstances and the location of the donor's death sources of information may include but not be limited to:

- Medical record or hospital chart
- Donor risk assessment interview
- Physical assessment of the donor to identify risk factors for potential infection with transmissible diseases, the extent of which is in keeping with the overall risk profile of the donor.
- Death certificate
- Coroner or pathologist's report on the physical assessment of death
- Treating physician or general practitioner interview/report.

In particular, the following details should be recorded:

- Data to unambiguously identify the donor (as a minimum, name of patient and date of birth).
- Cause of death and contributing factors
- Current and past medical history
- The time of irreversible cessation of the circulation of the blood—the important point here being a record of the beginning of the ischemic period for the corneas.
- In the instance of intended hypothermic storage of corneas, a review and interpretation of laboratory results (blood cultures, temperature trends, and white blood cell counts) must be performed to exclude or bacteremia or fungemia in the donor at the time of death. Discussion with the treating physician and gaining an insight into their clinical impressions is often critical in deciding on bacteremic status. However, bacteremia can be considered suitable if organ culture storage of corneas is performed where significant infection of corneal tissue will become evident as contamination in the storage medium.

When a formal donor risk assessment interview (DRAI) can be conducted, it should be with donor next of kin and/or most knowledgeable historian within the context of the donation. Its intent is to determine risks in the donor that may not be discovered through usual medical history pathways and processes described above. Formal interview templates developed by and standardized across organ, tissue and eye sectors are available for this purpose—The North American Uniform DRAI and its direct adaptation, the AUS-DRAI.[59] However, it is important to review such templates for the applicability to the region/nation in which the eye bank operates. Abbreviated versions of the DRAI when eye-only donation is undertaken are also used by the EBAA and EBAANZ member banks.

Communicable Disease Testing

As a minimum, the donor must be tested for the HIV, HBV, and hepatitis C virus. Depending on the jurisdiction and regulators, additional tests [e.g., syphilis and human T-lymphotropic virus (HTLV)] may be mandated. Best practice is now considered to be nucleic acid testing (NAT) for these viruses, validated for cadaveric blood (NAT testing decreases the "window" period from infection to detection of these viruses over serologic testing, thus reducing risk. It also allows for a reduction in deferral times for donors considered to be at higher epidemiological risk to these viruses). However, as for any pathology test there needs to be a consideration of efficiency, sensitivity, specificity, reliability, and of course availability. In many jurisdictions, *validated cadaveric* NAT testing is not readily available, and depending on the jurisdiction the risk reduction the NAT offers over serological testing is not significant.

In cases where *the donor has undergone significant blood loss,* or the donor is <12 years of age, *and* there has been significant transfusion/infusion of fluids, there exists a possibility that plasma dilution may affect the validity of any serology conducted postinfusion. In these instances, when reviewing the donor's history, it is important to record the amount and time of any transfusion or infusions (blood, colloid, and crystalloid). When no adequate pretransfusion/infusion sample is available for communicable disease testing (CDT), then a calculation should be used to determine that there has not been plasma dilution sufficient to affect test results. Examples of appropriate algorithms to follow (including relevant calculations) are available from Food and Drug Administration (FDA)[60] guidelines.

Eye Donation Surgery

As with all surgery, there are many different possible approaches to donor surgery and donor eye preparation/dissection and therefore this chapter will only deal with some of the salient points. The Procedures Manual of the Eye Bank Association of America does cover specific procedures written broadly enough to provide a framework for the development of an Eye Bank's own procedures, yet specific enough to establish accepted baseline standards.[61] In addition, an excellent introductory handbook and atlas has also been published which provides good illustrated step-by-step guides to eye bank surgical and evaluation techniques.[62]

JAYPEE BROTHERS

The person performing the donor surgery must use their professional judgment and satisfy themselves that all-reasonable steps and normal surgical precautions have been taken to minimize contamination or damage to the tissue. Ideally, the area should be one of restricted access as a first step toward aseptic technique, has appropriate lighting, sharps, and biohazard waste containers, and generally be clean and organized. Personnel must be trained in the procedures or in general surgical procedures. Importantly, retrieval personnel must be equipped and wear appropriate personal protective equipment (PPE).

Preparation of the Donor—Eye Decontamination

If an enucleation is to be performed many eye banks may forego extensive donor preparation opting instead to decontaminate the globe within the eye bank laboratory prior to the removal of the cornea. This is usually performed in the laboratory by rinsing the globe in a dilute povidone-iodine (PVP) solution (a 1–5% concentration resulting in 0.1–0.5% available iodine) for 1–2 minutes. The PVP solution must not contain any detergents as this could harm the corneal epithelium, and this should be checked beforehand. The PVP is then followed by a thorough rinse with a balanced saline solution. This is a very effective means of decontamination[63] if performed with appropriate concentrations of PVP over a short period.[64] The efficacy of the combined use of 0.02% chlorhexidine and 0.5% povidone-iodine has also been demonstrated while retaining corneal viability.[65]

Of great importance are more recent reports of an increasing trend in the rate of postkeratoplasty fungal infections and a reversal in the previously documented predominance of bacterial over fungal infections, with a disproportionate incidence of fungal infections after EK compared with PK.[66] It has been hypothesized that the additional time that lamellar tissue is exposed to warmer temperatures during tissue processing, results in prolonged exposure to a permissive environment for fungi to grow. In response the EBAA mandated double povidone-iodine soaks at the time of recovery to address contamination at an early stage of proliferation when the fungal population is most vulnerable. This, combined with reducing warming times that limits the fungi's subsequent growth, appears to have lowered risk with the EBAA reporting 2019 postkeratoplasty infection rates at their lowest in over a decade.[42]

For those eye banks that perform in situ excision of corneas, similar solutions can be used to minimize ocular flora and reduce contamination. This procedure is appropriate for donor preparation prior to both enucleation and excision. Here the delivery of the solutions is also important as the eyes should first be rinsed in a strong stream of balanced saline to remove all debris, mucus and foreign matter from the cornea and conjunctival sac. This alone will reduce microbial contamination. A strong vigorous stream may also play a role in the mechanical disruption of fungal biofilms, allowing for better removal of any fungal contaminants through mechanical means and through removal of the protective barrier to allow decontamination through PVP or chlorhexidine. A good stream of balanced saline is also required after a period of PVP application to ensure good removal of the PVP from the eye. The lids and the surrounding area can then be disinfected by a surgical skin preparation of PVP.

Enucleation, In Situ Excision and Corneoscleral Rim Sectioning

Enucleation or in situ excision can be performed in an operating theater, a morgue, hospital room or funeral home. Prime considerations are to minimize manipulation of tissues surrounding the eye to preserve donor appearance, to prevent touching or distortion of the cornea and thus minimize any cell loss (epithelial and endothelial), and to reduce bacterial contamination from both exogenous sources and from ocular flora. For in situ excision one must be especially aware of the bacteriologic considerations, as no further decontamination of the tissue is possible.

Corneoscleral rim excision after an enucleation is a similar process to the in situ excision. Ideally the procedure is performed in a biological safety cabinet which provides a clean area for the excision and at the same time protects the operator from exposure to possible pathogens residing on the eye itself. The dissection needs to be made through into and along the suprachoroidal space. Perforation of the choroid would cause vitreous leakage, which may cause the collapse of the globe and anterior chamber and compromise the cornea. In addition, the operator must be careful not to exert too much pressure on the globe, as this will increase the potential for the scissors to cut or catch on the choroid. During the procedure it is most important that as little stress as possible is placed on the cornea as any stretching of the endothelial cell layer can critically damage it.

Key Points—Donation of Eye Tissue

- Donor history gathering should be to an extent to which it is possible to make an acceptable judgment on donor risk.
- History gathering includes review of medical records/hospital chart, risk assessment interview with knowledgeable donor historian and physical assessment of the donor.
- As a minimum the donor must be tested for HIV, HBV, and HCV.
- In situ excision of corneas or enucleation of the whole globe provides equal outcomes but each has its own benefits and disadvantages (**Table 1**).
- Techniques in eye retrieval are available at www.cybersight.org/portfolio/introduction-to-eye-banking-a-handbook-and-atlas/
- Effective and careful eye decontamination through the use of PVP or equivalent solutions, and aseptic handling and processing are of great importance in mitigating the risk of fungal or bacterial transmission to the recipient.

JAYPEE BROTHERS

Table 1: Tissue retrieval considerations.

	In situ excision	*Enucleation*
Legal and regulatory	Tissue removal	Organ removal
Operative procedure	More difficult	
Staff	More training	
Time	Marginally longer	
Risk	Less invasive	Risk of hemorrhage
Postretrieval processing and time	Less	
Decontamination	At donor	At donor and repeated in laboratory
Eye bank facility	Not necessary	Laboratory
Contamination rate	Similar	Similar
Inspection anterior chamber	Pen light	Slit lamp
Tissue viability	Similar or better due to shorter death to preservation times	

CORNEAL EVALUATION

Except for tissue that would be potentially hazardous because of possible transmission of disease, there are no absolutely defined criteria for the acceptance or rejection of a cornea. The final decision regarding use rests with the surgeon for each individual and unique case of donor to recipient transplantation and the transplant procedure to be undertaken. However, in reaching a decision on acceptance or rejection of tissue for clinical use the ophthalmologist must rely on the eye bank's careful evaluation of the cornea and its classification of fitness for purpose for a specific procedure.

Good corneal evaluation by each corneal layer is now central in determining the fitness for purpose for a cornea. For PK, the cornea needs to be free of refractive corneal procedures (including photoablation surgery), superficial disorders of the conjunctiva (such as pterygia) that may affect the central optical zone, scars affecting the central optical zone, infiltrates (both infectious and noninfectious), and a good endothelium that passes the eye bank's standards. Donors for anterior lamellar keratoplasty procedures, tectonic grafts, and patch grafts such as for glaucoma drainage devices need to meet the same criteria as PK except that the state of the endothelium is not important. Conversely, donors for EK procedures noninfectious anterior pathology that does not affect the posterior stroma and endothelium is acceptable if the endothelial layer is acceptable.

Gross in situ Evaluation

Corneal evaluation begins with a gross examination of the corneas in situ. A simple penlight examination can reveal epithelial defects (drying, erosion, sloughing), corneal edema with associated haze and striations due to folding of Descemet's membrane, abnormal corneal shape, blood or cloudiness in the anterior chamber, corneal scars or infiltrates, arcus senilis, and any signs of conjunctivitis and discharge.

For in situ corneoscleral rim excisions a careful in situ examination is especially important. This is the only opportunity (other than a good medical history) to determine if there has been previous anterior segment surgery or if there is any pathology of the eye not identified through the donor screening process.

Slit-lamp Evaluation

The slit lamp enables a more accurate observation of the cornea, revealing earlier stages of pathology that are visible grossly. Whole eyes can be examined by the slit lamp within the container used in retrieval, or excised corneas can be examined through the bottom of the storage vial once the cornea and vial are manipulated so that the cornea is endothelial side down. The eye or cornea should be allowed to reach room temperature which makes the endothelium easier to visualize and more normal in appearance.

The cornea should be methodically examined to ensure each layer of the cornea is adequately assessed. The surrounding limbal/scleral area should also be checked for evidence of surgical incisions (these may also be at the periphery of the clear cornea) and for any sutures.

The epithelium is inspected for integrity and overall condition specifically clarity, exposure, sloughing, defects, trauma, foreign bodies, and infiltrates. Haze is often localized and coincides with ante- and postmortem exposure across the interpalpebral area. Swelling of the epithelium may cause some layers to detach (termed sloughing). Epithelial defects appear as clear depressed areas within an otherwise hazy epithelium. The extent and position (central or peripheral) of any of these findings needs to be considered in any assessment of the suitability of the cornea for transplantation.

The stroma is examined for overall clarity, amount of edema, and stromal folding. Major opacities are usually detected by the preceding gross examination but using higher magnification and a thin slit can better identify the

JAYPEE BROTHERS

opacity as scarring (generally a smooth gray appearance) or inflammatory infiltrates (generally whitish appearance with discrete borders). Stromal folding and haze are associated with corneal edema. The amount of corneal edema, and thus the severity and number of folds and the amount of haze will depend on time since donor death, temperature, integrity of the epithelium, and the postmortem integrity and function of the endothelium. The thickest folds are a good indicator of the overall severity of the edema. Striae, identifiable as fine gray/white lines, may also be in the stroma and are probably indicative of very localized disruptions of the stromal lamellae.

Any detachment of Descemet's membrane can be observed as a separate membrane that seems to come from and be continuous with the endothelial side of the cornea. This finding alone is usually enough to consider the cornea unsuitable for any transplantation procedure requiring an intact endothelium.

A specular reflection of endothelial layer can be observed in a small area of the endothelial reflex. At high power magnification an impression of cell density and the degree of cell uniformity in size and shape can be obtained. Guttae-like bodies (areas where no cells can be seen) may be observed in the specular reflection. The exact nature of these areas is difficult to determine. They may be guttae (bumps or excrescences of Descemet's membrane), vacuolated cells, or stress fractures (sometimes referred to as pseudoguttae) due to trauma during the donation process. Regardless of their nature these conditions should be regarded as a degenerative condition of the endothelium. The suitability of the cornea for PK would depend on the relative number and location of these bodies. (*Note*: the term "pseudoguttae" is sometimes also used to refer to guttae that appear at hypothermic storage temperatures but disappear at room temperature).

Anterior Chamber Optical Coherence Tomography

Anterior segment optical coherence tomography (AS-OCT) (adapted for eye bank use) is now being used for characterizing and evaluating donor tissues. Primarily, it was introduced for the examination of precut DSAEK tissue with advantages of improved accuracy when compared to ultrasound pachymetry measurements of thickness with the added benefit of providing a thickness profile of the whole cut posterior lenticule.[67] It is now also finding use supporting the slit-lamp examination in characterizing and measuring depth stromal opacities or lesions which is important in determining if the cornea can still be used for EK.[68] Some banks are also routinely using OCT to assist in the detection of unreported corneal ectasias or refractive surgery in donor tissue.[69]

Endothelial Microscopy

The condition of the corneal endothelium is central to evaluating the suitability of corneal tissue for both PK and EK, as it is primarily the layer responsible for the maintenance of corneal turgor and transparency. Endothelial microscopy, whether it is through the technique of specular microscopy or transmitted light/phase microscopy, allows for a reasonable determination of ECD, cell pleomorphism and polymegathism, and the identification of corneal guttae. These changes reflect the current well-being of the endothelium as well as being indicative of its functional reserve.[70]

Such objective information and has allowed the wide use of older corneal tissue based on endothelial appearance rather than arbitrarily excluding such tissue solely based on donor age (see section on donor age). In addition, endothelial microscopy has allowed for the use of corneas from donors that have had anterior segment surgery. In both cases, if the corneas have passed the endothelial microscopy criteria and slit-lamp criteria, they should be considered for penetrating or EK (with the receiving ophthalmologist being fully informed).

A low cell density may indicate that the cornea is unlikely to be able to withstand the rigors of transplantation. Bourne and O'Fallon[71] elegantly showed that there was a loss of 23% of the transplanted endothelial cells within the first week of transplantation and others have demonstrated that this cell loss may continue for up to at least 4 years.[44] The critical ECD below which any cornea undergoes decompensation is speculative although many clinicians estimate it to be 300–500 cell/mm^2. Based on the evidence of cell loss in the postoperative period and the estimated lower limit of a functional cell density, eye banks generally have a cutoff of between 1,500 and 2,200 cells/mm^2 (depending on the bank) below which they will no longer issue a cornea for penetrating or EK. In these instances, the cornea may still be suitable for anterior lamellar keratoplasty.

In addition to a low cell density an abnormal endothelial appearance may indicate that the cornea is compromised or functionally deficient. Corneas with considerable polymegathism or pleomorphism have been reported to have a decreased functional reserve[72] and an increased incidence of postoperative decompensation.[73] Corneal guttae have also been reported to reduce endothelial function.[74,75] Inflammatory cells and bacteria can also be easily seen with endothelial microscopy and their presence would lead to the exclusion of such corneas for transplantation.

Specular Microscopy

Specular microscopy is mostly used by those eye banks using hypothermic storage of corneoscleral buttons. A limitation with specular microscopy is that the area of the central corneal endothelium is much larger than can be sampled by the specular microscope even with multiple field examinations. Therefore, the information gained from specular microscopy should be interpreted within the context of the slit-lamp evaluation.

JAYPEE BROTHERS

For the best observation of the corneal endothelium, the cornea must be at room temperature. Thus, the most convenient time to perform specular microscopy is after the placement of the cornea in storage media, allowing sufficient time for the media to equilibrate with room temperature and for deturgescence of the cornea. Corneas can also be observed after a period of 4°C storage and subsequent warming to room temperature. The cycle of cooling, warming and recooling of a donor cornea has been shown to have no adverse effects on the metabolic or morphometric status of the donor cornea.[76] However, it becomes more difficult to adequately visualize the endothelium with specular microscopy after a period of storage. The Corneal Donor Study Group has demonstrated that the accuracy and interpretation of ECD measurements are directly related to factors that may affect image quality, and that variability in both endothelial image quality and ECD exists with multiple eye banks and readers. Because of this variability eye banks should standardize their approach ECD determination, set internal standards on ECD density, and consider that fair images are more likely to have a larger margin of error in determining ECDs. Thus, eye banks should provide a margin of safety when the cell count nears the lower limit established by the eye bank.[77]

Light Microscopy

Eye banks using normothermic (organ culture) storage methods use phase contrast microscopy and/or transmitted light microscopy often accompanied by intravital staining of the endothelial layer. This type of endothelial microscopy has the advantages of being able to assess the endothelium after storage and close to the time of transplantation and enables visualization of a larger area of the central cornea compared to specular microscopy. Intravital staining, usually with trypan blue, also provides some information on number of endothelial cells still functioning. Sucrose or balanced salt solutions are often added which cause the intracellular space to swell, making the cell borders easier to discern for ease of cell counting. The original technique is described by Sperling.[78] Such techniques can also be applied to corneas that are hypothermically stored.

Key Points—Corneal Evaluation

- In reaching a decision on acceptance or rejection of tissue for clinical use, the ophthalmologist must rely on the eye bank's careful evaluation of each layer of the cornea.
- Slit-lamp examination can provide information on the depth, width, and position of large to small abnormalities as well as pinpointing the depth of the pathology.
- AS-OCT is being used as an adjunct to slit lamp, and in screening for ectasias, and refractive surgery. Its use in examination of precut lamellae for DSAEK is well established.
- Specular microscopy and/or light microscopy is central to evaluating the suitability of the endothelium for PK and EK surgery.
- Accuracy of ECD is dependent on good image quality. Eye banks should set internal standards on ECD measurement and use cutoff limits as benchmarks not standards.

STORAGE

Unlike tissues such as bone or heart valves that may be extensively processed and altered from their natural state, corneas must be transplanted as a viable living tissue. Thus, the aim of all corneal storage techniques is simply to maintain this living viable state while holding the cornea for the period between donation and transplantation. This is the same aim as for solid organ transplantation such as kidney transplantation. However, while reliable kidney preservation time is still restricted to around 24 hours ischemic time, techniques developed over the past 30 years have enabled the extension of reliable corneal storage times to approximately 1 month.

Hypothermic Corneal Storage

McCarey and Kaufman modified an existing tissue culture medium, TC 199, by adding dextran as an osmotic agent to compensate for the inactivity of the cornea's normal water removal mechanism at 4°C. This extended reliable storage time is 2–3 days at 4°C and the media, MK medium, quickly became the storage system of choice for eye banks. Over the years the MK formulation has been improved by the addition of the more stable HEPES buffer and the replacement of the penicillin-streptomycin antibiotics to gentamicin which has a greater spectrum against gram-negative bacteria.[79] It remains a cheap, easy, simple and reliable form of corneal preservation.

In the mid-80s 2.5% chondroitin sulfate began being added to existing tissue culture media formulations which successfully extended corneoscleral storage times to 7–10 days. This was further modified by the addition of dextran which overcame the problem of the cornea absorbing smaller molecular weight moieties (such as chondroitin sulfate) which otherwise caused the osmotic flow of water into the cornea causing it to swell. Optisol, the widest available storage medium, is based on these formulation and actions,[80] as are other commercially available hypothermic solutions.

While the original publications suggested that Optisol was suitable for up to 14 days storage, in practice the maximum storage time most ophthalmologists feel happy with is 7–10 days with storage between 2° and 6°C. There is also data that shows Optisol is also able to preserve endothelial morphologic characteristics at 26°C for limited periods. While not recommended for storage, enhanced viability for short periods at room temperature provides a margin of safety when cold storage cannot be maintained.[81]

Commercially available hypothermic corneal storage solutions are supplemented with antibiotics (often gentamicin and streptomycin) to give broad antimicrobial coverage.[82] Concerns surrounding increasing trends in the rate of postkeratoplasty fungal infections[66] have seen renewed interest in the addition of antifungals, either by manufacturers[83] or by eye banks themselves[42,84] upon the

JAYPEE BROTHERS

direction of the transplanting ophthalmologist. However, the efficacy, safety, science, and cost-effectiveness of various supplementation regimes have been questioned.[42] There is preliminary data on the safety and efficacy of antifungal supplementation, but many questions remain unanswered, and many argue that larger scale validation studies must be done before for changing current standard procedures.[84] Improved eye decontamination protocols appear to have a greater role in reducing postkeratoplasty fungal infections.

Organ Culture (Normothermic) Storage

Organ-cultured corneas are incubated in nutrient medium at physiological temperature. They retain active cell metabolism and corneas stored in this way can be reliably preserved for up to 30 days. Organ culture storage has not been adopted in North America but has become the preferred storage method in the UK,[85] Europe,[86-88] New Zealand,[89] and Australia.[90] It has several advantages over hypothermic storage including fewer positive rim cultures[88] and its association with postkeratoplasty infection rates, and the expansion of the potential donor pool[90] (due to acceptance of bacteremic donors and extended death to recovery and preservation times).

In the most common method, excised corneoscleral disks from decontaminated eyes are suspended in glass bottles containing 100 mL of MEM medium with Earle's salts supplemented with 2–5% fetal bovine serum, L-glutamine and the antimicrobial agents penicillin, streptomycin, and amphotericin. Culture bottles are closed and incubated in a dry (non-CO_2) environment at a temperature between 28 and 37°C.[88] Many studies have shown that corneal ultrastructure, endothelial cell morphology, density and viability are well-maintained in organ-cultured corneas up to 48 days of storage[91,92] although in practice most are distributed between 10 and 28 days (average 16 days).[93]

Tissue swells during the culture period, becoming thickened and edematous (from 0.5 to 1 mm), but this is reversed during a period of days in dextran-containing thinning medium prior to distribution.[94] Various studies have confirmed that there is a dramatically lower incidence of endothelial cell death compared to cold-stored corneas and that despite 10–15% endothelial loss during culture, the endothelium is able to eliminate dying cells and repair itself.[95] The surface epithelial layers shed into the medium during increasing time in culture, which are quickly replaced by host cells postoperatively,[91] however, fresher tissue may be indicated for recipients with preoperative persistent epithelial defects.

Organ culture provides an inbuilt microbiological surveillance system, since any culture containing microorganisms not controlled by decontamination and antibiotics will become contaminated, and the cornea not used for transplant.[96] One study showed that 98.9% of corneoscleral rims are sterile after organ culture.[97] Contamination in culture is normally visually obvious by turbidity and pH change, however, corneal cultures are quarantined until a sample of the medium taken at 3–7 days of storage is tested and reported to show no growth of bacteria or fungi. Reported bacterial isolates are most commonly ocular flora such as *Staphylococcus* species,[96,98,99] while fungal growth most commonly is *Candida* species. Strikingly, in recent studies, *Candida* has become the most common contaminant seen in during organ culture.[96] This may reflect the changing epidemiological landscape of nosocomial fungal infections.[100] Notably, contamination during organ culture related directly to systemic infection in the donor is rare, and so with this method the donor pool can be expanded to include those with bacterial septicemia, a common reason for donor exclusion when hypothermic storage is performed.

After the incubation period, corneas cleared for serology and microbiology are evaluated by direct light microscopy of the endothelium before being transferred into thinning/transport medium containing 5% dextran prior to transplantation. Prolonged presence of dextran in culture is thought to be toxic to the cornea, therefore, the maximum recommended time in thinning medium is 2–4 days.[101,102] Since endothelial evaluation is performed at the end of the storage period near to transplantation, the quality and likely efficacy of the tissue can be determined with greater assurance. This allows for reliable use of corneas from older donors and extended death-to-preservation time, with no significant impact on graft survival when compared with younger or fresher tissue.

Compared to hypothermic storage, the organ culture technique is more complex, requiring additional equipment, testing, and greater technical expertise. Although the set-up and testing costs can make it a more expensive method, efficiency benefits can be gained by increased certainty of cornea provision and elimination of potentially unsafe tissue. It is a method best suited to an established eye bank with skilled technical staff, and where donor rates are variable, or distribution is required over wide geographical area. In addition to improved microbiological screening, the increased storage time allows the ability to provide ABO- or HLA-matched corneas for patients with high risk of rejection, and for optimizing allocation of corneas to specific patients. It more easily enables the operation of fully-scheduled transplant booking systems,[90] rather than those organized at short notice, and enables transport over long distances without the need for refrigerated conditions.

Key Points—Corneal Storage

- The benefits and disadvantages of hypothermic and organ culture storage are listed in **Table 2**.
- Both systems are equivalent in graft outcomes.
- Corneas for PK and EK must be transplanted as a viable living tissue and in this respect, corneas have more in common with organ transplantation than other tissue transplantation.

JAYPEE BROTHERS

Table 2: Storage procedures for the corneoscleral disk.

	Hypothermic	*Organ culture*
Technique	Simple and fast	More complex
Storage time	Up to 14 days	Up to 4–7 weeks
Tissue available immediately	Yes	No
Maintenance of hydration/thickness	Yes	No
		Second step reversal of swelling necessary
Epithelial and endothelial wound healing	No	Yes
	Stricter concerning donor supply	More tolerant for donor conditions affecting endothelial viability, e.g., time and temperature
Endothelial evaluation	Beginning of storage	End of storage
	Noninvasive specular microscopy	Invasive light microscopy with viability assay
	Small central area	Entire surface
Graft survival	Similar	
Microbiological tests	Not required	Mandatory
		Quarantine period
Bacteremic donors	No	Acceptable
Risk of postoperative endophthalmitis	0.1–2%	0–0.1%

EYE BANK PROCESSING FOR DESCEMET'S STRIPPING AUTOMATED ENDOTHELIAL KERATOPLASTY AND DESCEMET'S MEMBRANE ENDOTHELIAL KERATOPLASTY

The emergence of DSAEK and DMEK presents new opportunities for eye banking in the preparation of donor tissue. In addition, eye banks needed to revise their acceptance criteria for eye donation and the analysis of possible anterior or posterior corneal pathologies regarding specific transplant procedures.

Precut Descemet's Stripping Automated Endothelial Keratoplasty

Studies continue to demonstrate safety and efficacy of tissue prepared, cut, and processed by technicians compared to surgeons[103-105] and some studies indicate lower rates of postoperative infections for eye bank prepared tissue.[41] Additionally, DSAEK tissue prepared by the eye bank can save between 13 and 21 minutes per procedure leading to immense cost savings.[103]

Several studies have investigated the influence of donor factors on DSAEK outcome for both organ-cultured and hypothermically preserved corneas. Donor age and preoperative endothelial cell count were found to have no correlation with graft survival.[52,106-108] Interestingly, tissue from donors with diabetes were associated with increased risk for primary or early failure but the reasons for this remain unclear.[108]

Based on a hypothesis that thicker grafts impair best-corrected visual acuity after DSAEK, some corneal surgeons request thinner grafts from eye banks or prepare "ultrathin" corneal grafts, which, in some cases, can increase the cost of care or result in donor wastage. However, a 2016 systematic review and meta-analysis[109] examining the effect of DSAEK graft thickness on visual acuity agreed with Terry and associates[110] that "graft thickness may have a small effect on visual outcomes in the extremes of thickness, but not in the common range of 100–200 μm" and that "donor thickness has a tenuous relationship with visual outcomes". Nevertheless, with time, eye banks have pursued cutting thinner and thinner DSAEK preparations as surgeons have gained experience with the transplant procedure, and preparations <100 μm are now routine.

Interestingly, for hypothermically stored corneas, a large multicenter trial has now shown that thicker prelamellar-dissection donor tissue is associated with a higher graft dislocation rate. The risk was three times higher for tissues >600 μm compared with tissues ≤ 600 μm,[111] however, the thicker tissue (for hypothermically stored tissue) could simply be a marker for reduced endothelial function before dissection rather than an inherent issue with deep dissections.

Prestripped and Preloaded Descemet's Membrane Endothelial Keratoplasty

The challenge of preparing the delicate donor graft material for DMEK has been reported by individual surgeons as a key barrier in the uptake of DMEK surgery. It has been noted that the manual preparation of the donor tissue is difficult and incurs increased risks, including donor tissue loss, associated financial loss, and cancellation of the surgery.[112,113] Conversely, a facilitator of DMEK uptake has been the preparation of the graft undertaken by the eye

JAYPEE BROTHERS

for detailed information on ophthalmology books, visit our website www.Jaypeebrothers.com, for detailed information on ophthalmology books, visit our website www.Jay

CORNEAL TRANSPLANTATION

Corneal Transplantation is a practical guide, designed primarily to help corneal surgeons with varying levels of expertise attain a clear understanding of facts related to different techniques of corneal transplantation. Chapters pertaining to specific surgical techniques have been addressed by surgeons who are experts in their specific field. Every possible effort has been made in order to keep the content crisp and clear so as to make it reproducible by the novice surgeons. The current edition of the book is an amalgamation of the surgical techniques which are age old yet our saviors as well as the most recent innovations.



Namrata Sharma MD FRCOphth FRCSEd is a Professor of Ophthalmology (Cataract, Cornea and Refractive Surgery Services) at Dr Rajendra Prasad Centre for Ophthalmic Sciences, All India Institute of Medical Sciences, New Delhi, India. She did her fellowship in Ocular Inflammatory Diseases and Lamellar Keratoplasty Surgeries from the Moorfields Eye Hospital, London, UK. With 2 patents to her credit (Natamycin and Natamatrix), she has been awarded at several national as well as international occasions for her research works. She has published more than 555 publications in various national and international peer-reviewed journals and has authored 119 book chapters and 17 books. Her ongoing research is focused on the effect of collagen crosslinking in cases of infectious keratitis and the use of newer biosynthetic corneas as an alternative to human donor corneas. She was honored as one of the 100 most influential female ophthalmologists in the world in the "2021 Ophthalmologist Power List". She can be reached at *namrata.sharma@gmail.com*.



Ritu Nagpal MD FLVPEI (Cornea) is a Senior Research Associate in the Department of Ophthalmology at All India Institute of Medical Sciences (AIIMS), New Delhi, India. She completed her postgraduation in Ophthalmology from the prestigious Dr Rajendra Prasad Centre for Ophthalmic Sciences at AIIMS, New Delhi, following which she underwent a two-year Intensive Cornea and Anterior Segment Fellowship at the renowned LV Prasad Eye Institute at Hyderabad, Telangana. In order to carry forward with her learning, she had attained during the fellowship, and her love and passion for an academic career she joined back her parent institute as a Research Associate. Being fortunate enough to be trained and worked at two of the best places of Ophthalmology in India for the past 11 years, she is well-equipped in managing various corneal and ocular surface pathologies and in performing refractive procedures. She believes in principles of delivering good quality patient care and practices perfectionism in every part of her work. She can be reached at *doc.ritunagpal@gmail.com*.



Rasik B Vajpayee MS FRCSEd FRANZCO is a Professor at the University of Melbourne and Consultant at the Royal Victorian Eye and Ear Hospital. He has earlier served as the Professor and Head of Cataract, Cornea and Refractive Surgery Services at Dr Rajendra Prasad Centre for Ophthalmic Sciences, All India Institute of Medical Sciences, New Delhi, India and as the Professor and Head of the Surgical Division, Ophthalmology at the University of Melbourne, Australia. He is a clinician-scientist working mainly in the field of Cataract, Cornea, Ocular Surface Diseases and Refractive Surgery. His track record demonstrates a consistent and continuous effort to optimize management of complex cataracts and corneal diseases and improve outcomes of cataract and corneal transplantation surgery through clinical research. He has significant expertise in the management of various corneal conditions, complex cataract cases and keratorefractive procedures with numerous innovations to his credit. He was the first to pioneer the use of a single-donor corneal tissue to treat multiple patients, by using novel techniques of customized component corneal transplantation surgeries. His innovations in the field of corneal transplantation surgery have won "Best of Show Award" at the annual meetings of American Academy of Ophthalmology in 2003, 2004, 2006, 2008, and 2009. Some of these techniques also won best surgical technique awards at annual APACRS, ESCRS and RANZCO meetings. Having published more than 400 national and international publications, he is the author of 13 books with one of these being a best seller and 2 are translated into Spanish and Chinese languages. The American Academy of Ophthalmology has honored him with an Achievement Award in 2005 and with Senior Achievement Award in 2012. He can be reached at *rasikv@unimelb.edu.au*.

Printed in India

Available at all medical bookstores or buy online at www.jaypeebrothers.com

JAYPEE BROTHERS
Medical Publishers (P) Ltd.
EMCA House, 23/23-B, Ansari Road,
Daryaganj, New Delhi - 110 002, INDIA
www.jaypeebrothers.com

Join us on facebook.com/JaypeeMedicalPublishers

Shelving Recommendation
OPHTHALMOLOGY

ISBN 978-93-89587-22-7

9 789389 587227