pee.com, for detailed information on cardiology books, visit our website www.ejaypee.com, for detailed information on cardiology books,

Learn ECG in a Day

A Systematic Approach



Sajjan Madappady

2nd Edition

JAYPEE

Contents

1. **History of ECG** 1

2. **Physiology of Conduction System of Heart** 3
   Rates of Pacemakers 4
   Normal Spread of Electrical Activity in the Heart 4
   Clinical Significance 5

3. **Basics of ECG** 6
   Electrocardiography 6

4. **ECG Leads** 8

5. **Placement of Leads** 11

6. **Normal ECG Morphology** 13
   Normal ECG Pattern 15
      How to Name the QRS Complex? 15
   Normal R Wave Progression in Chest Leads 15

7. **Systematic Interpretation of ECG** 18
   Systematic Interpretation Guidelines for Electrocardiogram 18
      Look for Standardization and Lead aVR 19
      Rate 19
      Rhythm 20
      Axis 20
      P Wave Morphology 21
      P Mitrale or Left Atrial Enlargement 22
      P Pulmonale or Right Atrial Enlargement (Fig. 12 and Table 2) 23
      Inverted P Wave 24
      Intra-atrial Conduction Delay (IACD) (Fig. 13) 24
      P-R Interval 25
      Second Degree AV Block 26
      Mobitz Type II Block (Fig. 17) 26
      Third Degree AV Block (Fig. 18) 26
      QRS Wave Morphology 27
      Concepts Behind Zones of MI 27
      Non ST-elevation Myocardial Infarction (NSTEMI) (Fig. 26) 33
   Nice to Know 33
      Detection of Culprit Coronary Vessel 38
   Hypertrophy 39
   Left Ventricular Hypertrophy (Fig. 37) 39
   Strain Pattern 40

Left Ventricular Strain Pattern (Fig. 38) 40
Right Ventricular Hypertrophy (Fig. 39) 41
Right Ventricular Strain Pattern (Fig. 40) 41
Bundle Branch Block 42
Right Bundle Branch Block (Figs. 41 and 42) 42
Left Bundle Branch Block (Fig. 46) 45
Nice to Know 47
Criteria for Diagnosis 47

8. Arrhythmias..... 49
Disorders of Impulse Formation 49
Disorders of Impulse Conduction 49
Premature Beats/Ectopic Beats/Extrasystole 50
Supraventricular Premature Beat/Extrasystol 51
Ventricular Premature Beat/Ventricular Extrasystole 52
Nodal Rhythm or Junctional Rhythm 54
Sinoatrial Node Block 55
Sinus Pause 55
Abnormalities of Rhythm 57
Sinus Arrhythmia 57
Sinus Bradycardia (Fig. 17) 58
Sinus Tachycardia (Fig. 18) 59
Atrial Rhythms 59
Paroxysmal Supraventricular Tachycardia (PSVT) 60
Pathology 60
Atrial Fibrillation (Fig. 23) 62
Atrial Flutter (Fig. 25) 64
Nice to Know 65
Ventricular Rhythms 65
Ventricular Tachycardia (Figs. 27 and 28) 65
Torsades De Pointes (Fig. 29) 66
Ventricular Fibrillation (Fig. 30) 67
Idioventricular Rhythm (Fig. 31) 68
Wolff–Parkinson–White (WPW) Syndrome 68

9. Systematic Interpretation of Arrhythmias 71

10. Pediatric ECG Interpretation and Congenital Anomaly Detection 72
Introduction 72
Standard Initial Evaluation 72
Important Steps for Diagnosis of Congenital Heart Diseases 73
Acyanotic Congenital Heart Disease 74
Atrial Septal Defect 74
Partial AV Canal Defect (Primum Atrial Septal Defect) 74
Moderate Ventricular Septal Defect 75

Large Ventricular Septal Defect 75
Common Complete AV Canal Defect 76
Obstructive Acyanotic Heart Disease 76
Pulmonary Stenosis 76
Aortic Stenosis 77
Anomalous Left Coronary Artery from Pulmonary Artery 77
Cyanotic Congenital Heart Disease 77
Tetralogy of Fallot 77
Transposition of Great Vessels 78
Cyanotic Child with Heart Failure 78
Total Anomalous Pulmonary Venous Connection 78
Truncus Arteriosus 79
Tricuspid Atresia 79
Summary 80

11. Differential Diagnosis 81
P Wave 81
P-R Interval 82
Q Wave 82
R Wave 82
QRS Complex 83
ST Segment 83
T Wave 84
U Wave 84
Q-T Interval 84

Bibliography 87

Index 89

4 CHAPTER

ECG Leads

There are twelve leads consisting of six limb leads (I, II, III, aVR, aVL and aVF) and six chest leads (V_1–V_6). The limb leads consists of standard bipolar (I, II and III) and augmented (aVR, aVL and aVF) leads. The bipolar leads were so named because they record the difference in electrical voltage between two extremities (**Fig. 1** and **Flowchart 1**, **Figs. 2** and **3**, **Table 1**, and **Fig. 4**).

For example:

Lead I: Records the difference in voltage between the left arm and the right arm electrodes.

Lead II: The difference in voltage between the left leg and the right arm electrodes.

Lead III: The difference in voltage between the left leg and the left arm electrodes.

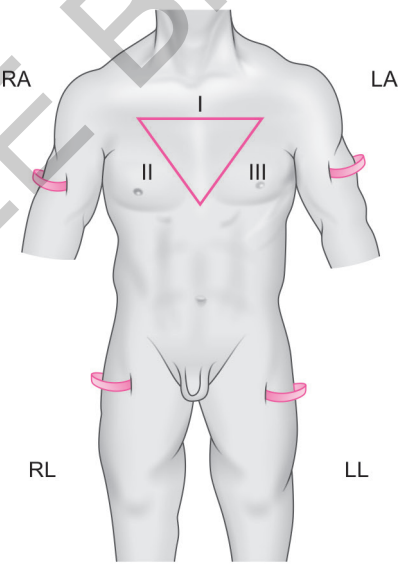

FIG. 1: Leads.

"Success means having the courage, the determination, and the will to become the person you believe you were meant to be." —George Sheehan

JAYPEE BROTHERS

In augmented limb leads, the abbreviation 'a' refers to augmented; V to voltage; R, L and F to right arm, left arm and left foot (leg) respectively. They record the electrical voltage of corresponding extremity.

FLOWCHART 1: Leads.

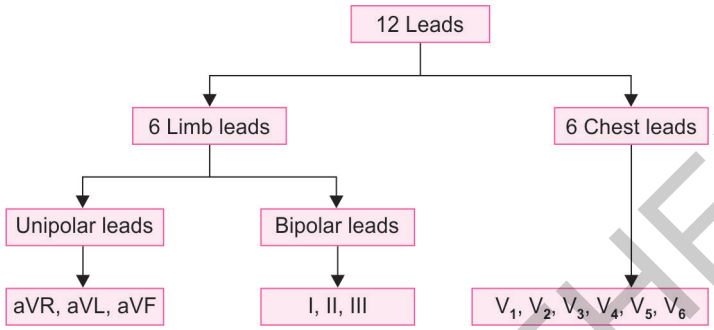

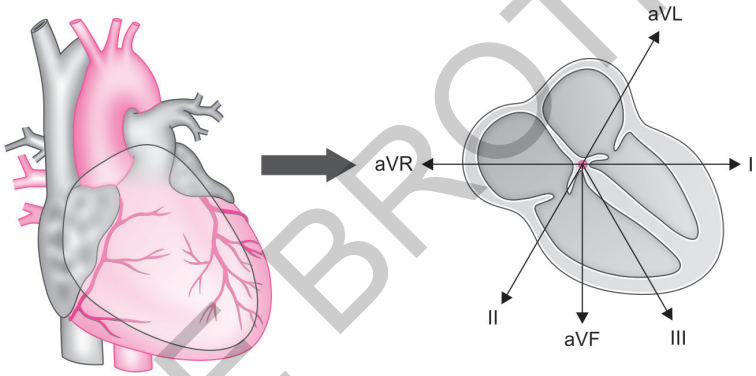

FIG. 2: Limb leads are placed in such a way that they bisect the heart at the center in the coronal plane.

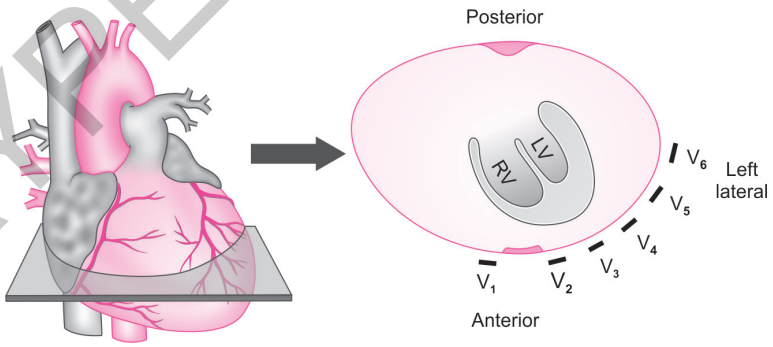

FIG. 3: Chest leads are placed in such a way that they bisect the heart in the horizontal plane.

"Failure comes only when we forget our ideals and objectives and principles."
—Jawaharlal Nehru

JAYPEE BROTHERS

TABLE 1: Relationship of 12 Leads to heart.

V_1–V_2	Septal wall
V_3–V_4	Anterior wall
I, aVL ,V_5–V_6	Lateral wall
II, III, aVF	Inferior wall

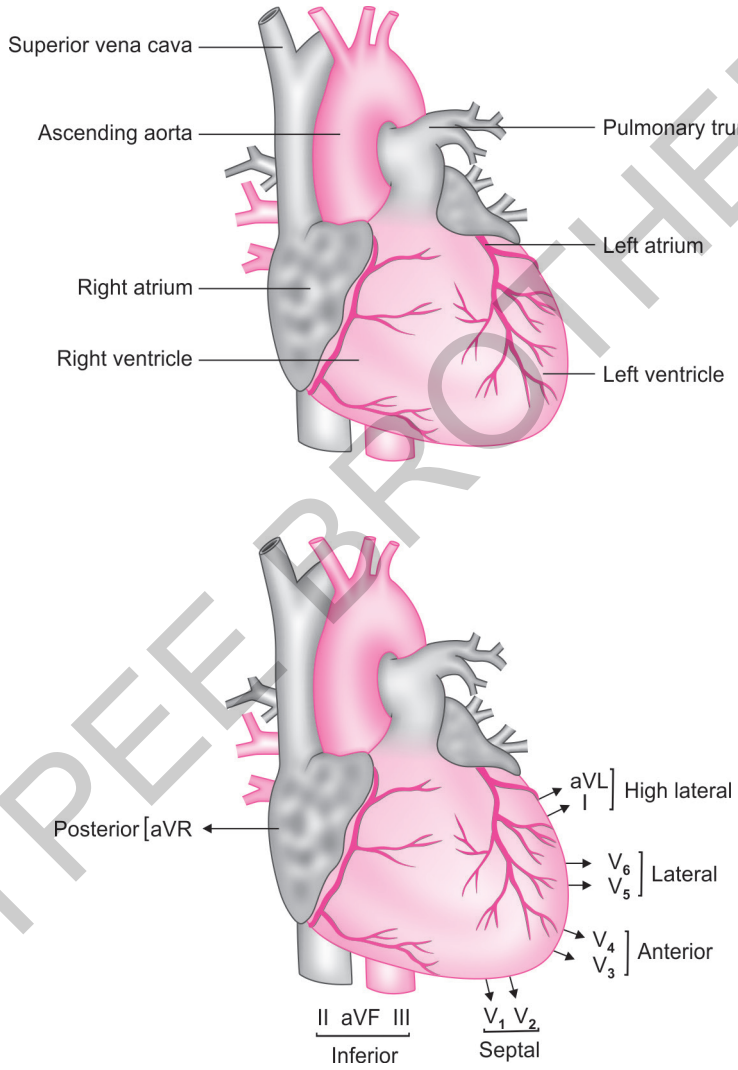

FIG. 4: Relationship of 12 Leads to heart.

"Take time to deliberate, but when the time for action has arrived, stop thinking and go in."
—Napoleon Bonaparte

JAYPEE BROTHERS

or detailed information on cardiology books, visit our website www.ejaypee.com, for detailed information on cardiology books, visit our we

Learn ECG in a Day
A Systematic Approach

Salient Features

- A systematic approach toward interpretation of ECG, i.e. where to start from and how to go through the ECG strip without missing a finding practically when a medico is faced with an ECG strip
- Three-dimensional concepts of ECG
- More than 100 line diagrams for better understanding of the concepts
- Useful to medical students, house surgeons, initial years of postgraduate students, paramedics, nursing students, and anyone in a clinical setting with the day-to-day practice who would like to brush up his ECG interpretation skills
- Elimination of unwanted details carefully without compromising the clarity of expression, making interpretation of ECG friendly
- Specialty introduced pediatric ECG interpretation and congenital anomaly detection
- Contents are arranged as for the convenience of the reader under the headings as—criteria, concept, cause, and clinical features which make it easy to recall
- Language is simple and lucid.

Sajjan Madappady is an author, motivator, creative artist, and healthcare entrepreneur who has been invited as a speaker for many national and international healthcare conferences and programs. He has been an integral part of the medical fraternity for the past 12 years. He has dared to push the boundaries of what is possible, in order to innovate and transform healthcare to make it an affordable basic human right. His transformation of ideas and thoughts has laid the foundation for the company Dynamic Medicare Pvt. Ltd. (www.DynamicMedicare.com), to assist patients in the healthcare process globally. He has pioneered in the field of medical tourism.

He completed his graduation and postgraduation from AJ Institute of Medical Sciences, Mangalore, Karnataka, India. He is the founder and President of Dynamic Education Trust, Mangalore, Karnataka, India. His incisiveness, inventiveness, creativity, and originality coupled with his broad knowledge of clinical medicine, never-ending thirst and enthusiasm for learning and teaching ECG have led to the publishing of this book. He has been training students and doctors on ECG at various institutions internationally and has been successfully able to enhance the interest of medicos by his innovative three-dimensional concepts of ECG (www.drsajjan.com).

Shelving Recommendations
CARDIOLOGY,
GENERAL MEDICINE

ISBN 978-93-89587-26-5

Buy from ejaypee

JAYPEE BROTHERS