ormation on endocrinology books, visit our website www.jaypeebrothers.com, for detailed information on endocrinology books, visit our website www.jaypeebrothers.com

SECOND EDITION

Clinical Atlas in ENDOCRINOLOGY & DIABETES

A Case-based Compendium



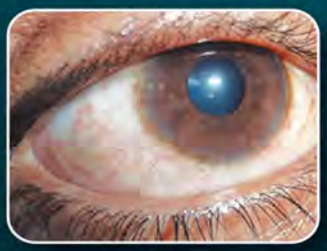
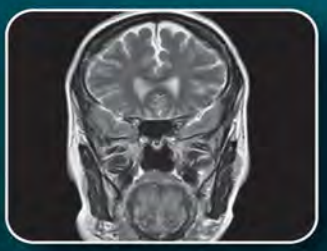

Nihal Thomas • Felix Jebasingh K
Mathews E Kurian

NOT TO BE MINISTERED UNTO BUT TO MINISTER
CHRISTIAN MEDICAL COLLEGE
VELLORE
INDIA

Foreword
Ashley Grossman

JAYPEE

Contents

CHAPTER 1	**THE TERRIFIC THYROID** Thyroid Gland and Related Disease	1
CHAPTER 2	**DIABOLICAL DIABETES** Diabetes Mellitus	71
CHAPTER 3	**AGGRESSIVE ADRENAL** Disorders of the Adrenal Gland	151
CHAPTER 4	**PITUITARY PASSIONS** Pituitary, Hypothalamus, and Pineal Gland	229
CHAPTER 5	**BOUNTIFUL BONE** Bone and Parathyroid Disease	313
CHAPTER 6	**REMINISCENCES IN REPRODUCTION** Disorders of Sexual Differentiation	395
CHAPTER 7	**MISCELLANEOUS MASQUERADES** Miscellaneous Disorders: Growth and Other Metabolic Disorders	429
	INDEX	495

Chapter 3

Aggressive Adrenal

Disorders of the Adrenal Gland

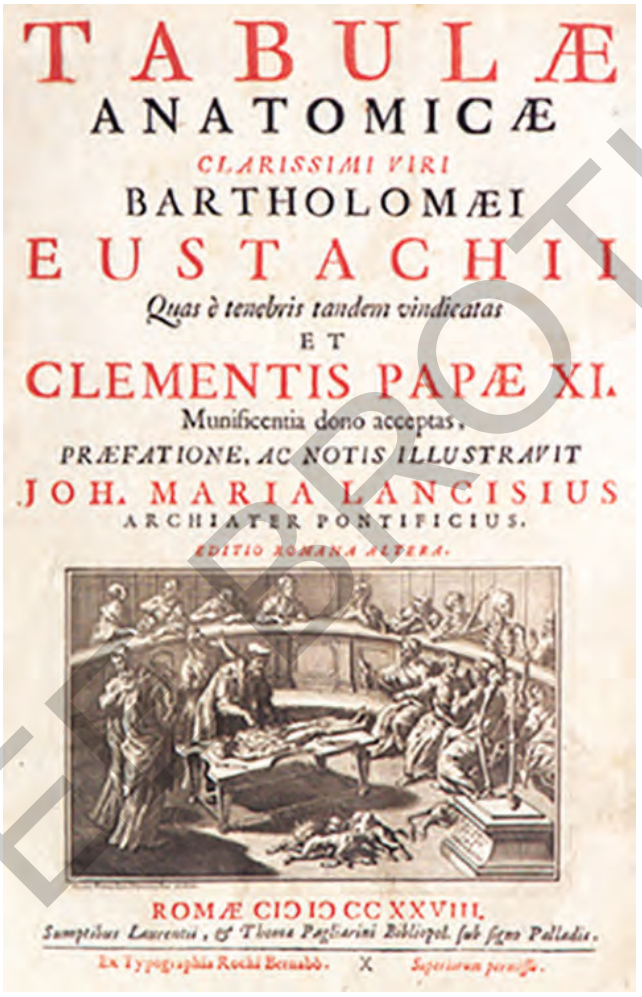
TABULÆ
ANATOMICÆ
CLARISSIMI VIRI
BARTHOLOMÆI
EUSTACHII
Quas è tenebris tandem vindicatas
ET
CLEMENTIS PAPÆ XI.
Munificentia dono acceptas,
PRÆFATIONE, AC NOTIS ILLUSTRAVIT
JOH. MARIA LANCISIUS
ARCHIATER PONTIFICIUS.
EDITIO ROMANA ALTERA.
ROMÆ CIↃ IↃ CC XXVIII.

Bartholomaeus Eustachius (1520–1574) in his book "Tabulae Anatomicae Bartholomei Eustachi quas a tenebris tandem vindicatas" which are anatomical illustrations of Bartolomeo Eustachi rescued from obscurity; first explained "Glandulae renibus incubentis" or "glands lying on the kidneys".

JAYPEE BROTHERS

THOMAS ADDISON

Thomas Addison (April 2, 1793 to June 29, 1860) was a renowned 19th century English physician and scientist. He is traditionally regarded as one of the "great men" of Guy's Hospital in London.

Among other pathologies, he discovered Addison's disease and Addisonian anemia (pernicious anemia).

He also described adrenal insufficiency in the year 1849 in the era where other endocrine functions had yet to be explained in detail, which he described from the autopsies he performed. At the time, there was no cure for adrenal insufficiency. Addison also noticed that 70–90% of patients with adrenal insufficiency had tuberculosis as well.



JAYPEE BROTHERS

If its fever, weight loss and other forces,
It could mean adrenal histoplasmosis,
You could be from Bangalore or from Rome,
You could be having Cushing's syndrome.
With a heart that's weak and a gut that's void,
It could mean, that its adrenal amyloid.
With Darkening skin and craving for salt,
Aldo and cortisol their production might halt.
With Racing heart and rising blood pressure,
In Phaeochromocytoma, it's not a pleasure.

JAYPEE BROTHERS

CASE 1

A 28-year-old lady presented with history of fever, weight loss, and cough for the past since 6 months. On examination, she had skin lesions over the face, palmar creases, and the oral mucosa (**Figures 1** to **3**). There were also episodes of abdominal pain and features suggestive of proximal myopathy. There was no history of vomiting, jaundice, or diarrhea. The chest X-ray is shown in **Figure 4**.

WHAT IS THE DIAGNOSIS?

Her investigations revealed low levels of serum sodium and high levels of serum potassium. Serum cortisol levels were undetectable with elevated adrenocorticotropic hormone (ACTH) levels (1,250 pg/mL). Considering hyperpigmentation with low blood pressure (BP) and a low serum sodium, primary adrenal insufficiency was diagnosed. She was given parenteral hydrocortisone.

Chest X-ray revealed a bilateral nodular and branching pattern involving the upper zones (**Figure 4**). Subsequently, she underwent a computed tomography (CT) scan of the thorax and abdomen, which confirmed the presence of nodular opacities involving the upper lobes of the lung bilaterally (**Figure 5**).

A CT scan of the abdomen also showed bilateral suprarenal masses (**Figures 6A** and **B**). A CT-guided adrenal fine-needle aspiration (FNA) biopsy revealed a granulomatous reaction with epithelioid histiocytes, lymphocytes, and multinucleate giant cells (**Figure 7**).



Figure 1: Hyperpigmentation of the face.



Figure 2: Mucosal hyperpigmentation.



Figure 3: Hyperpigmentation of the palmar creases (left: comparison with palm of patient's sibling).

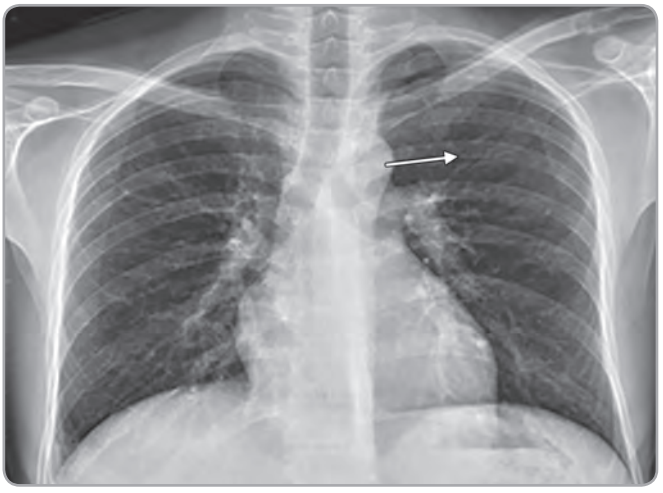

Figure 4: Nodular branching pattern involving the upper zone (shown with an arrow).

JAYPEE BROTHERS

Biopsies obtained from skin lesions and bone marrow grew *Histoplasma capsulatum*. She was then started on liposomal amphotericin B, which was later changed to itraconazole.

She was shifted to oral prednisolone and in due course of time, fludrocortisone was added following which the serum sodium levels were normalized. She responded well to the treatment and gained body weight by 10 kg over the next year and continues to be on regular follow-up.

DISCUSSION

Disseminated histoplasmosis occurs in 1:2,000 patients with acute infection. It is usually seen in patients with altered immunity and at extremes of age. Progressive illness, however, can be seen in acute stages of infection before cellular immunity evolves. *Histoplasma capsulatum* is a dimorphic fungus, which develops from microconidia that are inhaled into the lungs. It induces three types of tissue responses, including diffuse histoplasmosis, focal histoplasmosis, and tuberculoid granulomas.

Fungal culture remains the gold standard for the diagnosis, being positive in 75% of cases of disseminated histoplasmosis.[1]

The treatment includes intravenous liposomal amphotericin B (3–5 mg/kg/day) for 3 weeks followed by oral itraconazole 200 mg twice daily on a long-term basis.[2]



Figure 5: CT of the thorax showing nodular opacities involving the upper lobes of the lung (shown with an arrow).

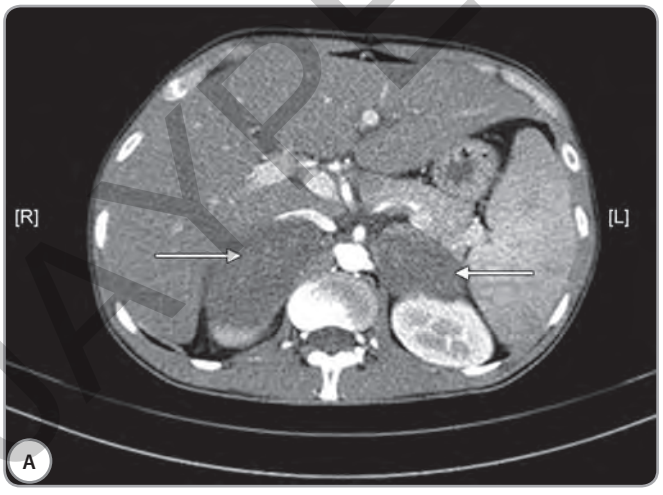

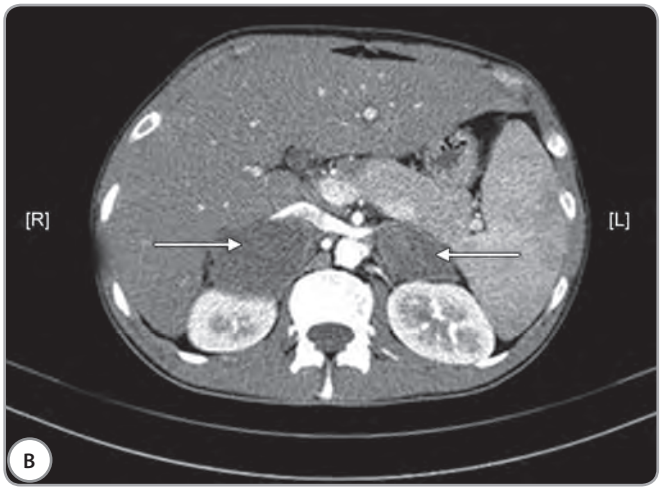

Figures 6A and B: CT of the abdomen with bilateral adrenal masses (shown with arrows).

JAYPEE BROTHERS

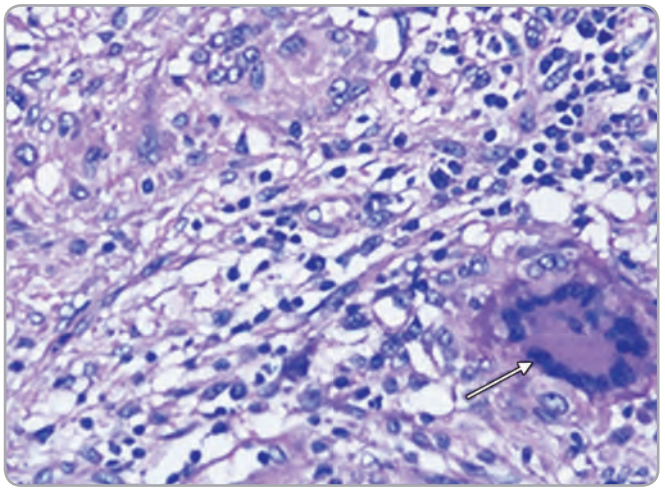

Figure 7: Figure illustrating a granulomatous reaction with epithelioid histiocytes, lymphocytes, and multinucleated giant cells (shown with an arrow) [hematoxylin and eosin (H and E) 200X magnification].

REFERENCES

1. Vyas S, Kalra N, Das PJ, Lal A, Radhika S, Bhansali A, et al. Adrenal histoplasmosis: An unusual cause of adrenomegaly. Indian J Nephrol. 2011;21(4):283-5.
2. Subramanian S, Abraham OC, Rupali P, Zachariah A, Mathews MS, Mathai D. Disseminated histoplasmosis. J Assoc Physicians India. 2005;53:185-9.

JAYPEE BROTHERS

CASE 2

A 36-year-old gentleman presented with an ulcer over the tongue for 4 months. The lesion had slowly increased in size and was associated with pain, odynophagia, and discomfort in speech. There was no history of associated trauma, intake of alcohol, smoking, or chewing tobacco. He ran a grocery store and was not involved in farming or excavation. On examination, a 2 × 2 cm ulcer with elevated margins was seen at the posterior aspect of the tongue (**Figure 1**). On palpation, the ulcer was tender and indurated.

WHAT IS THE DIAGNOSIS?

The patient's hemogram, chest X-ray, and human immunodeficiency virus (HIV) serology were normal. A biopsy of the ulcer revealed a characteristic "sunflowers in bloom" appearance of the macroconidia of *Histoplasma capsulatum* and the microconidia were also seen (**Figure 2**). Subsequently, he was started on oral itraconazole 200 mg thrice daily for 3 days followed by twice daily for 12 months.



Figure 1: An elevated ulcer in the posterior aspect of the tongue (shown with an arrow).

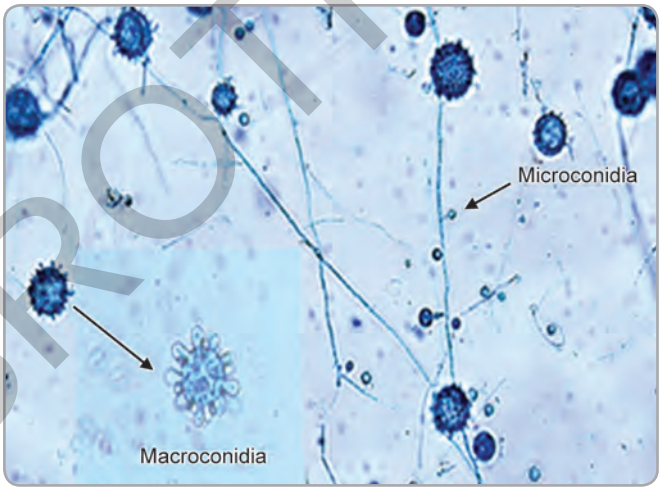

Figure 2: Lactophenol cotton blue preparation (400 X) showing macro- and microconidia of *Histoplasma capsulatum* (shown with arrows).

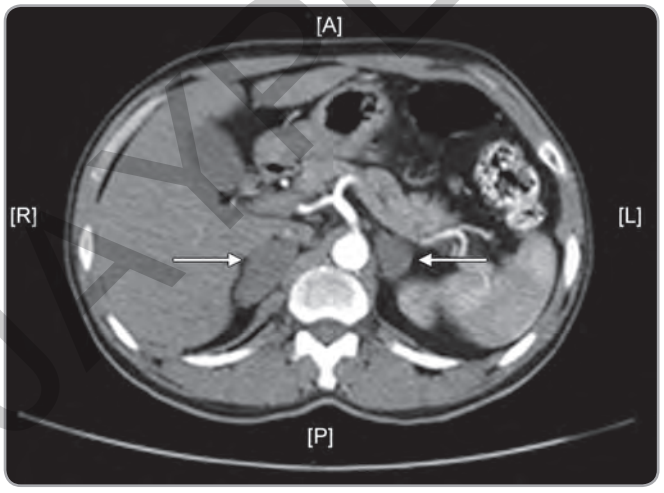

Figure 3: CT of the abdomen with contrast showing bilateral adrenal enlargement (shown with arrows).

JAYPEE BROTHERS

He also had bilateral adrenal enlargement (**Figure 3**) for which a CT-guided fine-needle aspiration cytology (FNAC) was done, which showed dimorphic capsulated fungi suggestive of histoplasmosis (**Figure 2**).

DISCUSSION

Histoplasmosis or Cave disease or Darling's disease was discovered in 1905 by Darling while working in the Canal Zone in Panama. Although localized oral lesions without any systemic involvement are uncommon, the presence of mucocutaneous lesions should always be considered as a manifestation of disseminated disease.[1] Goodwin et al. stated that the most characteristic lesion in chronic disseminated histoplasmosis is an oropharyngeal ulcer and is seen in up to 70% of cases.[2]

REFERENCES

1. Dunlap CL, Barnes WG. Oral histoplasmosis. J Mo Dent Assoc. 1969;49(7):26-9.
2. Goodwin RA, Shapiro JL, Thurman GH, Thurman SS, Prez RM. Disseminated histoplasmosis: clinical and pathologic correlations. Medicine (Baltimore). 1980;59(1):1-33.

JAYPEE BROTHERS

CLINICO-RADIOLOGICAL FINDINGS IN DISSEMINATED HISTOPLASMOSIS



Figure 1: Another patient showing histoplasmosis of the tongue (indicated with an arrow).

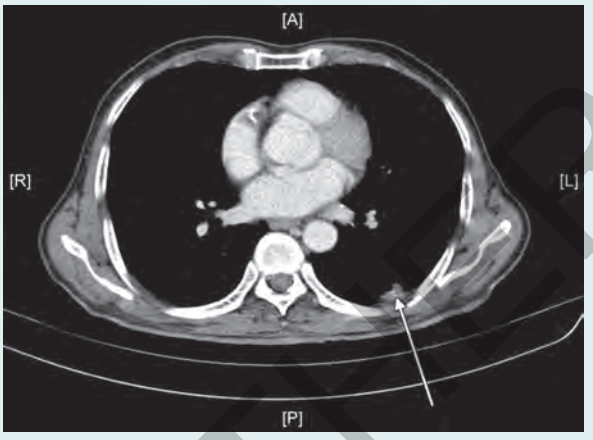

Figure 2: The aforementioned patient's CT thorax showing nodule in the left lung (shown with an arrow).

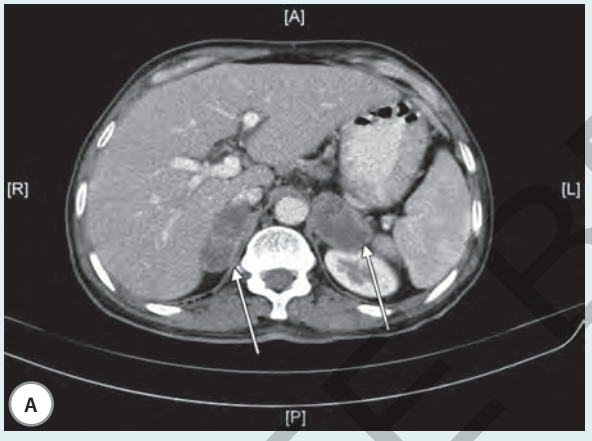



Figures 3A and B: CT scan of the adrenal glands showing bilateral hypodense lesions with heterogeneous enhancement replacing the adrenal glands (shown with arrows).

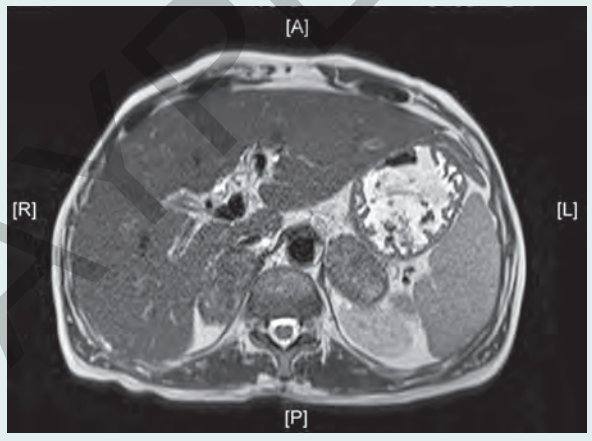

Figure 4: MRI of the abdomen showing bilateral enlarged heterogeneously hypointense adrenal lesions measuring 30 × 22 mm on the right and 36 × 21 mm on the left (shown with arrows).

A biopsy of the tongue lesion (**Figure 1**) was taken, which demonstrated macrophages containing intracellular round to oval capsulated small (3–5 µ) size yeast-like fungus resembling *Histoplasmosis capsulatum*. He was clinically and biochemically hypocortisolemic and hence was started on oral steroids. He was advised amphotericin B in view of disseminated histoplasmosis.

JAYPEE BROTHERS

CASE 3

A 28-year-old gentleman from Bangladesh presented with a history of intermittent fever, weight loss, and cough with expectoration for the past 6 months. On examination, he had multiple papular lesions with crust over the face (**Figures 1A** to **C**). A computed tomography (CT) scan of the abdomen that was done in his hometown showed bilateral adrenal gland enlargement (**Figures 2A** and **B**). He was empirically started on antitubercular therapy (ATT) by his family physician with no improvement. His biopsy showed a necrotic focus with a few small spherical structures resembling *Histoplasma* (**Figures 3A** and **B**). A silver methenamine and periodic acid-Schiff (PAS) diastase staining from the adrenal biopsy also revealed similar findings (**Figure 4**).

WHAT IS THE DIAGNOSIS?

This patient had biochemical features suggestive of hypocortisolemia and was diagnosed to have histoplasmosis of the face and adrenal glands. He was given prednisolone with fludrocortisone and itraconazole.

DISCUSSION

In India, the Gangetic state of West Bengal is the site of the most frequent infections.[1] *Histoplasma capsulatum* was isolated from the local soil proving endemicity to West Bengal. The soil content that is rich in nitrogen content as well as those enriched with birds' droppings, especially



Figures 1A to C: Plaques with crusts over the face (shown with the arrows).

JAYPEE BROTHERS

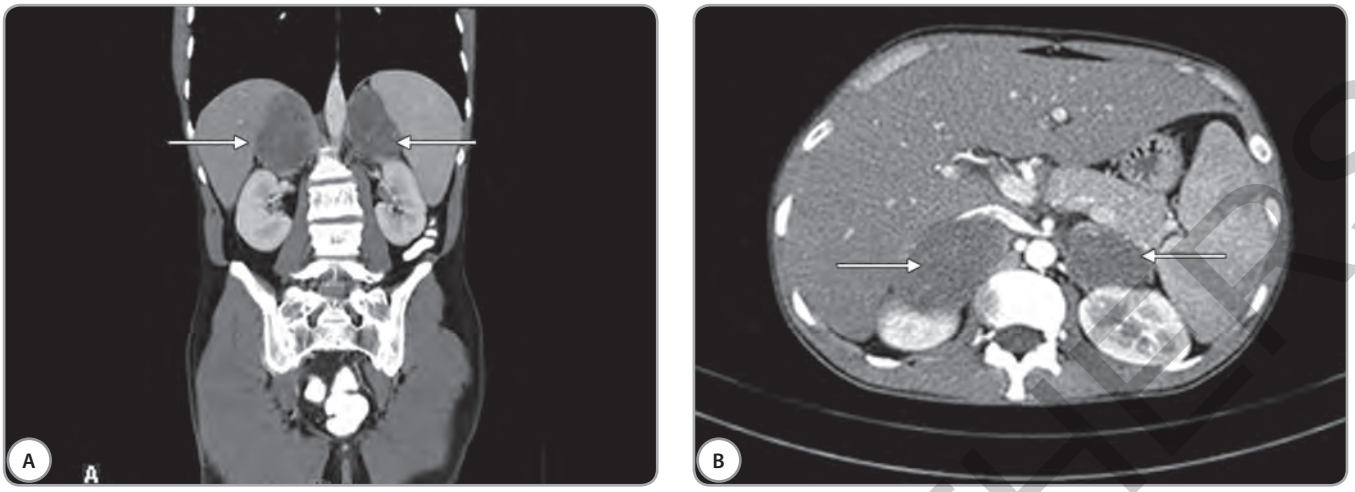

Figures 2A and B: CT of the abdomen showing bilateral enlarged adrenal glands (shown with arrows).

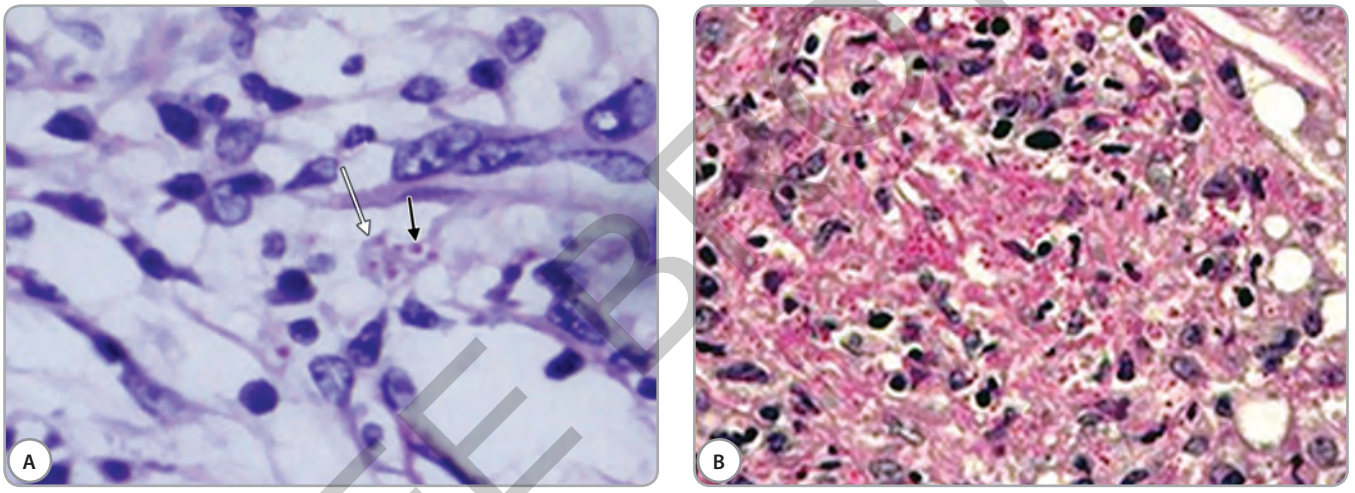

Figures 3A and B: Histopathological specimen from the adrenal gland showing a necrotic focus (shown with a white arrow) with few small spherical structures (shown with a black arrow) (periodic acid-Schiff with diastase, 400X magnification).

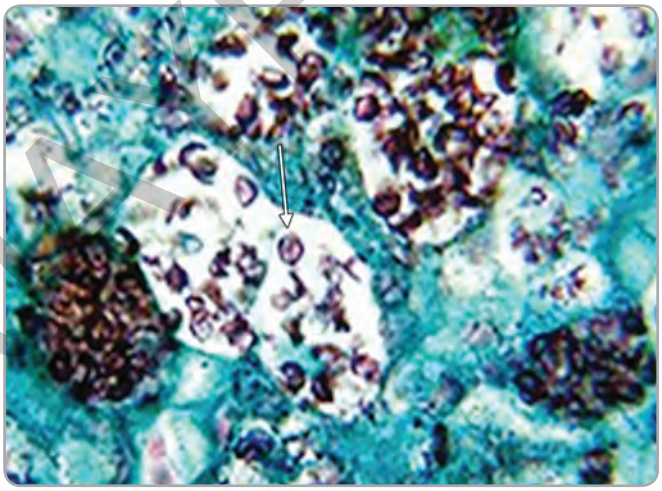

Figure 4: Silver methenamine staining of the adrenal gland biopsy tissue showing spherical microorganisms (shown with an arrow) and necrotic tissue.

JAYPEE BROTHERS

bats, is a source for *Histoplasma*. Hence, the soil with birds' droppings is a natural reservoir for this fungus and particularly beneath the trees where these birds rest in the nighttime.

The mode of infection is by the inhalation of the dimorphic soil fungus. These noncontagious organisms reach alveolar spaces wherein they multiply inside the mononuclear phagocytes. Under microscopy, the organisms will be seen as delicate, septate hyphae, and 1–2 μ thick with large rough-walled macroconidia measuring around 5–15 μ. In the Sabouraud's dextrose agar culture plate, they usually grow as a tan-white-brown woolly mold at 25–30°C. The organism reverts to yeast form at 37°C on sheep blood agar.[2]

REFERENCES

1. Sanyal M, Thammayya A. Histoplasma capsulatum in the soil of Gangetic Plain in India. Indian J Med Res. 1975;63(7): 1020-8.
2. Ajello L, Hay RJ. Medical mycology. In: Topley WWC, Wilson GS (Eds). Topley and Wilson's Microbiology and Microbial Infections, 9th edition. London: Arnold Publishers; 1997.

JAYPEE BROTHERS

detailed information on endocrinology books, visit our website www.jaypeebrothers.com, for detailed information on endocrinology books, visit our website www.jaypeebr

Clinical Atlas in
ENDOCRINOLOGY & DIABETES
A Case-based Compendium

Salient Features

- The Endocrine Emporium: *Clinical Atlas in Endocrinology and Diabetes*, Second Edition, is a comprehensive color atlas that covers every branch of "Endocrinology: Thyroid, Diabetes, Bone, Pituitary, Adrenal, and other Miscellaneous areas".
- This "Compendium" has problem-based clinical cases, which are serially interrogative and provide comprehensive diagnoses and therapeutic solutions with appropriate cross-references for further reading. Beyond the domain of clinical problems: The radiology, histopathology, and genetic profiles of patients are provided.
- The depth of information is of an encyclopedical quantum. Yet the simplicity may cater to endocrinologists, physicians, surgeons, general practitioners, and students alike!
- Further enticement is provided in the form of multiple choice questions for every section, selected from the best of question banks to tease the mind and also to prepare for a career pathway involving objective evaluative processes.

Nihal Thomas MBBS MD (Gen Med) MNAMS DNB (Endo) FRACP (Endo) FRCP (Edin) FRCP (Glas) FRCP (London) FACP PhD (Copenhagen) was former Vice Principal for Research, former Associate Director, and is professor of endocrinology at the Christian Medical College, Vellore, a 120-year-old tertiary care institution in Southern India. He has published more than 260 indexed publications and several chapters in books. He has initiated the integrated diabetes system and established a sustainable educational program for training of diabetes educators and doctors over the last decade having an international impact. Key research interest involves pathogenesis and evolution of diabetes in the young, relation to low birthweight, genomics, and also general endocrinology. The Department of Endocrinology, Christian Medical College, Vellore, Tamil Nadu was awarded the British Medical Journal South Asia award for diabetology team of the year (2015) and the Royal College of Physicians (London) award for teaching and training (2017).

Felix Jebasingh K MBBS MD (Gen Med) DM (Endo) DNB (Endo) PGDMLE (Med Law) is an Associate Professor in endocrinology at the Department of Endocrinology, Diabetes, and Metabolism at the Christian Medical College, Vellore, India and at CMC Vellore, Chittoor campus. He spearheads the once-weekly integrated diabetic foot clinic in conjunction with the departments of general surgery, vascular surgery, physical medicine and rehabilitation, physiotherapy as well as prosthetics and orthotics, respectively, in both the Vellore and the Chittoor campuses. He has 52 publications in various national as well as international journals and has written over 15 chapters in various textbooks on endocrinology and medicine. He has been a part of 20 multinational clinical trials as a principal investigator or coinvestigator. He has obtained funding from the Indian Council of Medical Research for the initiation of an epidemiological survey on non-communicable diseases in Meghalaya, India.

Mathews E Kurian MBBS is a research officer at the Department of Endocrinology, Diabetes and Metabolism at Christian Medical College, Vellore. He has been keenly involved in clinical trials and translational research with special focus toward pancreatic clamp studies in low BMI diabetes. His areas of interest include diabetes and health technology.

Printed in India

Available at all medical bookstores
or buy online at www.jaypeebrothers.com

JAYPEE BROTHERS
Medical Publishers (P) Ltd.
EMCA House, 23/23-B, Ansari Road,
Daryaganj, New Delhi - 110 002, INDIA
www.jaypeebrothers.com

Join us on facebook.com/JaypeeMedicalPublishers

Shelving Recommendations
ENDOCRINOLOGY
DIABETES

ISBN 978-93-89587-30-2